

Case Report

Ureteroarterial fistula following retrograde ureteral stenting in a patient with a double-barreled wet colostomy for cervical cancer[☆]

Marek Siorek^{a,1}, Brent Tierney^{b,1}, Jeffrey Fowler^b, Joshua D. Dowell^{a,*}^a Department of Radiology, Division of Interventional Radiology, The Ohio State University Wexner Medical Center, 395 W 12th Avenue, Columbus, OH 43210, USA^b Department of Obstetrics and Gynecology, Division of Gynecologic Oncology, The Ohio State University Wexner Medical Center, 395 W 12th Avenue, Columbus, OH 43210, USA

ARTICLE INFO

Article history:

Received 13 April 2015

Received in revised form 10 June 2015

Accepted 18 June 2015

Available online 23 June 2015

Keywords:

Arterial fistula
Ureteral stenting
Double barrel
Embolization

1. Introduction

Ureteroarterial fistula (UAF) is a rare cause of massive hematuria. As surgical and percutaneous approaches evolve, rare causes of bleeding from an ostomy need to be considered. The following case highlights the successful treatment of UAF in a cervical cancer patient with percutaneously converted retrograde ureteral stents via a double-barreled wet colostomy (DBWC), the formation of a single stoma for urinary and fecal diversion, after total exenteration.

2. Case report

A 64-year-old woman was diagnosed with stage IIIB adenocarcinoma of the cervix in August 2010. She was treated with combined modality chemotherapy and pelvic radiation. She underwent a total pelvic exenteration for local recurrence two years later with creation of a

DBWC and 6F bilateral ureteral stents for progressive dilation of the ureteral obstruction. Two weeks following surgery and prior to the scheduled routine removal of her bilateral ureteral stents, she presented with fever, nausea and hypotension. Bilateral percutaneous nephrostomy tubes were placed for hydronephrosis and the dislodged left and occluded right ureteral stents were removed.

Given her diagnosis, she wished to proceed with conversion to retrograde ureteral stents for improved quality of life measures, despite discussions on the increased risk of infection due to her DBWC. A staged conversion under fluoroscopy of the existing bilateral nephrostomy tubes was performed for nephroureteral stents (Cook, Inc., Bloomington, Indiana) and ultimately to 10.2 F retrograde ureteral stents (Cook, Inc., Bloomington, Indiana) (Fig. 1a) (Alago et al., 2008). The stents were then exchanged under fluoroscopic guidance every four weeks.

Seven months following initial conversion to retrograde stents and during a planned ureteral stent exchange, she complained of small blood clots from the ostomy. Nephrostograms during stent exchange demonstrated large bilateral filling defects in each collecting system. She was admitted and computed tomography (CT) and emergent selective catheter angiography for episodic bleeding were negative for active bleeding (Fig. 1b). Additionally, given the inherent difficulty in localizing a bleeding source in the setting of a DBWC, a technetium-99 m tagged red blood cell study was performed with multi-slice single photon emission CT (SPECT/CT) demonstrating increased uptake within the distal bowel and adjacent left ureter.

Emergent selective catheter angiography was again performed secondary to persistent severe hematuria. Angiography of the right common iliac artery revealed communication at the iliac artery bifurcation into the crossing right ureter (Fig. 1c). This suggested that the SPECT/CT findings were likely due to refluxing blood to the left ureter and bowel. To effectively exclude the UAF, the internal iliac artery was initially coil embolized (Tornado; Cook Medical, Bloomington, IN), to prevent the risk for future retrograde arterial flow from the internal iliac artery, followed by placement of a 10 mm × 3.8 cm covered stent graft (iCAST; Atrium Medical Corp, Hudson, NH) extending from the common iliac artery to the external iliac artery. The iCAST covered stent was chosen secondary to its low profile relative to other devices (Madoff et al., 2002). Post intervention angiogram revealed exclusion of the fistula (Fig. 1d). She had no additional episodes of bleeding, was discharged, and at nineteen months post intervention, she remains in good health without hematuria or infection.

Abbreviations: UAF, Ureteroarterial fistula; DBWC, Double-barreled wet colostomy; CT, Computed tomography; SPECT/CT, Multi-slice single photon emission CT.

[☆] None of the authors have a conflict of interest.

* Corresponding author at: The OH State University Wexner Medical Center, 395 W 12th Avenue, Suite, Columbus, OH 43210, USA.

E-mail address: Joshua.Dowell@OSUMC.edu (J.D. Dowell).

¹ Authors contributed equally to this work.

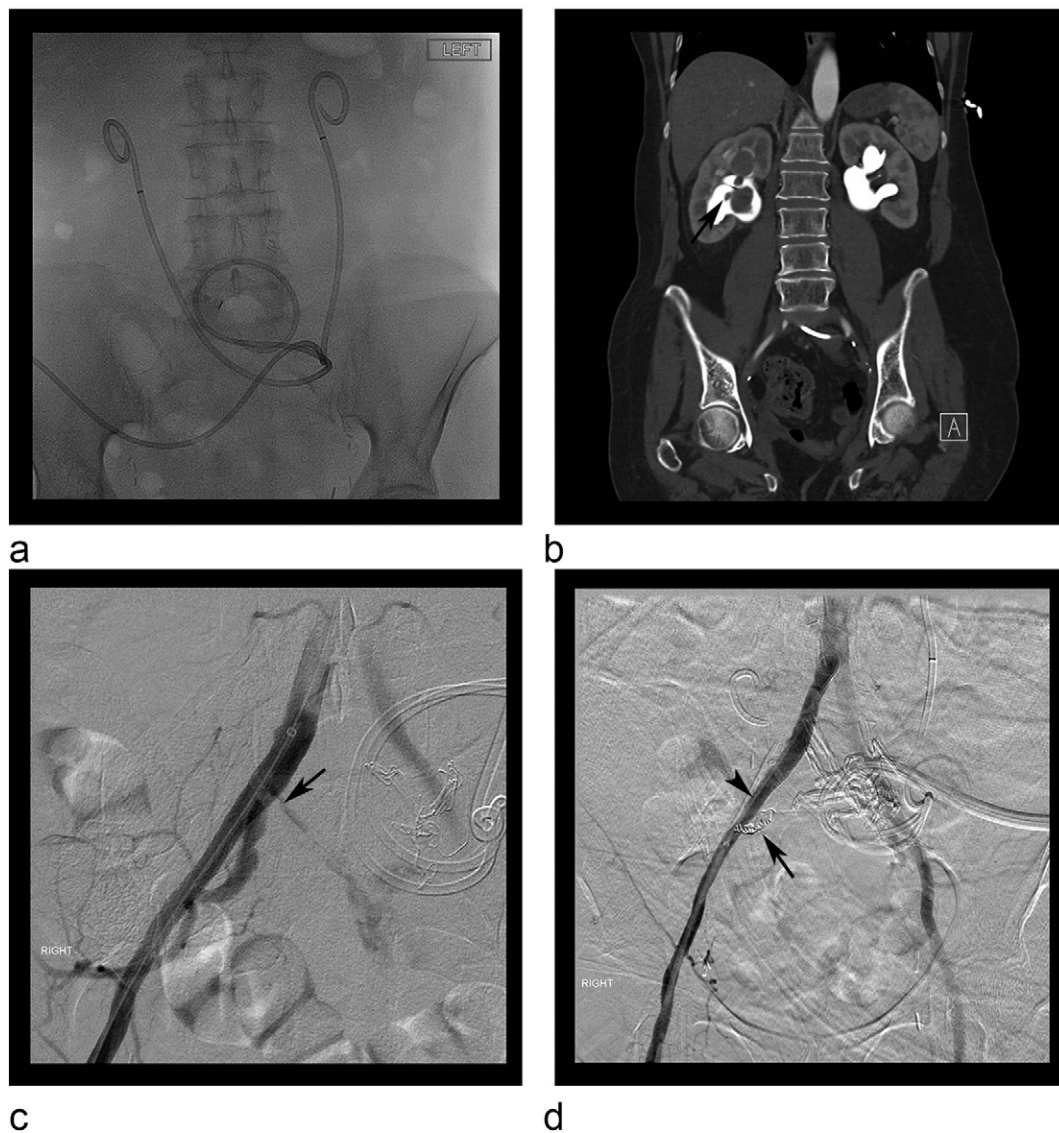


Fig. 1. (A) Abdominal radiograph demonstrating position of bilateral retrograde ureteral stents via the DBWC. (B) Coronal CT angiogram image revealing filling defects representing blood clots in the right renal collecting system (arrow). (C) Right common iliac artery digital subtraction angiography demonstrating fistulous communication at the level of the bifurcation with the passing right ureter (arrow). (D) Successful exclusion of the ureteroarterial fistula on post contrast angiography by right common iliac artery covered stent placement (arrowhead) and coil embolization of the internal iliac artery (arrow).

3. Discussion

UAF is a rare complication where a fistulous tract is created between an artery and a ureter. Risk factors include pelvic surgery, external beam radiation, and ureteral catheterization. Radiation or surgery causes fibrosis of the ureter to the adjacent artery (Fox et al., 2011; Okada et al., 2013; Van den Bergh et al., 2009). An indwelling ureteral stent can lead to alterations in ureteral elasticity and transmit adjacent arterial pulsations onto the ureteral wall. This repetitive force may eventually cause pressure necrosis and subsequent fistula formation (Okada et al., 2013). Indeed, the diagnosis should be considered in patients with ureteral stents, particularly those with a history of radiation therapy or ureteral surgery, presenting with large hematuria. The primary treatment is endovascular intervention with a reported 85% primary success rate (Fox et al., 2011). If the angiogram is negative, provocative angiography with removal of each retrograde ureteral stent over wire can be attempted (Okada et al., 2013). If provocative angiography is also unsuccessful, operative approaches may be entertained. In our case a technetium-99 m tagged RBC study was also performed with SPECT/CT which can detect bleeding from a gastrointestinal source at a rate

of 0.1 ml/min and has a sensitivity of 78.6–97% and specificity of 70.4–100% (Currie et al., 2011). Comparatively, angiography requires a bleeding rate of at least 1 ml/min and has a sensitivity of 47% and specificity of 100% to detect active bleeding (Currie et al., 2011). In situations in which the source of bleeding may be challenging to differentiate, a tagged RBC study may allow exclusion a gastrointestinal source.

A DBWC is less common than double diversion (two separate ostomies) for the treatment of metastatic cervical cancer (Backes et al., 2013; Guimaraes et al., 2006); however, it requires a single stoma and prevents surgical intervention in the small bowel. Although the use of retrograde ureteral stents is an unconventional approach for a patient with a DBWC, this patient did well, preferred the convenience of ureteral stenting rather than persistent nephrostomy tubes, and remained without infection. In the setting of a compliant patient with close follow-up, this patient's experience may prompt the safe use of retrograde ureteral stenting in similar patients. The role for anticoagulation or antibiotics are unclear following stent graft placement in a UAF (Alago et al., 2008). Given that our patient had a DBWC and the hazardous environment that this stent graft was deployed, she was prophylactically treated with oral ciprofloxacin upon discharge.

The present case describes a patient with recurrent cervical cancer who had a DBWC, with inherent increased difficulty in localizing the bleeding, coupled with a unique history of multimodal medical, surgical and procedural therapies. Indeed, as surgical and percutaneous approaches continue to evolve, the source of rare causes for hematuria may become increasingly challenging to identify. Therefore, an understanding of the anatomy, risk factors, surgical history, and endovascular treatment options will be important in making these more rare diagnoses and providing prompt patient care.

Conflict of interest statement

The authors declare no conflicts.

Informed consent was obtained from the patient for publication of this case report and accompanying images.

Transparency document

The [Transparency document](#) associated with this article can be found, in online version.

References

- Alago, W.J.R., Sofocleous, C.T., Covey, A.M., et al., 2008. Placement of transileal conduit retrograde nephroureteral stents in patients with ureteral obstruction after cystectomy: technique and outcome. *AJ. Am. J. Roentgenol.* 191, 1536–1539.
- Backes, F.J., Tierney, B.J., Eisenhauer, E.L., et al., 2013. Complications after double-barreled wet colostomy compared to separate urinary and fecal diversion during pelvic exenteration: time to change back? *Gynecol. Oncol.* 128 (1), 60–64.
- Currie, G.M., Kiat, H., Wheat, J.M., 2011. Scintigraphic evaluation of acute lower gastrointestinal hemorrhage: current status and future directions. *J. Clin. Gastroenterol.* 45 (2), 92–99.
- Fox, J.A., Krambeck, A., McPhail, E.F., et al., 2011. Ureteroarterial fistula treatment with open surgery versus endovascular management: long-term outcomes. *J. Urol.* 185, 945–950.
- Guimaraes, G.C., Ferreira, F.O., Rossi, B.M., et al., 2006. Double-barreled wet colostomy is a safe option for simultaneous urinary and fecal diversion. analysis of 56 procedures from a single institution. *J. Surg. Oncol.* 93, 206–211.
- Madoff, D.C., Toombs, B.D., Skolkin, M.D., et al., 2002. Endovascular management of ureteral-iliac artery fistulae with Wall-Graft endoprosthesis. *Gynecol. Oncol.* 85, 212–217.
- Okada, T., Yamaguchi, M., Muradi, A., et al., 2013. Long-term results of endovascular stent graft placement of ureteroarterial fistula. *Cardiovasc. Intervent. Radiol.* 36, 950–956.
- Van den Bergh, R.D., Moll, F.L., de Vries, J.P., et al., 2009. Arterioureteral fistulas: unusual suspects—systemic review of 139 cases. *Urology* 74, 251–255.