

Rare Case of Tension Pneumocephalus in Thoracic Trauma

Oana M. Stroie¹, Kyle V. Keinath², Christopher M. Knaus²

1. Diagnostic Radiology, Uniformed Services University of the Health Sciences, Bethesda, USA 2. Diagnostic Radiology, Walter Reed National Military Medical Center, Bethesda, USA

Corresponding author: Oana M. Stroie, omstroie@gmail.com

Abstract

Tension pneumocephalus is the presence of air within the cranial vault compressing the ventricles and the brain parenchyma. High altitudes can exacerbate this problem, especially when a dural defect exists and air is forced into the cranial cavity with no way to escape. This case demonstrates a rare presentation of thoracic trauma causing tension pneumocephalus due to emergent air evacuation.

Categories: Radiology, Neurosurgery, Trauma

Keywords: tension pneumocephalus, thoracic trauma, pneumocephalus, mount fuji sign, neurosurgery

Introduction

Pneumocephalus is the presence of air within the cranial vault. It is most often associated with craniofacial trauma, especially injuries involving the basilar skull. Other causes include cranial surgery, nasopharyngeal tumor invasion, infection, and epidural or spinal anesthesia [1,2]. There is a very limited number of reported cases involving thoracic and lumbar trauma, as in ours. Clinically, pneumocephalus may be asymptomatic. However, depressed mental status, headache, confusion, nausea, vomiting, seizures, dizziness, Cushing response, restlessness, focal neurological deficits, and cardiac arrest have been described and are more associated with tension versus nontension pneumocephalus [1,3,4].

Two mechanisms have been proposed to explain pneumocephalus, namely, “the inverted soda bottle mechanism” and “the ball valve mechanism.” In the first, leakage of cerebrospinal fluid (CSF) creates negative intracranial pressure causing a vacuum-like effect with additional accumulation of air within the cranial cavity until the pressure gradient is fixed or stable. The second is based on the presence of a one-way valve at the site of the leptomeningeal tear, where air is forced into the cranial cavity with no way to escape [5].

Case Presentation

A 45-year-old man was air evacuated with a gunshot wound to the chest. His condition worsened during transport. On arrival, CT imaging revealed multiple penetrating chest traumas and tension pneumocephalus (Figures 1, 2). The patient died soon afterward.

Review began 06/19/2021

Review ended 06/22/2021

Published 07/03/2021

© Copyright 2021

Stroie et al. This is an open access article distributed under the terms of the Creative Commons Attribution License CC-BY 4.0., which permits unrestricted use, distribution, and reproduction in any medium, provided the original author and source are credited.

How to cite this article

Stroie O M, Keinath K V, Knaus C M (July 03, 2021) Rare Case of Tension Pneumocephalus in Thoracic Trauma. Cureus 13(7): e16136. DOI 10.7759/cureus.16136

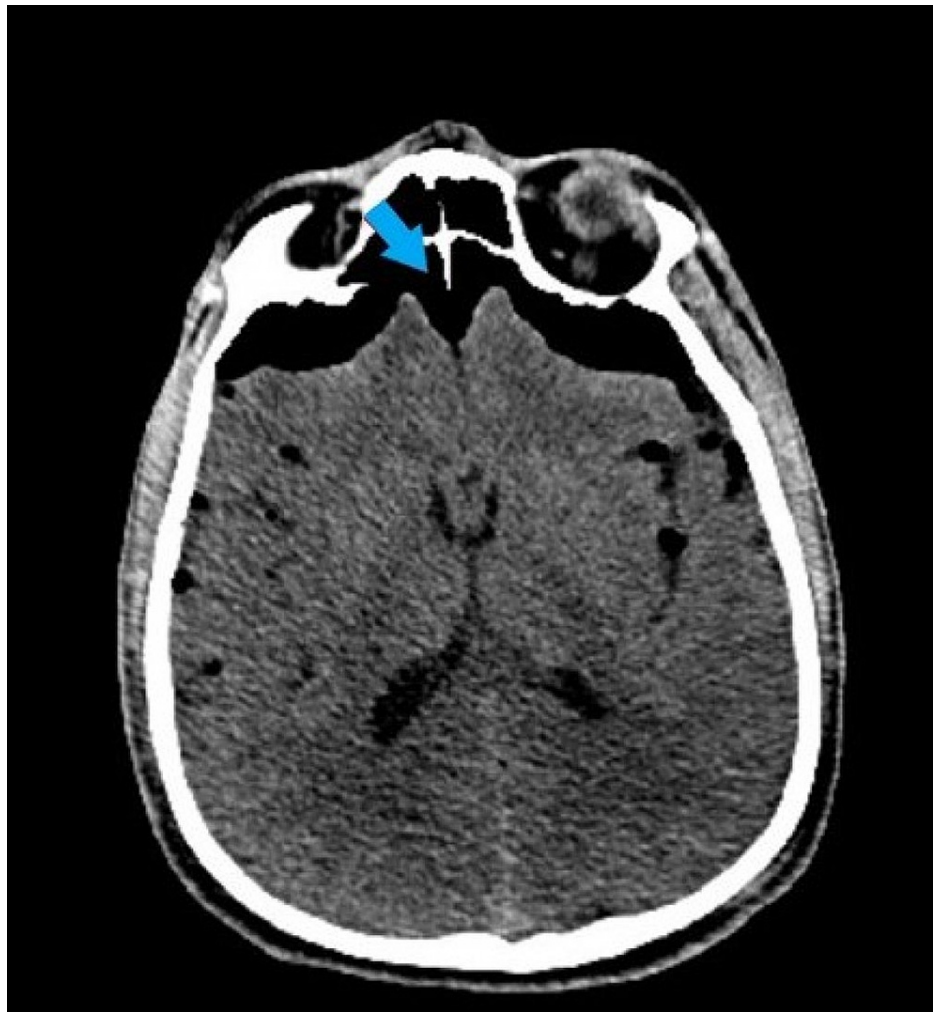

FIGURE 1: Noncontrast head CT through the frontal sinuses demonstrates the “Mount Fuji sign” of tension pneumocephalus (blue arrow).

CT: computed tomography

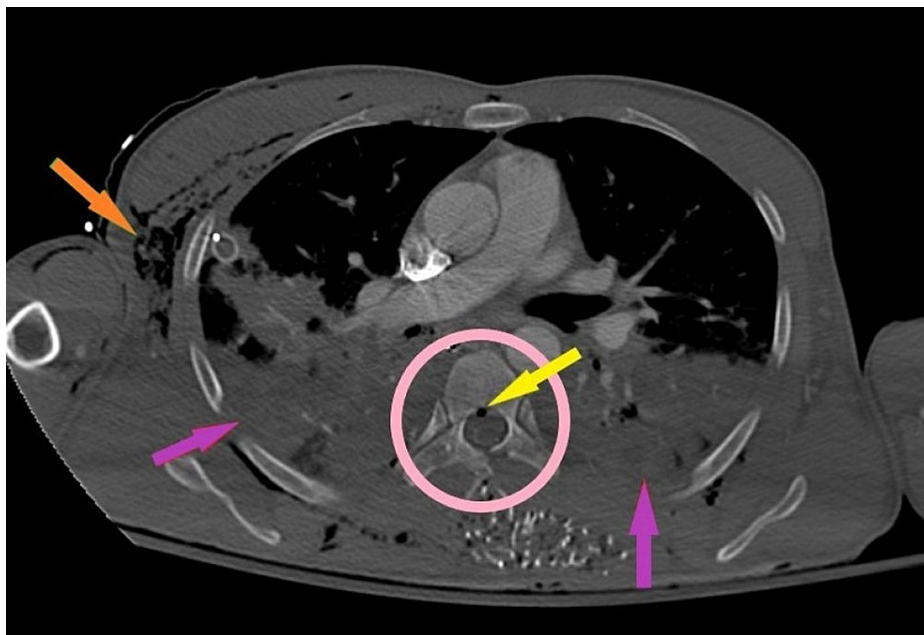


FIGURE 2: Contrast-enhanced CT with an axial bone window of the chest.

The orange arrow points to subcutaneous emphysema. The purple arrow points to bilateral hemorrhagic pleural effusions. The pink circle highlights the right costovertebral junction, right pedicle, and left lamina of T6 that is completely shattered. The yellow arrow points to hemorrhagic material in the spinal cord with punctate foci of gas.

CT: computed tomography

Discussion

The case is poignant especially for military medical providers operating in austere environments where patient transportation can often involve aircraft flights. On experiencing reduced atmospheric pressure, the volume of air within the cranium of a tension pneumocephalus patient will expand, as defined by $PV = nRT$ (the ideal gas law equation states that pressure multiplied by volume equals the number of gas moles multiplied by the universal gas constant and temperature). This expansion can cause an increased mass effect on the brain. In our case, given the physiology at initial presentation, we believe that an expanded tension pneumocephalus caused early brain herniation with pressure upon the brain stem causing central respiratory compromise and death.

In our case, thoracic penetration with associated spinal fracture allowed air entry into the spinal canal by the “ball valve mechanism” with direct air entry into the subarachnoid space creating an expanding tension pneumocephalus that was further exacerbated by changes in elevation during emergent air transport.

Tension pneumocephalus is a neurosurgical emergency and early identification is key to treatment. The entry of air can often create an early “peaking sign” with the compression of the frontal lobes on CT head imaging. As the entry of air surpasses the surface tension between CSF and the frontal lobes, it leads to a collapse of the frontal lobes and widening of the interhemispheric space creating the classic “Mount Fuji sign” that is characteristic of tension pneumocephalus [6]. When tension pneumocephalus is detected via imaging, immediate neurosurgery treatment is needed in the forms of needle aspiration, drilling of burr holes, craniotomy, ventriculostomy, and closure of the dural defect [5,6].

Conclusions

Tension pneumocephalus is a very rare complication of penetrating spine trauma that can be exacerbated by flight evacuation, and therefore, needs to be considered when transporting patients. The “Mount Fuji sign” is a continuation of the early “peaking sign” on head imaging. It is a characteristic finding of tension pneumocephalus and indicates that the gas is exerting a mass-like effect that exceeds the surface tension of CSF leading to a collapse of the frontal lobes and widening of the interhemispheric space. Tension pneumocephalus is a neurosurgical emergency and can be a result of trauma, infections, erosive pathology of the sinuses, and iatrogenic from neurosurgery or intrathecal anesthesia.

Additional Information

Disclosures

Human subjects: Consent was obtained or waived by all participants in this study. **Conflicts of interest:** In compliance with the ICMJE uniform disclosure form, all authors declare the following: **Payment/services info:** All authors have declared that no financial support was received from any organization for the submitted work. **Financial relationships:** All authors have declared that they have no financial relationships at present or within the previous three years with any organizations that might have an interest in the submitted work. **Other relationships:** All authors have declared that there are no other relationships or activities that could appear to have influenced the submitted work.

Acknowledgements

The views expressed herein are those of the authors and do not reflect the official policy or position of Uniformed Service University, Departments of the Army or Navy, Department of Defense, or the US Government.

References

1. Schirmer CM, Heilman CB, Bhardwaj A: Pneumocephalus: case illustrations and review. *Neurocrit Care*. 2010, 13:152-8. [10.1007/s12028-010-9363-0](https://doi.org/10.1007/s12028-010-9363-0)
2. Katz DS, Groskin SA, Wasenko JJ: Pneumothorax and pneumocephalus caused by pneumothorax and multiple thoracic vertebral fractures. *Clin Imaging*. 1994, 18:85-7. [10.1016/0899-7071\(94\)90154-6](https://doi.org/10.1016/0899-7071(94)90154-6)
3. Clement AR, Palaniappan D, Panigrahi RK: Tension pneumocephalus. *Anesthesiology*. 2017, 127:710. [10.1097/ALN.0000000000001703](https://doi.org/10.1097/ALN.0000000000001703)
4. Satapathy GC, Dash HH: Tension pneumocephalus after neurosurgery in the supine position. *Br J Anaesth*. 2000, 84:115-7. [10.1093/oxfordjournals.bja.a013368](https://doi.org/10.1093/oxfordjournals.bja.a013368)
5. Pillai P, Sharma R, MacKenzie L, Reilly EF, Beery PR 2nd, Papadimos TJ, Stawicki SP: Traumatic tension pneumocephalus - two cases and comprehensive review of literature. *Int J Crit Illn Inj Sci*. 2017, 7:58-64. [10.4103/IJCIIS.IJCIIS_8_17](https://doi.org/10.4103/IJCIIS.IJCIIS_8_17)
6. Michel SJ: The Mount Fuji sign. *Radiology*. 2004, 232:449-50. [10.1148/radiol.2322021556](https://doi.org/10.1148/radiol.2322021556)