

Successful High Flow Nasal Oxygen Therapy for Excessive Dynamic Airway Collapse: A Case Report

Jisoo Park, M.D.^{1,2}, Yeon Joo Lee, M.D.², Se Joong Kim, M.D.², Jong Sun Park, M.D.², Ho Il Yoon, M.D.², Jae Ho Lee, M.D.², Choon-Taek Lee, M.D.² and Young-Jae Cho, M.D.²

¹Division of Pulmonology, Department of Internal Medicine, CHA University, CHA Bundang Medical Center, Seongnam,

²Division of Pulmonary and Critical Care Medicine, Department of Internal Medicine, Seoul National University College of Medicine, Seoul National University Bundang Hospital, Seongnam, Korea

Excessive dynamic airway collapse (EDAC) is a disease entity of excessive reduction of the central airway diameter during exhalation, without cartilage collapse. An 80-year-old female presented with generalized edema and dyspnea at our hospital. The patient was in a state of acute decompensated heart failure due to pneumonia with respiratory failure. We accordingly managed the patient with renal replacement therapy, mechanical ventilation and antibiotics. Bronchoscopy confirmed the diagnosis of EDAC. We scheduled extubation after the improvement of pneumonia and heart condition. However, extubation failure occurred due to hypercapnic respiratory failure with poor expectoration. Her EDAC was improved in response to high flow nasal oxygen therapy (HFNOT). Subsequently, the patient was stabilized and transferred to the general ward. HFNOT, which generates physiologic positive end expiratory pressure (PEEP) effects, could be an alternative and effective management of EDAC. Further research and clinical trials are needed to demonstrate the therapeutic effect of HFNOT on EDAC.

Keywords: Airway Obstruction; Oxygen Inhalation Therapy; Pressure

Introduction

Excessive dynamic airway collapse (EDAC) is defined as more than 50% reduction of the sagittal diameter of the tra-

Address for correspondence: Young-Jae Cho, M.D.

Division of Pulmonary and Critical Care Medicine, Department of Internal Medicine, Seoul National University Bundang Hospital, Seoul National University College of Medicine, 82 Gumi-ro 173beon-gil, Bundang-gu, Seongnam 13620, Korea

Phone: 82-31-787-7058, **Fax:** 82-31-787-4052

E-mail: lungdrcho@gmail.com

Received: May 22, 2015

Revised: Jun. 19, 2015

Accepted: Jun. 19, 2015

© It is identical to the Creative Commons Attribution Non-Commercial License (<http://creativecommons.org/licenses/by-nc/4.0/>).

Copyright © 2015

The Korean Academy of Tuberculosis and Respiratory Diseases.

All rights reserved.

chea in forced expiration or during coughing. It is characterized by an excessive collapse of the posterior membranous trachea towards the lumen without cartilage collapse¹⁻⁴. EDAC presents with a variety of symptoms ranging from mild shortness of breath or cough to respiratory failure^{5,6}. Advances in imaging modalities, including bronchoscopy and dynamic radiographic studies, allow increased recognition of EDAC⁷. Current therapeutic management of EDAC includes conservative medical therapy, including bronchodilators and continuous positive airway therapy, and minimally invasive and open surgical interventions⁸.

Recently, there has been growing interest in high flow nasal oxygen therapy (HFNOT). HFNOT has been known to generate physiological positive airway pressure effect. Therefore, it was suggested that HFNOT could be replace to continuous positive airway pressure (CPAP) or non-invasive positive pressure ventilation (NIPPV)⁹. However, there was no study about HFNOT was used in management of EDAC.

Herein, we report a case of EDAC that caused inability to

wean from mechanical ventilation, and which was successfully managed with HFNOT.

Case Report

An 80-year-old female came to hospital because of general weakness for 1 week. She had diabetes mellitus and diastolic heart failure previously. She had symptoms like cough, increased sputum and 14 kg weight gain for 1 month (from 48 to 62 kg). At initial, her saturation (SpO_2) was 78% in room air. There were wheezing and diffuse crackle sound in both whole lung fields. Multifocal patchy consolidations in right upper lobe and both lower lobe were presented in her chest anteroposterior and chest computed tomography (CT) (Figure 1). White blood cell (WBC) count was $7,900/\mu\text{L}$, blood urea nitrogen/serum creatinine $48/1.83 \text{ mg/dL}$, FeNa 1.28%,

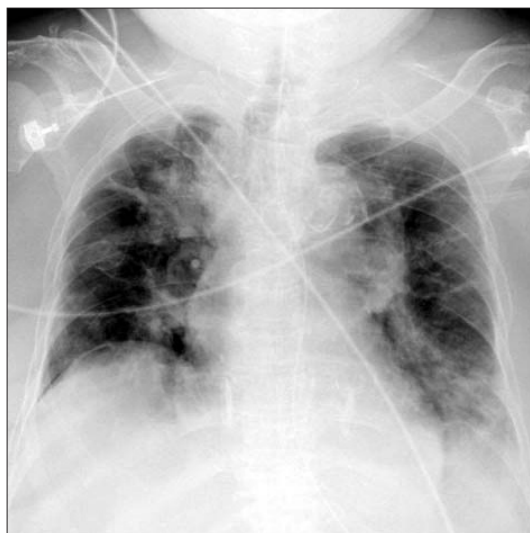

Figure 1. The initial chest radiography at our hospital shows patchy consolidations in left lower lung field and right upper lung field.

N-terminal of the prohormone brain natriuretic peptide $6,748 \text{ pg/mL}$, urine WBC $\geq 100/\text{high-power field (HPF)}$, urine bacteria $2+/\text{HPF}$ were checked. We assessed the patients with acute decompensated heart failure due to respiratory infection and acute kidney injury with urinary tract infection. Despite diuretics, oxygen therapy, empiric antibiotics and bronchodilator therapy, her hypoxemia with hypercapnea was aggravated. Eventually, she was intubated and mechanically ventilated in hospital day (HD) 1. For microbiologic evaluation of purulent sputum, we performed diagnostic bronchoscopy in HD 3, coincidentally we found out excessive dynamic airway compression in exhalation and purulent secretion in her bronchoscopy (Figure 2). Oxygen requirement of the patients was reduced in according to pneumonia was improved, so we tried to wean from mechanical ventilation in HD 13. However, carbon dioxide (CO_2) retention and poor expectoration of secretion cause failure to wean. Follow-up bronchoscopy was done for evaluating airway status, so we found EDAC was sustained (Figure 3). Therefore, we performed percutaneous dilatational tracheostomy and tried HFNOT with FiO_2 0.5 flow 30 L/min in HD 14. We found that the excessive dynamic tracheal compression in exhalation was decreased after applying of HFNOT (video file was showed in supplementary material, Video clip 1) (Figure 4), and CO_2 retention and expectoration were improved. After 3 days, she was stable, so she was transferred to general ward with HFNOT.

Discussion

EDAC and tracheobronchomalacia (TBM) are two different disease entities, included in expiratory central airway collapse. EDAC is a disease characterized by excessive bulging of the posterior membrane into the airway lumen during exhalation. On the other hand, there is weakness of the tracheobronchial cartilaginous walls in TBM¹⁻⁴. The reported prevalence of TBM and EDAC varies, reporting 4%–23% in patients undergoing bronchoscopy^{3,10}, and EDAC was present in 22% in chronic

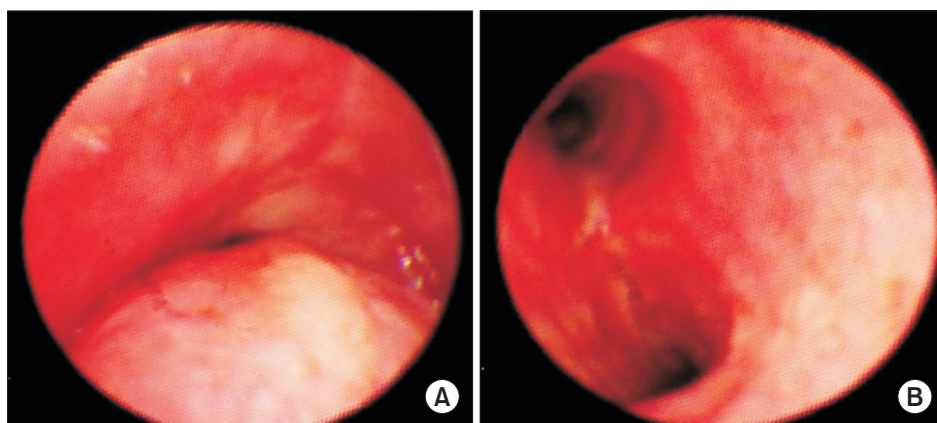


Figure 2. The initial bronchoscopy shows excessive dynamic airway compression at exhalation (A) and inhalation (B).

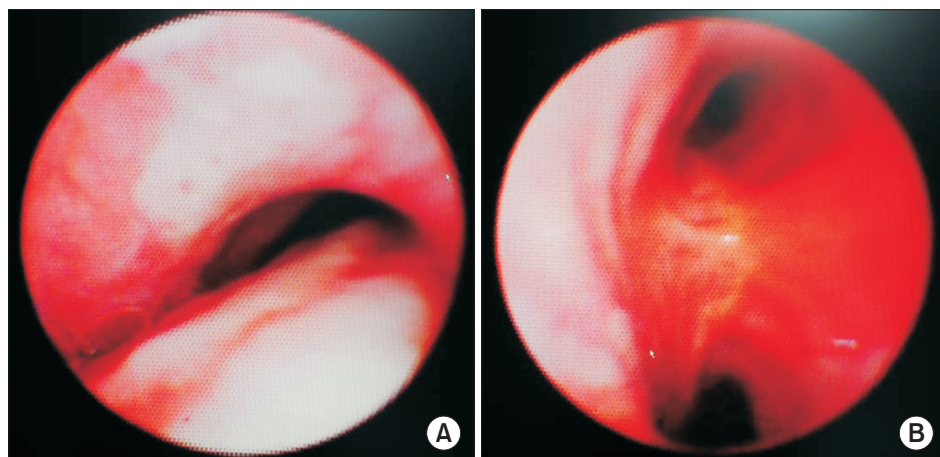


Figure 3. The follow-up bronchoscopy in hospital day 13 showed that excessive dynamic tracheal compression was sustained. (A) At exhalation. (B) At inhalation.

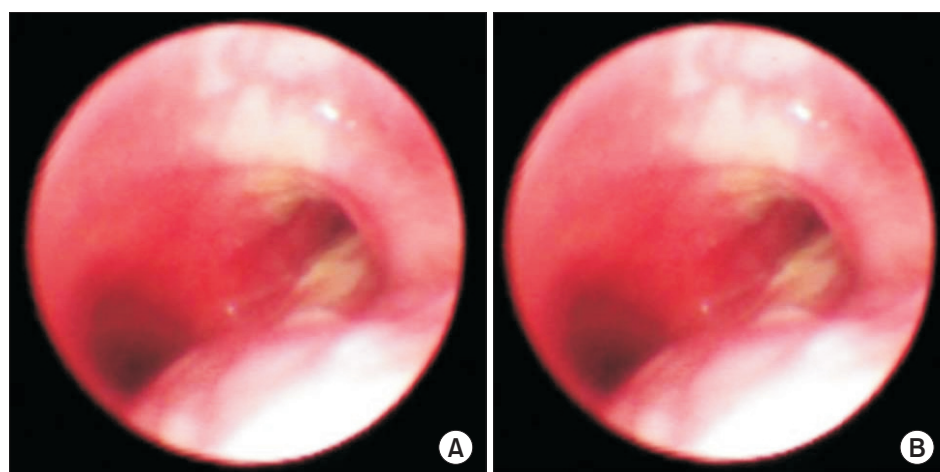


Figure 4. After applying of high flow nasal oxygen therapy, the bronchoscopy shows excessive dynamic tracheal compression was decreased at exhalation (A) and inhalation (B).

obstructive pulmonary disease (COPD) and/or asthma patients⁴.

These diseases are probably underdiagnosed because it shows nonspecific symptoms similar to patients with obstructive lung disease like COPD and asthma⁸. They can cause chronic cough, dyspnea, difficulty clearing secretions, recurrent bronchitis or pneumonia, syncope during episodes of coughing, pulmonary edema, and respiratory failure^{5,6,11}. In the case of respiratory failure, the patient may experience difficulties to wean or unexplained extubation failure¹². Physical examination may reveal wheezing, rhonchi, and decreased breath sounds⁶.

EDAC can be diagnosed using dynamic bronchoscopy or dynamic radiologic imaging such as dynamic CT. Suggestive symptoms and pulmonary function test help to diagnosis of EDAC, but they have no diagnostic value and is not predictive of disease progress. Otherwise, we should know that EDAC diagnosis is difficult because of bronchoscopy or CT performed under mechanical ventilation could give negative results².

Treatment for EDAC depends on the severity of symptoms,

degree, and extent of airway collapse. Many patients with EDAC are asymptomatic, therefore they should not be treated⁸. Proposed management strategies include conservative therapy (bronchodilators, CPAP, and NIPPV), minimally invasive therapy (endoluminal airway stents and laser therapy), surgical therapy (tracheostomy, airway splinting, and tracheal resection)⁸. Among them, CPAP and NIPPV act as pneumatic stents. Positive pressure application was known to decrease pulmonary resistance and improve airflow in patients with expiratory airflow obstruction¹³.

In this case, we diagnosed EDAC in patients by bronchoscopy. We could not perform pulmonary function test because of the patient was bed-ridden state in hospital. We could guess that EDAC of the patients contributed to retention of CO₂ and poor expectoration, therefore it caused failure to wean from mechanical ventilation. We tried HFNOT for applying intermittent positive end expiratory pressure (PEEP) in this case, and it worked well. To our knowledge, this case is the first case about HFNOT applying in management of EDAC. HFNOT is known to have a number of physiological effects.

In previous several studies, HFNOT generates a low level of PEEP¹⁴, improves oxygenation, increased the end-inspiratory lung volume, reduces airway resistance, increased functional residual capacity¹⁴, and makes better mucociliary clearance¹⁵. Therefore, we recommend that HFNOT can be an effective management method in EDAC.

There are no randomized studies about HFNOT applying in EDAC. Therefore, further research and clinical trials are needed to demonstrate the therapeutic effect of HFNOT on EDAC.

Supplementary Material

Supplementary material can be found in the journal homepage (<http://www.e-trd.org>).

Video clip 1. The bronchoscopic video of case. While the sagittal diameter of the trachea collapses about 90% in initial 15 seconds, after high flow nasal oxygen therapy (HFNOT) applying, the diameter of the trachea was recovered. Then, the diameter of the trachea re-collapses after taking off the HFNOT in the last 15 seconds.

Conflicts of Interest

No potential conflict of interest relevant to this article was reported.

References

- Murgu SD, Colt HG. Description of a multidimensional classification system for patients with expiratory central airway collapse. *Respirology* 2007;12:543-50.
- Murgu SD, Colt HG. Tracheobronchomalacia and excessive dynamic airway collapse. *Respirology* 2006;11:388-406.
- Kalra A, Abouzgheib W, Gajera M, Palaniswamy C, Puri N, Dellinger RP. Excessive dynamic airway collapse for the internist: new nomenclature or different entity? *Postgrad Med J* 2011;87:482-6.
- Park JG, Edell ES. Dynamic airway collapse: different from tracheomalacia. *Rev Port Pneumol* 2005;11:600-2.
- Murgu SD, Cherrison LJ, Colt HG. Respiratory failure due to expiratory central airway collapse. *Respir Care* 2007;52:752-4.
- Nuutinen J. Acquired tracheobronchomalacia: a clinical study with bronchological correlations. *Ann Clin Res* 1977;9:350-5.
- Murgu SD, Colt HG. Tracheobronchomalacia and excessive dynamic airway collapse: novel diagnostic tools clarify the issues. *Pulm Perspect* 2005;22:7-10.
- Murgu SD, Colt HG. Treatment of adult tracheobronchomalacia and excessive dynamic airway collapse: an update. *Treat Respir Med* 2006;5:103-15.
- Gotera C, Diaz Lobato S, Pinto T, Winck JC. Clinical evidence on high flow oxygen therapy and active humidification in adults. *Rev Port Pneumol* 2013;19:217-27.
- Ikeda S, Hanawa T, Konishi T, Adachi M, Sawai S, Chiba W, et al. Diagnosis, incidence, clinicopathology and surgical treatment of acquired tracheobronchomalacia. *Nihon Kyobu Shikkan Gakkai Zasshi* 1992;30:1028-35.
- Firdose R, Elamin E. Pulmonary edema secondary to dynamic tracheal collapse. *J Bronchol* 2004;11:118-21.
- Carden KA, Boiselle PM, Waltz DA, Ernst A. Tracheomalacia and tracheobronchomalacia in children and adults: an in-depth review. *Chest* 2005;127:984-1005.
- Martin JG, Shore S, Engel LA. Effect of continuous positive airway pressure on respiratory mechanics and pattern of breathing in induced asthma. *Am Rev Respir Dis* 1982;126:812-7.
- Sztrymf B, Messika J, Bertrand F, Hurel D, Leon R, Dreyfuss D, et al. Beneficial effects of humidified high flow nasal oxygen in critical care patients: a prospective pilot study. *Intensive Care Med* 2011;37:1780-6.
- Parke RL, Eccleston ML, McGuinness SP. The effects of flow on airway pressure during nasal high-flow oxygen therapy. *Respir Care* 2011;56:1151-5.