



Malignant transformation arising from mature cystic teratoma of the ovary presenting as ovarian torsion : a case report and literature review

Naoya Toba¹⁾, Toshifumi Takahashi²⁾, Kuniaki Ota²⁾, Atsuhiko Takanashi¹⁾, Yoshiyuki Iizawa¹⁾,
Yuta Endo³⁾, Shigenori Furukawa³⁾, Shu Soeda³⁾, Takafumi Watanabe³⁾, Hideki Mizunuma²⁾,
Keiya Fujimori³⁾ and Kazuyuki Takeichi¹⁾

¹⁾Department of Obstetrics and Gynecology, Aizu Chuo Hospital, Fukushima, Japan, ²⁾Fukushima Medical Center for Children and Women, Fukushima Medical University, Fukushima, Japan, ³⁾Department of Obstetrics and Gynecology, Fukushima Medical University School of Medicine, Fukushima, Japan

(Received December 12, 2019, accepted February 13, 2020)

Abstract

Objective : Ovarian torsion is an acute gynecological condition. Torsion is more likely to occur with benign rather than malignant tumors. Mature cystic teratoma of the ovary (MCTO) is frequent in women of reproductive age ; however, the incidence of malignant transformation is approximately 2%. We report a case of malignant transformation of MCTO presenting as ovarian tumor torsion.

Case report : A 51-year-old premenopausal woman was diagnosed with mature cystic teratoma in the left ovary 7 years ago. The patient visited our hospital because she had been experiencing of pain in left lower abdomen for the past two days. She was diagnosed with ovarian tumor torsion and underwent emergency surgery. The left ovarian tumor was twisted, and left salpingo-oophorectomy was performed. Histopathological examination revealed squamous cell carcinoma arising from the MCTO. We carefully followed the patients without performing staging laparotomy. On postoperative day 112, multiple lymph node metastases in the pelvic and para-aortic areas were found by positron-emission tomography and computed tomography. After referral to a university hospital, total hysterectomy, right salpingo-oophorectomy, partial omentectomy, and pelvic and para-aortic lymphadenectomy were performed. Metastases of squamous cell carcinoma were confirmed in the pelvic and para-aortic lymph nodes. Six courses of adjuvant chemotherapy with paclitaxel and carboplatin were given following radical surgery to prevent the recurrence of malignant transformation of MCTO. No recurrence of the disease has been observed during 2 years of follow-up.

Conclusion : When physicians diagnose large ovarian tumor torsion cases, preoperative examinations should be performed, with the possibility of malignancy in mind.

Key words : acute abdomen, ovarian torsion, mature cystic teratoma, malignant transformation, squamous cell carcinoma

Introduction

Ovarian tumor torsion is an acute gynecological condition that requires emergency surgery. Torsion is more likely to occur with benign rather than

malignant tumors¹⁻³⁾. Mature cystic teratoma of the ovary (MCTO) is a benign tumor that is frequently observed in women of reproductive age. However, malignant transformation occurs in <2% of MCTO⁴⁾. Here, we report a woman with malignant

Corresponding author : Toshifumi Takahashi E-mail : totakaha@fmu.ac.jp

©2020 The Fukushima Society of Medical Science. This is an open-access article distributed under the terms of the Creative Commons Attribution-NonCommercial-ShareAlike 4.0 International License (CC-BY-NC-SA 4.0).
<https://creativecommons.org/licenses/by-nc-sa/4.0/>

transformation of MCTO, which was presented as ovarian tumor torsion, and review the literature.

Case presentation

A 51-year-old premenopausal woman gravida 3, para 3, was diagnosed with left MCTO 7 years ago. The size of the MCTO was 59 mm at the time of diagnosis. She underwent regular ovarian examination for 2 years after the diagnosis but had not visited the hospital for 5 years. She had a history of appendectomy at 7 years of age and received medication for hyperthyroidism since she was 37 years old. She experienced left lower abdominal pain for 2 days and visited the hospital due to increasing pain. Physical examination showed a flat abdomen with tenderness around the left lower abdomen. A solid tumor was palpable by bimanual examination on the left side. Transvaginal ultrasonography revealed a 91-mm cystic and solid ovarian mass on the left ovary (Fig. 1). She was diagnosed with ovarian tumor torsion and had to undergo emergency surgery. Height, weight, and body mass index (BMI) were 165 cm, 96 kg, and 35.3 kg/m², respectively. Body temperature was within the normal range, pulse rate was 84 beats/min, and blood pressure was 121/55 mmHg. Peripheral blood examination showed that the white blood cell count was 8,820/ μ L, red blood cell count was 4.65×10^6 /

μ L, hemoglobin was 12.1 g/dL, and hematocrit was 37.5%. Biochemical data revealed that the C-reactive protein level was as high as 13.9 mg/dL. Levels of tumor makers, namely serum α -fetoprotein, carbohydrate antigen 19-9 (CA19-9), CA125, and squamous cell carcinoma (SCC) antigen were 4.0 ng/mL (reference, <10.0 ng/mL), < 2.0 U/mL (reference, < 37.0 U/mL), 84.1 U/mL (reference, < 35.0 U/mL), and 1.4 ng/mL (reference, < 1.5 ng/mL), respectively. Laparotomy was immediately performed. Operative findings showed 360° torsion of the left ovarian tumor without ascites in the pelvic cavity. There were no sign of congestion and rupture on the surface of the twisted ovary. The uterus and right ovary appeared normal. Left salpingo-oophorectomy was performed. The duration of operation was 54 min, and the volume of blood loss was 30 mL. The diameter of the extirpated ovarian tumor was 11 cm, and the tumor contained fat and hair. Histopathological findings showed both components of mature cystic teratoma and SCC with marked nuclear and cellular atypia in the solid part (Fig. 2). The pathological diagnosis was malignant transformation with SCC of MCTO. We recommended staging laparotomy to determine the treatment strategy. The patient refused to undergo the procedure; subsequently, a strict follow-up for stage IA ovarian cancer was conducted. The patient was discharged from the hospital 10 days post

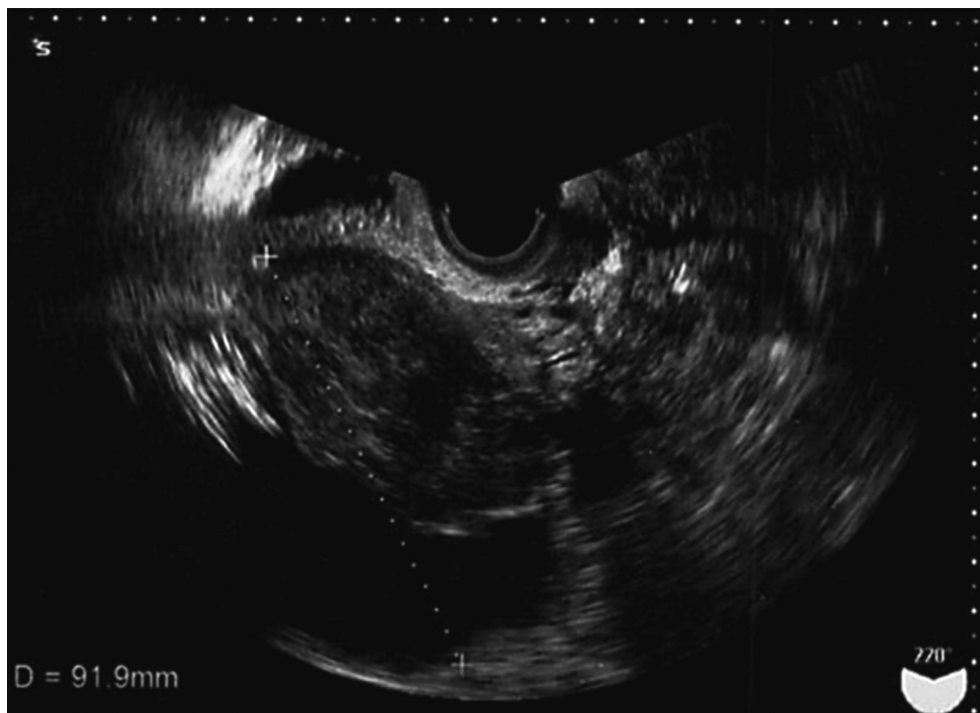

Fig. 1. Transvaginal ultrasonographic findings at onset of ovarian torsion
Transvaginal ultrasonography revealed a 91-mm cystic and solid ovarian mass on the left adnexal lesion.

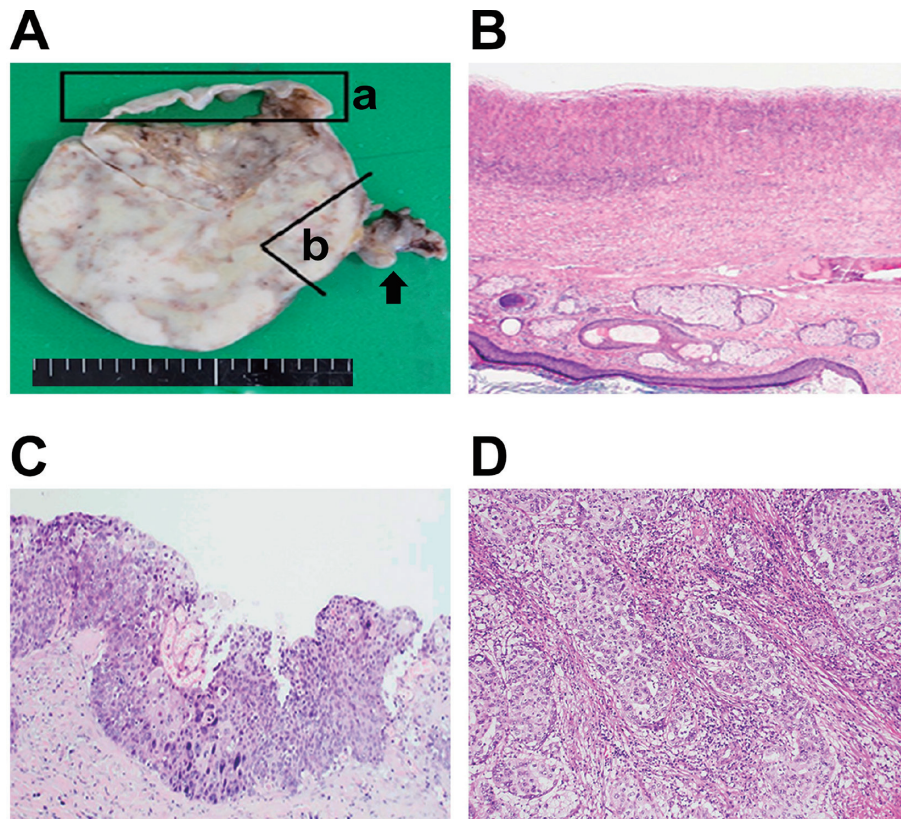


Fig. 2. Histopathological findings of the left adnexal tumor at the time of initial surgery
 A. Macroscopic appearance of the left ovarian tumor. The arrow indicates the left fallopian tube. B. Histological findings of mature cystic teratoma with keratinized epidermis and sebaceous glands (part of “a” of photograph A). C and D. Histological findings of squamous cell carcinoma component showing honeycomb-like arrangement with severe nuclear atypia (C, low magnification ; D, high magnification).

operation. On postoperative day 112, the serum CA125 level was as high as 101.4 U/mL. Positron-emission tomography and computed tomography (CT) showed some nodal lesions with remarkable uptake of 18F-fluorodeoxy glucose (Fig. 3). She was referred to a university hospital due to cancer recurrence. Her BMI was as high as 37.8 kg/m², and biochemical examination showed that she had hyperlipidemia and diabetes mellitus. The serum CA125, SCC antigen, CA19-9, and carcinoembryonic antigen (CEA) levels were 216 U/mL (reference, < 35.0 U/mL), 2.0 ng/mL (reference, < 1.5 ng/mL), < 2.0 U/mL (reference, < 37.0 U/mL), and 3.5 ng/mL (reference, < 5.0 ng/mL), respectively. The patient underwent radical surgery with total abdominal hysterectomy, right salpingo-oophorectomy, partial omentectomy, and pelvic and para-aortic lymph node dissection. Operative findings revealed that there was no ascites or dissemination in the abdominal cavity ; no metastatic lesion was found in the uterus and right adnexa. The enlarged pelvic and para-aortic lymph nodes were removed. Thereafter, complete surgical treatment was achieved. The

duration of operation was 360 min, and the volume of blood loss was 370 mL. Histopathological examination showed positive lymph nodes with SCC. The numbers of positive/total resected lymph nodes in the left obturator, left external iliac, and para-aortic nodes were 1/5, 2/7, and 1/1, respectively. Immunostaining was performed to assess whether the tumor cells were of epithelial or germ cell origin (Table 1); the results confirmed recurrence of the malignant transformation of MCTO with SCC (Fig. 4). The postoperative course was uneventful, and the patient was discharged 10 days post-op. She received 6 courses of conventional paclitaxel and carboplatin as adjuvant chemotherapy. She has had no recurrence for 2 years after treatment. The treatment course is shown in Fig. 5.

Discussion

Ovarian tumor torsion is more likely to occur with benign rather than malignant tumors. The actual incidence of adnexal mass torsion is unknown. Two studies reported that ovarian torsion

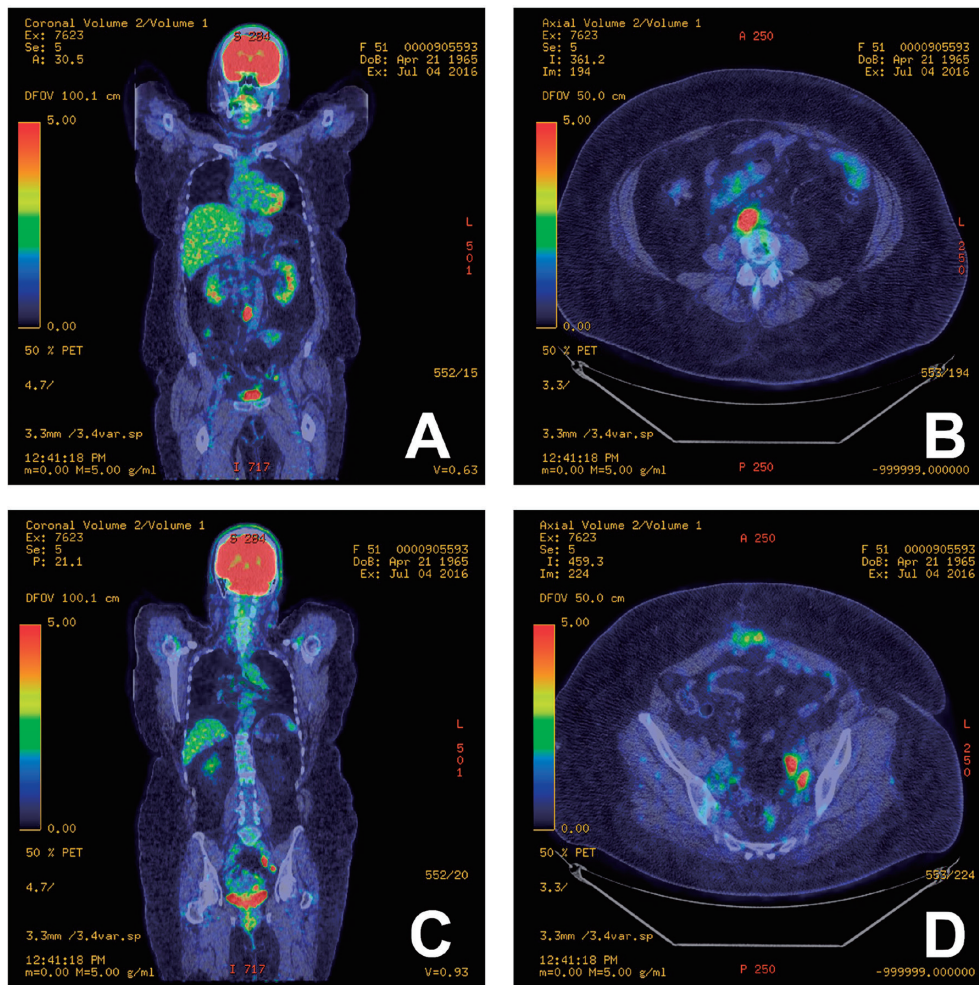


Fig. 3. PET-CT images
 A, B. High accumulation of FDG in the para-aortic lesion (SUVmax = 18.3). A, coronal section ; B, transverse section. C, D. High accumulation of FDG in pelvic lymph nodes (SUV max = 14.2). C, coronal section ; D, transverse section.
 PET, positron-emission tomography ; CT, computed tomography ; FDG, 18F-fluorodeoxyglucose ; SUVmax, maximum standardized uptake value

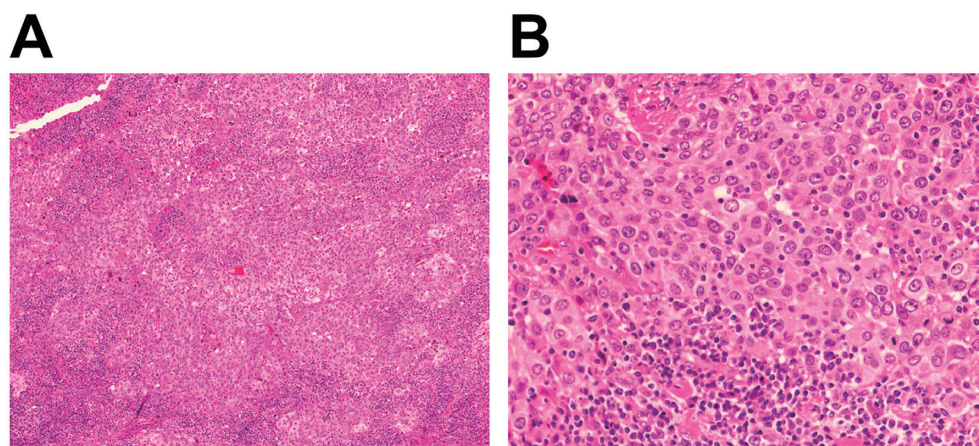


Fig. 4. Histopathological findings of resected lymph node
 A, B. Resected para-aortic lymph node shows substantial cellular and nuclear atypia (A, low magnification (40x) ; B, high magnification (400x).

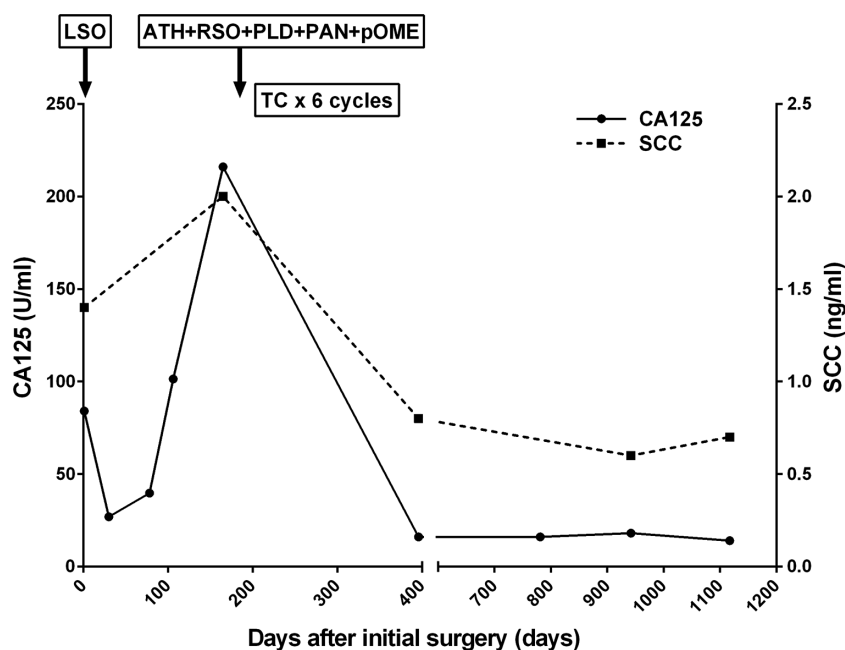


Fig. 5. Clinical course of treatment

The solid line indicates the CA125 level. The dotted line indicates the SCC antigen level.

LSO, left salpingo-oophorectomy; ATH, abdominal hysterectomy; RSO, right salpingo-oophorectomy; PLD, pelvic lymphadenectomy; PAN, para-aortic lymphadenectomy; pOME, partial omentectomy; TC, paclitaxel and carboplatin

Table 1. Immunostaining expression of various markers in resected lymph nodes

	Markers of epithelial origin or others	Markers of germ cell origin
Positive staining	CK AE1/AE3 EMA CK5/6 p63 p40 Calponin BAF47	none
Negative staining	CD30 SMA	c-kit Oct3/4 SALL4 AFP hCG

CK, cytokeratin; SMA, smooth muscle actin; AFP, α -fetoprotein; hCG, human chorionic gonadotropin

accounted for 2.7% of emergency surgeries⁵) and 15% of adnexal mass surgeries⁶). The proportion of torsion with malignant ovarian tumors is approximately 2%¹⁻³). A higher incidence of malignant tumors in cases of torsion was noted in menopausal women than in premenopausal women^{7,8}). As malignant ovarian tumors are less likely to cause tor-

sion, it is assumed that they adhere to adjacent pelvic tissue. In this case, however, the tumor did not adhere to anything and was twisted. Because MCTO, which is a benign tumor, is thought to be less likely to cause adhesion, the initial stage of malignant transformation of MCTO might be prone to torsion.

Although MCTO is a benign ovarian tumor that represents 20% of all ovarian tumors, it may progress to malignancy⁴). The incidence of malignant transformation of MCTO is approximately 0.2-2%^{4,9-12}). SCC, which arises from the ectoderm, accounts for 80% of malignant transformations^{4,13}). Other reported types of malignant transformation of MCTO include basal cell carcinoma, melanoma, adenocarcinoma, thyroid carcinoma, and carcinoid^{4,13}). In this case, it was difficult to distinguish between SCC and germ cell tumors based on tissue morphology. Immunostains for epithelial and germ cell markers yielded a histopathological diagnosis of SCC (Table 1). Immunostaining of epithelial markers, such as CK10 and CK18, are useful in the pathological diagnosis of SCC⁴).

Studies have reported various risk factors for malignant transformation of MCTO^{4,13-15}); including age > 45 years, tumor diameter > 10 cm, and high tumor marker levels. As far as tumor markers are concerned, serum SCC antigen levels are frequently high

Table 2. Cases with malignant transformation of mature cystic teratoma of the ovary presenting as ovarian tumor torsion

Authors (publication year)	Age	Meno-pause	Symp-toms	Tor-sion side	Rup-ture	Ascites	Contralateral ovary	Maxi-mal tumor size (cm)	Elevated tumor marker levels	Initial surgery	Ab-domi-nal cytol-ogy	Rapid pathol-ogy	Pathological diagnosis	Additional treatments	Stag-ing	Prognosis
Okano <i>et al.</i> (2002)	77	Yes	LAP, AA	Right	No	Yes, bloody	None of the tumors	13	None	BSO (laparotomy)	Yes	No	MCT with carcinoid	None	N.A.	N.A.
Min <i>et al.</i> (2006)	77	Yes	LAP, AA	Right	No	Yes, bloody	None of the tumors	17	CA125	ATH+BSO (laparotomy)	Yes	No	MCT with intestinal adenocarcinoma	None	N.A.	NED at 1 year after surgery
Korkontzelos <i>et al.</i> (2010)	56	Yes	LAP, AA	Right	No	N.A.	None of the tumors	17	N.A.	ATH+BSO (laparotomy)	No	No	MCT with SCC	None	N.A.	NED at 4 years after surgery
Tamura <i>et al.</i> (2013)	55	Yes	LAP, AA	Right	No	N.A.	MCT with SCC	11	CA19-9, SCC, CEA	BSO (laparotomy)	Yes	No	MCT with SCC	ATH+PLD+PAN+OME	IA	NED at 3 years after surgery
Nagao <i>et al.</i> (2015)	50s	Yes	LAP, AA	Right	No	None	MCT	8	hCG, CA19-9	BSO (laparotomy)	No	No	MCT with carcinoid	None	N.A.	N.A.
Yamada <i>et al.</i> (2016)	38	N.A.	LAP, AA	Right	No	None	None of the tumors	7	SCC	Cystectomy (laparoscopy)	No	No	MCT with SCC	None	N.A.	NED at 1.5 years after surgery
Cokmez <i>et al.</i> (2019)	38	N.A.	LAP, AA	Left	No	N.A.	None of the tumors	11	None	BSO (laparotomy)	No	No	MCT with papillary thyroid carcinoma	None	N.A.	N.A.
Present case	51	No	LAP, AA	Left	No	None	None of the tumors	11	CA125, SCC	LSO (laparotomy)	No	No	MCT with SCC	ATH+RSO+PLD+PAN+OME+adjuvant chemotherapy	IA	NED at 2 years after treatments

ATH, abdominal total hysterectomy ; BSO, bilateral salpingo-oophorectomy ; MCT, mature cystic teratoma ; SCC, squamous cell carcinoma ; PLD, pelvic lymphadenectomy ; PAN, para-aortic lymphadenectomy ; OME, omentectomy ; NED, no evidence of disease ; N.A., not applicable

in patients with SCC arising from MCTO^{4,13,16-19}. Levels of other tumor markers, such as serum CA125, C19-9, and CEA, are also high in patients with various histological types of malignant transformation of MCTO^{13,17}. In this case, the patient had the following risk factors: age > 45 years, tumor diameter > 10 cm, and elevated serum CA125.

CT and magnetic resonance imaging (MRI) are useful for the preoperative diagnosis of malignant transformation of MCTO⁴. Kido *et al.* reported the MRI findings for malignant transformation of MCTO and revealed that gadolinium enhancement might be helpful in its diagnosis²⁰. Moreover, Futagami *et al.* reported that gadolinium enhancement of the solid part of the tumor by MRI is a risk factor for malignant transformation¹⁵. In this case, we did not perform CT or MRI because an emergency surgery was performed. Ovarian tumor torsion may affect CT or MR images due to the time lapse after torsion and disruption of blood supply²¹. Physicians should consider this point during diagnosis.

Although the incidence of torsion or rupture of MCTO is 0.3-16%^{22,23}, ovarian tumor torsion in malignant transformation of MCTO has not been comprehensively analyzed. Therefore, we searched for cases of malignant transformation of MCTO presenting as ovarian tumor torsion in PubMed and Ichushi databases, the latter being a medical literature service provided by the nonprofit organization Japan Medical Abstracts Society. We searched for keywords, such as "mature cystic teratoma," "malignant transformation," and "ovarian torsion." These keywords were present in seven cases, and there were eight cases including this case of malignant transformation of MCTO with torsion²⁴⁻³⁰ (Table 2). The age of onset ranged from 38 to 77 years, and five of six patients were menopausal. All eight patients complained of lower abdominal pain and underwent emergency surgery. The laterality of torsion was on the right side in six patients and the left side in two patients. Two of eight patients had MCTO on both sides, and one case had SCC on the side without any torsion. Five of seven patients had increased serum tumor marker levels. The median diameter of the ovarian tumor on the torsion side was 11 cm (range, 7-11 cm). Seven of eight patients underwent laparotomy, and only one patient underwent laparoscopic surgery. Peritoneal cytology was performed in three of eight patients; no patients received rapid pathological diagnosis. The most common pathological diagnosis of malignant lesion was SCC (4 patients). Radical surgery for ovarian cancer was performed in two patients, in-

cluding ours. Except for our case, among four patients with the same prognosis, no recurrence after treatment has been reported.

The standard therapy for malignant transformation of MCTO includes radical surgery and adjuvant chemotherapy according to the staging⁴. In patients who choose not to have children, radical surgery, such as bilateral salpingo-oophorectomy, hysterectomy, and comprehensive surgical staging with peritoneal washing cytology, omentectomy, peritoneal biopsy, and pelvic plus para-aortic lymphadenectomy, is performed. After surgical staging, adjuvant chemotherapy with a combination of paclitaxel and carboplatin is performed in advanced disease. However, the prognosis of patients with malignant transformation of MCTO is worse than that of patients with common epithelial ovarian cancer⁴. Prognostic factors have been reported in patients with malignant transformation of MCTO. Age > 45 or 55 years, advanced staging, larger tumor, high cancer grade, absence of hysterectomy, presence of residual tumor lesions, absence of adjuvant chemotherapy, and non-platinum-based chemotherapy^{13,16,31,32} are poor prognostic factors. Lymphadenectomy is not a major prognostic factor in patients with malignant transformation of MCTO^{13,31}. In this case, however, a strict follow-up for stage IA ovarian cancer was conducted, and tumor recurrence in retroperitoneal lymph nodes developed 3 months after the initial surgery. Hurwitz *et al.* reported that secondary reduction surgery was effective in two patients with recurrence of malignant transformation of MCTO³³. In this case, the patient underwent adjuvant chemotherapy following radical surgery without residual lesions, and no recurrence was observed for 2 years after treatment. Secondary cytoreductive surgery might be considered in selected patients with recurrence of malignant transformation of MCTO.

Although ovarian tumor torsion requires emergency surgery, when physicians encounter large ovarian tumor torsion cases, preoperative examinations should be performed, keeping the possibility of malignancy in mind.

Disclosures

Conflict of interest: The authors declare no conflict of interest.

References

1. Oltmann SC, Fischer A, Barber R, *et al.* Cannot

- exclude torsion—a 15-year review. *J Pediatr Surg*, **44** : 1212-1216 ; discussion 1217, 2009.
2. White M, Stella J. Ovarian torsion : 10-year perspective. *Emerg Med Australas*, **17** : 231-237, 2005.
 3. Tsafirir Z, Hasson J, Levin I, *et al.* Adnexal torsion : cystectomy and ovarian fixation are equally important in preventing recurrence. *Eur J Obstet Gynecol Reprod Biol*, **162** : 203-205, 2012.
 4. Gadducci A, Guerrieri ME, Cosio S. Squamous cell carcinoma arising from mature cystic teratoma of the ovary : a challenging question for gynecologic oncologists. *Crit Rev Oncol Hematol*, **133** : 92-98, 2019.
 5. Hibbard LT. Adnexal torsion. *Am J Obstet Gynecol*, **152** : 456-461, 1985.
 6. Bouguizane S, Bibi H, Farhat Y, *et al.* [Adnexal torsion : a report of 135 cases]. *J Gynecol Obstet Biol Reprod (Paris)*, **32** : 535-540, 2003.
 7. Eitan R, Galoyan N, Zuckerman B, *et al.* The risk of malignancy in post-menopausal women presenting with adnexal torsion. *Gynecol Oncol*, **106** : 211-214, 2007.
 8. Cohen A, Solomon N, Almog B, *et al.* Adnexal torsion in postmenopausal women : clinical presentation and risk of ovarian malignancy. *J Minim Invasive Gynecol*, **24** : 94-97, 2017.
 9. Westhoff C, Pike M, Vessey M. Benign ovarian teratomas : a population-based case-control study. *Br J Cancer*, **58** : 93-98, 1988.
 10. Comerci JT, Jr., Licciardi F, Bergh PA, *et al.* Mature cystic teratoma : a clinicopathologic evaluation of 517 cases and review of the literature. *Obstet Gynecol*, **84** : 22-28, 1994.
 11. Singh P, Yordan EL, Wilbanks GD, *et al.* Malignancy associated with benign cystic teratomas (dermoid cysts) of the ovary. *Singapore Med J*, **29** : 30-34, 1988.
 12. Gadducci A, Giuliani D, Cosio S, *et al.* Clinical outcome of patients with malignant tumors associated with mature cystic teratomas of the ovary : a retrospective multicenter Italian study. *Anticancer Res*, **39** : 2513-2517, 2019.
 13. Hackethal A, Brueggmann D, Bohlmann MK, *et al.* Squamous-cell carcinoma in mature cystic teratoma of the ovary : systematic review and analysis of published data. *Lancet Oncol*, **9** : 1173-1180, 2008.
 14. Dos Santos L, Mok E, Iasonos A, *et al.* Squamous cell carcinoma arising in mature cystic teratoma of the ovary : a case series and review of the literature. *Gynecol Oncol*, **105** : 321-324, 2007.
 15. Futagami M, Yokoyama Y, Mizukami H, *et al.* Can malignant transformation in mature cystic teratoma be preoperatively predicted? *Eur J Gynaecol Oncol*, **33** : 662-665, 2012.
 16. Kikkawa F, Ishikawa H, Tamakoshi K, *et al.* Squamous cell carcinoma arising from mature cystic teratoma of the ovary : a clinicopathologic analysis. *Obstet Gynecol*, **89** : 1017-1022, 1997.
 17. Suzuki M, Tamura N, Kobayashi H, *et al.* Clinical significance of combined use of macrophage colony-stimulating factor and squamous cell carcinoma antigen as a selective diagnostic marker for squamous cell carcinoma arising in mature cystic teratoma of the ovary. *Gynecol Oncol*, **77** : 405-409, 2000.
 18. Emoto M, Obama H, Horiuchi S, *et al.* Transvaginal color Doppler ultrasonic characterization of benign and malignant ovarian cystic teratomas and comparison with serum squamous cell carcinoma antigen. *Cancer*, **88** : 2298-2304, 2000.
 19. Mori Y, Nishii H, Takabe K, *et al.* Preoperative diagnosis of malignant transformation arising from mature cystic teratoma of the ovary. *Gynecol Oncol*, **90** : 338-341, 2003.
 20. Kido A, Togashi K, Konishi I, *et al.* Dermoid cysts of the ovary with malignant transformation : MR appearance. *AJR Am J Roentgenol*, **172** : 445-449, 1999.
 21. Srisajjakul S, Prapaisilp P, Bangchokdee S. Imaging features of unusual lesions and complications associated with ovarian mature cystic teratoma. *Clin Imaging*, **57** : 115-123, 2019.
 22. Caruso PA, Marsh MR, Minkowitz S, *et al.* An intense clinicopathologic study of 305 teratomas of the ovary. *Cancer*, **27** : 343-348, 1971.
 23. Park SB, Kim JK, Kim KR, *et al.* Imaging findings of complications and unusual manifestations of ovarian teratomas. *Radiographics*, **28** : 969-983, 2008.
 24. Min KJ, Jee BC, Lee HS, *et al.* Intestinal adenocarcinoma arising in a mature cystic teratoma of the ovary : a case report. *Pathol Res Pract*, **202** : 531-535, 2006.
 25. Korkontzelos I, Stamatopoulos C, Antoniou N, *et al.* Malignant transformation of ovarian mature cystic teratoma in a postmenopausal woman presented as acute abdomen. *Arch Gynecol Obstet*, **281** : 177-179, 2010.
 26. Cokmez H, Gulbahar A, Yigit S, *et al.* Oncocytic and tall columnar type papillary thyroid carcinoma arising on a mature cystic teratoma : a case report and literature review. *J Pak Med Assoc*, **69** : 116-119, 2019.
 27. Tamura D, Ono N, Nagao D, *et al.* Two cases of mature cystic teratoma with malignant transformation. *Akitaken Sanka Fujinka Gakkaishi*, **18** : 45-50, 2013.
 28. Nagao S, Tamate M, Shikanai S, *et al.* [A case of ovarian carcinoid with mature cystic teratoma]. *Obstet Gynecol*, **82** : 691-696, 2015.

29. Yamada Y, Nakanishi K, Masuda A, *et al.* [A case of mature cystic ovarian teratoma with intraepithelial squamous cell carcinoma diagnosed postoperatively]. *Med J Kinki Cent Hosp*, **36** : 47-50, 2016.
30. Okano S, Katsube Y, Hirata E, *et al.* [A case of primary ovarian carcinoid]. *The Japanese Society of Clinical Cytology, The Bulletin of Hiroshima Chapter* : 18-21, 2001.
31. Li C, Zhang Q, Zhang S, *et al.* Squamous cell carcinoma transformation in mature cystic teratoma of the ovary : a systematic review. *BMC Cancer*, **19** : 217, 2019.
32. Chen RJ, Chen KY, Chang TC, *et al.* Prognosis and treatment of squamous cell carcinoma from a mature cystic teratoma of the ovary. *J Formos Med Assoc*, **107** : 857-868, 2008.
33. Hurwitz JL, Fenton A, McCluggage WG, *et al.* Squamous cell carcinoma arising in a dermoid cyst of the ovary : a case series. *BJOG*, **114** : 1283-1287, 2007.