

MEETING ABSTRACT

Open Access

Macular functional changes in patients with neovascular age-related macular degeneration receiving ranibizumab therapy (lucentis)

G C Scalzo*, F Campagna, G Randazzo, G Scordia

From de Senectute: Age and Health Forum
Catanzaro, Italy. 5-7 December 2009

Background

Vascular endothelial growth factor (VEGF) is considered to play an essential role in the pathogenesis of age-related macular degeneration due to its vascular permeability-inducing and angiogenic properties. Ranibizumab, a small antibody fragment designed to competitively bind all VEGF isoforms, passes after intravitreal injection into all retinal layers reaching the retinal pigment epithelium-choroid complex. The actions of ranibizumab result in reduced cell proliferation, reduced formation of new blood vessels, and minimization of vascular leakage. The aim of this study was to evaluate the prospectively macular function in in patients with neovascular age-related macular degeneration (AMD) patients undergoing repeated intravitreal injections of Ranibizumab therapy (Lucentis).

Materials and methods

Twenty patients affected by AMD (age range 60-72 years) were enrolled in the study. Inclusion criteria for this study were: evidence of age-related macular degeneration, angiographic evidence of predominantly classic and occult CNV extending under the center of the foveal avascular zone, absence of coexisting ocular disease. Patients enrolled showed baseline visual acuity ranged 1-0.84 logMAR, central microperimetric (Nikon MP-1) sensitivity 2 to 10 dB. Each patient underwent weekly assessments, for three months, of visual acuity, microperimetry and focal electroretinogram (FERG), performed according to a published technique.

Results

Following the first intravitreal injection, mean visual acuity (Figure 1), microperimetric sensitivity (Figure 2) and FERG amplitude (Figure 3) increased steadily from baseline values over the treatment period, with further improvements following each intravitreal injection ($P < 0.001$).

Conclusions

Ranibizumab therapy can improve central macular function in patients with predominantly classic and occult CNV.

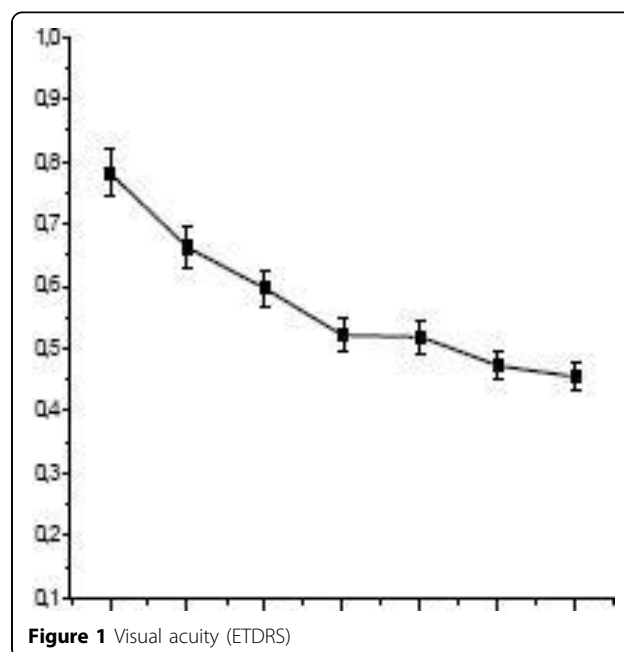


Figure 1 Visual acuity (ETDRS)

Department of Ophthalmology, Magna Graecia University, Catanzaro, 88100, Italy

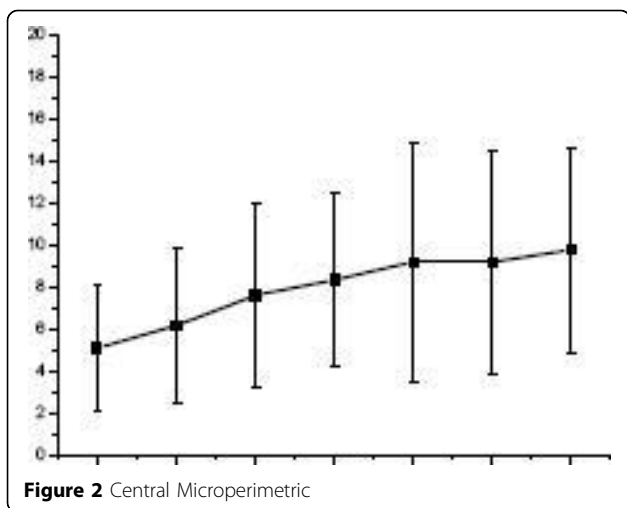


Figure 2 Central Microperimetric

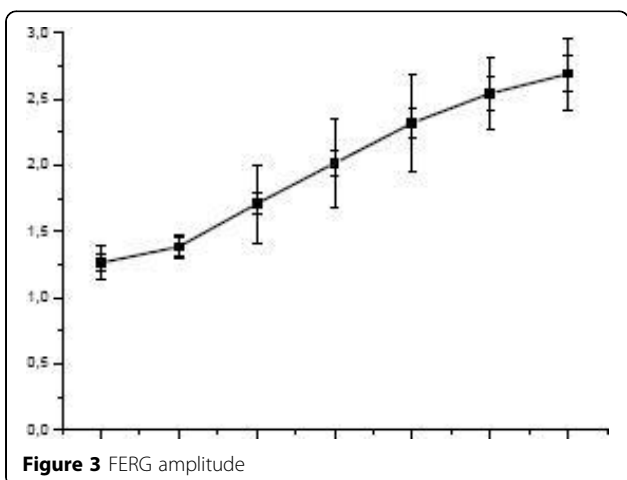


Figure 3 FERG amplitude

Published: 19 May 2010

References

1. Arden GB: Vaegan. Electroretinograms evoked in man by local uniform orpatterned stimulation. *J Physiol.* 1983, **341**:85-104.
2. Kourlas H, Abrams P: Ranibizumab for the treatment of neovascular age-related macular degeneration: a review. *Clin Ther.* 2007, **29**(9):1850-61.
3. McKibbin M, Papastefanou V, Matthews B, Cook H, Downey L: Ranibizumab monotherapy for sub-foveal haemorrhage secondary to choroidal neovascularisation in age-related macular degeneration. *Eye* 2009.

doi:10.1186/1471-2318-10-S1-A77

Cite this article as: Scalzo et al.: Macular functional changes in patients with neovascular age-related macular degeneration receiving ranibizumab therapy (lucentis). *BMC Geriatrics* 2010 **10**(Suppl 1):A77.

Submit your next manuscript to BioMed Central and take full advantage of:

- Convenient online submission
- Thorough peer review
- No space constraints or color figure charges
- Immediate publication on acceptance
- Inclusion in PubMed, CAS, Scopus and Google Scholar
- Research which is freely available for redistribution

Submit your manuscript at
www.biomedcentral.com/submit

