

Keratoconus associated with hereditary sensory and autonomic neuropathy II

Zalak Shah, Shwetambari Singh, Dipali Purohit,
Neha Shilpy¹

Key words: HSAN II, keratoconus, keratoconus progression, mutilations

Hereditary sensory and autonomic neuropathies (HSANs) are a group of an extremely rare inherited disorder of the peripheral nervous system with heterogeneous clinical presentations and

genetic causes.^[1] They are classified into types I–V based on the age at onset, inheritance pattern, clinical presentation, and genetic background.^[1]

HSAN II is a very rare autosomal recessive disease with unknown prevalence. It presents with usual onset in infancy—widespread sensory loss, mutilations in the hands and feet, acro-osteolysis, and mild or minimal autonomic dysfunction.^[1,2] HSAN II is distinguished by normal mental health from HSAN III and IV.^[2]

The reported ocular manifestations in HSANs are optic neuropathy, recurrent corneal ulcers, and neurotrophic keratitis.^[3-5] To the best of our knowledge, this is the first longitudinal report of keratoconus associated with HSAN II, describing the progression of keratoconus during a follow-up of 1.5 years.

A 16-year-old girl presented to our ophthalmology clinic with complaint of decreased vision in both eyes for the past 3 months. Her medical history included HSAN II diagnosis since childhood. She had a history of multiple injuries and unnoticed trauma. Her parents gave a strong history of lack of response to any painful stimuli and insensitivity to extreme temperature stimuli which were observed at the age of 1. Family history revealed that her younger brother had similar

Access this article online	
Quick Response Code:	Website: www.ijo.in
	DOI: 10.4103/ijo.IJO_895_21

Department of Refractive Surgery, Shree C.H.Nagri Eye Hospital, Ahmedabad, Gujarat, ¹Regional Institute of Ophthalmology, Rajendra Institute of Medical Sciences, Ranchi, Jharkhand, India

Correspondence to: Ms. Zalak Shah, Department of Refractive Surgery, Shree C. H. Nagri Eye Hospital, Ahmedabad - 380 006, Gujarat, India. E-mail: optomzalak@gmail.com

Received: 17-Apr-2021

Revision: 17-Aug-2021

Accepted: 21-Sep-2021

Published: 30-Jun-2022

This is an open access journal, and articles are distributed under the terms of the Creative Commons Attribution-NonCommercial-ShareAlike 4.0 License, which allows others to remix, tweak, and build upon the work non-commercially, as long as appropriate credit is given and the new creations are licensed under the identical terms.

For reprints contact: WKHLRPMedknow_reprints@wolterskluwer.com

Cite this article as: Shah Z, Singh S, Purohit D, Shilpy N. Keratoconus associated with hereditary sensory and autonomic neuropathy II. Indian J Ophthalmol 2022;70:2629-32.

complaints. History of consanguinity with parents being first cousins was noted.

The neurological medical reports showed the presence of wasting, normal muscle power and limbs reflex, absences of plantar reflex, impaired joint position sense, and reduced crude touch sensation in all the four limbs which were greater distally than proximally. Her IQ was within normal limits.

The external examination revealed the presence of ulcers and severe acro-mutilations in the fingers and toes. Multiple, well-defined, discrete, erythematous-based ulcers with sloping edges were present over the bilateral elbows, thighs, and

abdomen. Also, multiple superficial healed skin ulcers were present over the whole body [Fig. 1a-c].

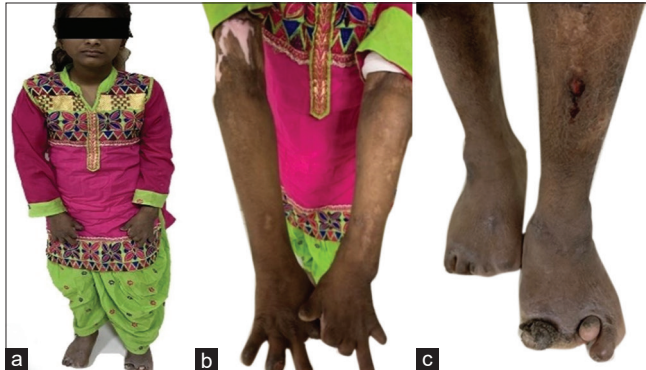

Figure 1: (a) Clinical photograph of the patient with hereditary sensory, and autonomic neuropathy II, severe mutilations and ulcers in the (b) fingers and (c) toes

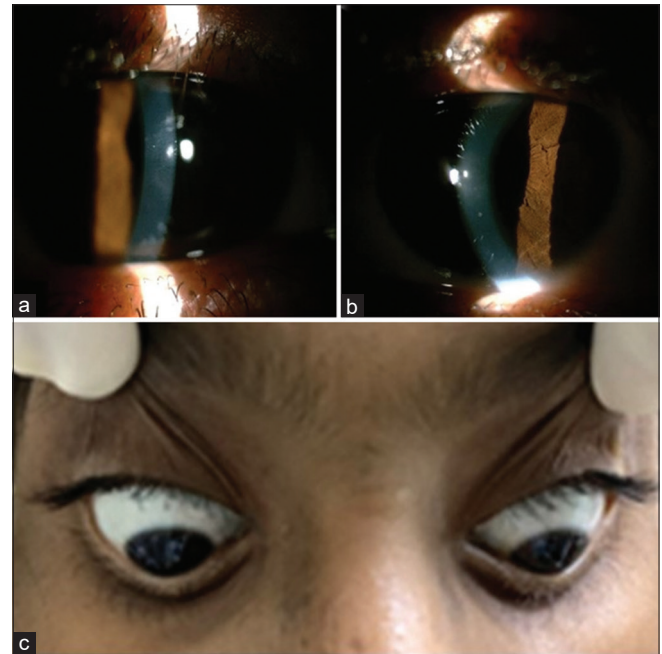


Figure 2: Photograph of the (a) right eye and (b) left eye slit-lamp bio-microscopy showed Vogt's striae in the right eye while protrusion in both the eyes. (c) presence of Munson's sign in both the eyes

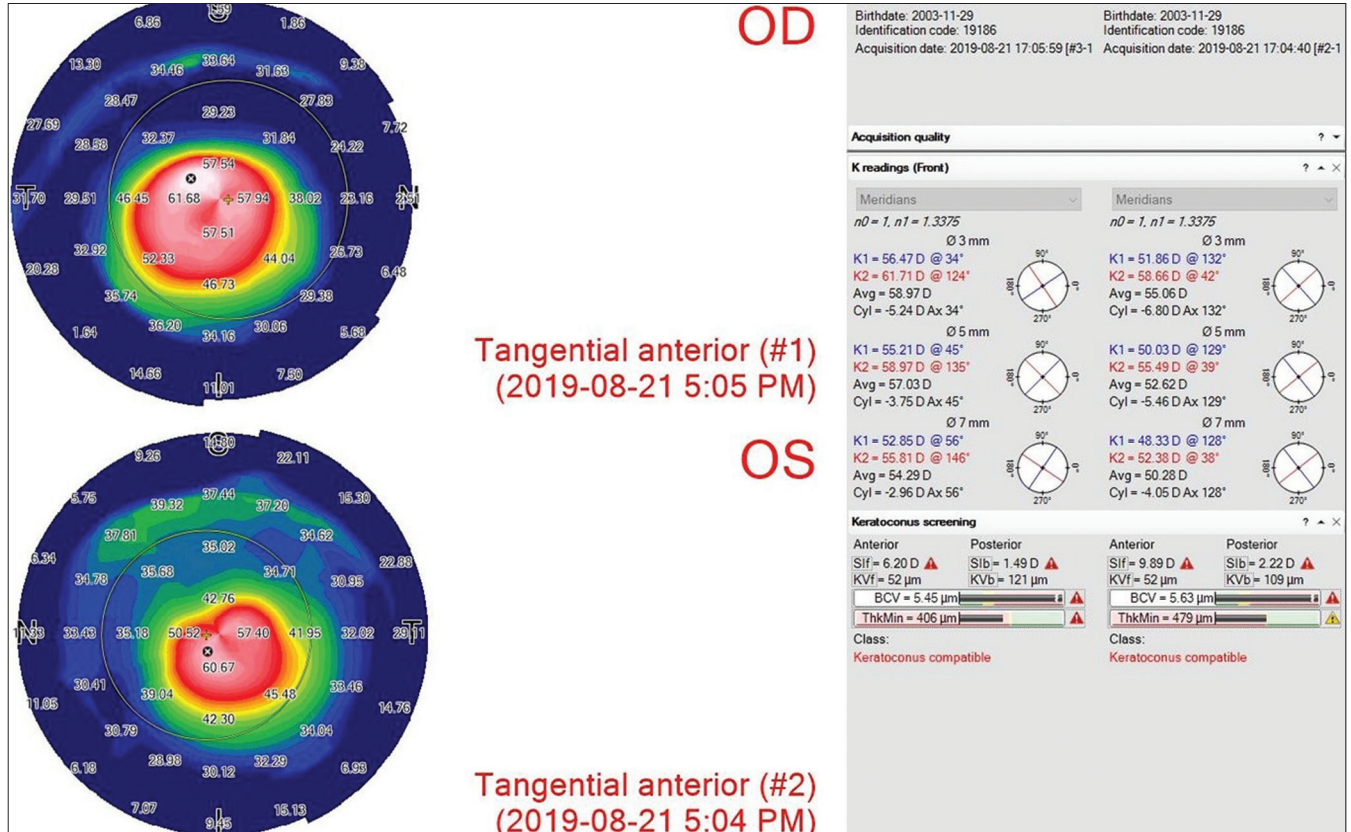


Figure 3: Corneal topography combined with the tomography of both the eyes showed central corneal steepening, reduced corneal thickness, and abnormal anterior and posterior elevation indices at the first visit of the patient

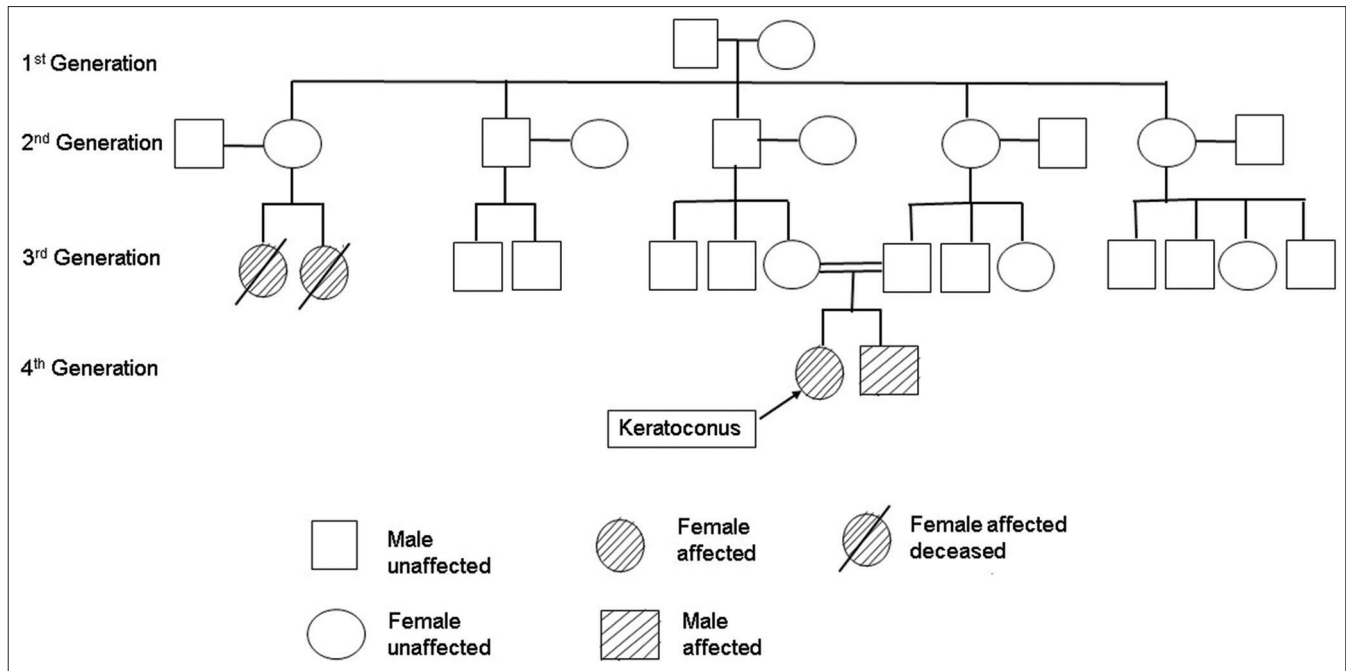


Figure 4: Pedigree chart of the family of the patient with hereditary sensory and autonomic neuropathy

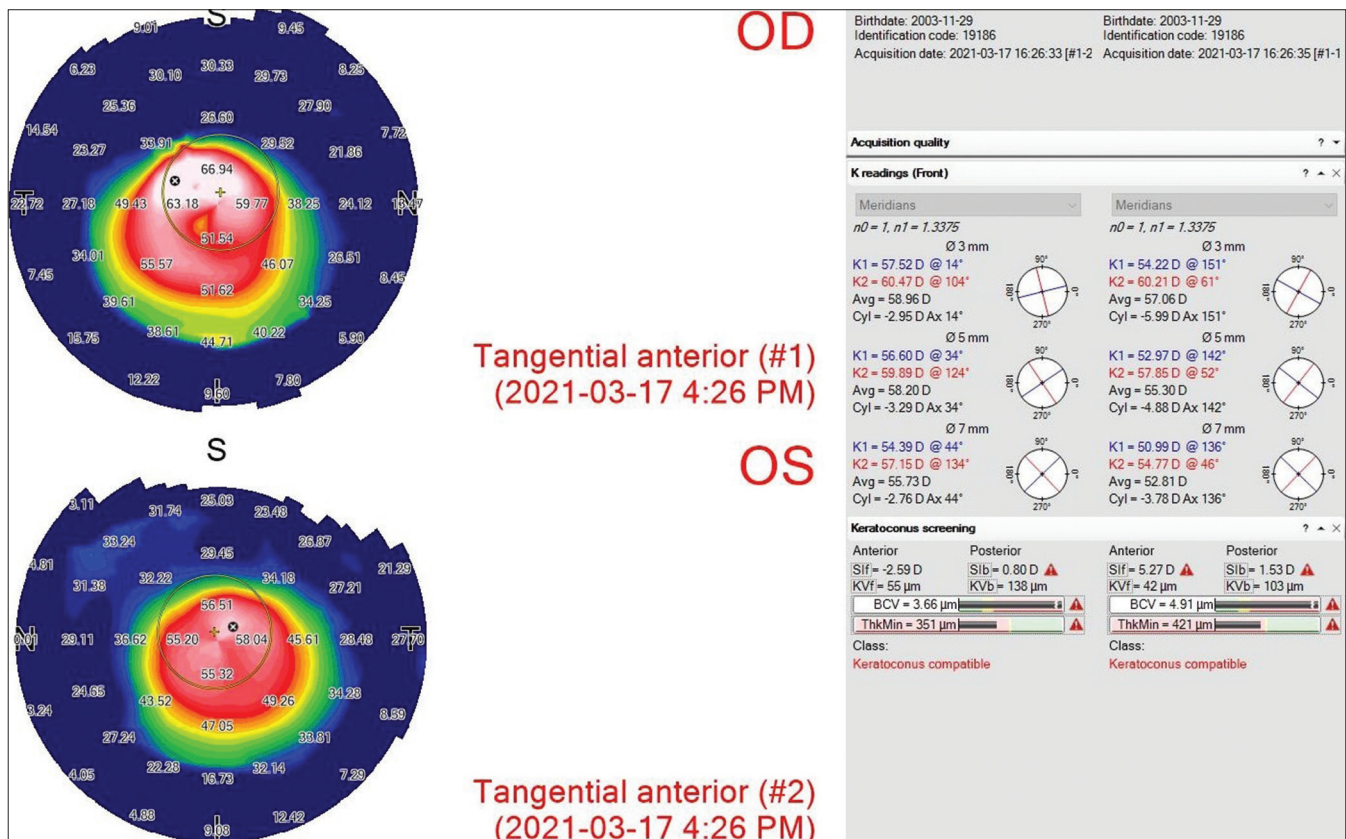


Figure 5: Corneal topography combined with the tomography of both the eyes showed increased central corneal steepening, reduced corneal thickness, and abnormal anterior and posterior elevation indices on the follow-up visit of the patient

At the baseline examination, her distance best-corrected distance visual acuity (BCVA) was 20/80 OD and 20/60 OS with a refractive error of -8.00/-2.00 × 80 OD and -6.00/-2.50 × 110

OS. The slit-lamp bio-microscopy of the right eye showed Vogt's striae while protrusion, Fleischer ring, and prominent corneal nerves were present in both eyes [Fig. 2a and b].

Munson's sign was visible in OU [Fig. 2c]. Her intraocular pressures were normal. Sirius corneal topographer combined with Scheimpflug tomographer showed bilateral central steepening in OU [Fig. 3]. The corneal apex power and thinnest pachymetry were 68.3 D and 406 μm in OD and 61.4 D and 479 μm in OS, respectively.

Her fundus examination showed mild temporal disk pallor in both eyes. Schirmer's 1 test was found to be within the normal range. A wisp of the cotton-tipped applicator was used for the qualitative assessment of the corneal sensations, which were found to be absent. The laboratory investigations were within normal limits. The MRI of the brain and spinal cord was normal. The nerve biopsy report was not available. The patient was called for a follow-up visit of the contact lens trial after 3 days.

A pedigree charting was done [Fig. 4]. The examination of the patient's parents and sibling was undertaken. The ocular examination did not show any similar or significant findings.

The patient did not come for the follow-up as per advice. The patient visited us after approximately 1.5 years. On examination, her distance BCVA was reduced to 20/120 OD and 20/60⁻² OS with a refractive error of $-8.00/-3.00 \times 90$ OD and with $-7.00/-2.50 \times 100$ OS. The corneal tomography showed that the corneal apex power had increased to 81.1 D OD and 63.3 D OS whereas the thinnest corneal thickness was decreased to 351 μm OD and 421 μm OS, respectively [Fig. 5]. The patient was given a trial of semi-scleral contact lenses, and with them, her distance visual acuity improved to 20/40⁻² OD and 20/30 OS. The epithelium-on corneal collagen cross-linking (CXL) was offered with explained prognosis.

Discussion

This case report describes a rare association of keratoconus with HSAN II. Keratoconus is usually an isolated sporadic condition, although multiple reports have described its association with other systemic or ocular disorders or in combination with rare genetic diseases.^[6]

The previous studies have reported that keratoconus in the pediatric age group with some genetic associations tends to progress rapidly.^[7] In our case too, the keratoconus progressed drastically in 1.5 years which demonstrates that pediatric keratoconus progresses more aggressively.

Rapidly progressive keratoconus is an indication of CXL.^[8] In this case, corneal sensations have been lost due to HSAN II. Considering the neurotrophic status of the cornea, epithelium-on CXL was advised. Any corneal surgery on the neurotrophic cornea can lead to poor wound healing and epithelial changes such as punctate epithelial keratopathy, persistent epithelial defects, corneal ulcer, and perforation.^[9] Owing to the possibility of corneal erosions, the corneal lenses were also not recommended. The patient was managed with scleral contact lenses, which are both safe and effective because they rest on the sclera. However, due to finger mutilations in

both hands, the patient will be reliant on her parents for lens insertion and removal.

The reported genes associated with HSAN II are HSN2/WNK1, FAM134B, and K1F1A,^[1] although no mutations were directly linked with keratoconus. Nerve biopsy and chromosomal analysis might have provided more information about the case. However, those could not be done and account for a limitation of our study.

Our case provides further evidence that HSANs are commonly associated with ocular problems, highlighting the significance of a detailed ophthalmic evaluation in these diseases.

Declaration of patient consent

The authors certify that they have obtained all appropriate patient consent forms. In the form the patient(s) has/have given his/her/their consent for his/her/their images and other clinical information to be reported in the journal. The patients understand that their names and initials will not be published and due efforts will be made to conceal their identity, but anonymity cannot be guaranteed.

Financial support and sponsorship

Nil.

Conflicts of interest

There are no conflicts of interest.

References

1. Auer-Grumbach M. Hereditary sensory and autonomic neuropathies. In: Handbook of Clinical Neurology. Vol. 115. Elsevier; 2013. p. 893-906.
2. King R. Hereditary sensory and autonomic neuropathy. In: Vallat J-M, Weis J, editors. Peripheral Nerve Disorders. Chichester, UK: John Wiley & Sons, Ltd; 2014. p. 119-25.
3. Mendoza-Santiesteban CE, Hedges TR 3rd, Norcliffe-Kaufmann L, Warren F, Reddy S, Axelrod FB, *et al.* Clinical neuro-ophthalmic findings in familial dysautonomia. *J Neuroophthalmol* 2012;32:23-6.
4. Gaur N, Meel R, Anjum S, Singh P. Hereditary sensory and autonomic neuropathy in a male child: 'The other side of not feeling pain.' *BMJ Case Rep* 2018;2018:bcr-2018-226873.
5. Sethi A, Ramasubramanian S, Swaminathan M. The painless eye: Neurotrophic keratitis in a child suffering from hereditary sensory autonomic neuropathy type IV. *Indian J Ophthalmol* 2020;68:2270-2.
6. Omer K. Epidemiology of keratoconus worldwide. *Open Ophthalmol J* 2018;12:289-99.
7. Mukhtar S, Ambati BK. Pediatric keratoconus: A review of the literature. *Int Ophthalmol* 2018;38:2257-66.
8. Mohammadpour M, Masoumi A, Mirghorbani M, Shahraki K, Hashemi H. Updates on corneal collagen cross-linking: Indications, techniques and clinical outcomes. *J Curr Ophthalmol* 2017;29:235-47.
9. Lambiase A, Sacchetti M. Diagnosis and management of neurotrophic keratitis. *Clin Ophthalmol* 2014;8:571-9.