

Primary amyloidosis involving the gastrointestinal tract, mesentery and omentum: A case report

GUIHUA DUAN¹, MIN QI², QIANG GUO¹ and ZHENGJI SONG¹

¹Department of Gastroenterology, The First People's Hospital of Yunnan Province, The Affiliated Hospital of Kunming University of Science and Technology, Kunming, Yunnan 650032; ²Department of Radiology, The Third People's Hospital of Kunming City, The Sixth Affiliated Hospital of Dali University, Kunming, Yunnan 650041, P.R. China

Received February 24, 2020; Accepted September 11, 2020

DOI: 10.3892/etm.2021.10579

Abstract. Amyloidosis, a systemic disease characterized by the deposition of misfolded protein, is difficult to rapidly diagnose due to its wide range of symptoms. The present study reported on a case of primary amyloidosis (AL) with involvement of the gastrointestinal tract, mesentery and omentum in a 66-year-old male presenting with recurrent diarrhoea and abdominal distension. Oesophagogastroduodenoscopy and enteroscopy revealed multiple gastric ulcers and multiple protuberant lesions in the colon. Laparotomy indicated multiple nodules in the mesentery of the small intestine. Contrast-enhanced CT revealed dilation of the small bowel with pneumatosis intestinalis and positive Congo red staining of gastric mucosa and mesentery biopsy specimens confirmed amyloid deposition. Therefore, the patient was diagnosed with AL. In this case, the clinical manifestation of mesentery amyloidosis was multiple nodules and extensive peritoneal adhesions, which, to the best of our knowledge, has not been reported by any previous study.

Introduction

Amyloidosis is a disease characterized by extracellular deposition of misfolded protein and involves multiple organs and tissue with widely varying clinical features (1). Thus, due to the wide range of symptoms, amyloidosis is difficult to rapidly diagnose. Several studies have reported amyloidosis with involvement of the gastrointestinal tract or peritoneum (2-10), but reports of amyloidosis involving both organs are rare. The present study reported a rare case of primary amyloidosis (AL) simultaneously involving the gastrointestinal tract, mesentery and omentum.

Case report

A 66-year-old male presented with repeated diarrhoea and abdominal distension for nine months and a 2-day history of bloody stool. The patient underwent laparotomy 1 month previously for adhesive ileus, which did not relieve his symptoms. The operation revealed multiple nodules in the mesentery of the small intestine and extensive peritoneal adhesions (Fig. 1). Post-operative pathology indicated hyaline degeneration and fibrinoid necrosis with inflammatory cell infiltration. The patient had lost 30 kg of body weight over nine months. He had no history of tuberculosis or rheumatoid arthritis and no family history of hereditary diseases.

On physical examination, the patient's body temperature, blood pressure, respiratory rate, pulse and BMI were 36.8°C, 110/78 mmHg, 19 bpm, 84 bpm and 17.2 kg/m², respectively. Palpation of the abdomen indicated multiple hard nodules of varying sizes in the abdominal wall as well as abdominal tenderness and mild rebound tenderness. Laboratory tests revealed the following (Table I): Haemoglobin 80 g/l, C-reactive protein 13.5 mg/l, erythroid sedimentation rate 28 mm/h, procalcitonin 0.12 ng/ml, globulin 16 g/l, albumin 26 g/l and CA125 187 U/ml. The patient's level of urinary immunoglobulin kappa light chain was 456 mg/l; the immunoglobulin lambda light chain level was normal. Serum immunoglobulin kappa and lambda light chain values were 8.31 and 2.56 g/l, respectively, serum immunoglobulin lambda light chain was decreased. According to bone marrow biopsy, the proportion of plasma cells in the bone marrow was slightly increased. T-SPOT tuberculosis-specific enzyme-linked immunospot assay and tuberculosis antibody tests were negative. Antinuclear antibody and antineutrophil cytoplasmic antibody spectra were also negative. Ultrasound examination of the abdomen demonstrated colonic wall thickening and stiffness. Abdominal contrast-enhanced CT revealed peritoneum and mesentery thickening, as well as distension of the small bowel with pneumatosis intestinalis (Fig. 2). Multiple gastric ulcers were observed on initial upper gastrointestinal endoscopy (Fig. 3), and histological examination revealed superficial gastritis with gland hyperplasia. At another hospital, enteroscopy performed one month previously revealed multiple protuberant lesions in the colon. On double-balloon enteroscopy via the oral route, duodenal and upper jejunal mucosa swelling (Fig. 4), as well

Correspondence to: Professor Zhengji Song, Department of Gastroenterology, The First People's Hospital of Yunnan Province, The Affiliated Hospital of Kunming University of Science and Technology, 157 Jinbi Road, Kunming, Yunnan 650032, P.R. China
E-mail: song4715@163.com

Key words: primary amyloidosis, gastrointestinal tract, mesentery, omentum, pneumatosis intestinalis

Table I. Laboratory data.

Item	Result	Normal values
Hemoglobin (g/l)	80	120-160
Fecal occult blood	+++	Negative
Urinary immunoglobulin kappa light chain (mg/l)	456.0	0-18.5
Urinary immunoglobulin lambda light chain (mg/l)	<50.0	0-50
Serum immunoglobulin kappa light chain (g/l)	8.31	6.29-13.5
Serum immunoglobulin lambda light chain (g/l)	2.56	3.13-7.23
C-reactive protein (mg/l)	13.5	0-8
PCT (ng/ml)	0.12	0-0.05
ESR (mm/h)	28	0-15
Albumin (g/l)	26	35-55
Globulin (g/l)	16	20-30
CA125 (U/ml)	187.00	0-35
T-SPOT.TB and tuberculosis antibody	Negative	Negative
ANCA and ANAs	Negative	Negative

ESR, erythroid sedimentation rate; PCT, procalcitonin.

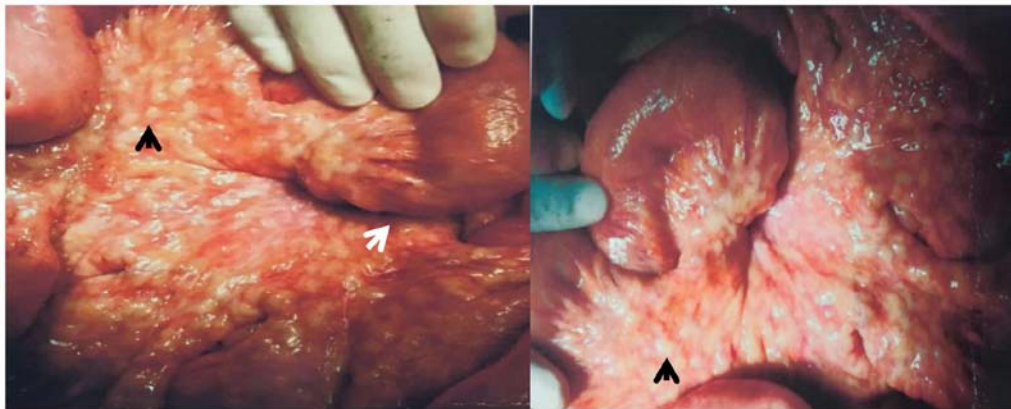


Figure 1. Multiple nodules in the mesentery of the small intestine (black arrow) and extensive peritoneal adhesions (white arrow) were observed during surgery.

as villous atrophy, were detected. Histological examination indicated chronic mucositis.

As the patient's symptoms were not relieved by our treatment or explained by the results of the examinations, repeated upper gastrointestinal endoscopy was performed, which revealed multiple gastric ulcers that bled easily upon contact. Congo red staining of gastric mucosa biopsy specimens confirmed the presence of amyloid deposits (Fig. 5). In addition, non-branching fibrils were observed in the gastric mucosa by electron microscopy. In mesentery biopsy specimens that were acquired during surgery, hyaline degeneration of arteriole walls was revealed by haematoxylin-eosin staining and those samples were positive on Congo red staining (Fig. 5). According to all available information and examinations of this patient, a diagnosis of AL involving the gastrointestinal tract and peritoneum was made. The patient was subsequently treated with corticosteroids and thalidomide. Regrettably, the patient responded poorly to treatment and died from massive haemorrhage of the gastrointestinal tract one month later.

Discussion

Amyloidosis is characterized by abnormal extracellular deposition of diverse types of amyloid proteins within various organs. Congo red staining is a common, effective test used to differentiate amyloid deposits from other protein deposits (1). Furthermore, nonbranching fibrils may be observed under electron microscopy in amyloidotic tissue (11). There are two major types of amyloidosis (12). The most common form is AL, which is associated with abnormal deposition of monoclonal immunoglobulin light chain (13,14) produced by a plasma cell clone. AL is also associated with plasma cell dyscrasias. The second most common form is secondary amyloidosis, which is associated with abnormal deposition of serum amyloid protein A. This form typically occurs as a result of chronic inflammatory diseases or infections. In the patient of the present study, urinary Igk was significantly increased, the proportion of plasma cells in the bone marrow was slightly increased and

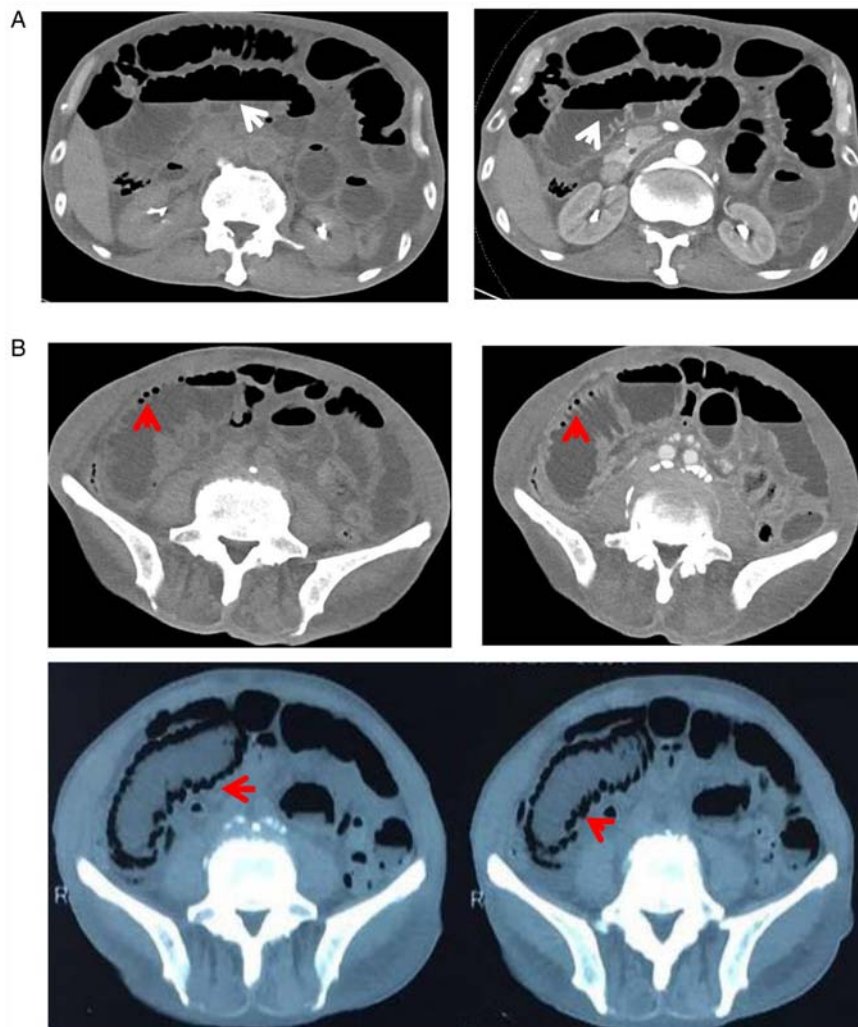


Figure 2. CT scans of the abdomen displaying (A) distension of the small bowel with pneumatosis and effusion (white arrow) and (B) distension of the small bowel with pneumatosis intestinalis (red arrow).

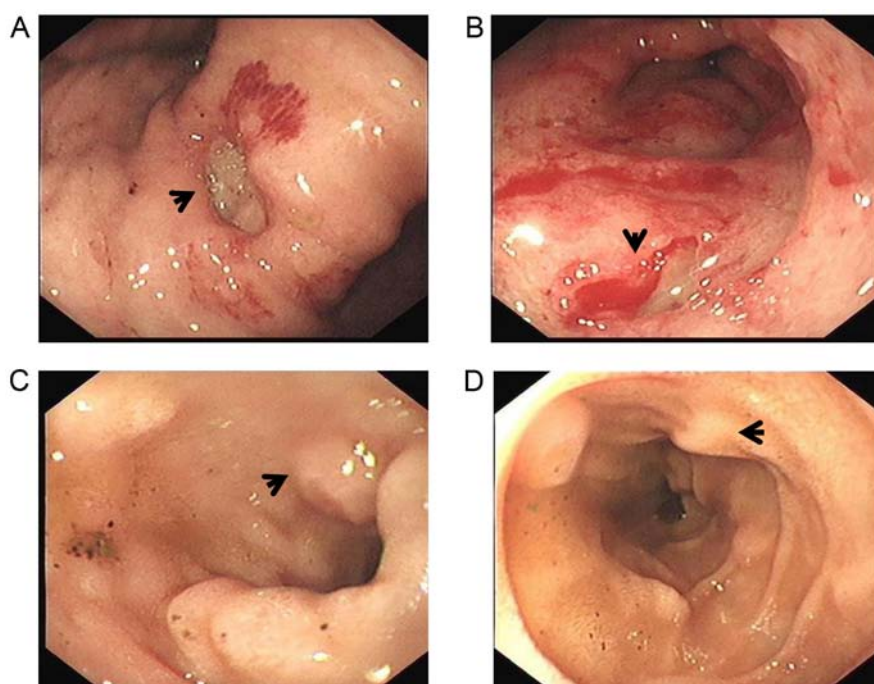


Figure 3. Upper gastrointestinal endoscopy revealing (A and B) multiple gastric ulcers (black arrow) and (C and D) swollen duodenal mucosa (black arrow).

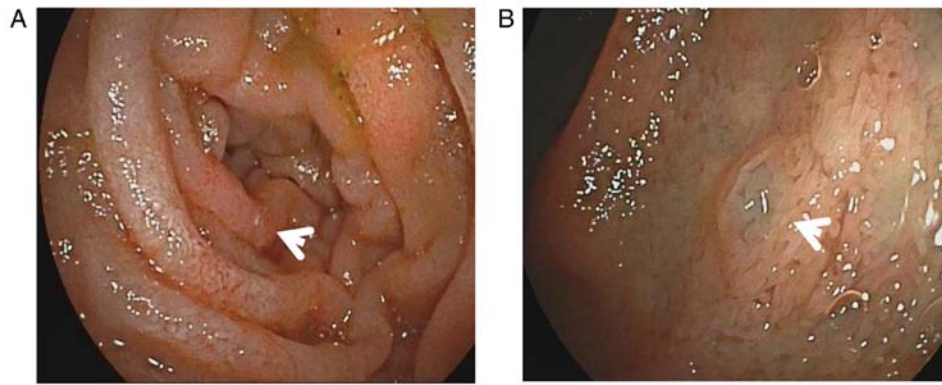


Figure 4. Double-balloon enteroscopy displaying swollen (A) duodenal (white arrow) and (B) upper jejunal mucosa (white arrow).

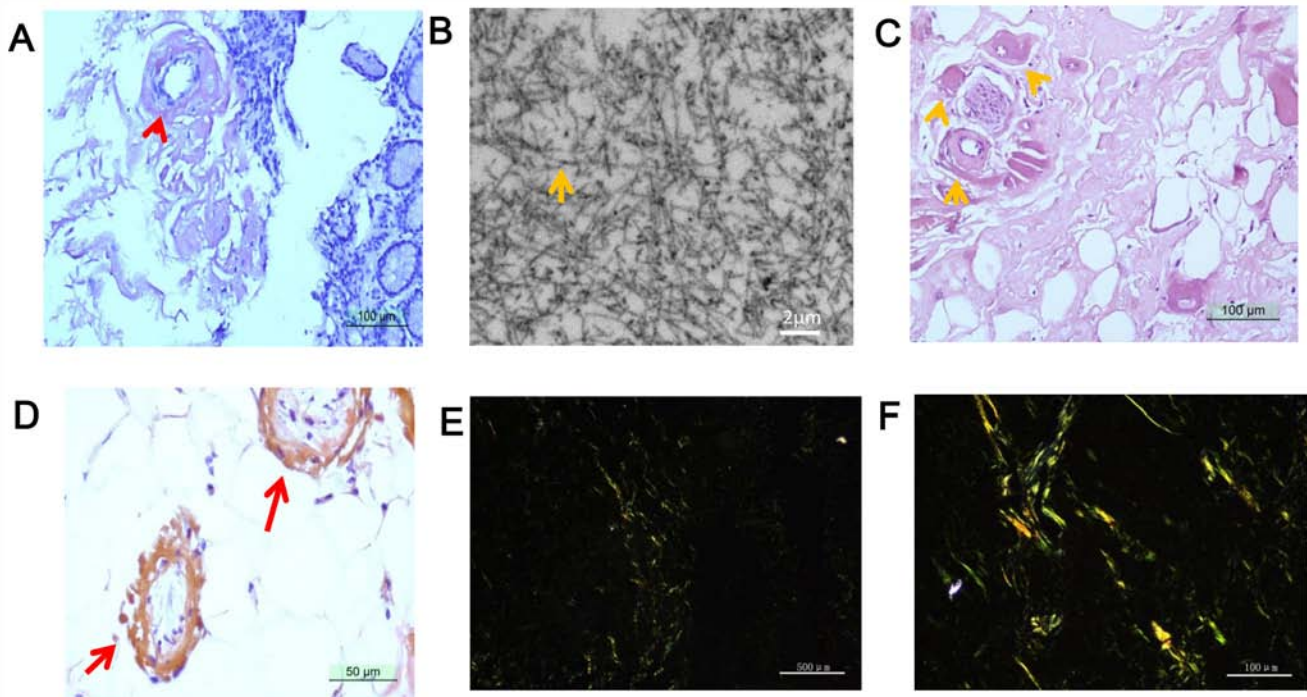


Figure 5. (A) Histopathology of gastric mucosa revealing orange-red amyloid deposits on Congo red staining (red arrow in magnified window). (B) Non-branching fibrils observed in the gastric mucosa by electron microscopy (yellow arrow; scale bar, 2 μm). (C) Histopathology of the mesentery indicating hyaline degeneration of arteriole walls (yellow arrow in magnified window; scale bar, 50 μm). (D) Histopathology of the mesentery revealing orange-red amyloid deposits on Congo red staining (red arrow; scale bar, 50 μm). (E and F) Congo red staining of mesentery with apple-green birefringence under polarized light microscopy (scale bar, 500 μm in A, C and E; 100 μm in F).

multiple organs were involved; therefore, this patient was diagnosed with AL.

The mesentery is a double layer of peritoneum that suspends the small and large bowel from the posterior abdominal wall, preventing these organs from collapsing into the pelvis (15). The mesentery, which contains vessels, nerves, lymphoid tissue, adipose tissue, fibrous tissue and macrophages (16), supplies the intestinal tract with nutrients and is involved in immune defence. These anatomical and functional features suggest that the mesentery acts as an organ (16). Furthermore, mesenteric abnormalities have been indicated to be involved in numerous diseases. The abdominal distension of the patient of the present study was likely due to amyloid deposition in the mesentery. Several studies have reported that the clinical presentation of amyloidosis involves the mesentery (6,7,9). In

the present case, mesentery amyloidosis was detected, which manifested as multiple nodules and extensive peritoneal adhesions; such a presentation has not been previously reported likely due to its rarity, to the best of our knowledge. Therefore, in the future, Congo red staining should be considered in similar situations.

Pneumatosis intestinalis is characterized by gas pockets in the wall of the small or large bowel (17); however, the pathogenesis of this condition remains elusive. One study speculated that pneumatosis intestinalis is due to disruption of intestinal mucosal integrity by amyloid deposits, leading to infiltration of luminal gas or gas-producing bacteria (18). Although gastrointestinal amyloidosis is a rare cause of pneumatosis intestinalis, several studies have reported that amyloidosis involving the intestinal tract may present as

pneumatosis intestinalis (17,19). Indeed, the patient of the present study had pneumatosis intestinalis. These results indicate that pneumatosis intestinalis may be a sign of amyloidosis involving the gastrointestinal tract, which may help accelerate the diagnosis of amyloidosis when it involves multiple organs and pneumatosis intestinalis is present.

The principle of the treatment of AL is to eliminate the underlying abnormal plasma cells by chemotherapy associated with haematopoietic stem cell transplantation. Corticosteroids have been indicated to be useful in the treatment of patients with AL experiencing refractory diarrhoea and protein loss enteropathy (20). Accordingly, the patient of the present study was treated with corticosteroids and thalidomide, which temporarily relieved his symptoms.

In summary, the present study reported on a rare case of AL simultaneously involving the gastrointestinal tract, mesentery and omentum. The detailed endoscopic and laparotomy findings for this case were also presented. Early diagnosis of AL is important, as most cases are diagnosed at a late stage and have poor prognosis. In patients with unexplained gastrointestinal symptoms, particularly those with multisystemic involvement, Congo red staining is recommended.

Acknowledgements

Not applicable.

Funding

No funding was received.

Availability of data and materials

All datasets used and/or analysed during the current study are available from the corresponding author on reasonable request.

Authors' contributions

GD and ZS conceptualized and designed the case study. MQ interpreted CT images and performed data collection. GD and QG analysed and interpreted the data. GD and ZS drafted and critically revised the manuscript. All authors read and approved the final manuscript.

Ethics approval and consent to participate

The study protocol conformed to the ethical guidelines of the Declaration of Helsinki and was approved by the Ethics Review Committee of The First People's Hospital of Yunnan Province (Kunming, China). Written informed consent was obtained from the legal guardian of the patient.

Patient consent for publication

The legal guardian of the patient provided consent for the publication of this case report.

Competing interests

The authors declare that they have no competing interests.

References

- Hazenbergh BP, van Gameren II, Bijzet J, Jager PL and van Rijswijk MH: Diagnostic and therapeutic approach of systemic amyloidosis. *Neth J Med* 62: 121-128, 2004.
- Asakura K, Yanai S, Nakamura S, Kawasaki K, Eizuka M, Ishida K, Sugai T, Ueda M, Yamashita T, Ando Y and Matsumoto T: Endoscopic findings of small-bowel lesions in familial amyloid polyneuropathy: A case report. *Medicine (Baltimore)* 95: e2896, 2016.
- Wang Z, Huang C and Ji F: Primary amyloidosis mimicking Crohn's disease: A case report. *Int J Clin Exp Med* 8: 16137-16139, 2015.
- Siau K, Elzubeir A, Cooper SC and Iqbal T: Amyloidosis: An unusual cause of upper gastrointestinal bleeding. *BMJ Case Rep* 2016: bcr2016217653, 2016.
- Groisman GM and Cohen HI: Small intestinal amyloidosis: A rare cause of diverticular disease. *Case Rep Pathol* 2014: 362835, 2014.
- Vanhoenacker F, Vanwambeke K and Jacomen G: Amyloidosis: An unusual cause of mesenteric, omental and lymph node calcifications. *JBR-BTR* 97: 283-286, 2014.
- Coulier B, Montfort L, Doyen V and Gielen I: MDCT findings in primary amyloidosis of the greater omentum and mesentery: A case report. *Abdom Imaging* 35: 88-91, 2010.
- Horger M, Vogel M, Brodoeufel H, Schimmel H and Claussen C: Omental and peritoneal involvement in systemic amyloidosis: CT with pathologic correlation. *AJR Am J Roentgenol* 186: 1193-1195, 2006.
- Halm U, Berr F, Tannapfel A, Klöppel R, Secknus R and Mössner J: Primary amyloidosis of the mesentery and the retroperitoneum presenting with lymphedema. *Am J Gastroenterol* 93: 2299-2300, 1998.
- Poturoğlu S, Mungan Z, Boztaş G, Kaymakoglu S, Ozdil S, Akyüz F, Aksoy N, Kamali S, Pinarbasi B, Cevikbaş U and Okten A: Peritoneal amyloidosis caused by familial mediterranean fever. *J Gastroenterol Hepatol* 20: 325-326, 2005.
- Sipe JD and Cohen AS: Review: History of the amyloid fibril. *J Struct Biol* 130: 88-98, 2000.
- Sipe JD, Benson MD, Buxbaum JN, Ikeda S, Merlini G, Saraiva MJ and Westermarck P: Nomenclature 2014: Amyloid fibril proteins and clinical classification of the amyloidosis. *Amyloid* 21: 221-224, 2014.
- Freudenthaler S, Hegenbart U, Schönland S, Behrens HM, Krüger S and Röcken C: Amyloid in biopsies of the gastrointestinal tract—a retrospective observational study on 542 patients. *Virchows Arch* 468: 569-577, 2016.
- Cowan AJ, Skinner M, Seldin DC, Berk JL, Lichtenstein DR, O'Hara CJ, Doros G and Sancharawala V: Amyloidosis of the gastrointestinal tract: A 13-year, single-center, referral experience. *Haematologica* 98: 141-146, 2013.
- Patel RR and Planche K: Applied peritoneal anatomy. *Clin Radiol* 68: 509-520, 2013.
- Coffey JC and O'Leary DP: The mesentery: Structure, function, and role in disease. *Lancet Gastroenterol Hepatol* 1: 238-247, 2016.
- Raghunathan V, Louis D and Wirk B: Gastrointestinal tract amyloidosis presenting with pneumatosis intestinalis. *J Clin Med Res* 9: 654-658, 2017.
- Khalil PN, Huber-Wagner S, Ladurner R, Kleespies A, Siebeck M, Mutschler W, Hallfeldt K and Kanz KG: Natural history, clinical pattern, and surgical considerations of pneumatosis intestinalis. *Eur J Med Res* 14: 231-239, 2009.
- Khalid F, Kaiyasa H, Binfadil W, Majid M, Hazim W and ElTayeb Y: Pneumatosis intestinalis due to gastrointestinal amyloidosis: A case report & review of literature. *Int J Surg Case Rep* 23: 29-32, 2016.
- Gertz MA: How to manage primary amyloidosis. *Leukemia* 26: 191-198, 2012.



This work is licensed under a Creative Commons Attribution-NonCommercial-NoDerivatives 4.0 International (CC BY-NC-ND 4.0) License.