

Received: 2021.02.22

Accepted: 2021.04.29

Available online: 2021.05.25

Published: 2021.07.02

# Oncocytic Papillary Carcinoma in an Autonomous Thyroid Nodule

## Authors' Contribution:

Study Design A  
Data Collection B  
Statistical Analysis C  
Data Interpretation D  
Manuscript Preparation E  
Literature Search F  
Funds Collection GABCDEF 1 **Kyle Cunningham**  
ABCDE 2 **Jonathan Antonetti**  
ABE 2 **Barton Wood**

1 OMS-IV, Alabama College of Osteopathic Medicine, Dothan, AL, USA

2 Department of Surgery, Brookwood Baptist Health, Birmingham, AL, USA

**Corresponding Author:** Kyle Cunningham, e-mail: [kcunn924@gmail.com](mailto:kcunn924@gmail.com)**Conflict of interest:** None declared**Patient:** Female, 30-year-old  
**Final Diagnosis:** Papillary thyroid carcinoma  
**Symptoms:** Hyperthyroidism • thyroid mass  
**Medication:** —  
**Clinical Procedure:** Thyroidectomy  
**Specialty:** Surgery**Objective:** Rare disease**Background:** Thyroid nodules are a common cause of neck swelling in clinical practice, even in iodine-sufficient communities. Most nodules are benign, but malignancy cannot be excluded. The majority of thyroid cancers occur in nonfunctioning nodules, but in rare cases they can present as an autonomous nodule. Papillary carcinoma, the most common type of thyroid malignancy, typically spreads quickly to local lymph nodes; however, current guidelines do not recommend biopsy of autonomous thyroid nodules. Early detection and surgical intervention can be curative in many of these cases.**Case Report:** This present case involved a woman in her early 30s who presented with an enlarging neck mass. Ultrasound demonstrated a unilateral right thyroid mass, and blood work showed triiodothyronine thyrotoxicosis. Thyroid scintigraphy was performed and showed unilateral increased uptake on the right side. The patient was treated initially with a thyroid lobectomy. Intraoperative frozen sectioning of the removed specimen showed papillary thyroid carcinoma, and a total thyroidectomy was performed. Radioactive iodine ablation therapy was not done, but given the patient's history and risk factors, recurrence of her disease is unlikely.**Conclusions:** The vast majority of autonomous thyroid nodules are noncancerous. However, patients should be informed of the possibility of malignancy, and cancer should be ruled out clinically. Papillary thyroid carcinoma accounts for the majority of tumors in both hot and cold nodules. However, the oncocytic subtype seen in the patient in this report is less common, presents a higher risk of recurrence, and typically occurs in older patients. Thyroidectomy is usually curative for patients with papillary thyroid carcinoma.**Keywords:** Hyperthyroidism • Thyroid Neoplasms • Thyroid NoduleFull-text PDF: <https://www.amjcaserep.com/abstract/index/idArt/931757>

910



1



7



## Background

Thyroid nodules are very common in clinical practice, with palpable nodules being found in about 5% of women and 1% of men in iodine-sufficient communities [1]. Thyroid cancer occurs in 7-15% of these patients, with papillary and follicular cancer accounting for more than 90% of the cases. Ultrasound should be performed on all patients with a thyroid nodule to confirm location and characteristics of the nodule. The vast majority of thyroid cancers present in a hypofunctioning (“cold”) nodule, but may present in a hyperfunctioning (“hot”) nodule in as many as 3.1% of cases [2]. The 2016 American Thyroid Society guidelines [1] state the following: “Since hyperfunctioning nodules rarely harbor malignancy, if one is found that corresponds to the nodule in question, no cytologic evaluation is necessary.” However, the possibility of cancer should not be ruled out completely in these patients. This case report describes a patient who presented with a unilateral hyperfunctioning thyroid nodule that was found to be cancerous upon thyroidectomy.

## Case Report

A woman in her early 30s presented to the clinic after being referred for a unilateral right neck mass that she had first noticed 3-4 weeks prior. She denied any symptoms of dysphagia, hoarseness, coughing, or fatigue. Physical exam was notable for an approximately 1.5-cm nodule in the right lobe of the thyroid.

Ultrasound showed a 1.3×1.2-cm solid nodule with irregular borders. Thyrotropin was low at 0.005 mU/L, while triiodothyronine was high at 5.03 nmol/L. The patient was referred for thyroid scintigraphy, which demonstrated significantly increased uptake in the right lobe of the thyroid compared with the left (Figure 1). The 24-h thyroid uptake was calculated at 53%, with normal values being 7-35%. Thyroid autoantibody titers were not obtained at this time.

The patient consented to undergo a thyroid lobectomy with possible total thyroidectomy. The right lobe of the thyroid was removed and sent to pathology during the operation. Frozen sectioning showed a 1.2-cm papillary thyroid carcinoma, oncocytic type, with 1 involved lymph node but no extranodal or vascular invasion. At this time, the left lobe of the thyroid was removed. The patient’s postoperative course was unremarkable, with no symptoms of hoarseness, dysphagia, or hypocalcemia the day after surgery. Radioactive iodine ablation therapy was deferred owing to the patient’s desire to become pregnant in the near future. The patient had no further complaints at her follow-up visit 1 month after surgery, including no hoarseness or symptoms of hypoparathyroidism. She is currently taking

levothyroxine for thyroid hormone replacement, and there is no evidence of disease recurrence at this time.

Final pathological examination showed papillary carcinoma, oncocytic variant, with 1 involved lymph node but no extranodal or extrathyroidal extension. The background parenchyma of the right thyroid lobe demonstrated diffuse hyperplasia and focal calcifications but no lymphocytosis. The left lobe showed focal nodular hyperplasia with otherwise normal findings. Genetic testing of the specimen was not performed.

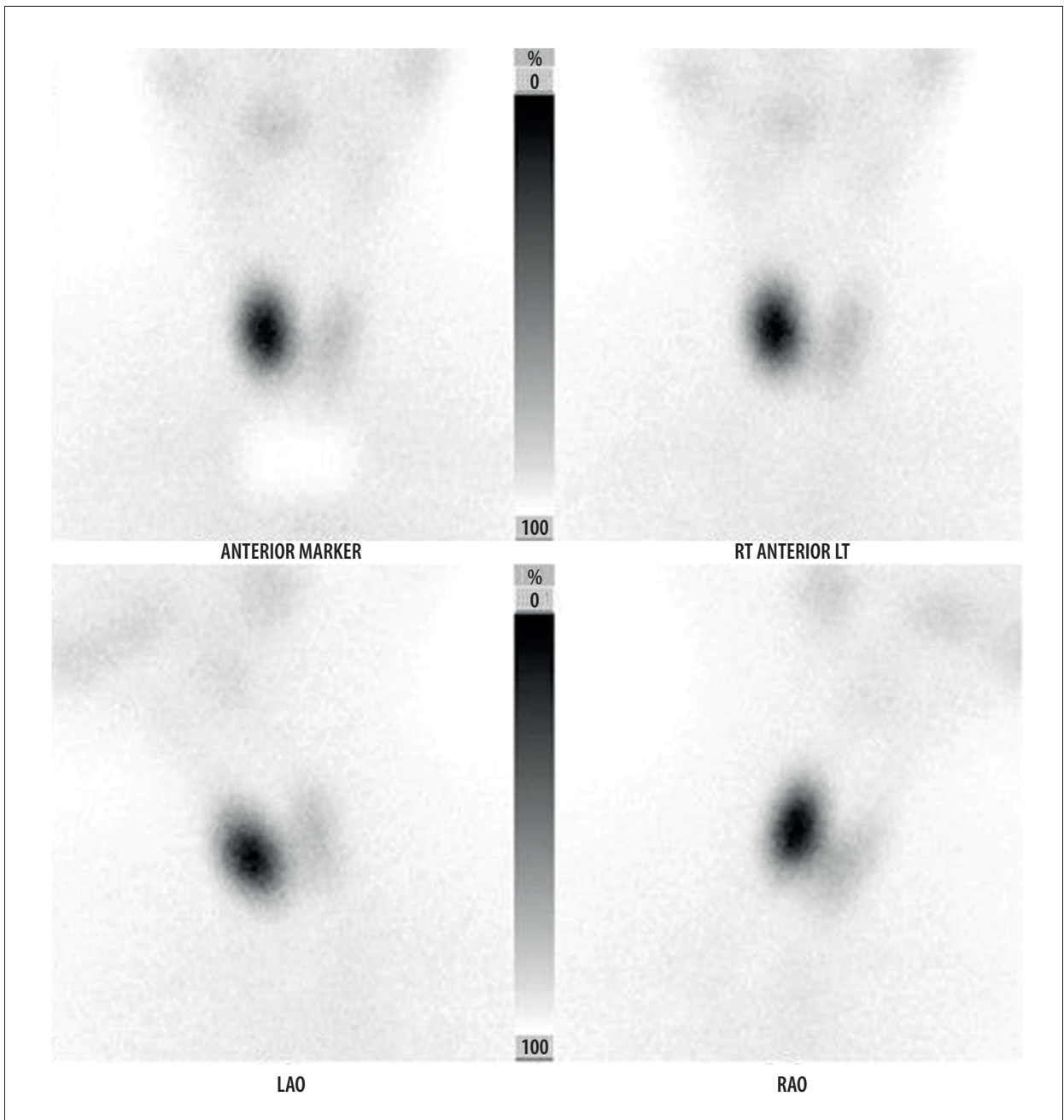
## Discussion

Although cancer in hot thyroid nodules is less common than in cold nodules, it does occur in approximately 3.1% of cases. Current guidelines do not recommend fine-needle aspiration and cytology of these masses, even in the presence of suspicious ultrasonography findings such as irregular borders that would warrant further testing in a cold nodule [1]. Papillary thyroid carcinoma represents 70-80% of all thyroid cancers but only 57.1% of tumors in autonomous nodules [2,3], with the majority of cases being conventional papillary thyroid carcinoma. The specimen removed in this case was the oncocytic variant of papillary thyroid carcinoma, which accounts for 5% of papillary thyroid carcinomas [4]. A review of the literature performed in 2013 did not find any cases of a hyperfunctioning oncocytic papillary thyroid carcinoma, so this patient’s case is extremely rare [2]. Oncocytic papillary thyroid carcinoma typically presents in older patients, with an average age at presentation 5 years older than other papillary carcinoma subtypes [5]. Oncocytic type papillary carcinoma also typically presents with a larger tumor, with an average size in 1 study of 2.8 cm compared with 1.5 cm for other papillary carcinomas.

Papillary thyroid carcinoma spreads quickly to local lymph nodes, but surgery is usually curative. The 10-year survival rate after surgery is approximately 97%, with female sex and younger age being associated with a better prognosis [6]. Thyroidectomy prevents recurrence of hyperthyroidism in more than 99% of patients with a hot nodule without the need for further radioactive iodine ablation therapy [7]. However, oncocytic papillary thyroid carcinoma is more likely to recur than other types of thyroid carcinoma [5]. Despite this risk, this patient’s prognosis is good, with very little risk for recurrence of her disease.

## Conclusions

Thyroid nodules are a common cause of a unilateral neck mass. Most nodules are noncancerous, and the current standard of care is not to perform a fine-needle aspiration on patients with a solitary thyroid nodule and hyperthyroidism. However,



**Figure 1.** Radioactive iodine uptake scan using  $^{123}\text{I}$  showing unilateral increased uptake on the right side.

early detection and treatment of a thyroid malignancy can be curative and prevent metastasis to lymph nodes, and cancer cannot be ruled out without pathological study of the specimen. Given that fine-needle aspiration is not recommended for these patients, clinicians should have a low threshold for operative management in order to prevent complications of an untreated malignancy. In addition, the higher recurrence rate of oncocytic papillary carcinoma compared with other types

of papillary carcinoma should encourage physicians to pursue radioactive iodine ablation therapy after surgery to decrease the risk of recurrent disease. In our case, this was declined due to the patient's desire to become pregnant.

#### **Conflict of Interest**

None.

## References:

---

1. Haugen B, Alexander E, Bible K, et al. 2015 American Thyroid Association management guidelines for adult patients with thyroid nodules and differentiated thyroid cancer: The American Thyroid Association Guidelines Task Force on Thyroid Nodules and Differentiated Thyroid Cancer. *Thyroid*. 2016;26(1):1-133
2. Mirfakhraee S, Mathews D, Peng L, et al. A solitary hyperfunctioning thyroid nodule harboring thyroid carcinoma: Review of the literature. *Thyroid Res*. 2013;6(1):7
3. Gonzalez-Gonzalez R, Bologna-Molina R, Carreon-Burciaga RG, Gómezpalacio-Gastelum M, et al. Papillary thyroid carcinoma: Differential diagnosis and prognostic values of its different variants: Review of the literature. *ISRN Oncol*. 2011;2011:915925
4. Carr AA, Yen TWF, Ortiz DI, et al. Patients with oncocytic variant papillary thyroid carcinoma have a similar prognosis to matched classical papillary thyroid carcinoma controls. *Thyroid*. 2018;28(11):1462-67
5. Wenter V, Jellinek A, Unterrainer M, et al. Long-term outcome of rare oncocytic papillary (Hürthle cell) thyroid carcinoma following (adjuvant) initial radioiodine therapy. *Eur J Nucl Med Mol Imaging*. 2019;46:2526-35
6. Ito Y, Miyauchi A, Kihara M, et al. Overall survival of papillary thyroid carcinoma patients: A single-institution long-term follow-up of 5897 patients. *World J Surg*. 2018;42(3):615-22
7. Ross D, Burch H, Cooper D, et al. 2016 American Thyroid Association guidelines for diagnosis and management of hyperthyroidism and other causes of thyrotoxicosis. *Thyroid*. 2016;26(10):1343-421