

# Unusual mucosal lesion: A case of rectal pseudolipomatosis in a 60-year-old patient

SAGE Open Medical Case Reports  
Volume 7: 1–4  
© The Author(s) 2019  
Article reuse guidelines:  
sagepub.com/journals-permissions  
DOI: 10.1177/2050313X19849281  
journals.sagepub.com/home/sco



Boubacar Efared<sup>1,2</sup>, Balandougou Sylla<sup>3</sup>, Nawal Hammas<sup>1,4</sup>,  
Hinde El Fatemi<sup>1,4</sup> and Laila Chbani<sup>1,4</sup>

## Abstract

Pseudolipomatosis is a very rare benign pathologic condition of colorectal mucosa. It is caused by the presence of gas bubbles in the intestinal mucosa. The endoscopic and histologic aspects are misleading as they suggest adipocytic or vascular lesions. We present herein a case of rectal pseudolipomatosis in a 60-year-old woman presenting with rectal bleeding. The endoscopic pattern was not suggestive of the lesion, and the histopathologic analysis of the patient's rectal biopsies revealed characteristic features of pseudolipomatosis. Rectocolic pseudolipomatosis is a very rare benign condition with challenging clinicopathologic presentation. Clinicians and pathologists should be aware of this uncommon lesion for correct diagnosis and appropriate clinical management.

## Keywords

Pseudolipomatosis, mucosa, rectum, histopathology

Date received: 28 January 2019; accepted: 16 April 2019

## Background

Pseudolipomatosis is a very rare pathologic condition initially described by Snover et al.<sup>1</sup> on colorectal mucosa. At histologic analysis, pseudolipomatosis consists of variable-sized optically empty spaces resembling adipocytes embedded in the lamina propria.<sup>1,2</sup> The frequency of pseudolipomatosis varies around 0.3%–1.7% in endoscopic series; however, the exact incidence of this lesion is difficult to assess because of its rarity and likely its diagnosis is often overlooked by pathologists and endoscopists.<sup>2–4</sup> Colic pseudolipomatosis is often diagnosed incidentally or it is found in patients with gastrointestinal disorders such as diarrhea, constipation, abdominal pain or rectal bleeding.<sup>3,5,6</sup> The pathogenesis of pseudolipomatosis is controversial, it is likely due to gas entrapment in the intestinal wall after mucosal injury by endoscopic procedures.<sup>1,2,5,6</sup> However, cases of pseudolipomatosis have been reported in patients with no history of endoscopy, and it has been postulated that the disease likely resulted from released gas from intestinal intraluminal bacteria.<sup>3,7</sup> Also, cases of gastric pseudolipomatosis have been reported in relation to iatrogenic endoscopic procedures or in connection with *Helicobacter pylori* infection.<sup>8–10</sup> Due to its rarity, the diagnosis of pseudolipomatosis can be misleading and challenging.<sup>2,4</sup> In order to increase awareness of this uncommon and banal condition, we

present herein a case of rectal pseudolipomatosis in a 60-year-old patient presenting with rectal bleeding.

## Case presentation

A 60-year-old woman presented with recently discovered mild rectal bleeding. Her medical history was unremarkable and she reported no previous colonoscopy. The physical examination was quite normal with no palpable mass. The patient's laboratory results were within normal limits. She then underwent colonic endoscopy. Approximately, 25 cm from the anal canal, the colonoscopy revealed diffuse rectal erythematous and superficial ulcerations with areas of

<sup>1</sup>Department of Pathology, Hassan II University Hospital, Fès, Morocco

<sup>2</sup>Department of Pathology, Faculté des Sciences de la Santé (FSS), Abdou-Moumouni University, Niamey, Niger

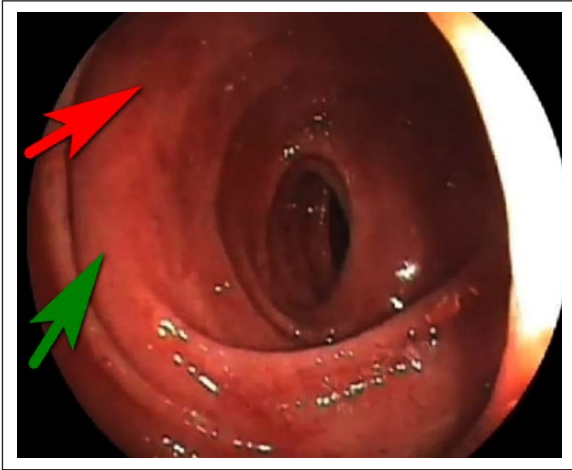
<sup>3</sup>Department of Gastroenterology, Hassan II University Hospital, Fès, Morocco

<sup>4</sup>Laboratory of Biomedical and Translational Research, Faculty of Medicine and Pharmacology, Sidi Mohamed Ben Abdellah University, Fès, Morocco

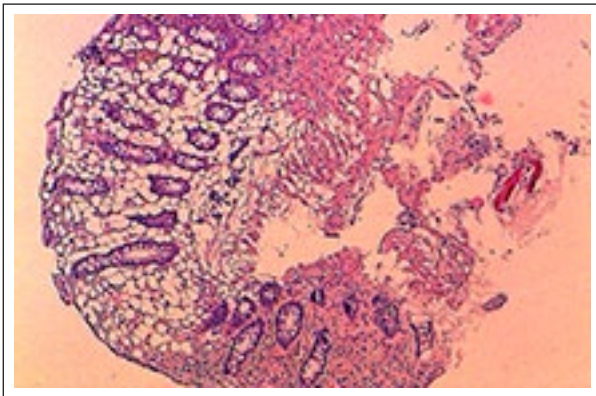
### Corresponding Author:

Boubacar Efared, Department of Pathology, Faculté des Sciences de la Santé (FSS), Abdou-Moumouni University, BP 10896, Niamey, Niger.  
Email: befared2013@gmail.com



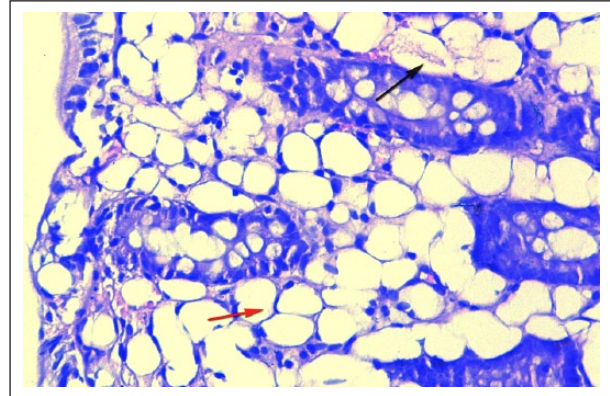


**Figure 1.** Endoscopic view showing erythematous rectal mucosa (red arrow) with areas of normal-looking mucosa (green arrow).



**Figure 2.** The histologic view showing focally ulcerated rectal mucosa recovered by normal epithelium with regular crypts without architectural distortion. The lamina propria is widely occupied by numerous variable-sized optically empty vacuoles resembling adipocytes. (Hematoxylin-eosin 100 $\times$ ).

normal-looking mucosa (Figure 1, arrows). There were no other abnormal mucosal lesions. Biopsies of the rectal ulcerations were performed. The histologic analysis showed focally ulcerated rectal mucosa recovered by normal epithelium with regular crypts without architectural distortion. The lamina propria was widely occupied by numerous variable-sized optically empty vacuoles resembling adipocytes (Figure 2). Focally, these vacuoles were fused and form large spaces with discrete amorphous and eosinophilic content (Figure 3, black arrow). The empty vacuoles were intermingled with inflammatory cells and seem to be lined by cells with oval to flattened nuclei (Figure 3, red arrow). These empty vacuoles were extended to the muscularis mucosae. The immunohistochemical analysis showed weak and focal positive staining with CD31 (Figure 4(a)) and S-100 (Figure 4(b)) around the empty spaces (vacuoles), corresponding to reactive inflammatory cells of the lamina propria. Then, the



**Figure 3.** Focally, the vacuoles are fused and form large spaces with discrete amorphous and eosinophilic content (black arrow). The empty vacuoles are intermingled with inflammatory cells and seem to be lined by cells with oval to flattened nuclei (red arrow) (Hematoxylin-eosin 400 $\times$ ).

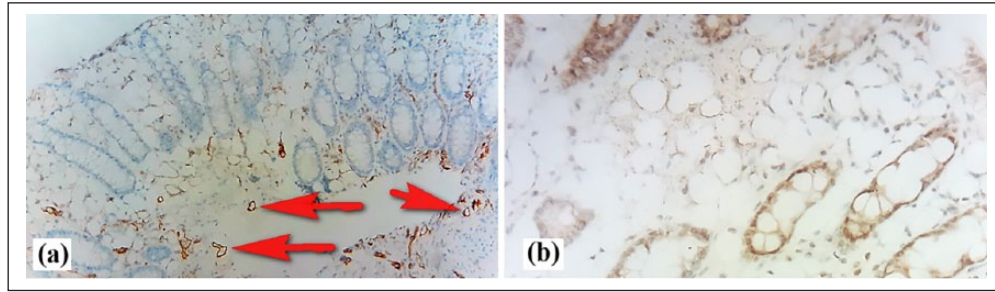
histopathologic diagnosis of rectal pseudolipomatosis was disclosed. After the diagnosis, the patient was lost to follow-up.

## Discussion

Pseudolipomatosis is a rare benign condition that may affect many parts of the digestive tract, especially the stomach or the rectocolic portion.<sup>6,8,9</sup> Also, cases of pseudolipomatosis have been reported in the female genital tract, causing challenging diagnostic issues.<sup>11,12</sup> Pseudolipomatosis affects adult patients with no established sex predominance.<sup>1,3,6</sup>

Despite the endoscopic and histomorphologic fat-like appearance of pseudolipomatosis, histochemical, immunohistochemical and ultrastructural, studies have proven that this appearance is in fact a result of gas accumulation in the mucosa rather than fat cells.<sup>1,3,6</sup> Many authors have reported evidences showing link between endoscopic procedures and the occurrence of pseudolipomatosis.<sup>6,9,10,13</sup> The chemical mucosal injury leading to gas penetration in the colic mucosa was attributed to disinfectants (hydrogen peroxide or peracetic acid) as pseudolipomatosis appeared in epidemic fashion after using these products for endoscopic disinfection.<sup>5,6</sup> It seems that any injury of any nature (chemical or traumatic) of the mucosa can lead to pseudolipomatosis. Kim and Moon<sup>10</sup> reported a case of gastric pseudolipomatosis following submucosal injection of normal saline and indigo carmine dye mixed with hyaluronic acid. Our current case had no history of endoscopic procedures and we have no informations about disinfectants used by the endoscopist.

The diagnosis of pseudolipomatosis could be challenging and misleading especially when both endoscopists and pathologists are not aware of it.<sup>2,4,11</sup> The clinical presentation is often asymptomatic or related to associated diseases (diarrhea, constipation and so on). The characteristic endoscopic



**Figure 4.** Immunohistochemical view showing weak and focal positive staining with CD31 (a) and S-100 (b) around the empty spaces, corresponding to reactive inflammatory cells of the lamina propria. Note the strong CD31 positive staining around vascular spaces in the muscularis mucosae (red arrows) (Immunohistochemistry 50 $\times$  and 100 $\times$ , respectively).

**Table 1.** Differential diagnoses of rectocolic pseudolipomatosis.

	Pseudolipomatosis	Lipoma	Lymphangioma
Age			
children	–	$\pm$	+
adults	+	+	+
Endoscopy	Whitish-yellowish plaques	Elevated mass	Elevated mass
Location			
intramucosal	+	$\pm$	$\pm$
extramucosal	–	+	+
Histology			
circumscription	–	+	+
“empty spaces” nature	Gas	Adipocytes	Lymphatics
“empty spaces” form	Vaguely uniform	Uniform	Variably-shaped
Immunohistochemistry			
S-100	–	+	–
vascular markers	–	–	+

–: usually absent;  $\pm$ : could be rarely present; +: usually present.

findings in colic pseudolipomatosis are white or yellow, flat to slightly elevated plaques, phenomenon described as the “snow white sign.”<sup>1,6</sup> However, these characteristic endoscopic patterns may be absent like in our current patient.<sup>5</sup>

The histopathologic aspect of rectocolic pseudolipomatosis shows typically numerous optically empty spaces resembling adipocytes. These spaces are embedded in the lamina propria and intermingled with inflammatory cells without destruction of glandular structures, and usually the inflammatory cells seem to line the empty spaces suggesting vascular structure or adipocytes.<sup>1,2,4,7</sup> Also, these spaces could have discrete eosinophilic amorphous content.<sup>7</sup> We have found focally empty spaces with these eosinophilic content in our current case. However, many lesions could mimic histologic patterns of pseudolipomatosis, such as mucosal lipoma, intestinal lymphangioma or even sclerolipomatosis found in Crohn’s disease.<sup>1,4,14–16</sup> A simple clinical, endoscopic and histopathologic confrontation would lead to the correct diagnosis. Table 1 summarizes some differential diagnoses of rectocolic pseudolipomatosis. At immunohistochemistry, the empty spaces observed in

pseudolipomatosis are not truly lined by cells expressing adipocytic markers (like S-100 protein) or vascular markers (CD31, CD34, Factor VIII, D2-40).<sup>1,4,6,7</sup> However, care should be taken not to interpret as falsely positive staining the scattered inflammatory cells that could surround empty spaces and be positive for S-100 or CD31.<sup>4,17,18</sup> In our case, scattered lamina propria inflammatory cells show positive staining with S-100 and CD31, and empty spaces are not truly positive as compared with internal controls (vessels or inflammatory cells). Thus, immunohistochemistry easily rules out the diagnosis of lipoma (negativity of S-100) or the diagnosis of lymphangioma (negativity of vascular immunomarkers). Also, pseudolipomatosis is encountered in adults and has endoscopic patterns different from those of colic lipoma or lymphangioma that usually show elevated masses at colonoscopy.<sup>6,15,16,19</sup>

Rectocolic pseudolipomatosis is a benign condition as endoscopic lesions tend to disappear in weeks following initial diagnosis, however, cases associated with pneumatosis intestinalis, subcutaneous and mediastinal emphysema and pneumoperitoneum have been reported.<sup>13,20</sup>

## Conclusion

Rectocolic pseudolipomatosis is a very rare benign condition with misleading and challenging clinicopathologic presentation. Clinicians and pathologists should be aware of this uncommon lesion for correct diagnosis and appropriate clinical management.

## Declaration of conflicting interests

The author(s) declared no potential conflicts of interest with respect to the research, authorship and/or publication of this article.

## Ethical approval

Our institution does not require ethical approval for reporting individual cases or case series.

## Funding

The author(s) received no financial support for the research, authorship and/or publication of this article.

## Informed consent

Written informed consent was obtained from the patient(s) for their anonymized information to be published in this article.

## ORCID iD

Boubacar Efareid  <https://orcid.org/0000-0002-8623-4005>

## References

1. Snover DC, Sandstad J and Hutton S. Mucosal pseudolipomatosis of the colon. *Am J Clin Pathol* 1985; 84(5): 575–580.
2. Ersoz F, Toros AB, Cakar E, et al. Colonic mucosal pseudolipomatosis: are we aware of it. *Ulus Cerrahi Derg* 2016; 32(2): 90–92.
3. Brevet M, Chatelain D, Bartoli E, et al. Colonic pseudolipomatosis: clinical, endoscopic and pathological features in nine cases. *Gastroenterol Clin Biol* 2006; 30(1): 9–13.
4. Caliskan A, Kohlmann WK, Affolter KE, et al. Intramucosal lipomas of the colon implicate Cowden syndrome. *Mod Pathol* 2018; 31(4): 643–651.
5. Kim SJ and Baek IH. Colonic mucosal pseudolipomatosis: disinfectant colitis. *Gastroenterol Nurs* 2012; 35(3): 208–213.
6. Cammarota G, Cesaro P, Cazzato A, et al. Hydrogen peroxide-related colitis (previously known as “pseudolipomatosis”): a series of cases occurring in an epidemic pattern. *Endoscopy* 2007; 39(10): 916–919.
7. Nakasono M, Hirokawa M, Muguruma N, et al. Colonic pseudolipomatosis, microscopically classified into two groups. *J Gastroenterol Hepatol* 2006; 21(1 Pt. 1): 65–70.
8. Alper M, Akcan Y, Belenli OK, et al. Gastric pseudolipomatosis, usual or unusual? Re-evaluation of 909 endoscopic gastric biopsies. *World J Gastroenterol* 2003; 9(12): 2846–2848.
9. Srivastava S, Subramaniam MM, Guan YK, et al. Gastric pseudolipomatosis: biopsy follow-up and immunohistochemical analysis of a rare condition. *Histopathology* 2011; 58(7): 1177–1178.
10. Kim SW and Moon WS. Iatrogenic gastric pseudolipomatosis during endoscopic submucosal dissection. *J Pathol Transl Med* 2017; 51(5): 513–515.
11. Heller A. Pseudolipomatosis in endometrial specimens does not represent uterine perforation. *Int J Surg Pathol* 2017; 25: 56–57.
12. Unger ZM, Gonzalez JL, Hanissian PD, et al. Pseudolipomatosis in hysteroscopically resected tissues from the gynecologic tract: pathologic description and frequency. *Am J Surg Pathol* 2009; 33(8): 1187–1190.
13. Iwamuro M, Tanaka T, Kawabata T, et al. Pseudolipomatosis of the colon and cecum followed by pneumatosis intestinalis. *Intern Med* 2018; 57: 2501–2504.
14. Shelley-Fraser G, Borley NR, Warren BF, et al. The connective tissue changes of Crohn’s disease. *Histopathology* 2012; 60: 1034–1044.
15. Kohga A, Kawabe A, Hasegawa Y, et al. Ileo-ileal intussusception caused by lymphangioma of the small bowel treated by single-incision laparoscopic-assisted ileal resection. *World J Gastroenterol* 2017; 23(1): 167–172.
16. Kim KM, Choi KY, Lee A, et al. Lymphangioma of large intestine: report of ten cases with endoscopic and pathologic correlation. *Gastrointest Endosc* 2000; 52(2): 255–259.
17. Kushner EJ, Weil BR, MacEaney OJ, et al. Human aging and CD31+ T-cell number, migration, apoptotic susceptibility, and telomere length. *J Appl Physiol (1985)* 2010; 109: 1756–1761.
18. McKenney JK, Weiss SW, Folpe AL. CD31 expression in intratumoral macrophages: a potential diagnostic pitfall. *Am J Surg Pathol* 2001; 25: 1167–1173.
19. Hotta K, Imai K and Shimoda T. Lymphangioma of the colon: a curious endoscopic finding. *Clin Gastroenterol Hepatol* 2014; 12(10): A24.
20. Koreishi A, Lauwers GY and Misraji J. Pneumatosis intestinalis: a challenging biopsy diagnosis. *Am J Surg Pathol* 2007; 31(10): 1469–1475.