

Unusual case of traumatic carotid artery dissection occurred during a work-related activity. A case report

CESARE GARBERI¹, ROSSANA RAVIZZA¹, RICCARDO COLOMBO¹, FEDERICA BORROMEO¹, CHIARA ROSSETTI¹, SIMONE CISINI¹, MARCO MOTTA², JUTTA MARIA BIRKHOFF¹

¹ Department of Biotechnology and Life Sciences, University of Insubria, Italy

² Forensic Medicine Unit, Ospedale di Circolo e Fondazione Macchi, Azienda Socio Sanitaria Territoriale dei Sette Laghi, Varese, Italy

KEY WORDS: Traumatic carotid artery dissection; work-related injury; ischemic stroke; ability to work; case report

PAROLE CHIAVE: Dissecazione carotidea traumatica; infortunio lavorativo; ictus; capacità lavorativa; case report

SUMMARY

Carotid artery dissection secondary to cervical blunt trauma is a rare and potentially life-threatening condition that can cause a variety of clinical presentations, including stroke, headache, neck pain, tinnitus, Horner syndrome and cranial neuropathies and is associated with long-term sequelae. We report a case of a 49-year-old industrial vehicles mechanic who was projected to the ground by the explosion of the tire of a heavy truck he was inflating. In the following hours he presented various neurological signs and symptoms and was admitted to the Emergency Department. During hospitalization the patient underwent clinical and instrumental investigations with AngioCT and MR finding of left internal carotid artery dissection in correspondence of its cervical segment and three acute ischemic lesions in the left temporal, parietal and occipital lobes. Medical management was successful and the patient was discharged from the hospital three weeks after the admission but he wasn't able to get back to work due to neurological sequelae. This case report illustrates that traumatic carotid artery dissection, although rare, should be considered in patients who present neurological symptoms after an explosion, can meet the criteria for a work-related injury and may lead to a permanent decrease in the ability to work.

RIASSUNTO

«Un singolare caso di dissecazione carotidea traumatica verificatasi in occasione di lavoro». La dissecazione carotidea secondaria ad un traumatismo contusivo cervicale è una condizione rara e potenzialmente mortale che può manifestarsi con svariate presentazioni cliniche tra cui ictus, cefalea, dolore cervicale, acufeni, sindrome di Horner e neuropatie dei nervi cranici ed è associata a postumi permanenti. Presentiamo il caso di un meccanico autoriparatore di veicoli industriali di 49 anni proiettato al suolo dall'esplosione dello pneumatico di un mezzo pesante che era intento a gonfiare. Nelle ore successive presentò una sintomatologia neurologica per la quale fu ricoverato presso il Pronto Soccorso. Durante l'ospedalizzazione il paziente venne sottoposto ad indagini cliniche e strumentali con riscontro all'angio-TC ed alla risonanza magnetica di dissecazione della carotide interna sinistra in corrispondenza del tratto cervicale e di tre tre focalità ischemiche acute in sede temporale, parietale ed occipitale sinistra. Il paziente fu trattato con successo con terapia medica e venne dimesso a distanza di tre settimane dall'accesso in Ospedale, ma non fu più in grado di ritornare al suo lavoro a causa dei postumi neurologici. Questo case report illustra che la dissecazione carotidea traumatica, sebbene rara, dovrebbe essere presa in considerazione in caso di pazienti che presentano sintomatologia neurologica in seguito ad un'esplosione, può soddisfare i criteri necessari per essere classificata come infortunio lavorativo e può portare ad una riduzione permanente della capacità lavorativa.

Pervenuto il 28.8.2018 - Accettato il 24.9.2018

Corrispondenza: Rossana Ravizza, Department of Biotechnology and Life Sciences, University of Insubria, via O. Rossi 9, 21100 Varese, Italy - Tel. +39 0332217510 - Fax +39 0332397509 - E-mail: rossana.ravizza@yahoo.it

INTRODUCTION

Traumatic carotid artery dissection (CAD) is a rare and potentially life-threatening condition that occurs in approximately 1% of all patients with blunt injury mechanisms (6) and is an important cause of ischemic stroke among young adults, accounting for 25% of ischemic stroke cases in patients younger than 45 (1).

Trauma mechanisms involved range from high speed motor vehicle accidents to trivial traumas in predisposed patients (for example patients with hypertension or connective tissue diseases). Distraction/extension, distraction/flexion or lateral flexion forces of the cervical spine may result in traumatic CADs as well (5).

Other clinical presentations include headache, neck pain, tinnitus, Horner syndrome and cranial neuropathies (1, 4, 2), and timing of ischemic signs onset is very variable: only 10% of cases present immediate symptoms although most clinical signs usually occur within the first 24 hours of the occurrence of the trauma (5).

With medical treatment, regression of the dissection and disappearance of the mural haematoma is observed in over 80% of cases at radiological follow-up but neurological sequelae and various degrees of residual stenosis may occur (1).

CASE REPORT

A 49-year-old industrial vehicles mechanic was inflating the tire of a heavy truck with the help of a colleague when the tire exploded and the two men were projected to the ground. The precise dynamic

of the accident was recorded by the video surveillance system of the garage (figure 1).

The 49-year-old man immediately began to suffer from left tinnitus and oppressive headache that partially regressed with symptomatic therapy.

The following morning, while he was working, he presented aphasia, left eyelid twitch, tremors and uncontrolled movements of the left limbs and was initially admitted to the Emergency Department.

Neurological exam assessed a subjective mild hypoesthesia in the left trigeminal territory and the patient underwent laboratory tests and instrumental investigation.

Computed Tomography (CT) Angiography of the head and supra-aortic arteries showed a kinking of the left internal carotid artery and a contextual soft thickening of the vascular wall causing a 50% luminal stenosis in correspondence of its cervical segment. This finding was suggestive of an atheromatous plaque or a focal dissection, and Magnetic Resonance Imaging (MRI) was requested by the radiologist for the differential diagnosis.

MRI of head and soft tissues of the neck (figure 2) detected three acute ischemic lesions in the left temporal, parietal and occipital lobes, as well as a signal hyperintensity of the left internal carotid wall in correspondence of the kinking with luminal stenosis shown by the CT angiography due to methaemoglobin products that at first was assumed to be related to a mural hematoma or less probably to an intraplaque hemorrhage.

An echocolor Doppler study of the carotid artery was also performed but didn't show any morphological changes consistent with a dissection in the examined segment of the vessel.



Figure 1 - Screenshots captured from the video surveillance system recording of the garage. The circled man is directly hit by the explosion, with a resulting cervical hyperextension causing a left internal carotid artery dissection; his colleague falls to the ground, suffering minor injuries to a hand

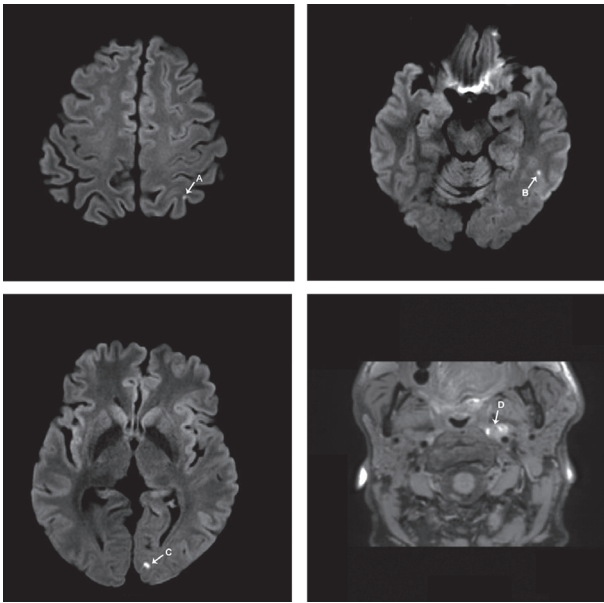


Figure 2 -MRI of head and soft tissues of the neck performed the day after the traumatic event. The arrows show ischemic lesions in the left temporal (A), parietal (B) and occipital lobes (C) and a signal hyperintensity of the left internal carotid wall (D)

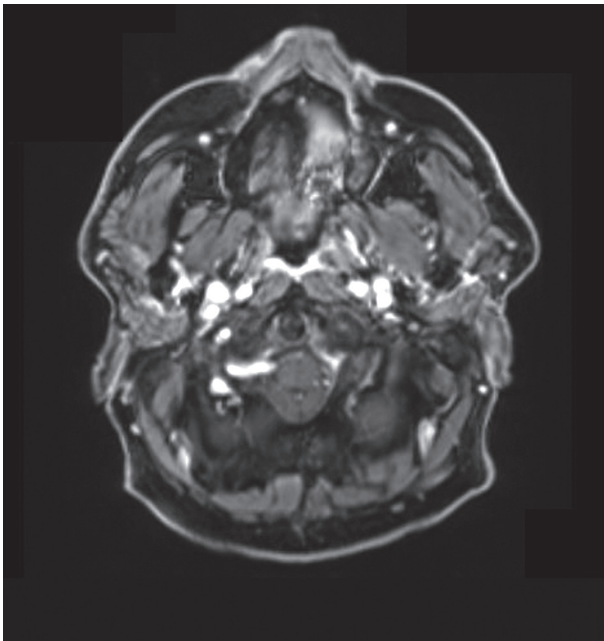


Figure 3 - MR angiography of the supra-aortic arteries (T-1 weighted scans) performed five months after the accident showing the disappearance of the focal stenosis and a marked hyperintensity reduction of the left internal carotid wall in correspondence of the kinking

Therefore the man was diagnosed with arterial ischemic stroke in the middle cerebral artery vascular territory consequent to traumatic left internal carotid artery dissection without surgical indications and transferred to a Stroke Center.

Medical management was successful and the patient, who was judged clinically improved but with a complete inability to work, was discharged from the hospital three weeks after admission.

Five months after the accident MRI of the head and MR angiography of the supra-aortic arteries showed a better visualization of the flow-related signal in correspondence of the cervical segment of the left internal carotid artery, a marked vascular wall hyperintensity reduction in T1-weighted scans in correspondence of the kinking and the disappearance of the focal stenosis (figure 3).

The forensic medical examination performed six months after the work-related injury revealed the persistence of a significant bilateral contracture of the sternocleidomastoid muscle, more marked on the left, and an homolateral contracture of the trapezius, painful neck movements, neck rotation possible only with a contemporary torso rotation, left arm and leg strength deficit, slight uncertainty in coordination tests and asymmetrical squat test (greater loading of the right leg). The examinee also alleged hypoesthesia of the left hand (back of the carpus, first and fourth finger) and paresthesia of lower limbs refractory to medical treatments.

The biological damage caused by these disabling sequelae was judged equal to 15% and led to a permanent decrease in the ability to work. Work reintegration was possible only after appropriate retraining in a different employment field.

CONCLUSIONS

We reported a rare case of traumatic internal carotid artery dissection as a consequence of a truck tire explosion.

The site of injury, the production mechanism, the timing of ischemic signs onset and the evolution of clinical manifestations make the injury consistent with the explosion occurred while the mechanic was inflating the tire.

Moreover, the internal carotid artery dissection

was caused by a violent and unexpected external event that occurred in the work environment while the employee was performing a work-related activity and led to a temporary complete inability to work for more than three days and to a permanent decrease in the ability to work and therefore it meets the requirements for being defined a work-related injury according to Italian law (3).

Due to the long-term sequelae, the man was no longer able to lift weights, use medium-heavy tools, perform works that require an extension of the cervical spine, drive industrial vehicles nor climb ladders, and since working as a mechanic requires manual handling of loads with lifting of the arms overhead and forced postures with neck hyperextension, these long-term sequelae caused also an important decrease in the specific ability to work estimated at approximately 40%.

Finally, this case report highlights the importance of appropriate retraining in a different employment field when the disabling sequelae of a traumatic

event prevent the patient to return to his previous job.

NO POTENTIAL CONFLICT OF INTEREST RELEVANT TO THIS ARTICLE WAS REPORTED BY THE AUTHORS

REFERENCES

1. Ben Hassen W, Machet A, Edjlali-Goujon M, et al: Imaging of cervical artery dissection. *Diagn Interv Imaging* 2014; 95: 1151-1161
2. Caplan LR: Dissections of brain-supplying arteries. *Nat Clin Pract Neurol* 2008; 4: 34-42
3. D.P.R. 30 giugno 1965, n. 1124: Testo unico sull'assicurazione degli infortuni sul lavoro, art. 2
4. Flis CM, Jager HR, Sidhu PS: Carotid and vertebral artery dissections: clinical aspects, imaging features and endovascular treatment. *Eur Radiol* 2007; 17: 820-834
5. Galyfos G, Filis K, Sigala F, et al: Traumatic Carotid Artery Dissection: A Different Entity without Specific Guidelines. *Vasc Specialist Int* 2016; 31: 1-5
6. Redekop GJ: Extracranial carotid and vertebral artery dissection: a review. *Can J Neurol Sci* 2008; 35: 146-152