

Confirmation of the pathogenicity of a mutation p.G337C in the COL1A2 gene associated with osteogenesis imperfecta

Mingrui Jia, PhD^a, Ranran Shi, MS^b, Xuli Zhao, PhD^a, Zhijian Fu, PhD^a, Zhijing Bai, MS^c, Tao Sun, PhD^a, Xuejun Zhao, MS^a, Wenbo Wang, MS^{d,e,f}, Chao Xu, MD^{d,e,f,*}, Fang Yan, MD^{a,*}

Abstract

Mutation analysis as the gold standard is particularly important in diagnosis of osteogenesis imperfecta (OI) and it may be preventable upon early diagnosis. In this study, we aimed to analyze the clinical and genetic materials of an OI pedigree as well as to confirm the deleterious property of the mutation.

A pedigree with OI was identified. All family members received careful clinical examinations and blood was drawn for genetic analyses. Genes implicated in OI were screened for mutation. The function and structure of the mutant protein were predicted using bioinformatics analysis.

The proband, a 9-month fetus, showed abnormal sonographic images. Disproportionately short and triangular face with blue sclera was noticed at birth. She can barely walk and suffered multiple fractures till 2-year old. Her mother appeared small stature, frequent fractures, blue sclera, and deformity of extremities. A heterozygous missense mutation c.1009G>T (p.G337C) in the COL1A2 gene was identified in her mother and her. Bioinformatics analysis showed p.G337 was well-conserved among multiple species and the mutation probably changed the structure and damaged the function of collagen.

We suggest that the mutation p.G337C in the COL1A2 gene is pathogenic for OI by affecting the protein structure and the function of collagen.

Abbreviations: COL1A1 = collagen type I alpha 1 chain, COL1A2 = collagen type I alpha 2 chain, DNA = deoxyribonucleic acid, HGMD = The Human Gene Mutation Database, NCBI = National Center for Biotechnology Information, OI = osteogenesis imperfecta, PCR = polymerase chain reaction.

Keywords: bioinformatics analysis, COL1A2 gene, mutation analysis, osteogenesis imperfecta, prenatal diagnosis

Editor: Cristina Oana Marginean.

Authorship: FY and CX conceived of and supervised the project, CX revised the manuscript content. MJ, ZF, and RS collected and analyzed the data; WW and ZB drafted the manuscript. XZ, TS, and XZ took responsibility for the integrity of the data analysis. All the authors have read and approved the final submitted version.

Funding: This work was supported by grants from the National Natural Science Foundation (81370891, 81500608, and 81670720), special funds for Taishan Scholar Project (tsqn20161071), and the Natural Science Foundation of Shandong Province (ZR2015HQ003).

The authors have no conflicts of interest to disclose.

^a Department of Pain Management, ^b Department of Pediatrics, Jinan, ^c Linyi County Traditional Chinese Medicine Hospital, Dezhou, ^d Department of Endocrinology and Metabolism, Shandong Provincial Hospital Affiliated to Shandong University, ^e Institute of Endocrinology, Shandong Academy of Clinical Medicine, ^f Shandong Clinical Medical Center of Endocrinology and Metabolism, Jinan, Shandong, China.

* Correspondence: Fang Yan, Shandong Provincial Hospital Affiliated to Shandong University, Jinan, Shandong, China (e-mail: yanfang19851234@163.com); Chao Xu, Shandong Provincial Hospital Affiliated to Shandong University, Institute of Endocrinology, Shandong Academy of Clinical Medicine, Shandong Clinical Medical Center of Endocrinology and Metabolism, Jinan, Shandong, China (e-mail: doctorxuchao@163.com).

Copyright © 2017 the Author(s). Published by Wolters Kluwer Health, Inc. This is an open access article distributed under the Creative Commons Attribution-NoDerivatives License 4.0, which allows for redistribution, commercial and non-commercial, as long as it is passed along unchanged and in whole, with credit to the author.

Medicine (2017) 96:39(e7783)

Received: 1 May 2017 / Received in final form: 11 July 2017 / Accepted: 17 July 2017

<http://dx.doi.org/10.1097/MD.0000000000007783>

1. Introduction

Osteogenesis imperfecta (OI), commonly known as “brittle bone disease,” is a worldwide hereditary metabolic bone disorder, whose incidence ranges from 1 in 15 to 20,000 births, occurring equally in sex and race.^[1] Currently, there are no effective therapies for the affected individuals.^[2,3] Thus, the genetic diagnostic technique may be important for providing families with accurate information and appropriate counseling regarding the health of the fetus.^[4,5]

OI is clinically and genetically heterogeneous characterized by bone fragility, with the clinical manifestations of reduced bone mass, frequent fractures, blue sclerae, dentinogenesis imperfect, hearing and sight impediments, muscle weakness, and joint laxity.^[6] Their phenotypic presentation varies from mild to lethal.^[7,8] About 90% of the OI patients have autosomal dominant mutations in the COL1A1 gene (OMIM 120150) encoding $\alpha 1$ type 1 collagen chain and in the COL1A2 gene (OMIM 120160) encoding $\alpha 2$ type 1 collagen chain.^[9] Recent studies have also identified autosomal recessive OI, which are induced by defects in at least 17 genes other than COL1A1 and COL1A2.^[10–13]

To date, various studies described genotype-phenotype correlations for missense mutations in both COL1A1 and COL1A2 genes which have been submitted to the University of Leicester’s (Leicester, UK) database (<http://www.le.ac.uk/genetics/collagen/>) highlighting mutations of the collagen gene.^[9,14] Despite better advance in our understanding of the genetics of OI over the last few years, the gene mutations described thus far only

account for approximately 70% of cases, and the search continues for the genes responsible for the remaining cases.^[15]

In the present study, we identified an OI pedigree even when the proband was a 9-month fetus. Her parents were told that their daughter might have the possibility of congenital diseases, but they insisted on having the baby. After her birth, we performed a molecular genetic analysis and a missense mutation c.1009G>T in the *COL1A2* gene was found. Subsequently, we performed bioinformatics analysis to verify the damaging property of this mutation, which will provide further insight into genetic basis of OI. Moreover, a continuous follow-up was performed to accumulate valuable data to further illustrate the complexity and better understand the genotype-phenotype correlations for OI and related connective tissue disorders.

2. Subjects and methods

2.1. Subjects

The research protocol was approved by the institutional review board of Shandong Provincial Hospital Affiliated to Shandong University and written informed consent was signed by the family members; the consent document from the baby was signed by her parents.

The proband was a 9-month female fetus. Her mother was admitted to our hospital (Shandong Provincial Hospital Affiliated to Shandong University, China) for pregnancy examination in April, 2015. The B-type ultrasonic signs indicated that the fetus might suffer from a kind of structural anomalies. Also, the features of her mother (nanism, scoliosis, cripple) drew our attention and continuous follow-up. All family members received careful clinical examinations and blood was drawn for genetic analyses (Fig. 1).

2.2. DNA extraction and amplification

Genomic deoxyribonucleic acid (DNA) kit (QIAamp Blood DNA Mini Kit, Qiagen) was used for extracting DNA from peripheral

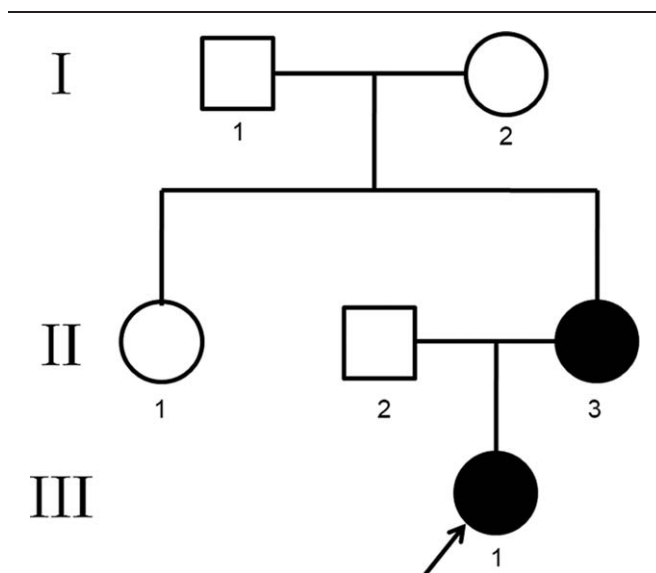


Figure 1. A Chinese pedigree with osteogenesis imperfecta. The proband is indicated by an arrow. The full black symbol indicates the patient with OI and white symbols represent unaffected individuals in the family. OI = osteogenesis imperfecta.

blood cells of the subjects. Primers referred in the previous study were used for amplifying the complete coding region and intron-exon boundaries of OI-related genes, including *COL1A1/2*, *BMP1*, and so on.^[16] The amplification was performed in an ABI9700 Polymerase Chain Reaction(PCR) amplifier (Life Technology).

2.3. Mutation analysis

The whole exons and flanking regions were directly sequenced by a dye terminator cycle-sequencing system on an ABI 3700 DNA sequencer (Life technology). The sequence results were compared with the wild-type sequence of corresponding genes by the AutoAssembler software (version 20; Perkin Elmer, Foster City, CA). Nucleotide number refers to the cDNA position and it is numbered from the first base of the start codon. The mutation was named using the recommendations of the Nomenclature Working Group, in which the cDNA and protein sequence positions were designed by the prefixes c. and p. respectively. When sequence variant in the proband was detected, the exon of other family members and 100 unrelated healthy individuals were screened to determine the inheritance and polymorphism.

2.4. Bioinformatics analysis

To analyze the sequence conservation of *COL1A2*, the multiple alignments of the *COL1A2* peptide sequences were performed using the ClustalW (version 2.0.10) program, and the sequences of the different species were obtained from the NCBI database. In order to explore the pathogenicity of the mutation, prediction was performed by PolyPhen-2 (<http://genetics.bwh.harvard.edu/pph/>) and SIFT (<http://sift.bii.a-star.edu.sg/>) software. The structure prediction is conducted by the Swiss Model (<https://swissmodel.expasy.org/>).

3. Results

3.1. Subjects

The proband showed abnormal sonographic images when she is a 9-month fetus: shortening, angulation, and a crumpled appearance of the long bones, tarda, and a crumpled appearance of the long bones, tarda, and transverse position. The measurements of the humerus, femur, tibia, and ulna were 5.1, 5.3, 5.5, and 4.9 cm, respectively, and all were less than the 5th centile for 36 weeks (Fig. 2A–D). The fetus had a narrowed thorax with short ribs (Fig. 2E and F); well-defined brain structure (Fig. 2G) and a calvarial deformation and ossification evidenced by easy skull compression with an ultrasound probe (Fig. 2H). The fetal biparietal diameter is 8.7 cm (45th centile).

The proband was delivered by caesarian at 36+6 weeks of gestation, with a birth weight of 2330 g (below the 3rd centile) and a body length of 42 cm (below the 3rd centile). The female baby was delivered with Apgar scores of 10 and 10 at 1 minute and 5 minutes, respectively. Physical findings included disproportionately short, bent limbs, a hypoplastic thorax, relative macrocephaly with caput membraneaceum, and triangular face with hypertelorism, protruding eyes, and blue sclerae.

Remarkably, the proband's mother showed a short habitus (130 cm, below the 3rd centile, far below the average height of Chinese women, Fig. 3A). There was extreme shortening and bowing of all 4 extremities and her left lower extremity is shorter than the right one. Scoliosis and bowing of legs were seen. She had a triangular face and blue sclera (Fig. 3B and C). Her skin was loose and thin. No clinical signs of hearing impairment,

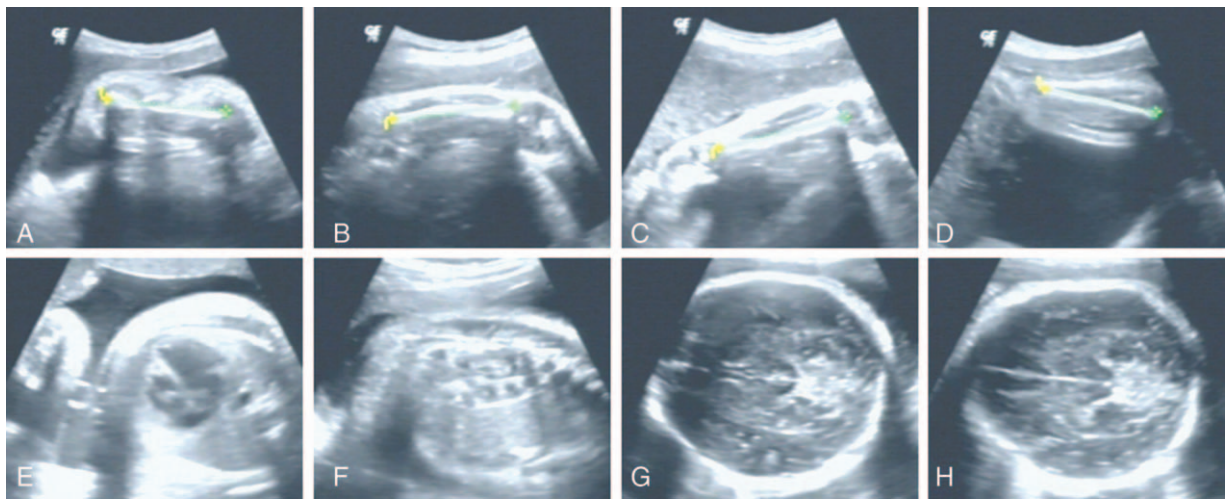


Figure 2. Prenatal ultrasonography at 36 weeks of the affected fetus. (A) Humerus with thin cortex, (B) curved femur, (C) tibia and (D) ulna with hypomineralization, (E and F) a narrowed thorax, (G) too-well-seen brain structure, the shape of the calvaria was easily changed before and (H) after the compression.

ophthalmological problems, cardiac murmur, respiratory difficulty, neurologic problems, or dentinogenesis imperfect were observed. Her intellectual development was normal. She suffered a low trauma fracture of the femur aged 5 leading to an abnormal gait due to unequal leg length. Since then she had multiple fractures of various bones including humeri, femora, tibiae, ulnae, and radii resulted from minor trauma, twisting injuries, falls, and collisions that occurred during typical childhood daily activities and play. However, she has not experienced any

fracture for 15 years, up to the age of 27 years. She did not receive pamidronate therapy. There was no family history of OI or other bone disorders.

After birth, conventional laboratory examinations were conducted for the proband. Investigations revealed decreased serum calcium and elevated alkaline phosphatase levels. The levels of hemoglobin, hematocrit, and mean corpuscular volume were reduced. Serum albumin and creatinine were below normal values, indicating that she was malnourished. Serum bone

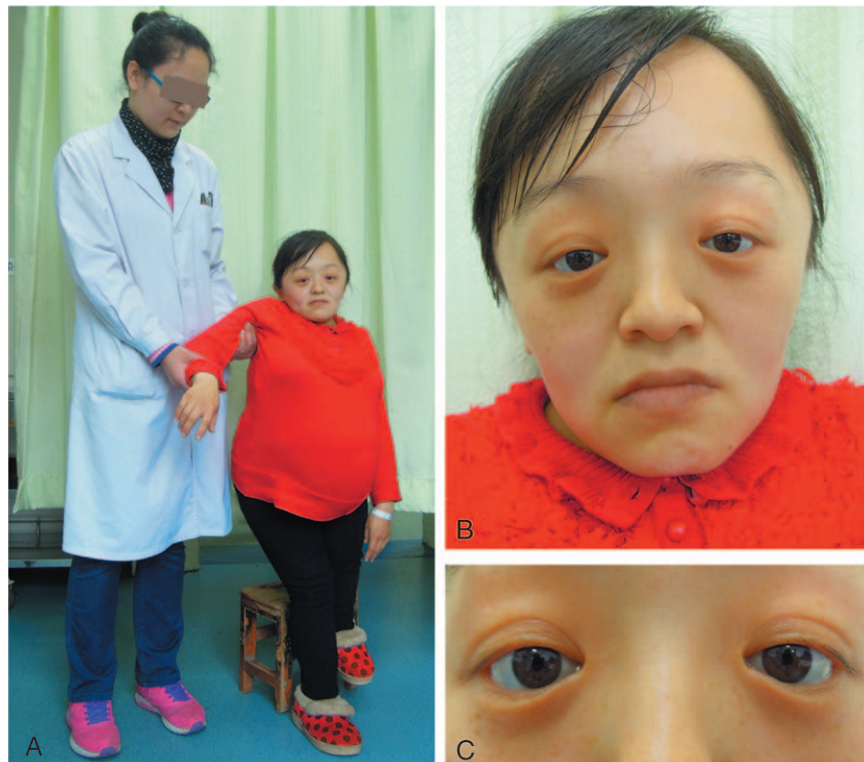

Figure 3. Clinical features of the proband's mother when she was 27 years old. (A) Short and unequal length of the patient's malformed legs, (B) facial features showing broad forehead, eyes wide apart, bilateral low-set ears, proptosis and progeric appearance, and (C) photograph of the eyes, showing typical blue sclerae.

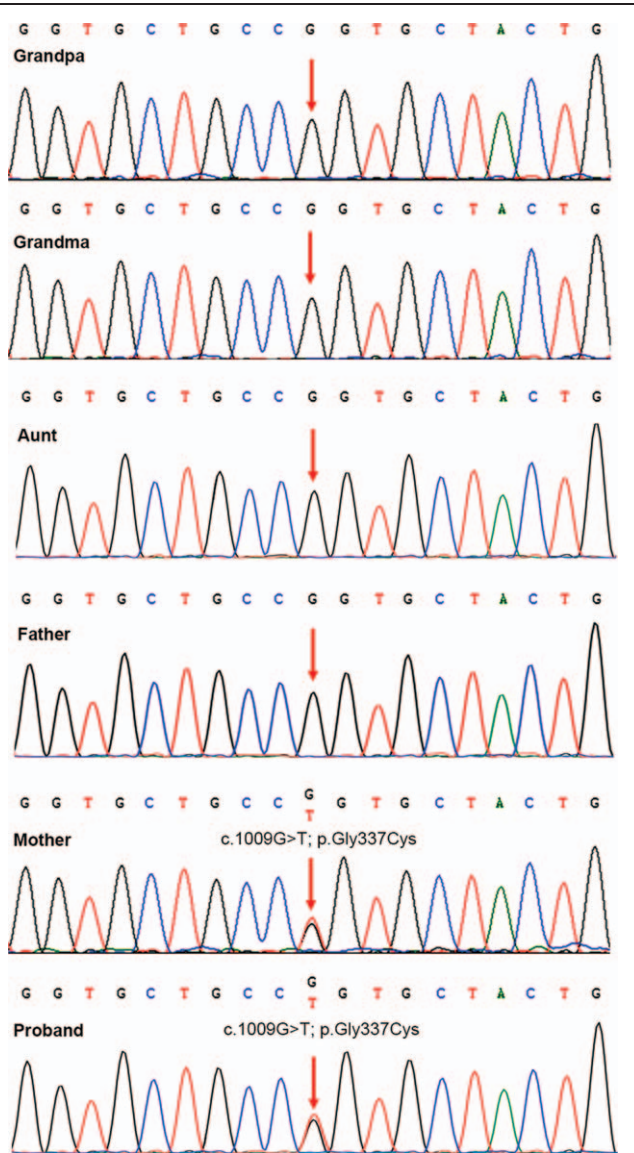


Figure 4. Sequence analysis of *COL1A2* exon 19. The nucleotide sequence of the patient and her family members were shown, respectively. The patient and her mother had a heterozygous G→T mutation at nucleotide 1009 in exon 19 (c.1009G>T), resulting in the substitution of glycine with cysteine acid at codon 337 (p.G337C). *COL1A2* = collagen type I alpha 2 chain.

metabolism markers, including parathyroid hormone, 25-hydroxy vitamin D, and 1,25-dihydroxycholecalciferol, were within normal limits. Plain radiographs of her long bones and dual-energy x-ray absorptiometry scans have not been performed yet due to ethical reasons.

The patients were diagnosed as OI type III according to her mother and her clinical characters including small stature, frequent fractures, blue sclera, and deformity of extremities.

3.2. Mutation analysis

Blood samples of the family were drawn for mutation analyses. We identified a missense mutation, G>T at nucleotide 1009 in exon 19 of the *COL1A2* gene, which lead to a predicted amino acid substitution from Gly to Cys at codon 337 of the proband in a heterozygote state. Her mother was positive for the same

variant (Fig. 4). The negative results of screening 100 controls ruled out the possibility of polymorphism. The Human Gene Mutation Database (HGMD, <http://www.hgmd.cf.ac.uk/ac/all.php>) had the record of this variant; however, the reference^[9] listed in the database is wrong. Therefore, the source of this variant is still uncertain. We also sequenced 9 other genes implicated in OI, including *COL1A1*, *CRTAP*, *LEPRE1*, *PPIB*, *SERPINH1*, *FKBP10*, *SERPINF1*, *SP7*, and *BMP1*.^[15] No causal variant was identified.

The proband's father, maternal aunt, and maternal grandparents showed no significant abnormality or mutations.

3.3. Bioinformatics analysis

According to sequencing alignment, the mutated amino acid (Gly) is well-conserved among multiple species (Fig. 5A). In addition, the PolyPhen-2 score was 1.00 and showed that the mutation was strongly predicted to be pathogenic (Fig. 5B). The result of SIFT was 0.00, indicating that the mutation may affect the protein function.

The alpha chains of collagen type I contain a glycine residue at every third position of their triple-helical domains. Glycine residues are essential for the alpha chains to intertwine correctly and for the assembly of collagen fibrils. The mutation is just located in the heterotrimer region of *COL1A2* protein, which is significant for collagen cross-linking structurally. G337C was also predicted to alter the protein tridimensional structure by the Swiss model program (Fig. 5C). A pliable loop (wild type) was changed to a tie (mutant type) which inevitably generated steric hindrance leading to the destabilization of the triple helical domain.

3.4. Follow-up

The patient was able to sit up at 7 months, speak at 12 months, and still could not walk till the last time of follow-up (2017-04-12). Intelligence was satisfactory, and motor development was normal. Physical examination indicated short stature and low weight (70 cm and 10 kg, respectively, both below the 3rd centile), triangular face with blue sclera (Fig. 6A–C).

The patient first came back to the hospital at 11 months of age (2015-03-14) due to a spontaneous fracture in the proximal part of right femur (Fig. 6D). The fracture in the right femur was in a healing state 2 months later; however, a new proximal femur fracture occurred in the left. X-ray examination also revealed severe osteoporosis, slender long bone with thin cortices (Fig. 6E). Because of the severe skeletal symptoms, treatment with intravenous pamidronate was started at the age of 13 months. The patient experienced the third fracture after a fall before the most recent follow-up, when she was 2 years old and an orthopedic surgical procedure had to be made to fix the femur (Fig. 6F).

Investigations revealed normal serum calcium, phosphorus, parathyroid hormone, 25-hydroxy vitamin D and 1,25-dihydroxycholecalciferol levels, and elevated alkaline phosphatase level.

4. Discussion

In the present study, we reported a missense mutation c.1009G>T of *COL1A2* gene in a Chinese pedigree with OI. The mutation is located in the heterotrimer region of *COL1A2* protein and the mutant amino acid (G337) is well-conserved

<i>H.sapiens</i>	293	PVGPPGNPGANL	TGAKGAAGLPGVAGAPGLPGPRGIPGPVGAAGATGAR	342
<i>P.troglodytes</i>	293	PVGPPGNPGANL	TGAKGAAGLPGVAGAPGLPGPRGIPGPVGAAGATGAR	342
<i>M.mulatta</i>	293	PVGPPGNPGANL	TGAKGAAGLPGVAGAPGLPGPRGIPGPVGAAGATGAR	342
<i>C.lupus</i>	293	PVGPPGNPGANL	TGAKGAAGLPGVAGAPGLPGPRGIPGPVGAAGATGAR	342
<i>B.taurus</i>	291	PVGPPGNPGANL	PGAKGAAGLPGVAGAPGLPGPRGIPGPVGAAGATGAR	340
<i>M.musculus</i>	299	PVGPPGNPGT	NLTGAKGATGLPGVAGAPGLPGPRGIPGPVGAAGATGAR	348
<i>R.norvegicus</i>	299	PVGPPGNPGANL	TGAKGATGLPGVAGAPGLPGPRGIPGPVGAAGATGPR	348
<i>G.gallus</i>	292	PVGPPGNPGANL	PGAKGAAGLPGVAGAPGLPGPRGIPGPPGPPGPPSGAR	341
<i>D.ferio</i>	283	PVGPPGNPGAN	GINGAKGAAGLPGIAGAPGPPGPRGGPPGPPGPPSGASGPR	332
A. <i>X.tropicalis</i>	284	PVGPAGNPGAN	VNGAKGAAGLPGVGGAPGLPGPRGIPGPPGPPSGPAGAR	333

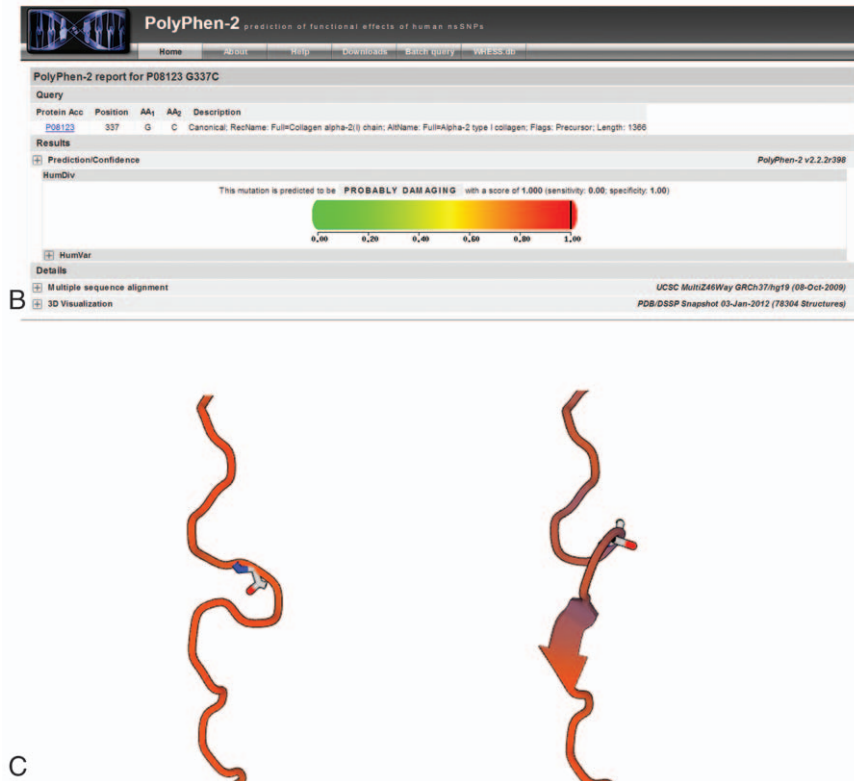


Figure 5. Bioinformatics analysis of COL1A2 protein. (A) Cutout from the alignment of COL1A2 protein of diverse vertebrate species using the ClustalW program. Numbers indicated the respective amino acid position. (B) The prediction of the mutation effect by the PolyPhen software program showing a damaging effect of the p.G337C mutation (score: 1.000 with a prediction: probably damaging). (C) 3D-structure of COL1A2 (321-359aa) predicted by the Swiss model program. Left: wild-type COL1A2; right: p.G337C mutant COL1A2. COL1A2 = collagen type I alpha 2 chain.

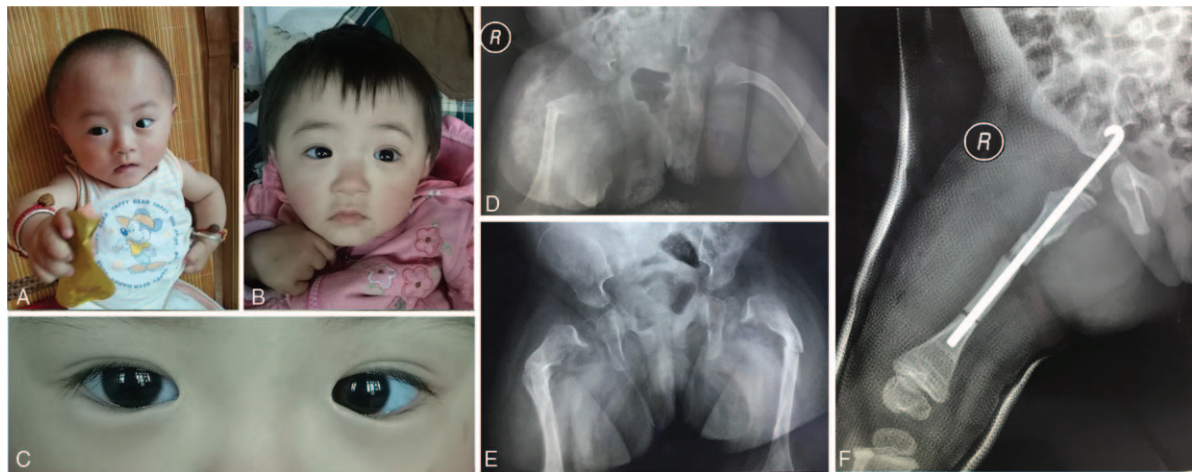


Figure 6. Clinical phenotypes of the proband. Facial features of age 1 (A) and 2 (B) years old showing broad forehead, a triangular face, and blue sclera (C); x-ray images from the patient; (D) femur radiogram taken at the age of 11 months showed a fracture of the proximal part in the right femur. The other limb showed curved femur, slender bones, and osteopenia; (E) radiogram of lower extremities taken at the age of 13 months showed healing state of the fracture of the proximal part in the right femur; (F) right femur radiogram taken at the age of 24 months showed multiple fractures of the right femur, and intramedullary rods were used to stabilize the fractures.

among multiple species. We also predicted the deleterious property of the mutation on structure and function on collagen. Our findings are beneficial for expanding the spectrum of mutations and further understanding genotype–phenotype relationship, which will help prenatal analysis and genetic counseling, as well as provide new insight into the function of the *COL1A2* gene.

This variant (p.G337C) have been reported before according to the record of HGMD.^[9,18] Based on previous and our findings, we can conclude that the substitution may be causative for the type III OI phenotype. First, patients carrying this variant showed representative clinical signs of OI, including small stature, frequent fractures, blue sclera, and deformity of extremities. Second, the important role of Gly in protein spatial structure suggested that it is indispensable in the conformation of collagen. We demonstrated that the position (G337) is quite conserved among multiple species and the mutation could destroy the structure of the protein. Third, the prediction of the effect of the G337 mutation by PolyPhen and SIFT software programs showed a consistent deleterious result. In addition, we did not find this variant in 100 controls and no other sequence change was identified in other OI relevant genes in the present pedigree.

There are some other mutations reported in the position (G337)^[9,17] or the adjacent position, such as G331,^[9,18] G334,^[9] and G340,^[9] which are all involved the amino acid glycine. The basic structural unit of a collagen molecule is a triple helix, which is composed of 3 polypeptide chains twisted around each other.^[19] Glycine occurs at every third position in the amino acid sequence which occupies the crowded center of the triple helix as it has a small side chain. Therefore, the substitution of glycine to other residues in the triple helical domain is the most common type of pathogenic mutation. The size of other amino acid will probably affect the correct formation of collagen, permit prolonged access of modifying enzymes, and decrease the thermal stability of the protein.^[9,20]

Up to now, a clear genotype-phenotype relationship is not definitive as a result of the complex pathogenic mechanism. In general, phenotypes resulting from mutations in *COL1A2* are milder than those resulting from mutations in *COL1A1*.^[9,21] There are more nonlethal regions in *COL1A2* than *COL1A1* (more than 80%, compared to 64.4%). According to the regional model, lethal substitutions in *COL1A2* are ranged as 8 regularly spaced clusters along the heterotrimer chain. Those lethal regions are concordant with proteoglycan binding sites along the fibril, indicating its role in fibril–matrix interactions.^[9] The mutation G337C in this study is located in the first lethal region, which is from 319–364 residues. However, the proband and her mother were diagnosed as type III OI (the severe one), which is an exception of this model. The phenotypes involved G337 substitutions are as follows: G337C and G337P with type III OI (1 case); G337R with type III/IV; and G337S with type I (3 cases), III (1 case), and IV (9 cases).

Studies showed that mutations in the triple-helical domain may affect multiple processes of producing type I collagen, including chain synthesis, helix folding, transiting from the rough endoplasmic reticulum via the Golgi into the extracellular space, procollagen processing, and fibril assembling, and mineralization in bone.^[22,23] Thus, some other factors, such as the interaction between fibril and extracellular proteins, may result in this phenotype exception.^[24,25]

In our study, the proband's mother obtained the *de novo* pathogenic variant of *COL1A2* gene, since her maternal parents showed no significant abnormality or mutations. DNA may be

modified, either naturally or artificially, by a number of physical, chemical, and biological agents, resulting in mutations. Except for catching a cold and fevered for 1 week, the proband's maternal mother recalled no other history of exposing to environmental mutagens such as ionizing radiations, poison, and so on during pregnancy. Mutagenesis may also occur endogenously such as through error in replication and repair of *COL1A2* gene.

The limitation of this study is that we did not perform extensive examinations on the pedigree, such as x-ray, biopsy, hearing examination, and so on. In addition, a transfection study *in vivo* is not available in the present study, which is useful in the further study of the disease mechanism.

In conclusion, mutation analysis as the gold standard is particularly important in diagnosis of OI and maybe preventable if it is diagnosed early. Women with OI who have significant skeletal deformity and short stature should be followed during pregnancy. In this study, we not only reported a Chinese pedigree with type III OI, confirmed by mutation p.G337C in *COL1A2*, but also predicted this mutation to be pathogenic using bioinformatics analysis. Our study may provide further insights into the function of *COL1A2* and help clinicians better understand OI.

Author Contributions: Fang Yan and Chao Xu conceived of and supervised the project, Chao Xu revised the manuscript content. Mingrui Jia, Zhijian Fu and Ranran Shi collected and analyzed the data, Wenbo Wang and Zhijing Bai drafted the manuscript. Xuejun Zhao, Tao Sun and Xuli Zhao took responsibility for the integrity of the data analysis. All the authors have read and approved the final submitted version.

Acknowledgments

The authors thank the families for their cooperation.

Reference

- [1] Kang H, Aryal ACS, Marini JC. Osteogenesis imperfecta: new genes reveal novel mechanisms in bone dysplasia. *Transl Res* 2016;181:27–48.
- [2] Monti E, Mottes M, Fraschini P, et al. Current and emerging treatments for the management of osteogenesis imperfecta. *Ther Clin Risk Manag* 2010;6:367–81.
- [3] Prockop DJ. Targeting gene therapy for osteogenesis imperfecta. *N Engl J Med* 2004;350:2302–4.
- [4] Harrington J, Sochett E, Howard A. Update on the evaluation and treatment of osteogenesis imperfecta. *Pediatr Clin North Am* 2014;61:1243–57.
- [5] Rauch F, Glorieux FH. Osteogenesis imperfecta. *Lancet* 2004;363:1377–85.
- [6] Silience DO, Senn A, Danks DM. Genetic heterogeneity in osteogenesis imperfecta. *J Med Genet* 1979;16:101–16.
- [7] Morello R, Bertin TK, Chen Y, et al. CRTAP is required for prolyl 3-hydroxylation and mutations cause recessive osteogenesis imperfecta. *Cell* 2006;127:291–304.
- [8] van Dijk FS, Nesbitt IM, Zwikstra EH, et al. PPIB mutations cause severe osteogenesis imperfecta. *Am J Hum Genet* 2009;85:521–7.
- [9] Marini JC, Forlino A, Cabral WA, et al. Consortium for osteogenesis imperfecta mutations in the helical domain of type I collagen: regions rich in lethal mutations align with collagen binding sites for integrins and proteoglycans. *Hum Mutat* 2007;28:209–21.
- [10] Forlino A, Marini JC. Osteogenesis imperfecta. *Lancet* 2016;387:1657–71.
- [11] Shapiro JR, Lietman C, Grover M, et al. Phenotypic variability of osteogenesis imperfecta type V caused by an IFITM5 mutation. *J Bone Miner Res* 2013;28:1523–30.
- [12] Glorieux FH, Rauch F, Plotkin H, et al. Type V osteogenesis imperfecta: a new form of brittle bone disease. *J Bone Miner Res* 2000;15:1650–8.

- [13] Volodarsky M, Markus B, Cohen I, et al. A deletion mutation in TMEM38B associated with autosomal recessive osteogenesis imperfecta. *Hum Mutat* 2013;34:582–6.
- [14] Xu XJ, Lv F, Liu Y, et al. A cryptic balanced translocation involving COL1A2 gene disruption cause a rare type of osteogenesis imperfecta. *Clin Chim Acta* 2016;460:33–9.
- [15] Marini JC, Reich A, Smith SM. Osteogenesis imperfecta due to mutations in non-collagenous genes: lessons in the biology of bone formation. *Curr Opin Pediatr* 2014;26:500–7.
- [16] Korkko J, Ala-Kokko L, De Paepe A, et al. Analysis of the COL1A1 and COL1A2 genes by PCR amplification and scanning by conformation-sensitive gel electrophoresis identifies only COL1A1 mutations in 15 patients with osteogenesis imperfecta type I: identification of common sequences of null-allele mutations. *Am J Hum Genet* 1998;62:98–110.
- [17] Zhuang J, Tromp G, Kuivaniemi H, et al. Direct sequencing of PCR products derived from cDNAs for the pro alpha 1 and pro alpha 2 chains of type I procollagen as a screening method to detect mutations in patients with osteogenesis imperfecta. *Hum Mutat* 1996;7:89–99.
- [18] Lund AM, Astrom E, Soderhall S, et al. Osteogenesis imperfecta: mosaicism and refinement of the genotype-phenotype map in OI type III. Mutations in brief no. 242. Online. *Hum Mutat* 1999;13:503.
- [19] Pauling L, Corey RB. The structure of fibrous proteins of the collagen-gelatin group. *Proc Natl Acad Sci U S A* 1951;37:272–81.
- [20] Raghunath M, Bruckner P, Steinmann B. Delayed triple helix formation of mutant collagen from patients with osteogenesis imperfecta. *J Mol Biol* 1994;236:940–9.
- [21] Prockop DJ, Constantinou CD, Dombrowski KE, et al. Type I procollagen: the gene-protein system that harbors most of the mutations causing osteogenesis imperfecta and probably more common heritable disorders of connective tissue. *Am J Med Genet* 1989;34:60–7.
- [22] Bachinger HP, Morris NP, Davis JM. Thermal stability and folding of the collagen triple helix and the effects of mutations in osteogenesis imperfecta on the triple helix of type I collagen. *Am J Med Genet* 1993;45:152–62.
- [23] Lisse TS, Thiele F, Fuchs H, et al. ER stress-mediated apoptosis in a new mouse model of osteogenesis imperfecta. *PLoS Genet* 2008;4:e7.
- [24] Di Lullo GA, Sweeney SM, Korkko J, et al. Mapping the ligand-binding sites and disease-associated mutations on the most abundant protein in the human, type I collagen. *J Biol Chem* 2002;277:4223–31.
- [25] Thiele F, Cohrs CM, Flor A, et al. Cardiopulmonary dysfunction in the Osteogenesis imperfecta mouse model *Aga2* and human patients are caused by bone-independent mechanisms. *Hum Mol Genet* 2012;21:3535–45.