



# Heads up Sutureless Chandelier assisted scleral buckle

Adel Gady AlAkeely<sup>\*</sup>, Abdulaziz Alageely, Omar Alageely

Retina Division, King Khaled Eye Specialist Hospital, Riyadh, Saudi Arabia

## ARTICLE INFO

### Keywords:

Rhegmatogenous retinal detachment  
Scleral buckle  
Vitreoretinal surgeries  
Scleral tunnel  
3D

## ABSTRACT

**Purpose:** This study aims to describe chandelier assisted scleral buckle (CSB) using 3D visualizing system in phakic uncomplicated Rhegmatogenous Retinal Detachment (RRD).

**Methods:** This technique was performed in 6 eyes of 6 patients with primary rhegmatogenous RD who underwent encircling circumferential scleral buckling with scleral tunnels. Heads up display 3D system was used for visualization and localization of the breaks, and Chandelier Endoillumination was used as a light source was inserted through a 27 G needle sclerotomy 3.5mm from the limbus. A partial-thickness scleral "belt-loop" tunnels in the four quadrants were created using crescent knife angle beveled (2.3 mm in width) to facilitate the smooth passage of the band a 240-silicone band as encircling circumferential buckle. Cryopexy was performed and the incision was closed with cautery or absorbable sutures.

**Results:** Primary attachment success of 5 out of 6 and overall success was 100%. No intraoperative or post-operative complications observed although fellows in training performed half the procedures.

**Conclusions:** Heads up Sutureless Chandelier assisted Scleral Buckle can achieve excellent anatomical success while improving ergonomics and training. Furthermore, it is a safe procedure with less risk of complications and retinal phototoxicity.

## 1. Introduction

Since the introduction of sutureless scleral buckling in 1986, The introduction of Chandelier endoillumination to scleral buckling (SB) has helped identify previously missed retinal breaks in the preoperative examination and helped perform subretinal fluid drainage in a much safer manner.<sup>1,2</sup> In fact, several case series have shown that the Chandelier assisted Scleral buckle (CSB) has a higher success rate than sutured SB with indirect ophthalmoscopy.<sup>3-8</sup> Recently, the adoption of 3D Heads up display system improved the ergonomics for the surgeon. Used alongside Chandelier endoillumination, it helps train new surgeons in the operation room by providing real-time visuals.<sup>9,10</sup> This new technology has been introduced to SB procedures and the outcomes were promising.<sup>9</sup> Moreover, the sutureless SB helps avoid suture-related complications, inadvertent penetration and infection.<sup>11</sup>

This study aims to describe CSB using 3D visualizing system with a scleral tunnel for sutureless anchoring of the encircling band in phakic Rhegmatogenous Retinal Detachment (RRD).

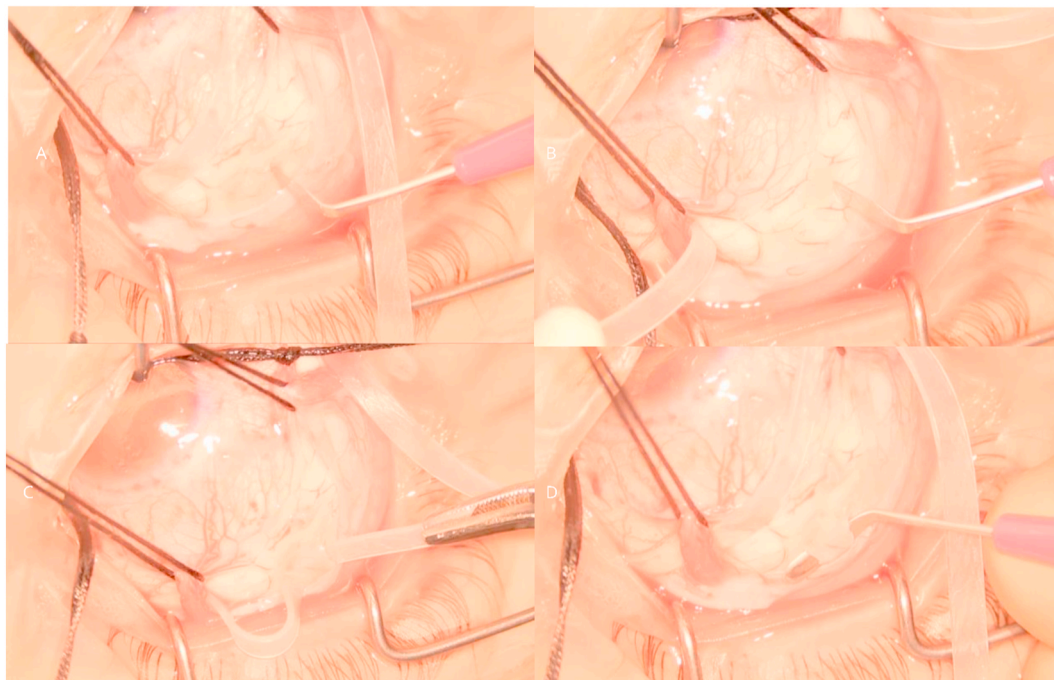## 2. Materials and methods

The Internal Review Board in our institute approved this study and all procedures involved adhered to the tenets of the Declaration of Helsinki. Signed consents were obtained from all study participants. We report a single-center, retrospective, consecutive surgical case series. Inclusion criteria were phakic lens status and absence of Posterior Vitreous Detachment (PVD) in patients who presented with RRD to King Khaled Eye Specialist Hospital from March 2019 to February 2020 and underwent 3D and chandelier-assisted scleral buckle with scleral tunnels. We exclude patients who had previous surgeries, sutured SB with indirect ophthalmoscopy and patients whom we did not use a 3D viewing system in their operation.

### 2.1. Surgical field visualization

All surgical procedures were performed using the NGENUITY 3D visualization system (Alcon Laboratories, Fort Worth, TX, USA). The system was integrated with a surgical microscope (Leica Microsystems GmbH Wetzlar, Germany) and a BIOM-5 wide-angle viewing system (OCULUS Surgical, Inc. Port St. Lucie, FL, USA) for visualization.

<sup>\*</sup> Corresponding author. Retina Division, King Khaled Eye Specialist Hospital, Umm al Hamam Al Gharbi, Al Urubah branch Rd, Riyadh, Saudi Arabia.  
E-mail address: [adel.alakeely@gmail.com](mailto:adel.alakeely@gmail.com) (A.G. AlAkeely).

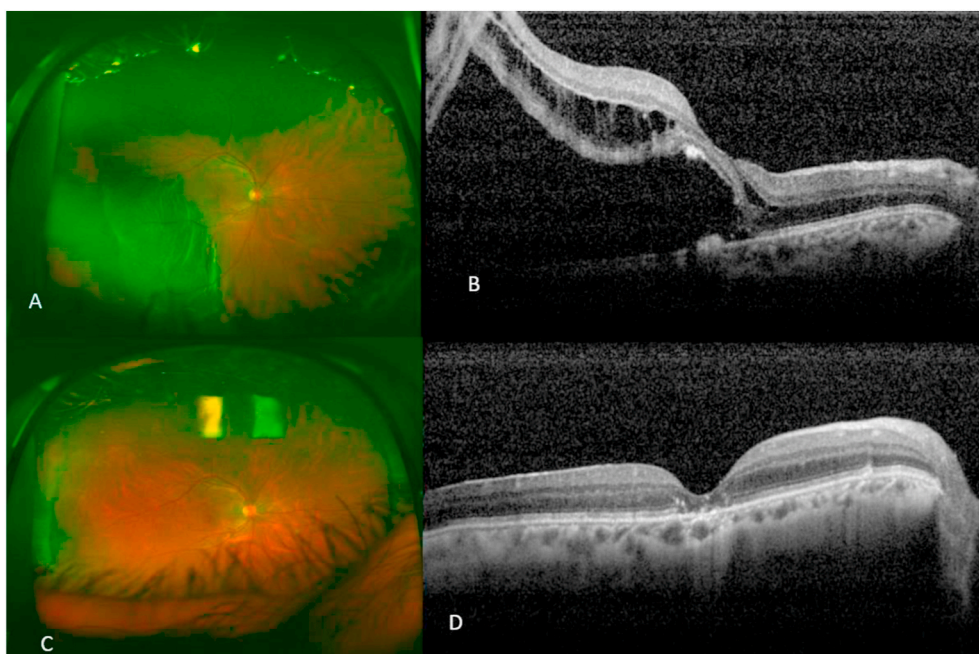


**Fig. 1.** A and B: Right eye partial thickness scleral wound was created with crescent knife. C: Crescent knife was passed through the partial thickness scleral “belt-loop” tunnels. D: 240 style scleral band passed through the tunnel.

**2.2. Surgical procedure**

All surgeries were performed under General Anesthesia. A standard conjunctival peritomy was performed and 4–0 silk sutures passed underneath rectus muscles for traction. 23 Gauge/0.6mm Combined Eckardt Multi-Fiber Endoillumination Probe/Chandelier (DORC, Zuidland, Netherlands) was used for the endo-illumination source the light fibers was removed from the metallic tube and inserted opposite to the break based on the preoperative assessment through a 27 G needle sclerotomy 3.5mm from the limbus. The breaks were localized and marked by a depression mark; then, cryotherapy was applied.

A partial-thickness scleral “belt-loop” tunnels in the four quadrants were prepared and completed using crescent knife angle beveled (2.3 mm in width) to facilitate the smooth passage of the band (Fig. 1). The location was 4 mm posterior to an imaginary line drawn between the muscle insertions in all quadrants except where the break is located as it was relocated posteriorly to support the posterior edge of the break. A 360-degree circumferential buckle using silicon band 240 Style, 2.5mm in width, was joined by a band silicone sleeve no additional segment buckles needed in any case. Peritomy was closed by either cauterization of the conjunctiva or suturing using an 8.0 absorbable Vicryl suture.



**Fig. 2.** A: Right eye preoperative Ultra wide-field fundus photo showing a Temporal RRD with macula off, B: Preoperative Optical coherence tomography (OCT) showing macular detachment and sub retinal hyper-reflective deposits associated with CNV secondary to Central serous Choriorretinopathy (CSCR). C: Postoperative photo of the same eye showing temporal indentation cause by the buckle with flat retina D: Post operative OCT showing flat macula disrupted outer retinal layers and nasal subretinal hyper-reflective lesion corresponding to resolved pigment epithelial detachment (PED).



Fig. 3. A case of RRD associated with retinoschisis while performing cryotherapy to the break at 8 o'clock and old laser scars at the edge of retinoschisis were performed are seen superiorly as seen in the heads up display.

### 3. Results

A total of 6 eyes of 6 patients were included in this study. 4 females and 2 males and the age ranged from 22 to 60 years. The macula was detached in half of the cases, with 5 patients having inferior detachment. Mean visual acuity at presentation was 0.32 LogMAR, and Median follow-up was 6 months (5–13 months). Primary attachment success was 5/6, and overall success was 100%. The mean final visual acuity achieved was 0.20 LogMAR. No intraoperative or postoperative complications were encountered in any of the 6 cases. One patient had RRD associated with Retinoschisis (Fig. 3). Two patients had refractive surgeries; one had Laser in Situ Keratomileusis (LASIK) and one had a phakic intraocular lens.

External drainage was performed in 2 cases and 2 needed paracentesis. PPV was performed for a failed buckle where the failure was related to Proliferative Vitreoretinopathy (PVR). One patient had concomitant Neovascularization (CNV) with Subretinal Fluid (SRF) that needed a Bevacizumab therapy course to resolve (Fig. 2).

### 4. Discussion

Scleral buckling is practiced/taught with decreasing frequency with a preference toward vitrectomy in recent times.<sup>11</sup> This has been attributed to the evolution in instrumentation, wide-field viewing systems and micro-incision cutters in pars plana vitrectomy (PPV).<sup>1</sup> Nevertheless, the adoption of endoillumination and wide-angle visualization systems have rejuvenated Scleral buckling for RRD repair in recent years.<sup>12</sup>

According to a recent large multicenter study, scleral buckle showed better results (91.7%) than pars plana vitrectomy (83.1%) in moderately complex phakic primary RRD.<sup>13</sup> These results encourage surgeons to utilize this procedure in favorable contexts.

There are several advantages to the use of Chandelier endoillumination over the indirect ophthalmoscope. That includes shorter surgical time, higher magnification, and better visualization, especially when it comes to image inversion. In addition to the educational value that it warrants by allowing training surgeons to observe the operation in Realtime.<sup>10</sup>

3D visualization system has been used in scleral buckle surgery and has shown improved retinal image resolution, better ergonomics for the surgeon and an ability to be used for educational purposes. The improvement in surgeon ergonomics is attributed to the heads-up position. Despite the reports of delays in the screen display of 0.09 seconds this was no noticeable given the large working area in an extraocular procedure such as scleral buckle.<sup>14</sup> Viewing the procedure on a large heads up display screen makes it easier for trainees to learn the steps of the procedure when done by the consultant and it allows for simultaneous remarks regarding the flow of the procedure when performed by the trainee.<sup>1</sup> Furthermore, when performing CSB, the 3D visualization

system's use gives the option to reduce the light intensity, thus reducing the risk of light toxicity.<sup>9</sup> Utilizing the heads-up system makes it easier for faculty to point out mistakes and correct them simultaneously, which, in contrast to the indirect ophthalmoscope in training set-up, would take a long time, causing decreasing levels of corneal clarity and visualization. Although fellows in training performed half the procedures in this study, there were no reported complications with a high success rate (overall success 100%). The only failed case was related to PVR, a frequent cause of primary SB failure.<sup>11</sup>

### 5. Conclusion

Heads up Sutureless Chandelier assisted Scleral Buckle can achieve excellent anatomical success while improving the surgeons' ergonomics and training experience. Furthermore, with less risk of complications and retinal phototoxicity compared to sutured scleral buckle with indirect ophthalmoscopy.

### Patient consent

Written consent to publish this case has not been obtained. This report does not contain any personal identifying information.

### Funding

No funding or grant support

### Authorship

All authors attest that they meet the current ICMJE criteria for Authorship.

### Declaration of competing interest

The following authors have no financial disclosures:AA, AA and AO.

### Acknowledgements

None.

### References

- Seider MI, Nomides RE, Hahn P, Mruthyunjaya P, Mahmoud TH. Scleral buckling with chandelier illumination. *J Ophthalmic Vis Res.* 2016;11(3):304–309.
- Sternberg Jr P, Tiedeman J, Premsky JG. Sutureless scleral buckle for retinal detachment with thin sclera. *Retina.* 1988;8(4):247–249.
- Imai H, Tagami M, Azumi A. Scleral buckling for primary rhegmatogenous retinal detachment using noncontact wide-angle viewing system with a cannula-based 25 G chandelier endoilluminator. *Clin Ophthalmol.* 2015;9:2103–2107.
- Roca JA, Maia M, da Cruz NFS, et al. Non-contact wide-angled visualization with chandelier-assisted scleral buckling for primary uncomplicated rhegmatogenous retinal detachment [published online ahead of print, 2020 May 14]. *Graefes Arch Clin Exp Ophthalmol.* 2020. <https://doi.org/10.1007/s00417-020-04737-1>.
- Frisina R, Forlini M, Date P, et al. Microscope-assisted ab externo surgery for the treatment of primary rhegmatogenous retinal detachment – new tech meets old art. *Ophthalmic Res.* 2020;63:34–40. <https://doi.org/10.1159/000501213>.
- Jeon GS, Han JR. Effectiveness of scleral buckling with a wide-field surgical microscope and chandelier illumination in retinal detachment repair. *Ophthalmologica.* 2019;242(1):31–37. <https://doi.org/10.1159/000496165>.
- Schwartz SG, Kuhl DP, McPherson AR, Holz ER, Mieler WF. Twenty-year follow-up for scleral buckling. *Arch Ophthalmol.* 2002;120(3):325–329. <https://doi.org/10.1001/archophth.120.3.325>.
- Haritoglou C, Brandlhuber U, Kampik A, Priglinger SG. Anatomic success of scleral buckling for rhegmatogenous retinal detachment—a retrospective study of 524 cases. *Ophthalmologica.* 2010;224(5):312–318. <https://doi.org/10.1159/000298752>.
- Kita M, Kusaka M, Yamada H, Hama S. Updated chandelier illumination-assisted scleral buckling using 3D visualization system. *Clin Ophthalmol.* 2019;13:1743–1748.
- Narayanan R, Tyagi M, Hussein A, Chhablani J, Apte RS. Scleral buckling with wide-angled endoillumination as a surgical educational tool. *Retina.* 2016;36(4):830–833.
- Shanmugam PM, Singh TP, Ramanjulu R, Rodrigues G, Reddy S. Sutureless scleral buckle in the management of rhegmatogenous retinal detachment. *Indian J Ophthalmol.* 2015;63(8):645–648.

12. Rishi Ekta, Manchegowda Pradeep T. Commentary: revival of scleral buckling technique with Chandelier illumination. *Indian J Ophthalmol.* 2019;67(3):431–432.
13. Ryan EH, Ryan CM, Forbes NJ, et al. Primary retinal detachment outcomes study report number 2: phakic retinal detachment outcomes. *Ophthalmology.* 2020; S0161–6420(20):30237–30242.
14. Ehlers JP, Uchida A, Srivastava SK. The integrative surgical theater: combining intraoperative optical coherence tomography and 3D digital visualization for vitreoretinal surgery in the DISCOVER study. *Retina.* 2018;38(Suppl 1):S88–S96.