

# Patients with pulse-synchronous tinnitus should be suspected to have elevated cerebrospinal fluid pressure

Journal of International Medical Research

2019, Vol. 47(9) 4104–4113

© The Author(s) 2019

Article reuse guidelines:

[sagepub.com/journals-permissions](http://sagepub.com/journals-permissions)

DOI: 10.1177/0300060519857846

[journals.sagepub.com/home/imr](http://journals.sagepub.com/home/imr)



Ping Guo<sup>1,\*</sup>, Wenfang Sun<sup>2,\*</sup>, Suming Shi<sup>1</sup> and Wuqing Wang<sup>1</sup> 

## Abstract

**Objective:** This study was performed to evaluate the prevalence and clinical importance of elevated cerebrospinal fluid (CSF) pressure among patients with pulse-synchronous tinnitus.

**Methods:** Nineteen patients underwent height and weight measurements, routine otologic examinations, ear computed tomography, brain magnetic resonance imaging, fundus examination, and tinnitus score assessment. We analyzed the data with Fisher's exact test, the t-test, and Pearson's correlation.

**Results:** The mean age of the 19 patients was  $39.2 \pm 8.1$  years (range, 27–54 years), and the mean body mass index was  $22.2 \pm 1.6$  kg/m<sup>2</sup> (range, 19.9–24.6 kg/m<sup>2</sup>). The proportion of patients with elevated CSF pressure was 68%. No significant correlation between the severity of tinnitus and CSF pressure was found. Lumbar puncture and oral administration of diuretics resulted in significant improvement in tinnitus.

**Conclusions:** If detailed physical and imaging examinations fail to detect the definite cause of pulse-synchronous tinnitus, a routine lumbar puncture should be performed to measure the CSF pressure. Elevated CSF pressure should be suspected in patients with pulse-synchronous tinnitus.

## Keywords

Pulsatile tinnitus, pulse-synchronous tinnitus, intracranial pressure, body mass index, cerebrospinal fluid, lumbar puncture

Date received: 8 November 2018; accepted: 28 May 2019

\*These authors contributed equally to this work.

### Corresponding author:

Wuqing Wang, NHC Key Laboratory of Hearing Medicine (Fudan University), Department of Otolaryngology, Eye Ear Nose & Throat Hospital, 83 Fenyang Road, Shanghai 200031, PR China.

Email: [wwuqing@eent.shmu.edu.cn](mailto:wwuqing@eent.shmu.edu.cn)

<sup>1</sup>NHC Key Laboratory of Hearing Medicine (Fudan University), Department of Otolaryngology, Eye Ear Nose & Throat Hospital, Shanghai, PR China

<sup>2</sup>Department of Otolaryngology, Chongqing General Hospital, Chongqing, PR China



## Introduction

Pulsatile tinnitus is an occasional otologic symptom encountered in the field of otolaryngology, and its diagnosis and management are dilemmas for the otolaryngologist. Pulse-synchronous tinnitus is caused by perception of a vascular somatosound that may originate from vascular structures within the cranial cavity, head and neck region, or thoracic cavity and is transmitted to the cochlea by bony or vascular structures.<sup>1-3</sup> Pulse-synchronous tinnitus can be classified as arterial, arteriovenous, or venous according to the vessel of origin. Arterial causes of pulse-synchronous tinnitus include atherosclerotic carotid artery disease; dural, skull base, and cervical region arteriovenous fistulas and arteriovenous malformations; glomus tumors of the jugular foramen and middle ear; a tortuous internal carotid artery; intrapetrous carotid artery dissection; and aneurysm and dehiscence of the superior semicircular canal.<sup>4-7</sup> The venous causes of pulse-synchronous tinnitus are jugular bulb abnormalities, transverse-sigmoid sinus stenosis and aneurysms, abnormal condylar and mastoid emissary veins, and idiopathic intracranial hypertension (IIH).<sup>8-10</sup> There are few differences between the terms "pulse-synchronous tinnitus" and "pulsatile tinnitus" in the published literature.<sup>1,2</sup>

The reported incidence of IIH with identifiable anomalies in patients with pulsatile tinnitus ranges from 2% to 37%.<sup>3,11</sup> The clinical presentation of IIH is highly variable, often resulting in a substantial delay in diagnosis. Headaches, unilateral or bilateral transient visual blurring, pulse-synchronous tinnitus, papilledema, and sixth nerve paresis are common features of IIH. Other reported symptoms of IIH include dizziness, vision impairment, and horizontal diplopia.<sup>12,13</sup> The treatment of IIH can be both medical and surgical to lower the

elevated intracranial pressure (ICP) and treat the symptoms. Weight loss has been considered in the treatment of IIH during the past several years. Lumbar puncture (LP) only has a transient effect on lowering the ICP.<sup>14,15</sup> Drugs including acetazolamide, topiramate, and steroids have also been used to treat IIH.<sup>13</sup>

IIH is not commonly encountered by otolaryngologists. Furthermore, IIH without papilledema or with atypical presentations can be misdiagnosed or missed. The present study was performed to evaluate the prevalence and clinical importance of elevated CSF pressure among patients with pulse-synchronous tinnitus.

## Materials and methods

This prospective study was conducted from February 2013 to August 2016. We recruited patients referred to the Department of Otorhinolaryngology, the Eye and ENT Hospital, Fudan University, Shanghai, China who presented with pulse-synchronous tinnitus. The study protocol was approved by the Ethics Committee of Fudan University's review board, and written informed consent was obtained from all study participants.

### *Patient selection*

Patients with pulse-synchronous tinnitus who met the following criteria were enrolled in the study: persistent pulse-synchronous tinnitus was present at the initial presentation; the rhythm of the tinnitus was consistent with the heartbeat; the tinnitus decreased but did not disappear when compressing the neck veins ipsilateral to the tinnitus and quietly walking upright; and the tinnitus increased when turning the head toward the side contralateral to the tinnitus, while remaining in a supine or contralateral lateral position, and when defecating or moving heavy objects.

The exclusion criteria were dural arteriovenous fistulas/malformations; middle ear, temporal bone, and intracranial space-occupying lesions; abnormal neurological examination findings; and endocrine, metabolic, and cardiovascular diseases.

### **Assessment methods**

All patients underwent physical and neurological examinations including weight and height measurements, blood biochemistry and endocrine examinations, routine otologic examinations such as tympanic membrane examination with an electric otoscope, and pure-tone audiometry and acoustic impedance audiological evaluations. A standardized ophthalmological examination was performed, including visual acuity, a slit-lamp examination, eyeball motility and pupil examinations, indirect and direct ophthalmoscopy, and fundus photography. Computed tomography, magnetic resonance arteriography, and magnetic resonance venography were performed on all patients.

Each patient's body mass index (BMI) was calculated using the formula  $BMI = \text{weight (kg)} / [\text{height (m)}]^2$ . The BMI was categorized according to the National Heart, Lung, and Blood Institute guidelines as follows:<sup>16</sup> BMI of  $<18.5 \text{ kg/m}^2$  was considered underweight, BMI of  $18.5$  to  $24.9 \text{ kg/m}^2$  was considered normal, BMI of  $25.0$  to  $29.9 \text{ kg/m}^2$  was considered overweight, and BMI of  $30.0$  to  $39.9 \text{ kg/m}^2$  was considered obese.

The severity of tinnitus was scored from 1 (mild or no handicap) to 5 (most serious) based on the Tinnitus Handicap Inventory (THI).<sup>17</sup> The same questionnaire was used for tinnitus assessments before LP, 30 minutes after LP, before the administration of diuretics, and 4 weeks after the administration of diuretics.

### **LP and CSF pressure measurement**

All patients underwent CSF pressure measurement in the standardized LP manometry position. They were instructed to stay in the lateral decubitus position with their legs straightened and were given about 15 minutes to relax before recording the stabilized opening pressure. We did not collect CSF until the opening pressure was recorded. For patients with an opening pressure of  $>200 \text{ mmH}_2\text{O}$ , CSF was withdrawn until a final CSF pressure of  $<180 \text{ mmH}_2\text{O}$  was obtained. CSF was collected from all patients for standard cytological and biochemical analyses.

### **Treatment programs**

All patients who underwent LP manometry and had an elevated CSF pressure received no diuretic pharmacotherapy until 3 days after the LP. The study drug was acetazolamide (250 mg). The initial dosage of the study drug was 1 g/day divided into two doses, and the dosage was gradually increased 2 g/day after 1 week. The duration of oral acetazolamide treatment was 4 weeks. During the administration of acetazolamide, potassium chloride was administered orally and electrolytes were measured weekly.

### **Statistical analysis**

The statistical analysis was performed using the statistical software SPSS 20.0 (IBM Corp., Armonk, NY, USA). A p-value of  $<0.05$  was considered statistically significant. Fisher's exact test and the t-test were used to compare changes in THI severity in response to LP and acetazolamide treatment. Pearson's correlation was used to identify associations between the tinnitus severity grade and CSF pressure before CSF pressure reduction.

## Results

Thirty-four patients had persistent pulse-synchronous tinnitus at the initial presentation; only 19 patients who underwent LP with normal CSF contents were included in the final sample.

The proportion of patients with an elevated CSF pressure was 68% (13/19); six patients had CSF pressures ranging from 200 to 250 mmH<sub>2</sub>O, and seven patients had CSF pressures ranging from 300 to 350 mmH<sub>2</sub>O. Their mean BMI was  $22.2 \pm 1.6$  kg/m<sup>2</sup> (range, 19.9–24.6 kg/m<sup>2</sup>). Their mean age was  $39.2 \pm 8.1$  years (range, 27–54 years), and 10 of the 13 patients were women. The duration of tinnitus ranged from 1 month to 3 years (median, 6 months). The affected side was the right side in nine patients (69%) and the left side in three patients (23%); one patient (5%) was affected bilaterally.

Eleven of the 13 patients with an elevated CSF pressure only had pulse-synchronous tinnitus at the initial presentation; 1 patient also had migraine and 1 patient also had hypertension. No patient exhibited papilledema.

Magnetic resonance imaging revealed empty sellae in two patients and unilateral preferential flow in seven patients; no other positive imaging findings were observed. The patients' characteristics are summarized in Table 1.

### Adverse events

With the exception of one patient who complained of a mild, low-pressure headache 30 minutes after the LP that quickly subsided within 1 day, no other patients experienced obvious complications. Cytological and biochemical analyses of the patients' CSF were normal. No patient was found to have an electrolyte imbalance.

### *Elevated CSF pressure and severity of pulse-synchronous tinnitus*

The THI score was correlated with the CSF pressure according to Spearman's correlation; however, the correlation was not statistically significant (Figure 1).

### *Reduced CSF pressure and severity of pulse-synchronous tinnitus*

LP resulted in an improvement of tinnitus in 9 of 13 patients with an elevated CSF pressure 30 minutes after the procedure (mean THI, 1.6; 95% confidence interval, 0.9–2.4;  $p < 0.05$ ) (see Figure 2). The severity of tinnitus remained unchanged after the procedure in two patients with grade 1 tinnitus and two patients with grade 2 tinnitus.

After 1 month of treatment with diuretics, the tinnitus improved in 9 of 13 patients with an elevated CSF pressure (mean THI, 1.3; 95% CI, 0.7–1.9;  $p < 0.05$ ) (see Figure 3), including the patients who maintained tinnitus improvement, while the tinnitus was reduced in the remaining 2 of 13 patients. The severity of tinnitus remained unchanged after the procedure in 3 patients with grade 1 tinnitus and one patient with grade 2 tinnitus.

We separated the patients with elevated CSF pressure into two groups according to the severity of CSF pressure elevation to compare the efficacy of acetazolamide and response to LP. Group A comprised six patients with CSF pressures ranging from 200 to 250 mmH<sub>2</sub>O, and Group B comprised seven patients with CSF pressures ranging from 300 to 350 mmH<sub>2</sub>O. Six of seven patients in Group B experienced remission of tinnitus in response to LP, compared with only three of six patients in Group A; however, the difference was not statistically significant. The tinnitus remission rate in Groups A and B in response to acetazolamide was also not significantly different (Table 2).

**Table 1.** Symptoms and examination findings in patients with elevated cerebrospinal fluid pressure

Patient	Age, y	Sex	Side	Duration of tinnitus	Other symptoms	BMI, kg/m <sup>2</sup>	Hearing	Tympanogram	Perimetry	Fundus examination	CT	MRI	ICP, mmH <sub>2</sub> O
1	27	F	R	3 mo	No	20.1	Low-sen	A	Normal	Normal	n-path	n-path	320
2	34	F	L	6 mo	No	23.6	Low-sen	A	Normal	Normal	n-path	Empty sella	300
3	46	F	R	3 y	No	22.6	Normal	C	Normal	Normal	n-path	Upf	230
4	35	M	L	10 mo	No	24.1	Low-sen	A	Normal	Normal	n-path	Upf	310
5	39	M	R	1 mo	No	23.1	High-sen	A	Normal	Normal	n-path	Upf	250
6	46	F	L	5 mo	No	22.4	Low-sen	A	Normal	Normal	n-path	Upf	240
7	33	F	R	6 mo	Migraine	20.2	Low-sen	A	Normal	Normal	n-path	n-path	335
8	31	F	R	10 mo	No	21.3	Low-sen	C	Normal	Normal	n-path	Upf	325
9	52	F	R	3 mo	No	24.6	High-sen	A	Normal	Normal	n-path	n-path	235
10	39	F	R	1 mo	No	20.7	Normal	A	Normal	Normal	n-path	Upf	340
11	38	M	R	6 mo	Hypertension	23.2	Low-sen	A	Normal	Normal	n-path	n-path	220
12	54	F	B	1 y	No	22.6	High-sen	A	Normal	Normal	n-path	Upf	240
13	35	F	R	2 y	No	19.9	Normal	C	Normal	Normal	n-path	Empty sella	315

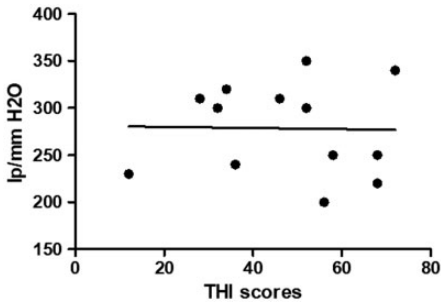
BMI, body mass index; CT, computed tomography; MRI, magnetic resonance imaging; ICP, intracranial pressure; Upf, unilateral preferential flow; F, female; M, male; R, right; L, left; n-path, no pathology; Low-sen, average hearing threshold of 125 Hz, 250 Hz, 500 Hz, 1000 Hz >25 dBnHL; High-sen, average hearing threshold of 2000 Hz, 4000 Hz, 8000 Hz >25 dBnHL

### Discussion

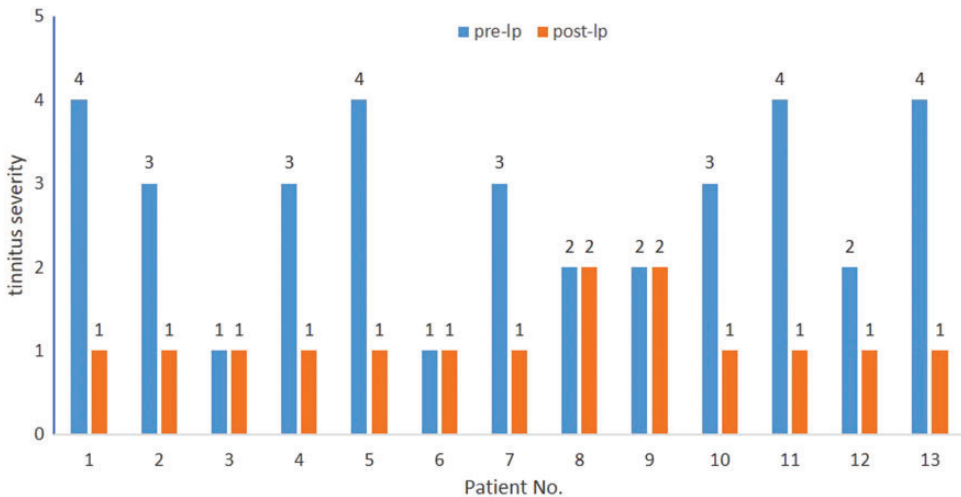
Some patients with pulsatile tinnitus have a treatable cause.<sup>3,18</sup> Establishment of the correct diagnosis of pulsatile tinnitus will prevent a potentially life-threatening underlying disorder and avoid disastrous consequences. Individual reports have mentioned that IIH is one of the most common causes

of venous pulse-synchronous tinnitus and may even be the first or only clinical presentation.<sup>19</sup> According to past studies, IIH predominantly affects obese women of childbearing age (20–44 years).<sup>20–22</sup> However, women of normal weight or men can often be missed in clinical practice when considering the possibility of IIH syndrome as a cause of pulse-synchronous tinnitus. In this study, all patients had a normal weight (BMI range, 19.9–24.6 kg/m<sup>2</sup>) and two patients were male, and their tinnitus improved after performance of LP and reduction of the CSF pressure.

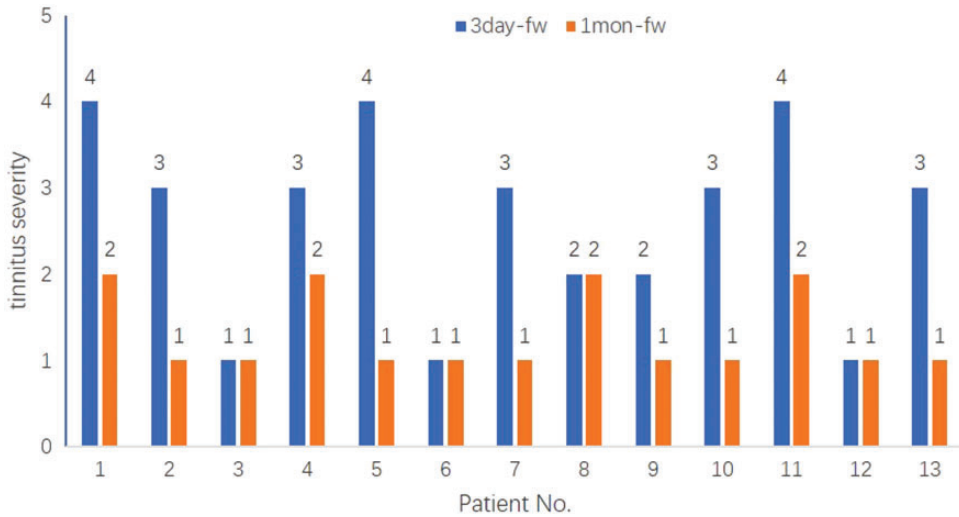
The first diagnostic criteria for IIH were published in 1937. As imaging technology improved, updated modified criteria were subsequently published in 2002 and 2013.<sup>23,24</sup> In the most recent modified criteria,<sup>24</sup> a definitive diagnosis IIH is based on the presence of papilledema; normal neurological examination findings, neuroimaging findings, and CSF composition; and elevated ICP. In the present study, the patients had pulse-synchronous tinnitus at the initial



**Figure 1.** Correlation between tinnitus severity and cerebrospinal fluid pressure. The tinnitus scores are plotted along the horizontal axis, and the cerebrospinal fluid pressures are marked along the vertical axis. Pearson’s correlation,  $p < 0.05$ .



**Figure 2.** Impact of lumbar puncture and tinnitus severity (THI grade). THI grades before LP (pre-LP) and after LP (post-LP) are plotted along the vertical axis, and the patient numbers are marked along the horizontal axis. THI grade I represents both mild and no tinnitus. Paired t-test,  $p < 0.05$ . THI, Tinnitus Handicap Index; LP, lumbar puncture.



**Figure 3.** Impact of diuretics and tinnitus severity (THI grade). THI grades before (3-day follow-up) and after (1-month follow-up) diuretic treatment are plotted along the vertical axis, and patient numbers are marked along the horizontal axis. THI grade 1 represents both mild and no tinnitus. Paired t-test,  $p < 0.05$ . THI, Tinnitus Handicap Index.

**Table 2.** Changes in the severity of tinnitus according to the Tinnitus Handicap Inventory score in both groups in response to lumbar puncture and acetazolamide

	Lumbar puncture	Diuretics
Group A (n = 6)	1.3 ± 1.2	1.0 ± 0.9
Group B (n = 7)	1.7 ± 1.2	1.8 ± 1.1
p	0.59	0.34

Data are presented as mean ± standard deviation.

Assessed using Fisher's exact or the  $\chi^2$  test,  $p < 0.05$ .

Group A, cerebrospinal fluid pressures ranging from 200 to 250 mmH<sub>2</sub>O; Group B, cerebrospinal fluid pressures ranging from 300 to 350 mmH<sub>2</sub>O.

presentation without typical IIH symptoms or signs; therefore, diagnosis of IIH at the initial assessment was difficult.

When the diagnostic criteria for IIH are only partially fulfilled or not fulfilled in patients without papilledema or sixth nerve palsy, a combination of an elevated CSF pressure and radiologic criteria can suggest the diagnosis.<sup>24</sup> Specific neuroimaging findings such as empty sellae, CSF

leakage, transverse venous sinus stenosis, flattening of the posterior globes, distention of the optic nerve sheaths, cerebellar tonsillar herniation, tortuosity of the optic nerve, and optic nerve head protrusion may suggest long-standing IIH.<sup>24,25</sup> Other findings include normal brain parenchyma without evidence of hydrocephalus, a mass, or a structural lesion and no abnormal meningeal enhancement. Bono et al.<sup>26</sup> found that the typical neuroimaging findings in patients with elevated CSF pressure were bilateral transverse sinus stenosis; however, only two patients in the present study had typical neuroimaging findings such as empty sellae, which helped us to consider the probability of IIH in these patients without a definite cause of pulse-synchronous tinnitus.

Nonspecific symptoms of IIH such as headache; transient visual obscurations; pulse-synchronous tinnitus; binocular diplopia; and neck, shoulder, or back pain have been reported in some studies and can complicate the diagnosis of IIH.<sup>24,26,27</sup>

Bono et al.<sup>26</sup> found that headache was the most common symptom of high CSF pressure, while tinnitus was reported only in 41% of 148 patients with isolated CSF hypertension. In the present study, however, only 1 patient with elevated CSF pressure had headache, and 13 of 19 patients with pulse-synchronous tinnitus had elevated CSF pressure. This reminds us that atypical presentations of elevated CSF pressure vary and require close attention.

Treatment of elevated ICP can be both medical and surgical. LP and diuretics can reduce or completely resolve tinnitus in patients with IIH.<sup>12</sup> In the present study, the patients' tinnitus resolved and the THI severity was significantly reduced after LP ( $p < 0.05$ ), the tinnitus symptoms recurred 3 days after the LP. However, the tinnitus severity was significantly reduced 1 month after starting acetazolamide treatment ( $p < 0.05$ ). Additionally, the tinnitus remission rates were not significantly different between patients with CSF pressure of 200 to 250 mmH<sub>2</sub>O and 300 to 350 mmH<sub>2</sub>O. These results support the association of pulsatile tinnitus with elevated CSF pressure.

Clinical observations suggest that the symptoms and signs of IIH will improve with weight reduction,<sup>28</sup> but our analysis showed no significant correlation between BMI and tinnitus severity. However, few data in the literature have explored the relationship between tinnitus severity and ICP. In this study, we found no significant relationship between tinnitus severity and the LP opening pressure.

Pulse-synchronous tinnitus is a common feature in patients with IIH and was reported in 52% of patients in one study, with two-thirds presenting bilaterally.<sup>29</sup> We found that most patients had unilateral pulse-synchronous tinnitus in the present study. One hypothesis is that the presentation of unilateral pulse-synchronous tinnitus might be related to unilateral preferential flow on magnetic resonance

imaging and that the presentation of unilateral tinnitus and elevated CSF pressure rather than typical IIH symptoms, signs, and imaging findings may indicate early-stage IIH.

Because pulse-synchronous tinnitus is associated with otologic symptoms such as hearing loss, dizziness, and a feeling of aural fullness, the otolaryngologist may be the first to be consulted. However, when the clinical presentation of IIH is not obvious (especially in patients of normal weight), the otolaryngologist might ignore an elevated CSF pressure. It may be worth involving a neurologist in the follow-up of patients with pulsatile tinnitus with an elevated CSF pressure.

## Conclusion

Elevated CSF pressure should be suspected when detailed physical and imaging examinations have failed to identify the cause of pulse-synchronous tinnitus. Such patients are not limited to obese women of childbearing age but may also include patients of normal weight. Otolaryngologists should pay attention to the possibility of elevated CSF pressure in patients with pulse-synchronous tinnitus, especially in those who do not present with typical symptoms of IIH. For patients with pulse-synchronous tinnitus who also present with an elevated CSF pressure, LP and oral administration of diuretics may be an effective short-term treatment strategy.

## Declaration of conflicting interest

The authors declare that there is no conflict of interest.

## Funding

The authors disclosed receipt of the following financial support for the research, authorship, and/or publication of this article: This work was supported by the National Nature Science



Foundation of China (grant no. 81670933 to Wuqing Wang; <http://www.nsf.gov.cn/>).

## ORCID iD

Wuqing Wang  <https://orcid.org/0000-0002-7395-9525>

## References

- Eisenman DJ. Sinus wall reconstruction for sigmoid sinus diverticulum and dehiscence: a standardized surgical procedure for a range of radiographic findings. *Otol Neurotol* 2011; 32: 1116–1119.
- Mattox DE and Hudgins P. Algorithm for evaluation of pulsatile tinnitus. *Acta Otolaryngol* 2008; 128: 427–431.
- Sismanis A. Pulsatile tinnitus: contemporary assessment and management. *Curr Opin Otolaryngol Head Neck Surg* 2011; 19: 348–357.
- Sismanis A, Stamm MA and Sobel M. Objective tinnitus in patients with atherosclerotic carotid artery disease. *Am J Otol* 1994; 15: 404–407.
- Bink A, Berkefeld J, Kraus L, et al. Long-term outcome in patients treated for benign dural arteriovenous fistulas of the posterior fossa. *Neuroradiology* 2011; 53: 493–500.
- Zager EL, Shaver EG, Hurst RW, et al. Distal anterior inferior cerebellar artery aneurysms. Report of four cases. *J Neurosurg* 2002; 97: 692–696.
- Lustig LR and Jackler RK. Paraganglioma (glomus tumor). In: Hughes GB and Pensak ML (eds) *Clinical otology*. New York: Thieme, 2007, pp.326–330.
- Bold EL, Wanamaker HH, Hughes GB, et al. Magnetic resonance angiography of vascular anomalies of the middle ear. *Laryngoscope* 1994; 104: 1404–1411.
- Sismanis A and Smoker WR. Pulsatile tinnitus: recent advances in diagnosis. *Laryngoscope* 1994; 104: 681–688.
- Sismanis A, Butts FM and Hughes GB. Objective tinnitus in benign intracranial hypertension: an update. *Laryngoscope* 1990; 100: 33–36.
- Bae SC, Kim DK, Yeo SW, et al. Single-center 10-year experience in treating patients with vascular tinnitus: diagnostic approaches and treatment outcomes. *Clin Exp Otorhinolaryngol* 2015; 8: 7–12.
- Markey KA, Mollan SP, Jensen RH, et al. Understanding idiopathic intracranial hypertension: mechanisms, management, and future directions. *Lancet Neurol* 2016; 15: 78–91.
- Goodwin J. Recent developments in idiopathic intracranial hypertension (IIH). *Semin Ophthalmol* 2003; 18: 181–189.
- Kupersmith MJ, Gamell L, Turbin R, et al. Effects of weight loss on the course of idiopathic intracranial hypertension in women. *Neurology* 1998; 50: 1094–1098.
- Lavinio A, Czosnyka Z and Czosnyka M. Cerebrospinal fluid dynamics: disturbances and diagnostics. *Eur J Anaesthesiol Suppl* 2008; 42: 137–141.
- Boddu SR, Corey A, Peterson R, et al. Fluoroscopic-guided lumbar puncture: fluoroscopic time and implications of body mass index- a baseline study. *AJNR Am J Neuroradiol* 2014; 35: 1475–1480.
- Newman CW, Jacobson GP and Spitzer JB. Development of the tinnitus handicap inventory. *Arch Otolaryngol Head Neck Surg* 1996; 122: 143–148.
- Guo P and Wang WQ. Degree of sigmoid sinus compression and the symptom relief using magnetic resonance angiography in venous pulsating tinnitus. *Clin Exp Otorhinolaryngol* 2015; 8: 111–116.
- Giuseffi V, Wall M, Siegel PZ, et al. Symptoms and disease associations in idiopathic intracranial hypertension (pseudotumor cerebri): a case-control study. *Neurology* 1991; 41: 239–244.
- Johansson MC, Eriksson P, Peker Y, et al. The influence of patent foramen ovale on oxygen desaturation in obstructive sleep apnoea. *Eur Respir J* 2007; 29: 149–155.
- Idiculla T, Zachariah G, Br K, et al. The incidence and prevalence of idiopathic intracranial hypertension in south Sharaqiah region, Oman. *Oman J Ophthalmol* 2013; 6: 189–192.
- Kesler A, Stolovic N, Bluednikov Y, et al. The incidence of idiopathic intracranial hypertension in Israel from 2005 to 2007: results of a nationwide survey. *Eur J Neurol* 2014; 21: 1055–1059.

23. Friedman DI and Jacobson DM. Diagnostic criteria for idiopathic intracranial hypertension. *Neurology* 2002; 59: 1492–1495.
24. Friedman DI, Liu GT and Digre KB. Revised diagnostic criteria for the pseudotumor cerebri syndrome in adults and children. *Neurology* 2013; 81: 1159–1165.
25. Bidot S, Saindane AM, Peragallo JH, et al. Brain imaging in idiopathic intracranial hypertension. *J Neuroophthalmol* 2015; 35: 400–411.
26. Bono F, Curcio M, Rapisarda L, et al. Cerebrospinal fluid pressure-related features in chronic headache: a prospective study and potential diagnostic implications. *Front Neurol* 2018; 9: 1090.
27. Özge A and Bolay H. Intracranial hypotension and hypertension in children and adolescents. *Curr Pain Headache Rep* 2014; 18: 430.
28. Hannerz J and Ericson K. The relationship between idiopathic intracranial hypertension and obesity. *Headache* 2009; 49: 178–181.
29. Wall M, Kupersmith MJ, Kiebertz KD, et al. The idiopathic intracranial hypertension treatment trial: clinical profile at baseline. *JAMA Neurol* 2014; 71: 693–701.