

AMYLOIDOSIS AND FEMALE PROTEIN IN THE SYRIAN HAMSTER

Concurrent Regulation by Sex Hormones

BY JOHN E. COE AND MARY JANE ROSS

*From the National Institutes of Health, National Institute of Allergy and Infectious Diseases,
Laboratory of Persistent Viral Diseases, Rocky Mountain Laboratories,
Hamilton, Montana 59840*

Amyloid is a pathological deposit of highly ordered proteinaceous material found in tissues of man and many animals (for review see references 1, 2). Congophilia and green birefringence are diagnostic histological features of amyloid and are caused by the fibril component that is arranged as a β -pleated sheet and characteristically resistant to proteolysis and insoluble in physiological solution. The fibril is the major component, and in human amyloidosis, the fibril can be derived from a variety of serum precursor proteins such as IgL chain, prealbumin, β_2 -microglobulin, and calcitonin. In reactive or secondary amyloidosis of humans, the fibril is composed of another protein called amyloid A (AA)¹ protein, derived from a putative precursor serum protein, apo SAA (3); a similar homologous AA protein is responsible for the fibril component in animal models of amyloidosis except in the senescence-accelerated mouse (4). In most instances the pathogenesis of amyloid has been related to the abnormal expression and accumulation of the serum fibril precursor, which can be either an aberrant protein or a normal protein with excessive synthesis or altered metabolism. In addition to the β -pleated fibril component, amyloid deposits in man and experimental animals also contain another minor protein component that is called amyloid P component (AP) (5, 6) and is derived from a related protein in serum called serum AP (SAP). The role of SAP in amyloid formation is unknown. SAP binds to the fibril in calcium dependent fashion (7), and by this means SAP may simply accumulate in amyloid as a secondary event. However, in the presence of calcium, SAP has been observed to form ordered structures by itself, so that a primary framework role for fibril assembly was proposed for this ubiquitous although minor constituent of amyloid (8). Nevertheless, there is little evidence that SAP actively contributes in a primary fashion to the pathogenesis of amyloid, except for a recent report on amyloidosis of humans (9) where a genetic marker 5' to the SAP gene was linked to a predisposition for reactive amyloidosis in juvenile arthritis.

Amyloidosis in the Syrian hamster is a model in which SAP rather than the fibril precursor may play a critical role in the sex-limited expression of amyloid. In this

¹ *Abbreviations used in this paper:* AA, amyloid A protein; AEF, amyloid-enhancing factor; AP, amyloid P component; DES, diethylstilbestrol; FP, female protein; SAA, serum amyloid A protein; SAP, serum amyloid P component.

species, the homologue of SAP is under sex hormone control so that female hamsters express large amounts (1–3 mg/ml serum) of this protein, called female protein (FP), and serum levels in males are 100–200-fold lower (usually <0.005 mg/ml) (10). From metabolic and mRNA data, these serum levels reflect the relative differences in hepatic synthesis of FP by male and female hamsters (11, 12). Previous studies showed that FP functions like a hamster SAP because FP was found to be a constituent of hamster amyloid, and plasma metabolism of ¹²⁵I-FP was altered in a diagnostic manner in the amyloidotic hamster (13). Although FP is apparently only a minor constituent of amyloid similar to SAP in other species, amyloid deposition is directly related to the high serum levels of FP found in the aging normal female or in the estrogen-treated male (13). Serum levels of FP can be markedly changed in male or female hamsters by exogenous sex steroids. Therefore, this hamster amyloid model provides a unique opportunity to hormonally manipulate the synthesis of one component of amyloid, the SAP homologue, and determine if high rates of FP production are important for amyloid formation. In the present report, the down-regulating effects of testosterone on FP synthesis are used to modulate serum levels of this SAP homologue in male and female hamsters. The results herein substantiate a concurrence between FP synthesis and amyloidosis, indicating that excessive FP production plays a critical role in deposition of amyloid in the Syrian hamster.

Materials and Methods

Animals. Randomly bred Syrian hamsters (*Mesocricetus auratus*) were obtained from Rocky Mountain Laboratory hamster colony and were fed Purina Laboratory Chow and water ad lib.

Histologic Procedures. Tissue from necropsy was examined after sectioning of frozen tissue or of formalin-fixed, paraffin-embedded material. The histologic procedures and the histologic distribution and quantification of amyloid were previously described (13). Also in this study small pieces of fresh tissue from necropsy were squashed between microscope slides and then fixed and stained. Congo red staining (14) was done on histologic sections and on squash preparations of liver, spleen, and kidney and these were examined for typical birefringence by polarization microscopy. If any organ contained detectable amyloid, the animal was counted as amyloidotic; kidney was frequently the last organ to develop detectable amyloid. As a rough quantification of the amount of amyloid in a squash preparation, the ratio of birefringent material to normal tissue was graded from 1⁺ (minimal birefringence found in <1% of tissue area) to 4⁺ (maximal birefringence found in >25% of tissue area).

Amyloid Experiments. Male Syrian hamsters under pentobarbital or ether anesthesia were castrated by excision of the testicle after ligation of spermatic cord. Various modes of long-term testosterone administration were tried; testosterone (Sigma Chemical Co., St. Louis, MO) was administered as a pellet (Innovative Research of America, Toledo, OH) or as contents of a silastic tube (Dow-Corning, Midland, MI) 1.47 mm ID, 25 or 50 mm long, which was closed at both ends by silastic medical adhesive (Dow-Corning) cement. Silastic bags, testosterone pellets, diethylstilbestrol (DES) pellets, (15 mg, Pelletrol; Franklin Laboratories, Denver, CO) and α zearalenol pellets (12 mg, Ralgro; Pitman-Moore, Terre Haute, IN) were surgically implanted subcutaneously in ether anesthetized animals; their presence was verified by gross observation at necropsy. Hamsters, under ether anesthesia, were bled from retro-orbital plexus and serum FP levels were determined by ring diffusion assay as before (10). Because amyloid normally accumulates in the aging Syrian hamster (female >>> male), the animals were routinely 3 mo of age on day 0 of the experiment unless otherwise noted. In each experiment, serum FP levels were monitored at least monthly to determine effectiveness of hormone treatment. In general, pellets and silastic bags provided hormone effect for 3 to 4 mo and in long-term experiments were reimplanted every 3–4 months. The sodium-

caseinate (Difco Laboratories, Detroit, MI) was from the same lot as before and prepared/injected as previously described (13).

Statistical analysis used the Fisher Exact Test.

Results

Studies on Amyloid in Male Syrian Hamsters. Amyloid is a common spontaneous disease in the Syrian hamster and can be found in the female hamster at an earlier age than in the male hamster (13, 15-22). To determine if testicles are responsible for this sex difference in expression of amyloid, male Syrian hamsters were castrated at 6 wk of age and necropsied 10 mo later (11.5 mo of age), when spleen, liver, and kidney were examined for presence of amyloid. Table I compares results from 17 castrated hamsters and 15 control (sham castrated) hamsters. One of 15 controls showed evidence of amyloid, a 6% incidence similar to previous results with normal male hamsters (13). In contrast, a significant ($p = <0.001$) number (15 of 17) of castrated male hamsters had amyloid deposits, an incidence that was similar to that of normal 11-mo-old female hamsters (13). After castration, the level of serum FP rapidly increased, as shown before (23), and at necropsy the average FP concentration was 0.248 mg/ml in serum of castrates (vs. 0.002 mg/ml in control serum). Castrated (or estrogen-treated) male hamsters typically achieve a serum FP level less than half that of normal female hamsters, and serum levels decrease with aging (23).

DES administered to male hamsters promotes deposition of amyloid (13, 15, 20, 24-26). This could be the result of the estrogenic properties of DES or some other unknown toxic or amyloidogenic effect of DES. One of the known estrogenic effects of DES in the male Syrian hamster is involution of testicles with inhibition of testosterone synthesis, and without testosterone, serum FP promptly increases ~50-fold; the serum FP response pattern to DES administration is similar to that seen after castration (23). To determine if testosterone deficiency is the important component for DES induction of amyloidosis, exogenous testosterone was administered to some of the DES-treated male hamsters and the incidence of amyloid was compared (Table II). After 6.5 mo of treatment with DES alone, all 23 male hamsters (100% incidence) showed amyloid deposits. This incidence was significantly ($p = 0.002$) diminished to 60% (9 positive of 15 examined) when testosterone was also administered. FP levels were monitored during the course of the experiment and exogenous testosterone was effective in partial (but not complete) suppression of high FP levels induced by DES. Thus, FP levels were still 10-20-fold higher than normal

TABLE I
*Incidence of Amyloid in Male Syrian Hamsters at 11.5 mo of Age
with/without Castration (at Age 6 wk)*

	Number of animals examined	Presence of amyloid			Incidence	Serum FP at necropsy
		Spleen	Liver	Kidney		
Control	15	1	1	1	6%	0.002 (<0.001-0.005)*
Castrated	17	15	14	14	88%	0.248 (0.001-0.670)

* Mean (range) mg/ml.

in the testosterone-DES group of male hamsters, and the incidence of amyloidosis (9 of 15) was also significantly ($p = <0.001$) greater than that seen in normal controls (3 of 20) (Table II). Quantification of the amount of birefringent amyloid present in tissue squash preparations after Congo red staining indicated that the amount of amyloid infiltrate in all 23 DES-treated animals was distinctly greater (3-4+) than that found in the 9 amyloidotic hamsters in the DES/testosterone treated group (1-2+) (Table II).

In our hands, sodium caseinate injections cause very slow accumulation of amyloid in male Syrian hamsters; however, when combined with DES treatment, the process of amyloid formation is markedly accelerated (13). Using this combination treatment for 4.5 mo, 18 of 21 male hamsters developed amyloid (86%) (necropsy serum FP average 0.58 mg). Another 21 male hamsters received the same combination treatment, and in addition, testosterone (silastic bag day 0, day 90); after 4.5 mo amyloid was found in only 2, a significantly ($p = <0.001$) lower 9.5% incidence (necropsy serum FP level average 0.11 mg/ml). Therefore, testosterone also inhibited amyloid deposition resulting from DES/caseinate treatment.

α Zearalenol is a resorcylic acid lactone compound that has estrogenic activity and that alters hepatic FP synthesis after injection into Armenian hamsters (our unpublished data). When three pellets (12 mg each) were injected into 10 male Syrian hamsters (on day 0, day 90), serum FP levels did not significantly increase, and after 5.5 mo of treatment all animals were histologically negative for amyloid by pathological examination. Thus, zearalenol is an example of an estrogen that does not increase FP synthesis or enhance amyloid formation in male Syrian hamsters.

Studies on Amyloid in Female Syrian Hamsters. The normal female Syrian hamster can acquire amyloid at a younger age and in greater quantity than the normal male hamster; in the RML hamster colony, amyloid is detectable in most normal female hamsters that are more than 1 yr old (13). The 100-200-fold greater levels of serum FP in female as compared with male hamsters can be lowered in female hamsters by treatment with testosterone. To determine if female hamsters with low FP levels acquired less amyloid with aging, testosterone was administered on a long-term basis to otherwise normal female hamsters, and they were killed at various ages to determine at what age amyloidosis was first detected. Fig. 1 shows results of an experiment in which 2-mo-old female hamsters were implanted with silastic bags (with or without testosterone) on day 0 and reimplanted with similar bags at 4, 6, 10, and 15 mo. Individual hamsters were monitored for serum FP levels during the experiment and groups of animals were necropsied at various times (11, 13, 15, 17, and 21 mo of treatment). Serum FP concentration was suppressed in the testosterone-treated groups, although FP levels were rarely as low as that found in normal males. Examination of tissues obtained at necropsy indicated that amyloid was present in all the control female hamsters after 11 mo or more treatment (13 mo or more of age); however, no amyloid was found in the testosterone-treated groups after 11 mo or 13 mo treatment. After 15 mo of treatment (17 mo of age), three of four hamsters were still nonamyloidotic, and even after 21 mo of treatment (23 mo old) one female hamster was free of amyloid. Normal female hamsters more than 1 yr old without detectable amyloid deposits in liver, spleen, or kidney are rarely found in our colony. Also, normal female hamsters living 23 mo are unusual, and all of the control group females were dead by 23 months of age. In addition, there was a distinct difference

TABLE II
Effect of Testosterone on DES-induced Amyloidosis in Male Syrian Hamsters

DES*	Treatment Testosterone†	Serum FP during experiment after the following months of treatment			Amyloid incidence after 6.5 mo treatment				
		3.0	4.5	6.5	Spleen	Liver	Kidney	Percent	Amount
+	0	0.46 [‡] (0.22-0.89)	0.53 (0.21-1.14)	0.62 (0.36-0.88)	23/23	21/23	18/23	100%	3-4 +
+	+	0.07 (0.011-0.30)	0.108 (<0.001-0.290)	0.160 (0.015-0.58)	9/15	6/15	6/15	60%	1-2 +
0	0	0.007 (<0.001-0.03)	0.007 (<0.001-0.014)	0.008 (<0.002-0.021)	3/20	0/20	3/20	15%	1 +

Male Syrian hamsters were 3 mo old at start of experiment.

* DES pellet (15 mg) on day 0, 120.

† Testosterone pellet (40 mg) on day 0, 120.

‡ Mean mg/ml (range).

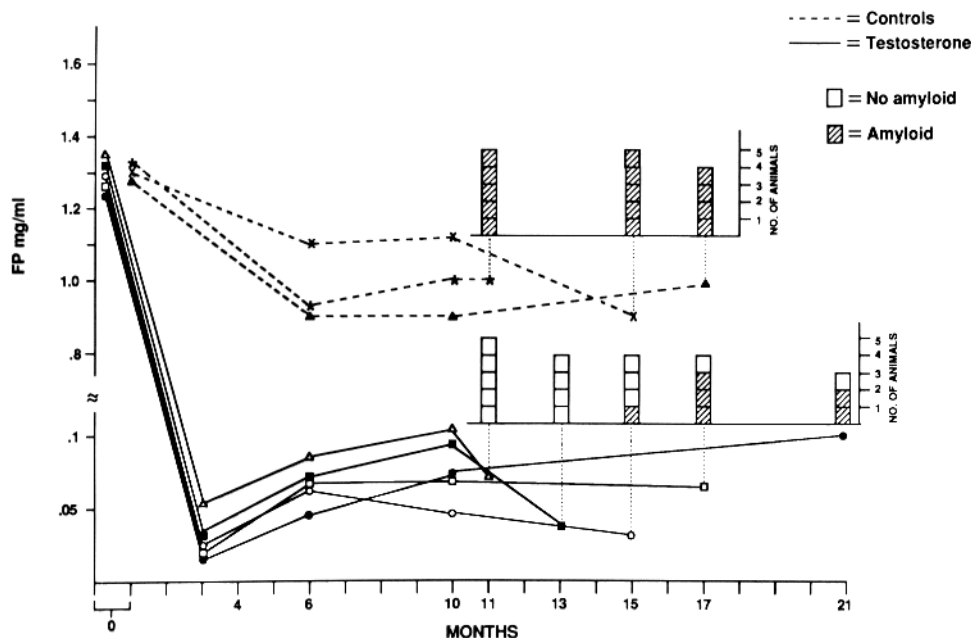


FIGURE 1. Effect of chronic testosterone treatment on development of amyloid in aging female Syrian hamsters. On day 0, 2-mo-old female hamsters were given a silastic bag (25 × 1.45 mm) either containing testosterone (—) or without testosterone, controls (---). A similar silastic bag was reimplanted subsequently on month 4, 6, 10, and 15 of experiment and individual serum FP levels were monitored. Groups of experimental and control animals were killed at 11, 13, 15, 17, and 21 mo, and the presence of amyloid in tissues of individual animals was evaluated by histological examination. Chronic testosterone treatment diminished serum FP, and diminished incidence of amyloid in aging female hamsters. None of the female control hamsters were alive after 21 mo of the experiment.

in amount of amyloid in the two groups, with very heavy (4+) amyloid deposit in all control animals at 15 and 17 months treatment and only lightly positive (1+) deposits in amyloid-positive hamsters of the testosterone-treated group, even after 17-21 mo of treatment.

In the previous experiment, testosterone treatment was initiated in young (2-mo-old) female hamsters. We also tested for effectiveness of testosterone when treatment was initiated in younger (1-mo-old) and older (3-mo-, 5-mo-old) female hamsters (Table III, top). All female hamsters were pathologically examined at 10 mo of age (5-9 mo of treatment), and amyloid was not detected in any of the 14 testosterone-treated hamsters. In contrast, a significant ($p = <0.001$) number, 10 of 17 (59%), of controls contained detectable amyloid deposits at this age. Thus, testosterone given from 1 to 5 mo of age was effective in retarding the development of amyloidosis in the aging female hamster.

DES will also enhance amyloidosis when injected into female Syrian hamsters. Therefore, long-term testosterone treatment was also used in an attempt to protect the DES-treated female from amyloidosis. The results of four separate experiments indicated that in the presence of DES, testosterone could still partially suppress se-

TABLE III
*Effect of Chronic Testosterone Treatment on Amyloid Development in
 Aging and DES-treated Female Syrian Hamster*

Number of female hamsters	Treatment (duration)	Amyloid incidence				Percent	Serum FP at Necropsy
		Age (mo)	Spleen	Liver	Kidney		
14	T* (5-9 mo)	10	0	0	0	0	0.16 (0.14-0.4)†
17	C [‡] (5-9 mo)	10	10	10	9	59%	0.91 (0.49-1.2)
17	D + T (3 mo)	6	8	4	3	47%	0.3 (0.15-0.63)
23	D [†] (3 mo)	6	20	15	11	87%	0.73 (0.23-1.1)

* Testosterone bag (50 mm) day 0 (×2), day 51 (×1), implanted at age 1 mo (n = 4), 3 mo (n = 3), 5 mo (n = 7).

† Mean (range) FP mg/ml.

‡ Control, plain silastic bag day 0 (×2), day 51 (×1), implanted at age 1 mo (n = 8), 3 mo (n = 5), 5 mo (n = 4).

|| DES pellet (15 mg) + testosterone bag (25 mm) day 0, implanted in 3-mo-old hamsters.

† DES pellet (15 mg) day 0, implanted in 3-mo-old hamsters.

rum FP levels and amyloidosis. Two experiments with similar treatment schedules are compiled in Table III (bottom); after 3 mo of treatment with DES alone (6 mo of age), amyloid incidence was 87% (20/23), whereas with additional testosterone treatment, amyloid incidence was significantly ($p = 0.013$) decreased to 47% (8/17).

Discussion

When compared with other mammals, Syrian hamsters are unique in the following ways; (a) these hamsters have an SAP homologue (FP) that is under sex hormone control (10); (b) female hamsters have the highest normal serum concentration of an SAP homologue, 10-100-fold greater than serum SAP in other mammals (27); (c) amyloidosis is a sex-limited disease, as female hamsters, under normal or experimental conditions, can acquire more amyloid at an earlier age than male hamsters (13, 17, 21, 22); and (d) female hamsters die at an earlier age than male hamsters (16, 17, 21, 22, 28) due to amyloid accumulations (15, 17, 20, 25). We have speculated that these sex-limited phenomena are related to each other, and that the high serum FP level in female Syrian hamster plays a primary role in amyloid deposition in Syrian hamster (13). Such an etiology is tenable because only one of the amyloid constituents, FP, is under sex hormone control. The other component of hamster amyloid, the AA fibril (29), is presumably derived from serum AA (SAA), and SAA is not under sex hormonal control as it is expressed equally in male and female Syrian hamster (30; and Dowton, B., personal communication). Thus, sex-related amyloidosis of Syrian hamster may represent a form of amyloid in which overproduction of the minor amyloid constituent, the SAP homologue, is responsible for deposition of the major component, the AA fibril. As reported herein, experimental manipulation of FP synthesis by hormones provides an opportunity to correlate production of this SAP homologue with amyloid deposition.

The induction of amyloid by administration of DES (or estrogens) to Syrian hamsters (15, 20, 25, 26) is another unique phenomenon that has not been reported in any other species. Our previous studies confirmed this finding and also showed that

DES markedly enhances serum FP concentration in male hamsters (13). DES turns off testosterone synthesis indirectly via a pituitary inhibition; this "chemical castration" stimulates FP synthesis in a manner similar to that found after surgical castration (23). In the present study, testosterone administration abrogated the DES induction of amyloid in both normal and sodium caseinate-injected male Syrian hamsters (provided sufficient testosterone was given to suppress serum FP levels). Therefore, the amyloidogenic effect of DES in male Syrian hamster was related to a paucity of endogenous testosterone. Surgical castration also eliminates testosterone in male Syrian hamsters, and as shown herein, the subsequent increased FP synthesis was associated with early onset of amyloidosis with aging. Kirkman and Yau (28) observed that castration of male Syrian hamsters resulted in a shortened life span when compared with intact male hamsters; they noted that such a result was unusual because orchietomy characteristically promotes longevity in mammals. The results of the present study suggest that the shortened longevity of castrated male hamsters may be related to early onset of amyloidosis in a time frame similar to that found in normal female Syrian hamsters. Not all estrogens have this amyloidogenic effect in male Syrian hamster because α zearalenol, a resorcylic acid lactone compound (31), does not promote amyloid deposition in hamsters. This may be explained by the finding that α zearalenol also does not cause testicular involution or cause increased serum levels of FP in male Syrian hamster, although zearalenol does affect FP synthesis in other hamsters such as Armenian hamster (our unpublished data).

Testosterone also inhibited amyloid accumulations in female Syrian hamsters, provided that sufficient amounts were given to depress serum FP levels. In DES-treated female hamsters, large amounts of testosterone produced only partial (20–50%) suppression of FP serum levels and only partial suppression of amyloid. However, testosterone treatment of otherwise normal female hamsters was more effective in lowering serum FP levels and decreasing amyloid accumulation with aging. Under chronic testosterone treatment alone, all treated female hamsters remained free of amyloid until >14 mo of age and individual 18- and 22-mo-old female hamsters were found to be negative for amyloid. This is a remarkable event considering that in our hamster colony, amyloid is consistently found in normal female hamsters >1 yr old. These treated female hamsters also lived longer than female controls, indicating that chronic testosterone treatment enhanced longevity of female Syrian hamsters.

Testosterone treatment also limited amyloidosis when started in 1-, 2-, or 5-mo-old females. Preliminary data suggest that a slightly lower level of serum FP may be attained by earlier testosterone treatment of female hamsters. Attempts to actually reverse the deposition of amyloid by lowering serum FP levels are currently under investigation. However, this experiment requires a more precise method to quantify amyloid in tissues than the rough estimate used occasionally in the present study. In this report, examinations for amyloid were performed at a time when a positive/negative difference in detectable amyloid was present in experimental and control groups so that quantification was not necessary. However, the rough quantification used occasionally herein was valid due to large differences between groups; for example, when the testosterone-treated female hamster developed amyloid, the deposits were markedly less than normal female hamsters of the same age with high levels of FP.

High FP serum concentration is associated with amyloid deposition; however, it does not appear to be the only factor responsible for amyloidosis of the Syrian hamster. For example, DES is quite amyloidogenic when administered to male hamster but also promotes amyloidosis in female Syrian hamsters, and this occurs without a detectable increase in serum levels of FP; indeed, a modest decrease in serum FP concentration may occur in DES-treated female hamsters (our unpublished data). We have not eliminated the possibility that DES in the female hamster may produce changes in metabolism of FP that are more conducive to amyloidosis. Other factors to consider are the amyloid-promoting factors that have been described in mouse (32) and hamster (33) models. These amyloid-enhancing factors (AEF) are very efficient (injection of relatively small amounts induce amyloid deposits detectable within a few days), and accordingly differ from normal serum FP that is associated with amyloidosis after months of high serum levels. Also, injections of native FP into hamsters have not induced amyloidosis in an AEF fashion (our unpublished results), although a degradation product of FP with characteristics of an enhancement factor has not been ruled out. Finally, the Syrian hamster itself must be considered because this species appears to have a peculiar propensity for amyloidosis; although this disease is especially prominent in female hamsters, it is also found in normal aging male hamsters with low levels of serum FP (13). In other hamster species amyloid deposits are very rare. For example, the Armenian hamster also has a circulating female protein, with levels 10-fold greater than those found in the serum of male Syrian hamsters, yet amyloidosis is not found in the aging (and long-lived) Armenian hamster (our unpublished data).

A wide variety of pathophysiological events have been cited as etiologic in amyloidosis. This disease is certainly multifactorial also in the Syrian hamster; however, the unique sex association of amyloid in this species indicates that sex hormones are etiologically important and, as shown herein, testosterone does diminish amyloidosis presumably by decreasing synthesis of FP, a minor constituent of amyloid. Excessive synthesis of FP, the P component homologue, is a critical factor for the deposition of amyloid in the aging Syrian hamster.

Summary

Previous results have shown that when compared to male Syrian hamsters, female Syrian hamsters have a distinct predisposition to acquire amyloidosis either normally with aging or experimentally with sodium caseinate or diethylstilbestrol (DES) treatments. In the present study, we tested the influence of testosterone on expression of amyloid to determine if this hormone was solely responsible for the sex-limited amyloidosis of the Syrian hamster. Males deprived of testosterone by castration acquired amyloid at an unusually young age, an age of onset similar to that in female hamsters. Also, the amyloidogenic effect of DES in male Syrian hamsters was inhibited by concomitant injections of testosterone, indicating that estrogens induce amyloid in male hamsters by inhibiting testosterone synthesis. When administered to female hamsters, testosterone inhibited expression of amyloid in aging female Syrian hamsters and extended the life span of this gender. Of the two components of amyloid, the major component Amyloid A-derived fibril or the minor constituent, Amyloid P component, only the P component is under sex hormone control in the

Syrian hamster; testosterone inhibits the hepatic synthesis of the P component homologue (called female protein), which is normally expressed 100–200-fold greater in female vs. male Syrian hamster. In general, the serum level of female protein under various experimental conditions correlated with the presence of amyloid and indicated that in the Syrian hamster the P component homologue is of primary importance in the deposition of amyloid.

The authors are grateful to Dr. Bill Hadlow for preparation and examination of histological sections, and to Irene Cook Rodriguez for preparation of manuscript.

Received for publication 30 October 1989 and in revised form 4 January 1990.

References

1. Glenner, G. G. 1980. Amyloid deposits and amyloidosis: the beta-fibrilloses (first of two parts). *N. Engl. J. Med.* 302:1283.
2. Husby, G., and K. Sletten. 1986. Chemical and clinical classification of amyloidosis. *Scand. J. Immunol.* 23:253.
3. Benditt, E. P. 1986. Amyloid protein AA and its precursor, the acute phase protein(s) Apo SAA: a perspective. In *Amyloidosis*. J. Marrink and M. H. Van Rijswijk, editors. Morimus Nijhoff Publishers, Dordrecht. 101–106.
4. Higuchi, K., A. Matsumura, K. Hashimoto, A. Honma, S. Takeshita, M. Hosokawa, K. Yasuhira, and T. Takeda. 1983. Isolation and characterization of senile amyloid-related antigenic substance (SAS_{SAM}) from mouse serum: APO SAS_{SAM} is a low molecular weight apoprotein of high density lipoprotein. *J. Exp. Med.* 158:1600.
5. Cathcart, E. S., I. R. Comerford, and A. S. Cohen. 1965. Immunologic studies on a protein extracted from human secondary amyloid. *N. Engl. J. Med.* 273:143.
6. Bladen, H. A., M. V. Nylen, and G. G. Glenney. 1966. The ultrastructure of human amyloid as revealed by the negative staining technique. *J. Ultrastruct. Res.* 14:449.
7. Pepys, M. B., R. F. Dyck, F. C. deBeer, M. Skinner, and A. S. Cohen. 1979. Binding of serum amyloid P-component (SAP) by amyloid fibrils. *Clin. Exp. Immunol.* 38:284.
8. Painter, R. H., I. DeEscallon, A. Massey, L. Pinteric, and S. B. Stern. 1982. The structure and binding characteristics of serum amyloid protein. *Ann. NY Acad. Sci.* 389:199.
9. Woo, P., J. O'Brien, M. Robson, and B. M. Ansell. 1987. A genetic marker for systemic amyloidosis in juvenile arthritis. *Lancet.* ii:767.
10. Coe, J. E., S. S. Margossian, H. S. Slayter, and J. A. Sogn. 1981. Hamster female protein. A new pentraxin structurally and functionally similar to C-reactive protein and amyloid P component. *J. Exp. Med.* 153:977.
11. Coe, J. E., and M. J. Ross. 1983. Hamster female protein. A divergent acute phase protein in male and female Syrian hamsters. *J. Exp. Med.* 157:1421.
12. Downton, S. B., D. E. Woods, E. C. Mantzouranis, and H. R. Colten. 1985. Syrian hamster female protein: analysis of female protein primary structure and gene expression. *Science (Wash. DC).* 228:1206.
13. Coe, J. E., and M. J. Ross. 1985. Hamster female protein, a sex limited pentraxin, is a constituent of Syrian hamster amyloid. *J. Clin. Invest.* 76:66.
14. Puchtler, H., F. Sweat, and M. Levine. 1962. On the binding of Congo red by amyloid. *J. Histochem. Cytochem.* 10:355.
15. Dontenwill, W., H. Ranz, and U. Mohr. 1960. Experimentelle untersuchungen zur amyloidenstehung beim goldhamster. *Beitr. Pathol. Anat.* 122:390.
16. Birt, D. F., and P. M. Pour. 1983. Influence of dietary fat on spontaneous lesions of Syrian golden hamsters. *J. Natl. Cancer Inst.* 71:401.

17. Schmidt, R. E., R. L. Eason, G. B. Hubbard, J. T. Young, and D. L. Eisenbrandt. 1983. Pathology of Aging Syrian Hamsters. CRC Press, Inc., Boca Raton, Florida. 219-242.
18. Dunham, L. J., and K. M. Herrold. 1962. Failure to produce tumors in the hamster cheek pouch by exposure to ingredients of betel nut: histopathologic changes in the pouch and other organs by exposure to known carcinogens. *J. Natl. Cancer Inst.* 29:1047.
19. Gleiser, C. A., G. L. Van Hoosier, W. G. Sheldon, and W. K. Read. 1971. Amyloidosis and renal paramyloid in a closed hamster colony. *Lab. Anim. Sci.* 21:197.
20. Handler, A. H., and F. C. Chesterman. 1968. Spontaneous diseases. In *The Golden Hamster, Its Biology and Use in Medical Research*. R. A. Hoffman, P. F. Robinson, and H. Magalhaes, editors. Iowa State University Press, Ames, IA. 209-213.
21. McMartin, D. N. 1979. Morphologic lesions in aging Syrian hamsters. *J. Gerontol.* 34:502.
22. Dontenwill, W., H.-J. Chevalier, H.-P. Harke, U. Lafrenz, G. Reckzeh, and B. Schneider. 1974. Die generalisierte amyloidose des Syrischen goldhamsters bei chronischen Beräuchungsversuchen. *Z. Versuchstierkd.* 16:75.
23. Coe, J. E. 1977. A sex-limited serum protein of Syrian hamsters: definition of female protein and regulation by testosterone. *Proc. Natl. Acad. Sci. USA.* 74:730.
24. Coe, J. E. 1986. Amyloid and female protein: sex-related occurrence in the Syrian hamster. In *Amyloidosis*. J. Marrink, and M. H. Van Rijswijk, editors. Martinus Nijhoff Publishers, Dordrecht, The Netherlands. 341-346.
25. Franks, L. M., and F. C. Chesterman. 1957. Adrenal degeneration and tumor formation in the golden hamster following treatment with stilboestrol and methylcholanthrene. *Br. J. Cancer.* 11:105.
26. Russfield, A. B., and M. N. Green. 1965. Serum protein patterns associated with amyloidosis in the Syrian hamster. *Am. J. Pathol.* 46:59.
27. Coe, J. E. 1983. Homologs of CRP: a diverse family of proteins with similar structure. In *Contemp. Top. Mol. Immunol.* 9:211.
28. Kirkman, H., and P. K. S. Yau. 1972. Longevity of male and female, intact and gonadectomized, untreated and hormone-treated, neoplastic and non-neoplastic Syrian hamsters. *Am. J. Anat.* 135:205.
29. Linke, R. P., P. R. Hol, E. Gruys, O. Geisel, W. B. J. Nathrath, and G. Trautwein. 1984. Immunohistochemical identification and crossreactions of amyloid-A fibril protein in man and eleven other species. *J. Comp. Pathol.* 94:339.
30. Webb, C. W., P. W. Tucker, and S. B. Dowton. 1989. Expression and sequence analysis of serum amyloid A in the Syrian hamster. *Biochemistry.* 28:4785.
31. Wilson, M. E., and W. M. Hagler. 1985. Metabolism of zearalenone to a more estrogenically active form. In *Estrogens in the Environment. II. Influences on Development*. J. A. McLachlan, editor. Elsevier Science Publishing, New York. 238-248.
32. Axelrad, M. A., R. Kisilevsky, J. Willmer, S. J. Chen, and M. Skinner. 1982. Further characterization of amyloid-enhancing factor. *Lab. Invest.* 47:139.
33. Niewold, T. A., P. R. Hol, A. C. J. van Andel, E. T. G. Lutz, and E. Gruys. 1987. Enhancement of amyloid induction by amyloid fibril fragments in hamster. *Lab. Invest.* 56:544.