



Case Report

Urticaria-like decompression illness in a caisson worker treated successfully in a monoplace chamber

Komugi Okeya,¹  Shinya Suzuki,² Yasuaki Koyama,¹  and Yoshiaki Inoue¹

¹Department of Emergency & Critical Care Medicine, University of Tsukuba Hospital, Ibaraki, Japan, and

²Department of Emergency Medicine, Kameda Medical Center, Kamogawa, Japan

Background: Although decompression illness is rare for nondivers, it can happen in an environment involving rapid decompression. Recompression is the recommended treatment. We herein report a decompression illness case with cutis marmorata and osteonecrosis in both legs during pneumatic caisson work.

Case Presentation: A 59-year-old compressed air worker suffered sudden dyspnea during pneumatic caisson work. He had rash on his trunk and limbs. He was diagnosed with decompression illness, and hyperbaric oxygen therapy was performed twice. He had no neurological dysfunction nor sequelae on discharge, but magnetic resonance imaging follow-up revealed osteonecrosis in both legs.

Conclusion: A detailed medical history should be taken when treating patients with dyspnea at work. Cutis marmorata often precedes more severe symptoms. Early introduction of hyperbaric oxygen therapy is desirable.

Key words: Atmosphere exposure chambers, cutis marmorata, decompression sickness, hyperbaric oxygen therapy, osteonecrosis

INTRODUCTION

DECOMPRESSION ILLNESS IS a result of intravascular or extravascular bubbles that form as a result of decompression.¹ Decompression illness is not a common disease in Japan, although it has been reported in divers, compressed air workers, and aviators, especially in areas where scuba diving is not popular as a tourist attraction. Recompression is the usual recommended treatment.¹ We herein present a decompression illness case caused by working with compressed air under the ground. The patient had dyspnea and rash that looked like urticaria.

CASE PRESENTATION

THE PATIENT WAS a 59-year-old man with no medical history who had sudden dyspnea, vertigo, and chest discomfort during construction work under the ground. The emergency medical team noticed hypoxemia (oxygen saturation [SpO₂] of 79% on room air) when they arrived. The

patient's SpO₂ quickly increased to 100% under 10 L/min of oxygen inhalation with a reservoir face mask. He had stable heart rate (70 bpm), body temperature (36.2°C), respiratory rate (20 bpm), although his blood pressure was slightly low (82/54 mmHg) on the scene. He was transferred to our hospital while continuing oxygen inhalation.

His consciousness was clear, and he was able to appropriately answer questions (Glasgow Coma Scale E4V5M6) on arrival at our hospital. His blood pressure recovered to 111/71 mmHg and heart rate was 71 bpm. His SpO₂ level was 100% under 10 L/min of oxygen inhalation with a reservoir face mask. Respiratory rate was 20 breaths/min. Body temperature was 37.1°C. Physical examination revealed normal light reflex, no conjunctival anemia, no abdominal pain, nor muscular defense. He had an urticaria-like rash on his chest, abdomen, back, and limbs (Fig. 1). On this point, the differential diagnosis was myocardial infarction, pulmonary embolism, or anaphylactic shock. Blood tests showed elevated white blood cell counts (13,100/mm³), D-dimer (10.2 µg/mL), creatine kinase myocardial band (30 µ/L), and C-reactive protein (1.61 mg/dL). The other results did not show remarkable changes. Electrocardiogram showed normal sinus rhythm. Chest x-ray was normal. We did not perform computed tomography or ultrasound examination to diagnose air embolism because of their low evidence for detection of air embolism based on previous reports.^{2,3}

Corresponding: Komugi Okeya, MD, University of Tsukuba Hospital, Department of Emergency & Critical Care Medicine, Ibaraki, Tsukuba, Amakubo, 2 Chome 1-1, 305-8576 Japan. E-mail: komugi_wheat@yahoo.co.jp.

Received 16 Jul, 2022; accepted 17 Nov, 2022

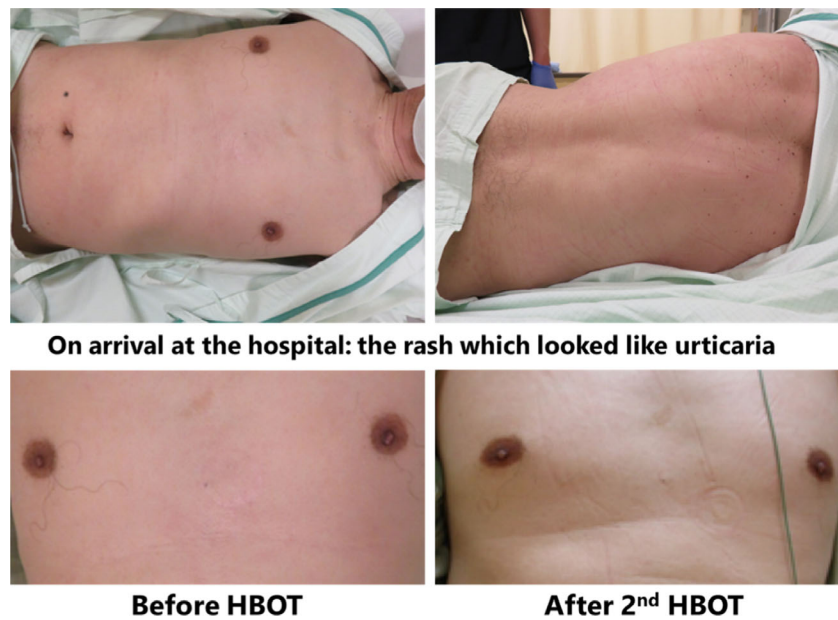


Fig. 1. Characteristic rash of the patient. HBOT, hyperbaric oxygen therapy.

A more detailed medical history was probed, and found that he had engaged in pneumatic caisson work to construct bridge girders under 3.2 atm atmospheric pressure for 90 min. He felt pruritus during his decompression schedule (at 0.4 atm). His chief complaints of sudden dyspnea, vertigo, and chest discomfort occurred 2.5 h after he had finished this decompression schedule (Fig. 2A). We diagnosed his condition as decompression illness based on this medical history and these findings. A schema of his work place is shown in Figure 2B.

The first hyperbaric oxygen therapy (HBOT) was performed 2 h after arrival to the hospital following the confirmation of negative results for coronavirus disease 2019 (COVID-19) polymerase chain reaction. He was treated under the Hart–Kindwall protocol in a monoplace chamber: 2.8 atmosphere absolute (ATA) for 30 minutes, reduction to 2.0 ATA over the course of 30 min, maintenance of 2.0 ATA for 60 minutes, and reduction to 1.0 ATA over the course of 30 minutes (total 2.5 h). He underwent HBOT because his clinical symptoms including rash disappeared completely after the second HBOT. He was discharged from the hospital on day 3 without any symptoms, including skin rash and neurological abnormal findings (Fig. 2C).

After being discharged from our hospital, he was followed by a local clinic doctor, and did not complain of any symptoms. His doctor referred him for magnetic resonance imaging in case the articular surface of his knee had collapsed, which showed osteonecrosis in both femurs and both tibias 7 weeks after his symptom onset (Fig. 3). He was observed

conservatively, and fortunately spends his life without any problems.

DISCUSSION

WHEN ENVIRONMENTAL PRESSURE is reduced rapidly, decompression illness occurs. Intravascular and extravascular bubbles obstruct vasculature as delayed symptoms mechanically, which causes stroke-like signs and symptoms, and activates clotting and inflammatory cascades, which are known as delayed symptoms.¹ Hypoxemia, elevated D-dimer, and a slightly elevated creatine kinase myocardial band were noted in our patient. These findings could have been consistent with these mechanisms.

Decompression illness includes two pathophysiological mechanisms: arterial gas embolism and decompression sickness. Historically, decompression sickness is classified into type 1 and type 2.⁴ Type 1 includes mild cases that only have “bends” and pain in joints and limbs, whereas type 2 is more complicated and involves more severe symptoms in the respiratory or central nervous system. Although the characteristic rash, which spreads irregularly and develops mottled appearances, with areas of pallor surrounded by cyanotic patches (*cutis marmorata*) has been classified into type 1, it often precedes the spinal cord injury, such as paralysis or bladder and rectal disturbances.^{5,6} Some patients with decompression illness with *cutis marmorata* have been reported to have died of multiple organ failure.^{7,8}

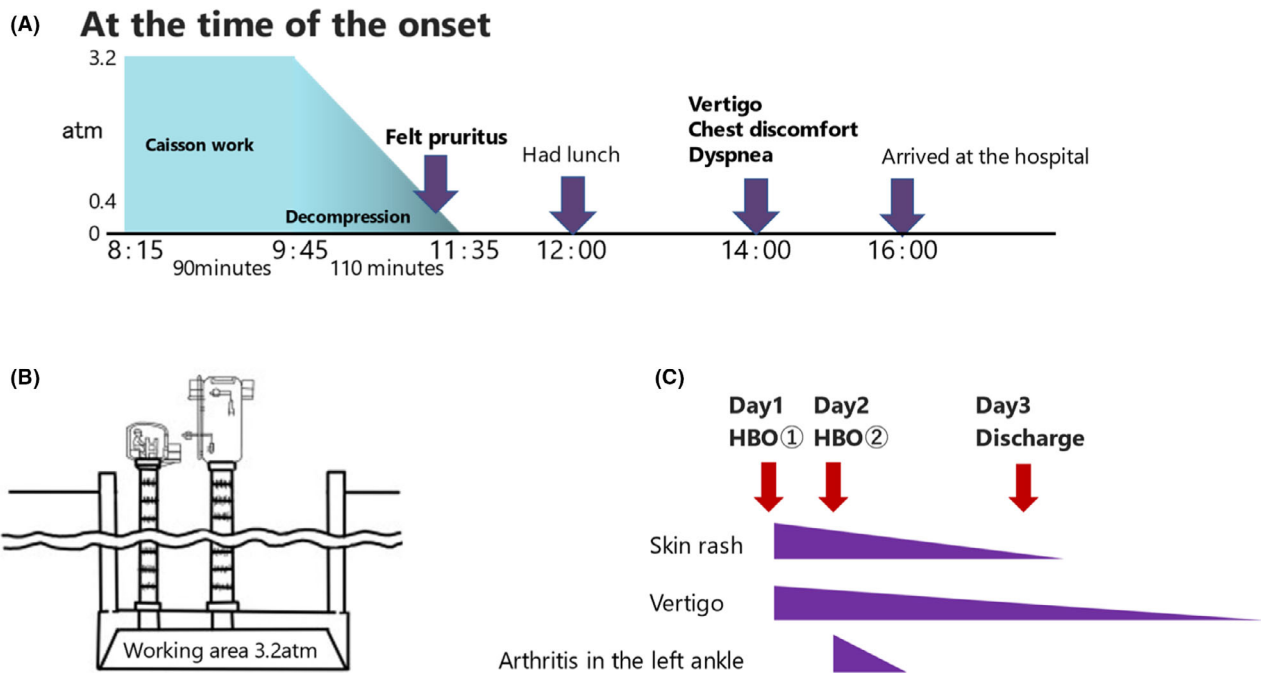


Fig. 2. (A) The medical history of the patient. (B) The schema of pneumatic caisson. (C) The clinical course of the patient after hospitalization. HBOT, hyperbaric oxygen therapy.

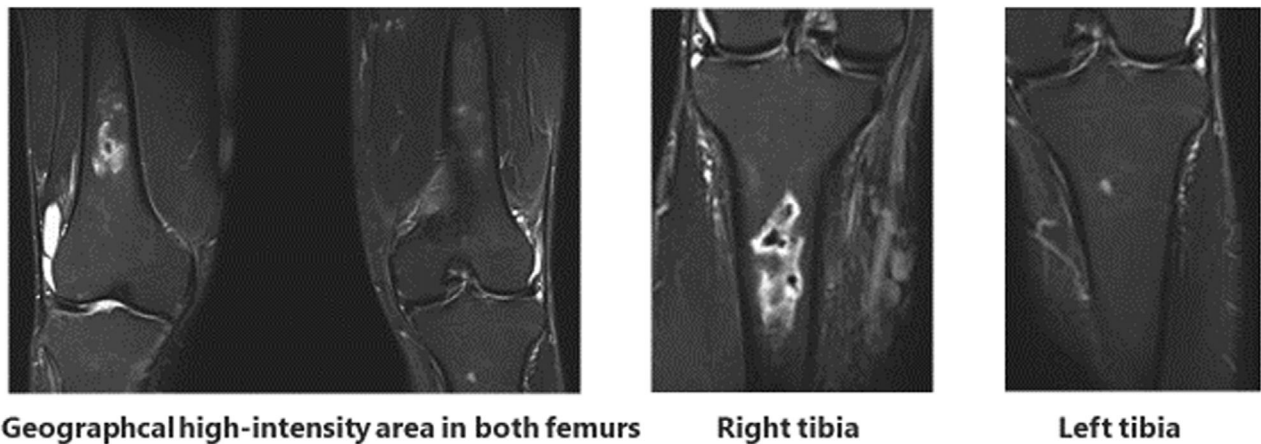


Fig. 3. The magnetic resonance imaging (MRI) images taken 7 weeks from the onset.

In this case, the rash in the chest, abdomen, back, and limbs was not like cutis marmorata, because it was not cyanotic, but we considered the rash to be suggestive of cutis marmorata. The patient could be diagnosed as a severe case, as he suffered sudden dyspnea, vertigo, chest discomfort, and hypoxia (SpO₂ of 79% on room air). The follow-up magnetic resonance imaging revealed osteonecrosis in both femurs and tibias.

The aim of recompression treatment with oxygen is to improve blood flow by compression of bubbles, to rapidly

cease bubbles, to deliver oxygen sufficiently to damaged tissues, and to improve the ischemia–reperfusion injury.¹ For better prognosis, recompression within 2 h from the onset of illness is recommended.⁹ Prompt recompression treatment is needed, because abundant inert gas is contained in the air in caisson work compared with diving. In addition, HBOT is recommended to be repeated until all the symptoms disappear or if there is lack of improvement on 2 consecutive treatments.¹

In this case, we performed HBOT two times as vertigo and rash remained after the first HBOT. All the symptoms

disappeared after the second HBOT and the patient was discharged on that day.

The patient confessed that he had experienced appearance of the rash and pain in both knees and ankles several times during and after his compressed air work in follow-up consultations. He had not consulted with a doctor nor was treated with appropriate decompression as the rash had disappeared over time, and he had considered himself as a mild case. This might have made him more likely to relapse, and several episodes might have caused formation of the osteonecrosis.

Multiple chamber treatments are recommended in severe decompression illness. This is to reduce the risk of oxygen toxicity and easier access to the patients with sudden clinical change, compared with monoplace chambers.¹ We performed the Hart–Kindwall protocol in the monoplace chamber, as our hospital only had this chamber. We successfully treated the patient without any adverse events. The effectiveness of the Hart–Kindwall protocol is shown in another report.¹⁰ The mining work that this patient engaged in is quite popular in Japan. Therefore, decompression illness can occur ubiquitously in Japan. As previously stated, the prompt introduction of the treatment is desirable. Treatment with the Hart–Kindwall protocol with a monoplace chamber should be considered in cases with a long travel time to a facility with multiple chambers.

CONCLUSION

THE PATIENT WAS treated for decompression illness induced by compressed air work and he recovered without any neurological sequelae. Obtaining an appropriate and detailed medical history can help diagnose decompression illness when treating patients who complain of dyspnea at work. Cutis marmorata often precedes more severe symptoms involving the central nervous system and the prompt introduction of HBOT is desirable.

DISCLOSURE

APPROVAL OF THE Research Protocol with Approval No. and Committee Name: N/A.

Informed Consent: Written informed consent was obtained from the patient for the publication of this case report and any accompanying images.

Registry and the Registration No. of the Study/Trial: N/A.

Animal Studies: N/A.

Conflict of Interest: None.

ACKNOWLEDGMENTS

NONE.

FUNDING INFORMATION

NO FUNDING INFORMATION provided.

REFERENCES

- Vann RD, Butler FK, Mitchell SJ, Moon RE. Decompression illness. *Lancet* 2011; 377: 153–64.
- Benson J, Adkinson C, Collier R. Hyperbaric oxygen therapy of iatrogenic cerebral arterial gas embolism. *Undersea Hyperb. Med.* 2003; 30: 117–26.
- Moon RE. Hyperbaric treatment of air or gas embolism: current recommendations. *Undersea Hyperb. Med.* 2019; 46: 673–83.
- Golding FC, Griffiths P, Hempleman HV *et al.* Decompression sickness during construction of the Dartford tunnel. *Br. J. Ind. Med.* 1960; 17: 167–80.
- Navy Department. US Navy Diving Manual. Revision 7. Vol 5: Diving Medicine and Recompression Chamber Operations. NAVSEA 0910-LP-115-1921. Washington, DC: Naval Sea Systems Command, 2016.
- Kalenzos VN. Images in clinical medicine. Cutis marmorata in decompression sickness. *N. Engl. J. Med.* 2010; 362: e67.
- Oode Y, Yanagawa Y, Inoue T, Oomori K, Osaka H, Okamoto K. Cutaneous manifestation of decompression sickness: cutis marmorata. *Intern. Med.* 2013; 52: 2479.
- Doi H, Asamoto S, Arai Y. [Treatment of severe decompression sickness in general hospital] Ippan byouinn ni okeru jyuusyuu gennatsusyuu ni taisuru tiryoukeikenn (in Japanese). *J. Japan Soc. Hyperb. Undersea Med.* 2020; 55: 26–33.
- Thalman ED. Principles of U.S. Navy recompression treatments for decompression sickness. 45th Workshop of UHMS, 1996: 75–95.
- Cianci P, Slade JB Jr. Delayed treatment of decompression sickness with short, no-air-break tables: review of 140 cases. *Aviat. Space Environ. Med.* 2006; 77: 1003–8.