

[CASE REPORT]

Fulminant Respiratory Failure Caused by Anti-asparaginyl tRNA Synthetase (Anti-KS) Antibody Syndrome-related Interstitial Lung Disease

Naohiro Oda¹, Akihiko Taniguchi², Toshiyuki Aokage³, Satoru Senoo², Kenta Nagashima⁴,
Reo Mitani¹, Ichiro Takata¹ and Nobuaki Miyahara²

Abstract:

Anti-asparaginyl transfer RNA (tRNA) synthetase (KS) antibodies, detected in <5% patients with anti-aminoacyl-tRNA synthetase antibody syndrome, are strongly associated with interstitial pneumonia but not myositis and skin symptoms. A recent report suggested that most patients with interstitial pneumonia and anti-KS antibody (KS-ILD) may present with chronic disease. We herein report a rare case of severe acute respiratory failure in a KS-ILD patient requiring extracorporeal membrane oxygenation (ECMO). ECMO is useful for facilitating not only lung rest until recovery but also the definitive diagnosis and treatment of ILD. KS-ILD can develop acutely with fulminant respiratory failure, as observed in this case.

Key words: anti-KS antibody, anti-asparaginyl tRNA synthetase antibody, anti-ARS antibody syndrome, interstitial pneumonia, extracorporeal membrane oxygenation

(Intern Med 61: 3409-3414, 2022)

(DOI: 10.2169/internalmedicine.9239-21)

Introduction

Eight types of anti-aminoacyl-transfer RNA (tRNA) synthetase (ARS) antibodies, including anti-histidyl (Jo-1), anti-threonyl (PL-7), anti-alanyl (PL-12), anti-glycyl (EJ), anti-isoleucyl (OJ), anti-asparaginyl (KS), anti-phenylalanyl (Zo), and anti-tyrosyl (Ha) tRNA synthetase antibodies, have been reported. Patients positive for these antibodies have common clinical symptoms, such as myositis, interstitial pneumonia, a fever, arthritis, Raynaud's symptoms, and mechanic's hand, and are identified as having anti-ARS antibody syndrome. However, anti-ARS antibody-positive cases have also been suggested to exhibit characteristic clinical features (1, 2).

Anti-KS antibodies, detected in less than 5% of patients with anti-ARS antibody syndrome, are strongly associated with interstitial pneumonia but not myositis and skin symptoms (1, 3-5). In previous reports, 98% of patients with anti-

KS antibodies had interstitial pneumonia, which was the sole manifestation in half of them (6). A recent report describing the clinical, radiological, and pathological findings of interstitial pneumonia with anti-KS antibody (KS-ILD) suggested that most patients with KS-ILD may present with chronic disease (7).

We herein report a rare case of severe acute respiratory failure in a patient with KS-ILD requiring extracorporeal membrane oxygenation (ECMO). ECMO is useful not only for facilitating lung rest until recovery but also as a bridge to the definitive diagnosis and treatment of ILD. As observed in our patient, KS-ILD can develop acutely with fulminant respiratory failure.

Case Report

A 70-year-old woman with cold-like symptoms for the past week was admitted to a hospital with a diagnosis of severe pneumonia. The patient was treated with meropenem;

¹Department of Internal Medicine, Fukuyama City Hospital, Japan, ²Department of Allergy and Respiratory Medicine, Okayama University Hospital, Japan, ³Advanced Emergency and Critical Care Medical Center, Okayama University Hospital, Japan and ⁴Emergency Medical Center, Fukuyama City Hospital, Japan

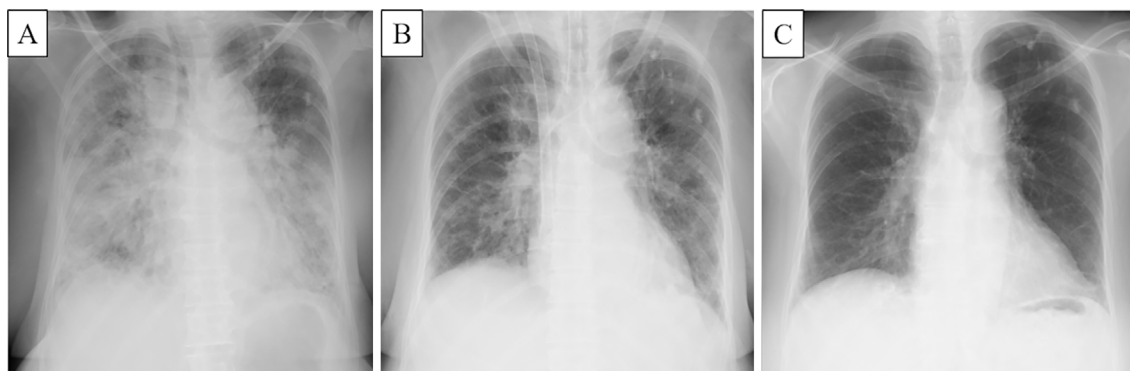
Received: December 17, 2021; Accepted: February 13, 2022; Advance Publication by J-STAGE: April 2, 2022

Correspondence to Naohiro Oda, pgjj77o3@s.okayama-u.ac.jp

Table 1. Laboratory Findings on Admission and Results of Antibody Test.

Hematology		Serology		Antibody test	
White blood cells	23,980 / μ L	Albumin	2.3 g/dL	Anti-RNP antibody	-
Neutrophils	85.2 %	T-Bil	1.2 mg/dL	Anti-SS-A antibody	232 U/mL
Lymphocytes	8.4 %	AST	31 U/L	Anti-SS-B antibody	13.1 U/mL
Monocytes	6 %	ALT	11 U/L	Anti-Scl-70 antibody	-
Eosinophils	0.2 %	ALP	129 U/L	Anti-dsDNA antibody	-
Red blood cells	4.29 \times 10 ⁶ / μ L	LDH	573 U/L	Anti-Centromere antibody	-
Hemoglobin	13 g/dL	BUN	13.8 mg/dL	PR3-ANCA	-
Platelet count	365 \times 10 ³ / μ L	Creatinine	0.44 mg/dL	MPO-ANCA	-
Coagulation		CRP	18.75 mg/dL	Anti-CCP antibody	59 U/mL
Prothrombin time	63 s	Procalcitonin	0.47 ng/mL	Anti-ARS antibody	128.4 index
APTT	50.3 s	CPK	58 U/L	Anti-MDA5 antibody	-
Fibrinogen	486 mg/dL	Ferritin	462 ng/mL	Anti-KS antibody	+
FDP	11.6 μ g/mL	KL-6	388 U/mL	Anti-Ro52 antibody	+
D-dimer	4.7 μ g/mL	SP-D	292 ng/mL		

APTT: activated partial thromboplastin time, FDP: fibrin degradation product, T-Bil: total bilirubin, AST: aspartate aminotransferase, ALT: alanine aminotransferase, ALP: alkaline phosphatase, LDH: lactate dehydrogenase, BUN: blood urea nitrogen, CRP: C-reactive protein, CPK: creatine kinase, KL-6: Krebs von den Lungen-6, SP-D: surfactant protein-D, RNP: ribonucleoprotein, SS: Sjögren's syndrome, Scl-70: topoisomerase I, dsDNA: double-stranded deoxyribonucleic acid, PR3-ANCA: proteinase-3-anti-neutrophil cytoplasmic antibody, MPO-ANCA: myeloperoxidase-anti-neutrophil cytoplasmic antibody, CCP: cyclic citrullinated peptide, ARS: aminoacyl-tRNA synthetase, MDA5: melanoma differentiation-associated protein 5, KS: asparaginyl-tRNA synthetase

**Figure 1. Chest X-ray findings on the 2nd (A), 8th (B), and 39th (C) day of hospitalization.**

however, her respiratory condition deteriorated, and the patient was transferred to our hospital for intensive care on the second day of hospitalization. The patient was a non-smoker and presented with a history of hypertension and pulmonary tuberculosis. She had never before presented with clinical symptoms or chest X-ray findings suggestive of interstitial pneumonia.

A physical examination revealed Glasgow Coma Scale E3 V1M5, a fever (37.7°C), tachycardia (144 bpm), hypertension (172/90 mmHg), tachypnea (46 breaths per minute), and weak crackles in both lungs. Her oxygen saturation measured using a pulse oximeter under manual ventilation with the Jackson-Rees circuit was 70-80%, and the patient was intubated. The blood test results were as follows: white blood cells, 23,980/ μ L; neutrophils, 20,430/ μ L; hemoglobin, 13.0 g/dL; platelet count, 365,000/ μ L; D-dimer, 4.7 μ g/mL; albumin, 2.3 g/dL; creatine kinase, 58 U/L; aspartate aminotransferase, 31 U/L; lactate dehydrogenase, 573 U/L; creatinine, 0.44 mg/dL; blood urea nitrogen, 13.8 mg/dL; C-

reactive protein, 18.75 mg/dL; procalcitonin, 0.47 ng/mL; ferritin, 462 ng/mL; Krebs von den Lungen-6 (KL-6), 388 U/mL; and surfactant protein-D (SP-D), 292 ng/mL (Table 1). Chest X-ray showed consolidation in both lungs (Fig. 1). Chest computed tomography (CT) revealed diffuse ground-glass opacities (GGOs) and consolidation in both lungs, suggesting diffuse alveolar damage (DAD) (Fig. 2A-C). Sputum gram staining, sputum and blood culture, urinary antigen tests for *Streptococcus pneumoniae* and *Legionella*, and an antigen test for influenza using nasopharyngeal swabs were all negative. Broad-spectrum antibiotic therapy (meropenem, vancomycin, azithromycin, and peramivir) was initiated to treat suspected severe pneumonia.

As her partial pressure of arterial oxygen/fraction of inspiratory oxygen (FIO₂) ratio was 95.5 under mechanical ventilation (FIO₂, 1.0; positive end expiratory pressure, 10 cmH₂O; and pressure control, 20 cmH₂O) with muscle relaxants, the patient was transferred to advanced critical care at another hospital's emergency center, and veno-venous

Table 2. Results of BAL Fluid Analysis.

Color	Pale and bloody
Cell count	27.2×10 ⁴ /mL
Neutrophils	35 %
Macrophages	18 %
Eosinophils	0 %
Lymphocytes	47 %
CD4/8 ratio	0.2

ECMO was started for severe acute respiratory distress syndrome (ARDS). On the fifth day of hospitalization, bronchoalveolar lavage (BAL) was performed. The cell count in the BAL fluid was 27.2×10⁴/mL, with 35% neutrophils, 18% macrophages, 0% eosinophils, and 47% lymphocytes with a cluster of differentiation (CD) 4/CD8 ratio of 0.2 (Table 2). A multiplex polymerase chain reaction test for respiratory pathogens (influenza virus, coronavirus, parainfluenza virus, human metapneumovirus, adenovirus, respiratory syncytial virus, human rhinovirus, enterovirus, *Mycoplasma pneumoniae*, *Chlamydomphila pneumoniae*, and *Bordetella pertussis*) using the BAL fluid was negative. A transbronchial lung biopsy was not performed because of concerns of bleeding complications. Further workup revealed positivity for anti-ARS antibodies (128.4 index), anti-Sjögren's syndrome (SS)-A antibodies (232 U/mL), anti-SS-B antibodies (13.1 U/mL), and anti-cyclic citrullinated peptide antibodies (59 U/mL). The sample was negative for anti-melanoma differentiation-associated protein 5 (MDA5) antibodies. Protein and RNA immunoprecipitation revealed anti-KS antibodies and anti-Ro52 antibodies (Table 1). Chest CT revealed that the GGOs in both upper lobes and consolidation in both lower lobes were reduced (Fig. 2D-F).

On the ninth day of hospitalization, ECMO was terminated. The patient had no symptoms of muscle weakness, arthritis, Raynaud's symptoms, or skin manifestations. Anti-ARS antibody syndrome was diagnosed, and treatment with prednisolone (50 mg, 1 mg/kg) was initiated for interstitial lung disease (ILD) on the 10th day of hospitalization. On the 12th day of hospitalization, the patient was transferred to our hospital again. On the 16th day of hospitalization, the patient was extubated. Chest CT revealed residual reticular shadows in both lower lobes on the 39th day (Fig. 2G-I). On the 44th day, the patient was discharged. Thereafter, the patient was diagnosed with Sjögren's syndrome based on positive fluorescein staining test results during an ocular examination, the production of <5 mm of tears over 5 min during Schirmer's test, and anti-SS-A- and anti-SS-B-positive titers.

Although prednisolone was tapered to 8 mg, cyclosporine was added because of gradual exacerbation of ILD, along with elevated serum KL-6 and SP-D levels at 72 weeks after onset (Fig. 3A-C, 4). Fourteen weeks after the addition of cyclosporine, the CT findings improved, and the serum KL-6 and SP-D levels decreased (Fig. 3D, 4).

Discussion

In the present case, ILD caused by an immunological mechanism was suggested based on anti-KS antibody positivity and BAL fluid findings of lymphocyte predominance, and KS-ILD was diagnosed. A detailed microbiological examination revealed no findings suggestive of infection, and the trigger for ARDS was unknown. We believe that KS-ILD can develop acutely with fulminant respiratory failure, as observed in this case.

Based on chest CT or lung biopsy findings, nonspecific interstitial pneumonia (NSIP) and usual interstitial pneumonia (UIP) are the most common ILD patterns in patients with anti-KS antibodies. Among the pathologically diagnosed KS-ILD cases, 67% were NSIP, 26% were UIP, 4% were organizing pneumonia, and 8% were unclassifiable interstitial pneumonia in a previous study (6). The frequency of UIP in patients with anti-KS antibodies was higher than that in patients with antibodies other than anti-ARS. Most patients with KS-ILD responded well to corticosteroids, but some survived with ongoing disease, even without immunosuppressive therapy (6, 7). This suggests that a chronic stable clinical course in patients with KS-ILD is a possible clinical feature. Our patient initially presented with ILD with a DAD pattern on imaging, accompanied by severe acute respiratory failure, which is an atypical clinical feature of KS-ILD.

Shi et al. (2) reported that 36 of 124 (29%) cases of anti-ARS antibody syndrome that did not include anti-KS antibody syndrome were positive for anti-Ro52 antibodies. In their report, rapid progressive interstitial lung disease (RP-ILD) was an important prognostic factor in anti-ARS antibody syndrome, and 8 of 11 patients with RP-ILD were positive for anti-Ro52 antibody. According to a report by Hamaguchi et al. (1), only 1 of 13 (8%) cases of anti-KS antibody syndrome was positive for anti-Ro52 antibodies. Although anti-Ro52 antibodies are rarely positive in patients with anti-KS antibody syndrome, anti-Ro52 antibody positivity may have been associated with severe acute respiratory failure after KS-ILD in this case.

Our patient met the classification criteria for Sjögren's syndrome during her clinical course (8). NSIP is the most common ILD pattern in patients with primary Sjögren's syndrome, and lymphatic interstitial pneumonia is a rare disease but strongly associated with primary Sjögren's syndrome (9). The presence of Sjögren's syndrome in patients with anti-KS antibody syndrome is uncommon, with Hamaguchi et al. (1) reporting Sjögren's syndrome in only 1 of 13 (8%) patients with anti-KS antibody syndrome and Aiko et al. (7) reporting Sjögren's syndrome in only 1 of 19 (5%) patients with anti-KS antibody syndrome. Further research into the impact of Sjögren's syndrome in combination with anti-KS antibody syndrome on ILD is warranted.

The clinical course in half of the dermatomyositis/polyomyositis patients with interstitial pneumonia, including those

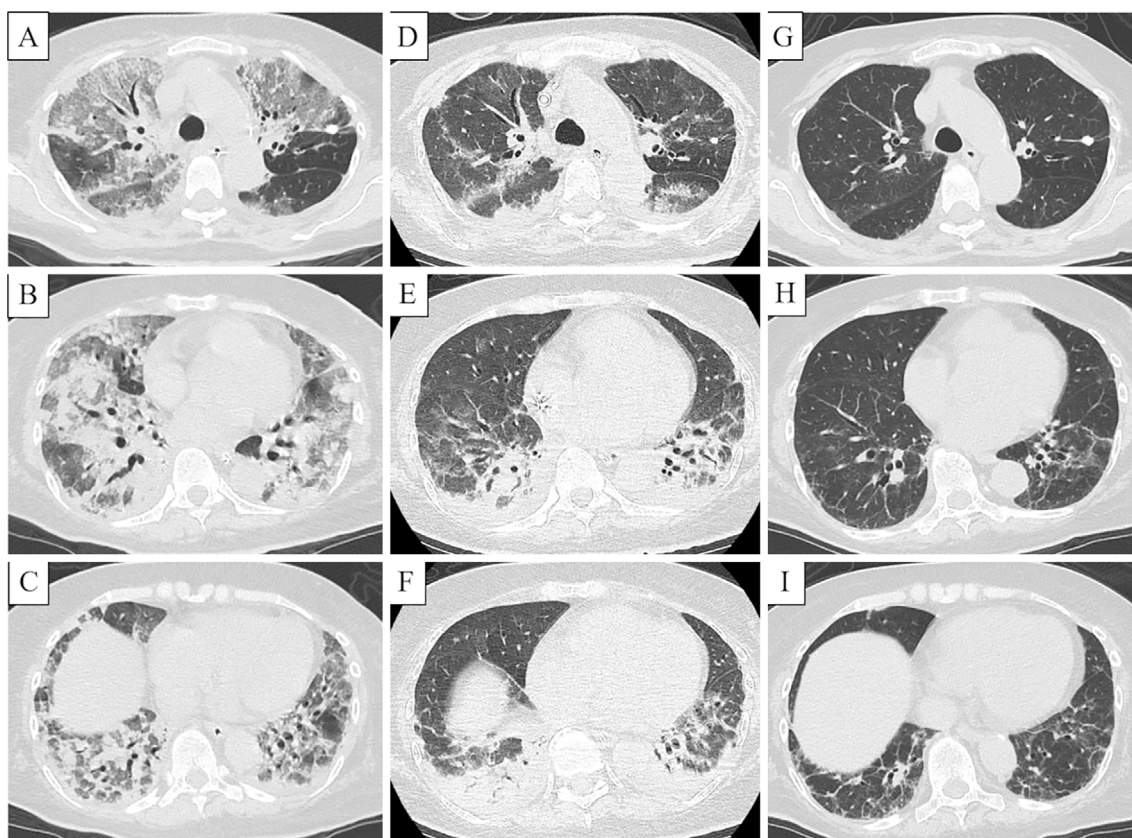


Figure 2. Computed tomography (CT) shows diffuse ground-glass opacities (GGOs) and consolidation in both lungs on the second day of hospitalization (A-C). CT shows that the GGOs in both upper lobes and consolidation in both lower lobes were reduced on the eighth day of hospitalization (D-F). Chest CT shows residual reticular shadows in both lower lobes on the 39th day of hospitalization (G-I).

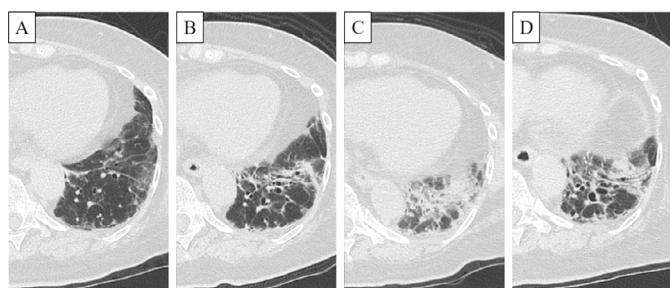


Figure 3. Computed tomography (CT) shows that the reticular shadows in the left lower lobes worsened from 18 weeks (A) to 48 weeks (B) after the onset. CT shows consolidation in the left lower lobes 72 weeks after the onset (C). CT shows that consolidation in the left lower lobes was reduced at 86 weeks after the onset (D).

with anti-ARS antibody syndrome (excluding anti-MDA5 antibody-positive cases), is an acute/subacute onset (10, 11). Although it is important to note that some cases are rapidly progressive and fatal, most cases show improvement or stabilize in the short term with immunosuppressive therapy. However, during long-term management, relapse is common, and fibrosis may gradually develop. Debray et al. (12) reported that more than 30% of patients developed fibrosis on CT over a period of approximately 2 years. Yamakawa et al. (10) also reported that the condition of most patients im-

proved within 1 year of the disease onset, but approximately 1/3 of patients reported relapse or worsening of the condition. In the present case, after recovery from acute respiratory failure, ILD re-exacerbated during tapering corticosteroid doses over one year later, although the addition of cyclosporine stabilized the disease. Even if the initial response to corticosteroid treatment is good in anti-ARS antibody syndrome, the use of calcineurin inhibitors in combination with corticosteroids may be considered for long-term management to prevent fibrotic foci in the chronic phase (11).

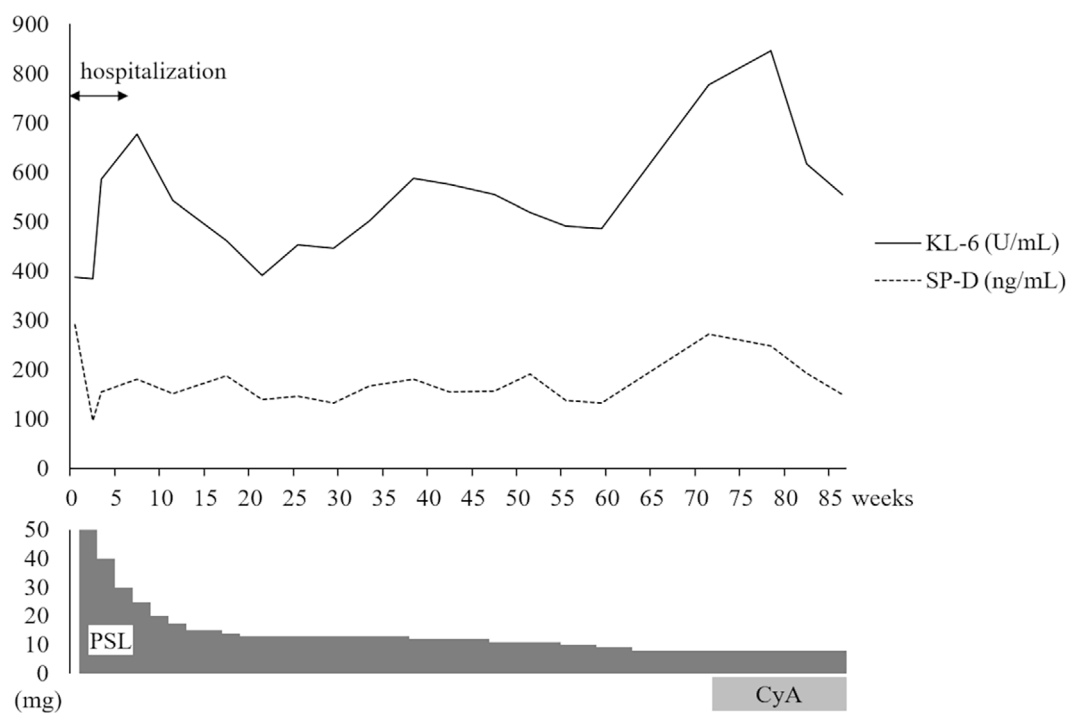


Figure 4. Clinical course. KL-6: Krebs von den Lungen-6, SP-D: surfactant protein-D, PSL: prednisolone, CyA: cyclosporine

The indications for ECMO for acute respiratory failure of ILD should be carefully considered. Acute exacerbation of idiopathic pulmonary fibrosis has a very poor prognosis and should not be considered for ECMO except as a bridge to lung transplantation (13). However, ECMO is important not only for facilitating lung rest until recovery but also as a bridge to a definitive diagnosis and treatment of ILD. There are a series of cases in which acute interstitial pneumonia was diagnosed by BAL and a lung biopsy during respiratory support with ECMO, and appropriate immunosuppressive therapy was administered (14). In the present case, the patient was initially thought to have severe pneumonia but was diagnosed with KS-ILD based on anti-KS antibody positivity and BAL fluid findings with lymphocyte predominance; the patient was then successfully treated with corticosteroids. Anti-ARS antibody syndromes, especially anti-KS antibody syndrome, may be underestimated as an etiology of ILD because these patients often present only with ILD without symptoms of connective tissue diseases. Therefore, clinicians should be aware of anti-ARS antibody syndrome as an important etiology of ILD.

In conclusion, although KS-ILD has been reported to be a chronic disease, it can present with severe acute respiratory failure. The clinical features of KS-ILD need to be further investigated after the accumulation of more cases.

The authors state that they have no Conflict of Interest (COI).

Acknowledgement

We thank Ran Nakashima (Department of Rheumatology and Clinical Immunology, Graduate School of Medicine, Kyoto Uni-

versity, Kyoto, Japan) for measuring the anti-ARS antibody levels.

References

1. Hamaguchi Y, Fujimoto M, Matsushita T, et al. Common and distinct clinical features in adult patients with anti-aminoacyl-tRNA synthetase antibodies: heterogeneity within the syndrome. *PLoS One* **8**: e60442, 2013.
2. Shi J, Li S, Yang H, et al. Clinical profiles and prognosis of patients with distinct antisynthetase autoantibodies. *J Rheumatol* **44**: 1051-1057, 2017.
3. Hirakata M, Suwa A, Nagai S, et al. Anti-KS: identification of autoantibodies to asparaginyl-transfer RNA synthetase associated with interstitial lung disease. *J Immunol* **162**: 2315-2320, 1999.
4. Hirakata M, Suwa A, Takada T, et al. Clinical and immunogenetic features of patients with autoantibodies to asparaginyl-transfer RNA synthetase. *Arthritis Rheum* **56**: 1295-1303, 2007.
5. Schneider F, Aggarwal R, Bi D, Gibson K, Oddis C, Yousem SA. The pulmonary histopathology of anti-KS transfer RNA synthetase syndrome. *Arch Pathol Lab Med* **139**: 122-125, 2015.
6. Ge Y, Li S, Li S, He L, Lu X, Wang G. Interstitial lung disease is a major characteristic of anti-KS associated ant-synthetase syndrome. *Ther Adv Chronic Dis* **11**: 2040622320968417, 2020.
7. Aiko N, Yamakawa H, Iwasawa T, et al. Clinical, radiological, and pathological features of anti-asparaginyl tRNA synthetase antibody-related interstitial lung disease. *Respir Investig* **58**: 196-203, 2020.
8. Fujibayashi T, Sugai S, Miyasaka N, Hayashi Y, Tsubota K. Revised Japanese criteria for Sjögren's syndrome (1999): availability and validity. *Mod Rheumatol* **14**: 425-434, 2004.
9. Ito I, Nagai S, Kitaichi M, et al. Pulmonary manifestations of primary Sjögren's syndrome: a clinical, radiologic, and pathologic study. *Am J Respir Crit Care Med* **171**: 632-638, 2005.
10. Yamakawa H, Hagiwara E, Kitamura H, et al. Predictive factors for the long-term deterioration of pulmonary function in interstitial lung disease associated with anti-aminoacyl-tRNA synthetase anti-

- bodies. *Respiration* **96**: 210-221, 2018.
11. Takei R, Yamano Y, Kataoka K, et al. Predictive factors for the recurrence of anti-aminoacyl-tRNA synthetase antibody-associated interstitial lung disease. *Respir Investig* **58**: 83-90, 2020.
 12. Debray MP, Borie R, Revel MP, et al. Interstitial lung disease in anti-synthetase syndrome: initial and follow-up CT findings. *Eur J Radiol* **84**: 516-523, 2015.
 13. Trudzinski FC, Kaestner F, Schäfers HJ, et al. Outcome of patients with interstitial lung disease treated with extracorporeal membrane oxygenation for acute respiratory failure. *Am J Respir Crit Care Med* **193**: 527-533, 2016.
 14. Gonçalves-Venade G, Lacerda-Príncipe N, Roncon-Albuquerque R Jr, Paiva JA. Extracorporeal membrane oxygenation for refractory severe respiratory failure in acute interstitial pneumonia. *Artif Organs* **42**: 569-574, 2018.

The Internal Medicine is an Open Access journal distributed under the Creative Commons Attribution-NonCommercial-NoDerivatives 4.0 International License. To view the details of this license, please visit (<https://creativecommons.org/licenses/by-nc-nd/4.0/>).