

Journal section: Oral Medicine and Pathology  
Publication Types: Review

doi:10.4317/jced.52860  
<http://dx.doi.org/10.4317/jced.52860>

## Pathogenesis and clinicohistopathological characteristics of melanoacanthoma: A systematic review

Elena Cantudo-Sanagustín <sup>1</sup>, Aída Gutiérrez-Corrales <sup>1</sup>, Manuel Vigo-Martínez <sup>2</sup>, María-Ángeles Serrera-Figallo <sup>1</sup>, Daniel Torres-Lagares <sup>3</sup>, José-Luis Gutiérrez-Pérez <sup>3</sup>

<sup>1</sup> Master in Oral Surgery

<sup>2</sup> Medical Doctor. Diplomate in Dental Surgery. Lecture in Oral Medicine. University of Seville

<sup>3</sup> Professor of Oral Surgery. Co-Head of Master in Oral Surgery. University of Seville

*Correspondence:*

Facultad de Odontología de Sevilla  
C/ Avicena s/n 41009  
Sevilla, SPAIN  
[danielth@us.es](mailto:danielth@us.es)

Cantudo-Sanagustín E, Gutiérrez-Corrales A, Vigo-Martínez M, Serrera-Figallo MA, Torres-Lagares D, Gutiérrez-Pérez JL. Pathogenesis and clinicohistopathological characteristics of melanoacanthoma: A systematic review. J Clin Exp Dent. 2016;8(3):e327-36.  
<http://www.medicinaoral.com/odo/volumenes/v8i3/jcedv8i3p327.pdf>

Received: 22/11/2015  
Accepted: 08/01/2016

Article Number: 52860 <http://www.medicinaoral.com/odo/indice.htm>  
© Medicina Oral S. L. C.I.F. B 96689336 - eISSN: 1989-5488  
eMail: [jced@jced.es](mailto:jced@jced.es)  
**Indexed in:**  
Pubmed  
Pubmed Central® (PMC)  
Scopus  
DOI® System

### Abstract

**Introduction:** The melanoacanthoma is a rare benign pigmented tumor, characterized by a fast radial growth and clinical behavior similar to melanoma. Color changes in oral mucosa and dermis are consequence of increased melanocyte activity as response to an irritant factor. There is a vast phenotypic variety. It is difficult to distinguish between a benign pigmented lesion and a melanoma at its early stage. Due to its clinical relevance is crucial to diagnose possible malignancy of the lesions.

**Objectives:** The aim of this article is to conduct a systematic review of all published articles, as well as update and evaluate etiologic factors and clinicopathological features.

**Material and Methods:** We carried out a search in the Medline database (PubMed) using the key words “oral melanoacanthoma” AND “oral melanoacanthosis” AND “oral melanoepithelioma”. Inclusion criteria were all published articles since its discovery. Demographic data, histological features and immunohistochemical findings were extracted from the full articles.

**Results:** A total of 56 articles were analysed. 114 injuries drawn from these articles were studied, a total of 115 injuries with our contribution case. The 74.78% of authors claim a reactive pathogenesis. The average age of lesion appearance is 34.79 years, with an age range of 5-87 years. There is a predominance of the female sex in solitary phenotype 3: 2 and a ratio of women to men 5: 3 if it is multifocal phenotype. Bilateral phenotype is slight higher in women of 2: 1.

**Conclusions:** Histopathological analysis of the lesión is vital to diagnose malignancy. Therefore, any heterogeneous, pigmented lesion with irregular edges, raised surface, fast growth and abrupt appearance should be biopsied. More emphasis on the potential irritants should also be put to improve the quality of life of our patients and to reduce morbidity of melanoacanthoma, as well as, several similar clinical behavior disease.

**Key words:** Melanoacanthoma, oral cancer, diagnosis.

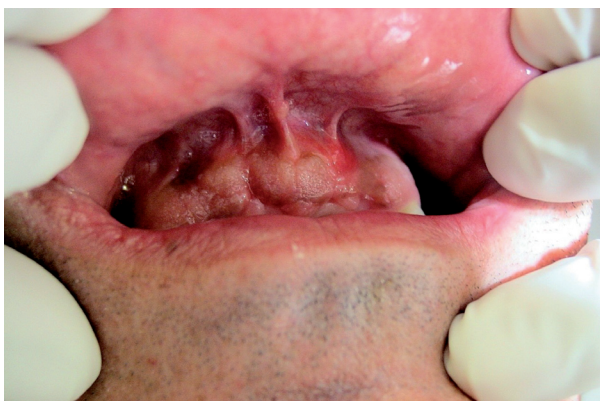**Introduction**

Melanoacanthoma was first described by Bloch in 1926 as melanoepithelioma. In 1960, Mishima and Pinkus introduced the term melanoacanthoma to clarify the term melanoepithelioma type 1 and 2 previously described by Bloch in 1927 (1). The term melanoacanthoma corresponds to Bloch’s melanoepithelioma type 1. First lesion in the oral mucosa was presented by Tomey and Dorey in the Maxilofacial and Oral Pathology Congress of the American Academy, in 1978. According to this revision, Schneider *et al.* described their first case in 1981 (2). Since then, solitary and, less frequent, multiple lesions have been described in the oral mucosa with a total number of 115 cases to the date in our search.

Melanoacanthoma is a rare benign mixed epithelial tumor, characterized by the mucocutaneous pigmentation with dendritic melanocytes dispersed among the epithelium with acanthosis areas, espongiosis on melanocyte presence. The presence of inflammatory infiltration of lymphocytic and eosinophils is a common find (3,4).

The high of incidence is between the third or fourth decade, it shows higher prevalence in black race and women although some cases were reported in Caucasia race.

Lesions may occur as isolated or multiple, planned or raised, with well defined or diffuse edges and the color ranges from dark brown to black. There have been described multiple cases and others with bilateral lesion (Fig. 1). Melanoacanthoma lesions can be asymptomatic or develop with pain, burning or itching. Its etiology is related to irritative or traumatic factors (5).



**Fig. 1.** Histological images of the pyogenic granuloma showing an appearance similar to granulation tissue. The histological type of the pyogenic granuloma is non-lobular capillary hemangioma. Arrow heads label blood vessels surrounded by connective tissue.

Cutaneous melanoacanthoma are more likely to appear in head, neck and chest and less frequently in the eyelids or lips. Intraoral lesions are usually asymptomatic and preferentially located in the buccal mucosa (47.54%), palate (18.03%), lips (11.47%) and gum (5.6%) (6). While cutaneous melanoacanthoma never disappear,

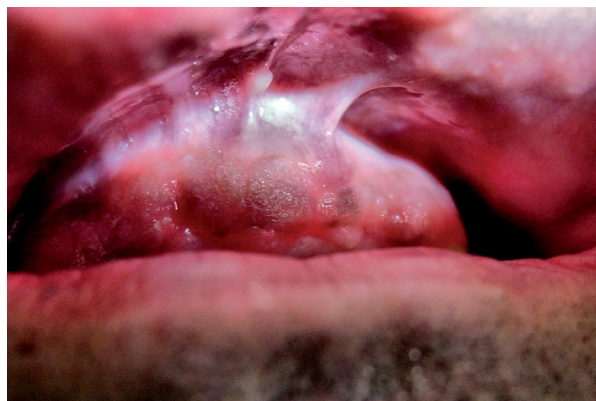oral melanoacanthoma can regress after the elimination of irritating factor or after being biopsied. Cutaneous variant occurs mainly in fair-skinned adults while the oral melanoacanthoma has a predilection for blacks and younger patients (7).

Radial growth is a high potential pathognomonic sign, it can mask a subyacent melanoma (3).

These characteristics have been studied with electronic microscopy, and several tests had been used like: immunoprecipitation test with the aim of analyze patient’s serum to search antibody antimelanoma, immunofluorescence to look for present antigens on melanoma lesion: immunohistochemical studies have demonstrated melanocytic reactivity of the melanocytes which reside on the basal, parabasal and cellular spinous strata for the marker HMB-45; the protein S-100 serves as marker of the presence of melanocytic dendritic cells, very useful for its diagnosis confirmation, as the marker Melanin-A also is used with this purpose (7).

Quirurgical exéresis shows a great ratio of success without recurrences (Fig. 2). It offers the advantage of preserve the borders of the lesion for a histopathologic analysis. Sometimes, even after the incisional biopsy, an involution of the lesion is observed with high frequency. Other ways of treatment are laser ablation with Argon, crioterapy, curettage and the topic application of Fluorouracil 5% (8).

The aim of the present article is to make a systematic review of all the published cases, as to actualize and evaluate etiologic factors and its clinicopathologic characteristics.



**Fig. 2.** Same lesion after a follow up of 10 years. It keeps stable.

**Material and Methods**

A systematic, computerized database search was conducted using the National Center for Biotechnology Information (NCBI) to search MEDLINE (Pubmed). The search was conducted using the following MeSH terms: “oral melanoacanthoma” AND “oral melanoacanthosis” AND “oral melanoepithelioma”.

For the initial selection, we selected all articles published since melanoacanthoma. Demographic data, histological characteristics and immunohistochemical findings were taken from the full text. From the literature a total of 59 articles, in relation with melanoacanthoma, were obtained, three of those were excluded after complete reading. We evaluated 56 articles. A total of 115 patients, including the case presented by our team, were diagnosed. Figure 3 describes, in a flow diagram, search phases of our systematic review.

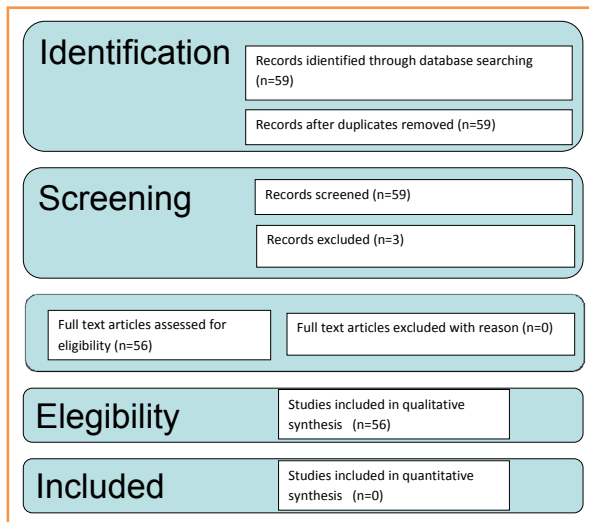


Fig. 3. Prisma Flow Diagram: different stages of the search in a systematic review.

### Results

The review of the literature shows that oral melanoacanthoma affects patients aged between 5 and 87 years, with a mean age of 34.79 years. There is higher prevalence in women, 54.4% versus 38.4% in men.

The ratio female-male is 3: 2. There is a predominance of the female sex in solitary phenotype 3: 2 and when the multifocal phenotype is the ratio female-male is 5: 3. In the bilateral phenotype is slight higher in women, 2: 1. The solitary phenotype appears more frequently (18.26% of cases) than the multifocal phenotype (13.91% of cases). The locations from highest to lowest frequency are buccal mucosa 33.9%, 13.04% palate, 5.22% lips, 13.91% alveolar mucosa including retromolar area and lingual mucosa, 3.48% tongue, 4.35% back, 3.48% abdomen, 3.48% scapula, 3.48% ear, 3.48% eyelid, 2.6% leg, 2.6% buttock, 1.74% neck, 1.74% floors mouth, 1.74% nose, 1.74% armpit, chest 0.87%, 0.87% vermilion lipstick, hip 0.87%, 0.87% base of the penis, arms 0.87% 0.87% temporal region, 0.87% submental region, 0.87% scrotum groin area, 0.87% preauricular area, 0.87% shoulder and 0.87% forehead.

The most frequent presentation is blackish brown in

40.8% of cases, followed by bluish black 3.2%, 1.6% reddish brown and grey 0.8%.

It has a predilection for black race (37.39%) followed by caucasian (19.13%), latin American (3.47%) and Asians (3.47%). 77.42% of the authors assert that the etiology is related to irritative factors.

Table 1, table 1 continue, table 1 continue-1, shows all cases submitted for analysis and the results of our systematic review.

### Discussion

The variability of phenotypic expression justifies the controversy of the classification of this entity. There are different phenotypes with multiple expressions: cutaneous or oral melanoacanthoma, painful or asymptomatic, fast growing or stable, multiple or solitary melanoacanthomas; as well as different locations and histopathologic features.

Zemtsov *et al.* consider that oral melanoacanthoma is a tumor wrongly named and defined it as an unusual proliferation of dendritic melanocytes mucositis in the epidermis (9). Horlick, propose the term mucosal melanotic macula for the reactive type of this lesion (10).

The etiology is still unclear, but most of the authors associate it with a continuing traumatic process that stimulate melanocytic activity (3,5,11,12).

Most of the injuries are related to trauma and its appearance varies from weeks to months. They even disappear after eliminating irritants or biopsy. This fact makes the reactive etiology stronger.

The reactive etiology of melanoacanthoma and other pigmented lesions may be associated with chronic contact with petroleum derivatives, such as sodium lauryl sulfate, nitrophenol, phenolphthalein, chlorophenol, phenylenediamine sulfate, cocamidopropyl betaine or amine fluoride. These components are found in toothpastes and mouthwashes and they act as irritants causing morphological changes. Pathology 100% of lesions supports this, and it is related to oral and cutaneous melanoma phenotype (13-15).

Most of the the authors observe the occurrence of these lesions in trauma areas of bruxism patients, lesions matching the occlusal plane or very prominent cusps of molars and premolars. Likewise, lesions have also been described in patients with a recent dental restoration, which entails a soft tissue trauma during the adaptation period (16,17).

Silver amalgam fillings have also been described as etiological factors that may cause pigmentation and changes in the epithelium (17). There is much controversy with this restorative material. Many countries, like Germany and the US, have already forbidden its use in dental therapy due to its corrosion and risk of toxicity, while other countries like Spain argue that this material has been used for hundred of years without an apparent risk.

Table 1. Described cases of melanoacanthoma found in literature search.

AUTHOR	NUMBER OF PATIENTS	AGE	SEX	APPEARANCE	COLOR	SIZE (cm)	ETIOLOGY	ETHNICITY
Kennedy <i>et al.</i> 2013 - J Indian Soc. Periodontol	1	13	M	Multifocal	Black-Brown	4	Reactive	B
Wagner <i>et al.</i> 2013 - Gen Dent	1	48	F	Solitary	Brown	0.7	Reactive	W
Patnayak <i>et al.</i> 2013 - J Lab Physicians	2	15	F	Solitary	-	1.5x1.0	Reactive	-
		53	M		-	1x1		
Vasani <i>et al.</i> 2013 - Indian Dermatol Online J	1	62	M	Solitary	Black	15x8	Reactive	B
Bhattacharyya 2013 - Today's FDA	1	72	M	Multifocal	Black	-	-	B
Das Chagas <i>et al.</i> 2013 - BMC Res Notes	1	58	M	Multifocal	Black-Brown	-	Reactive	B
Rohilla <i>et al.</i> 2013 - Int J Clin Pediatr Dent	1	12	F	Solitary	Black-Brown	-	Reactive	A
Ashok Gupta <i>et al.</i> 2012 - J Oral Maxillofac Pathol	1	22	F	Multifocal	Black	-	Reactive	-
Gondak <i>et al.</i> 2012 - Med Oral Patol Oral Cir Bucal	1	-	-	Solitary	-	-	Reactive	-
Jain <i>et al.</i> 2011 - Indian J Dermatol Venereol Leprol	1	58	F	Multiple	Black	3x3-12x10	Reactive	-
Galindo <i>et al.</i> 2011 - JADA	1	63	F	Multiple	Brown-black	0.03-0.06	Reactive	W
Shankar <i>et al.</i> 2011 - Indian J Dermatol	1	65	M	Solitary-giant	Brown-black	10x5	Reactive	B
Tapia <i>et al.</i> 2011 - Quintessence Int	1	35	F	Solitary	Brown	0.6x0.3	Reactive	W
Geetha <i>et al.</i> 2011 - Indian J Dermatol Venereol Leprol	1	8	M	Bilateral	Brown-black	5x3	Reactive	W
Arava-Parastatidis <i>et al.</i> 2011 - JADA	1	32	F	Solitary	-	-	Reactive	W
Brooks <i>et al.</i> 2010 - Pediatric Dermatol	1	17	M	Solitary	-	-	Reactive	W
Marocchio <i>et al.</i> 2009 - J Oral Sci	1	74	F	Multifocal	Brown	-	Reactive	B
Lakshminarayanan <i>et al.</i> 2009 - Med Case Rep	1	24	F		Brown	0.25	Reactive	A
Brooks <i>et al.</i> 2009 - J Periodontol	1	60	F	Multifocal	Brown	0.1-0.4	Reactive	W
Brooks <i>et al.</i> 2008 - Gen Dent	1	47	F	Solitary	-	0.2x0.3	Reactive	B
Krahl <i>et al.</i> 2008 - J Disch Dermatol Ges	0	-	-	-	-	-	Reactive	-
Bregni <i>et al.</i> 2007 - Med Oral Patol Oral Cir Bucal	8	7	M	Solitary	Dark-brown flat	0.3	Reactive	W
		25	M	-	Dark-brown flat	1	Reactive	LAM
		33	F	-	Dark-brown flat	0.6	Reactive	LAM
		40	F	-	Dark-brown flat	0.5	Reactive	LAM
		8	M	-	Dark-brown flat	0.3	Reactive	LAM
Yarom <i>et al.</i> 2007 - Int J Dermatol	1	60	F	Multifocal	Brown	-	Reactive	W
Rosicello <i>et al.</i> 2006 - Dermatol Surg	1	38	F	Multifocal	Black-brown	0.04	-	W
Andrews <i>et al.</i> 2005 - Ann Otol Rhinol Laryngol	1	45	M	Ulcerated	-	2.5	Reactive	B
Contreras <i>et al.</i> 2005 - Med Oral Patol	1	40	F	-	-	-	Reactive	W
Khiczak <i>et al.</i> 2004 - Int J Dermatol	1	45	F	-	Brown	2.5x0.5x0.8	Reactive	-
Buchner <i>et al.</i> 2004 - J Oral Pathol Med	7	36	F	-	Brown	1.0	Reactive	B
		37	M	-	Brown	0.2	Reactive	B
		51	M	-	Black	0.6	Reactive	A
		24	F	-	Black	2.0	Reactive	B
		63	M	-	-	0.4	Reactive	B
		52	F	-	Black	0.6	Reactive	A
		44	F	-	Brown	1.0	Reactive	B
Fomatora <i>et al.</i> 2003 - Am J Dermatopathol	10	5-77	2M 8F	Solitary	-	0.2	Reactive	7B 3W

Table 1 continue. Described cases of melanoacanthoma found in literature search.

Fatahzadeh <i>et al.</i> 2002 - Oral Surg Oral Med Oral Pathol Oral Radiol Endod	1	39	M	Multifocal	-	Brown	1.0	Reactive	B
Flaitz 2000 - Am J Dent	1	40	F	Solitary	-	Brown-black	-	Reactive	B
Heine <i>et al.</i> 1996 - Gen Dent	1	27	M	Bilateral	-	Brown	2.0x2.0	Reactive	B
Eisen <i>et al.</i> 1991 - J Am Acad Dermatol	0	-	-	-	-	-	-	Reactive	-
Simon <i>et al.</i> 1991 - Arch Dermatol	0	-	-	-	-	-	-	Reactive	-
Pérez-Oliva <i>et al.</i> 1990 - Med Cutan Ibero Lat Am	4	-	-	Solitary	-	-	-	Reactive	-
Tomich <i>et al.</i> 1990 - J Dermatol Surg Oncol	4	26	F	Solitary	-	Black	2.5	Reactive	B
		21	M	Solitary	-	Brown	2	Reactive	B
		14	F	Multifocal	-	Brown	3x2	Reactive	B
		39	F	Solitary	-	Black	5	Reactive	B
Vion <i>et al.</i> 1989 - Dermatologica	1	66	M	-	-	Red-brown	0.40x0.25	-	W
Whitt <i>et al.</i> 1988 - J Am Dent Assoc	1	25	M	Solitary	-	Red-brown	0.04	Reactive	B
Maize 1988 - Dermatol Clin	0	-	-	-	-	-	-	Unknown	-
Horlick <i>et al.</i> 1988 - J Am Acad Dermatol	2	36	M	Multifocal	-	Blue-black	-	Reactive	B
		16	F	Solitary	-	Brown-black	3x2	-	W
Sexton <i>et al.</i> 1987 - Am J Dermatopathol	3	32-43	B	-	-	-	-	Reactive	F
Lambert <i>et al.</i> 1987 - Int J Dermatol	0	-	-	-	-	-	-	-	-
Frey <i>et al.</i> 1984 - J Surg Oncol	1	39	B	-	-	Brown	2x1.8	Reactive	F
Wright <i>et al.</i> 1983 y 1988 - J Periodontol	2	36	F	Multifocal	-	Brown	1.5	Reactive	B
		27	F	Solitary	-	Brown	2x3	-	-
Prince <i>et al.</i> 1984 - J Cutan Pathol	5	80	F	-	-	-	4x4	Reactive	B
		69	F	-	-	Brown-black	5x5	Reactive	B
		69	M	-	-	Gray-black	10	Reactive	W
		79	F	-	-	Gray-black	5x4	Reactive	W
		48	M	-	-	-	2.5	Reactive	W
		30	F	-	-	-	2x4	Reactive	B
		19	M	-	-	Blue-brown	2.0	Reactive	M.B
		26	M	-	-	Blue-brown	3x1	-	W
		25	F	-	-	-	2x5	-	B
		19	F	-	-	-	2x2	-	B
		32	M	-	-	Blue-black	1x0.4	-	B
		19	F	-	-	Brown	-	Reactive	B
Goode <i>et al.</i> 1983 - Oral Surg Oral Med Oral Pathol	10	36	F	-	-	Brown	0.3	Reactive	B
		18	F	-	-	Dark-gray	4x4	-	B
		22	M	-	-	Black	0.5	-	-
		30	F	-	-	-	2x4	Reactive	B
		19	M	-	-	Blue-brown	2.0	Reactive	B
		26	M	-	-	Blue-brown	3x1	-	W
		25	F	-	-	-	2x5	-	B
		19	F	-	-	-	2x2	-	B
		32	M	-	-	Blue-black	1x0.4	-	B
		19	F	-	-	Brown	-	Reactive	B
		32	M	-	-	Blue-black	1x0.4	-	B
		19	F	-	-	Brown	-	Reactive	B
		36	F	-	-	Brown	0.3	Reactive	B
Zina <i>et al.</i> 1982 - J Cutan Pathol	1	60	M	-	-	Brown-black	10	-	W
Schneider <i>et al.</i> 1981 - Oral Surg Oral Med	1	9	F	Solitary	-	Brown	1.3x1.1	Reactive	B

**Table 1 continue-1.** Described cases of melanoacanthoma found in literature search.

Oral Pathol	I	39	F	-	Brown	5	-	B
Tomich 1978 - 32nd Annual Meeting of the American Academy of Oral Pathology	I	18	F	Multifocal	Black-Brown	5-6	Reactive	B
Matsuoka <i>et al.</i> 1979 - Arch Dermatol	I	74	M	-	Brown	3x3	-	W
Schlappner 1978 - J Cutan Pathol	I	87	F	-	-	0.09x0.12	Reactive	W
Delacretaz 1975 - Dermatologica	I	40	M	-	Black	-	Reactive	B
Spott <i>et al.</i> 1972 - Arch Dermatol	I	63	F	-	-	-	-	-
Sánchez Yus <i>et al.</i> 1969 - Actas Dermosifiliogr	8	-	M	-	-	-	-	-
		58	M	-	-	-	-	-
		-	M	-	-	-	-	-
		58	F	-	-	-	-	-
		-	M	-	-	-	-	-
		36	M	-	-	-	-	-
		-	F	-	-	-	-	-
Mishima <i>et al.</i> 1960 - Arch Dermatol	12	61	F	-	-	0.12x0.14	Reactive	-
		46	F	-	-	0.20x0.20	-	-
		68	F	-	-	0.10x0.10	-	-
		59	M	-	-	0.06x0.06	-	-
		81	M	-	-	0.10x0.10	-	-
		77	F	-	-	0.20x0.20	-	-
		60	F	-	-	0.20x0.15	-	-
		54	F	-	-	0.13x0.16	-	-
		62	M	-	-	1x1	-	-
		79	M	-	-	0.25x0.20	-	-
		63	M	-	-	0.50x0.50	-	-
		68	M	-	-	0.45x0.28	-	-
		61	M	-	-	0.20x0.15	-	-
Actual case	I	53	M	Multifocal	Brown-black	2.0	Reactive	W
<b>Summary</b>	<b>115</b>	<b>5-87</b> (34,79)	<b>Female</b> (68) Male (47) Unknown (5) Proportion 7:2	<b>Solitary (11)=8%</b> Multifocal (6)=4 8% Unknown(53)=42,4%	<b>Brown-black (51)=</b> 44,35% <b>Blue-black (4)=</b> 3,48% <b>Red-brown (2)=1,6%</b> <b>Gray (2)=2,6%</b> <b>Unknown(56)=44,8%</b>	<b>0,04-8cm</b>	<b>Reactive (86)=74,78</b> % Unknown(29)=25,22%	<b>W(22)=19,13%</b> % <b>B(43)=37,39%</b> LAM(4)=3,48% A(3)=2,60% Unknown(35)= 30,43%

Described cases of melanoacanthoma found in literature search. F (Female), M (Male), W (White), B (Black), A (Asian), LAM (Latin American mestizo), R (Recurrence).



In 2007 Yarom *et al.* describe as etiologic factors ill-fitting removable prosthesis, patients treated for chronic asthma, constant bite of the cheeks, hydrogen peroxide mouthwashes and nonspecific chronic trauma (18,19).

There are also described in the literature lesions suddenly appeared after implants surgery or associated with ferrous lactate chronic treatment for iron-deficiency anemia.

Zemtsov *et al.* proposed to their patients removing toothpastes and mouthwashes containing hydrogen peroxide resulting in the spontaneous resolution of melanoacanthoma. They show that the most common irritant are mercury and petroleum derivatives as cinnamic aldehyde, in toothpastes, which may cause allergic contact dermatitis (8).

Toothpastes with abrasive components, such as, calcium phosphate or calcium carbonate, act as irritant factors which produce tissue reaction after chronic contact (20).

Brooks *et al.* found that there are alterations of superficial dermis in cutaneous phenotype, but they didn't observed fast growth or spontaneous resolution as it does in oral melanoacanthoma (21,22).

Galindo *et al.*, along with other authors, argue that melanoacanthoma does not need any specific treatment or follow up because there have not been reported cases of malignancy with features of dysplasia or atypia (6).

However, we found in the literature (Zina, in 1982), a case of simple hydroacanthoma with a malignant transformation into a porocarcinoma. This extremely rare tumor classification is highly complex due to its histopathological similarities with other lesion and degenerative changes of any lesion with age. The relationship between melanocytes and keratinocytes is very similar to the reaction observed in the melanoacanthoma (23). This rare lesion was named Bort-Jadasshon intraepidermal epithelioma and it matches with the terms described by Bloch in 1927 and Mishima in 1960 when melanoacanthoma was called "non-cutaneous benign melanoepithelioma nevoid" (24,25).

Simon believes for there are three variants of melanocytic seborrheic keratosis: irritant, non-irritating and nested variants. He considers that oral melanoacanthoma is an irritant seborrheic keratosis and he suggests the term melanoacanthoma should be removed (12).

Concerning relations between melanoacanthoma and seborrheic keratosis it should be noted that the only difference between the two processes is that in melanoacanthoma can be found many melanocytes at every level of tumor epidermis, while in seborrheic keratoses, melanocytes are not increased and they can only be found in basal area (26). Authors like Sanchez Yus and Simon

Huarte concluded that both tumors are the same entity and they should not be separated. The electron microscope, shows that the distribution and arrangement of melanocytes are notably different in melanoacanthomas compared to seborrheic keratoses. Melanocytes are small with intense mitotic activity, melanin granules are present in the cytoplasm and several basal keratinocytes proliferate (27).

Clinical appearance similar to other pigmented lesions, family history, drug use or systemic drugs, hormones, heavy metals and changes in the morphological pattern are important for the differential diagnosis (11). Some pathological entities described in table 2, table 2 continue should be included.

Back to melanoacanthoma histology, this is a pigmented tumor that exhibits great morphological variability. Pathological characteristics show stratified squamous epithelium with proliferation of melanocytes and melanin presence in the basal layer and suprabasal layers without invading the underlying connective tissue, prone to the central keratinization (endoqueratinización). The predominant cell pattern prickly keratinocytes or basal differentiation is present in different areas. Melanocytes have extensive dendritic processes and striking areas of acanthosis (27).

The presence of inflammatory infiltrate is found in the great majority of melanoacanthomas. The block in the transference of melanin from melanocytes to keratinocytes is the nature of this entity. Alteration in the normal pattern and speed differentiation of keratinocytes alters cell characteristic of keratinocytes surface which inhibits pigment donation.

The etiological hypotheses of reactive origin pigmented lesion is supported by the frequent presence of inflammatory infiltrate of lymphocytes.

Langerhans cells are present in every Malpighian layer except from the basal layer. These cells are related to proliferation control of keratinocytes. Therefore, the study of Langerhans cells is interesting due to its disposition at every layers (27).

## Conclusions

The histopathological analysis of the melanoacanthoma suspicious lesion is crucial to rule out malignancy, as it may hide a subyacent oral melanoma. Any heterogeneous pigmented lesion with irregular borders, raised surface, fast growth and sharp appearance should be biopsied. Since over 75% of reported cases indicate an irritating background, more emphasis must be put on the control of them. This can improve the quality of life of our patients and reduce morbidity of numerous pathologies.

**Table 2.** Differential diagnosis of various pathologies.

	<b>Characteristics</b>	<b>Frequent localization, higher age incidence and race predilection</b>	<b>Clinical characteristics</b>	<b>Observations</b>
<b>Intraoral nevus</b>		Palate and gums 3rd and 4th decade	Brown-dark	0.1% of the population
<b>Melanotic macula</b>	Increased melanin. Presence of melanocytes in the basal and parabasal layer with normal stratified squamous epithelium	Vermilion lower lip, buccal mucosa and gingiva and palate		
<b>Fisiological pigmentations</b>	Pigmented macules of different sizes and configurations. It appears since childhood or puberty	Black race	Brown-dark	Infrequent
<b>Laugier-Hunziker's syndrome</b>	Acquired benign pathology. Solitary or multiple macules, lenticular or linear, well-defined or diffuse margins	Buccal mucosa, lips and palmoplantar surfaces. Caucasian women. Second half of the adulthood. 50% of the cases with nail pigmentation	Brown-grey-dark	Infrequent
<b>Peutz-Jegher's syndrome</b>	Autosomal dominant disorder. Hyperchromic multiple melanotic macules varying in size and shape.	Buccal mucosa, lips and tongue. 1st decade of life. 60% of patients age of 20	Presence of adenohamartomatous gastrointestinal polyps. Dark brown	A thorough follow-up of these patients because of the high risk of malignant transformation is necessary.
<b>Addison's disease</b>	Endocrine disease with infectious origin, autoimmune or due to malignant adrenal gland. Adenocorticotropina overproduction of the hormone and hyperstimulation of the melanocytes.	Any region of the oral mucosa	Mucocutaneous hyperpigmentation. Diffuse / localized pattern. Associated symptoms: weakness, nausea, vomiting, anorexia, weight loss and postural hypotension.	It is crucial to diagnose oral lesions, they precede extraoral manifestations.
<b>Vascular pathology</b>	Petechiae, ecchymosis, bruises, varicose veins and hemangiomas	Any region of the oral mucosa	Bluish-red coloration. Pulsatile.	Risk of bleeding.
<b>Osler-Weber-Rendu's syndrome</b>	Tumor with autosomal dominant hereditary pattern	Telangiectasia on the lips, tongue and extremities	Reddish-blue spider veins.	Oral changes and epistaxis are vital for early diagnosis.
<b>Amalgama tatoo or focal Argirosis</b>	It is a iatrogenic injury posterior to soft tissue implantation of amalgam particles.	Mucosa adjacent fillings	These can be detected in X-rays	Microscopically, the particles are typically aligned along the collagen fibers and blood vessels, a few lymphocytes and macrophages they can also be found



**Table 2 continue.** Differential diagnosis of various pathologies.

<b>Melanoma</b>	Related to removable prosthesis trauma, irritants such as tobacco and alcohol and poor oral hygiene.	Maxillary gingiva and the hard palate mucosa are the locations most affected African blacks, asians, americans and hispanics. Tongue, lips or jaw mucosa are other areas of predilection The peak incidence is in the seventh decade of life and it is more common in males.	The clinical features are extremely variable, they can suddenly appear and fast growth causing ulceration, bleeding and pain (these features are related to the early stages of oral melanoma), or they can present macules, plaques, patches or nodules asymptomatic for years, (in the most advanced) stages.	Primary melanoma of the oral cavity is a rare malignancy (0.2% to 8% of all melanomas in Europe and the United States). Clinically classified into four types: nodular melanoma, diffuse surface melanoma, acral lentiginous melanoma and lentigo maligna melanoma. Determining the depth of invasion in millimeters is the most important factor, especially in cutaneous melanoma prognosis. Most of the cases of oral melanoma revised were diagnosed when they were in advanced stages so that the ratio of survival significantly decreases.
<b>Lentigo malign</b>		Middle-aged. Peak incidence 65-80 years. Developed in areas of sun exposure, 86% head and neck.	Dark diamond structures. Slate gray globules points. Isobara structures. Zig-zag pattern (Brown or blue-grey dots or blue combined with lines)	The dendritic melanocytes are cytologically atypical and they are grouped only on the basis of epithelium. High power of recurrence.
<b>Squamous cell carcinoma and salivary glands tumors salivary glands</b>				They also contain dendritic melanocytes
<b>Kaposi's sarcoma</b>	Characteristic in HIVpatients, but also found in liver transplant patients, drug injecting and immunocompromised patients	Palate and gingiva	It shows red, blue or purple macula in early stages and pigmented nodules and plaques in later stages. The lumps are painful and bleeding.	Histologically, early onset maculas are composed of lines of endothelial vessels while, avanced nodular lesions contained spindle-shaped cells interspersed in the endothelium.
<b>Smoker's Melanosis</b>	It is a benign dark pigmentation in the oral mucosa developed in 25% of the smokers.	Anterior gum and interdental papilla	Brown-dark	It usually disappear when the patient gives up smoking, persistence make them candidates for pathological analysis.
<b>Diffuse and multifocal drug-induced melanosis</b>	Drugs that cause oral pigmentation are: minocycline, antimalarials, chemotherapy and antiretroviral drugs used in the treatment of HIV patients.	Hard palate and gingiva	Brown-dark	Oral pigmentation dissapears after removing the drug
<b>Simple pigmented malignant hydroacanthoma</b>	Malignant tumor often confused with melanoacanthoma, seborrheic keratoses and Bowen's disease. Described by Yu-Yun Lee <i>et al.</i> (38)	Predilection for the limbs of women.	Brown-dark	Extremely rare

## References

1. Kennedy Babu SPK, Agila S, Sivaranjani P, Kashyap V. An unusual clinical presentation of gingival melanoacanthoma. *J Indian Soc Periodontol.* 2013;17:657-60.
2. Schneider LC, Mesa ML, Haber SM. Melanoacanthoma of the oral mucosa. *Oral Surg Oral Med Oral Pathol.* 1981;52:284-7.
3. Contreras E, Carlos R. Oral melanoacanthosis (melanoachantoma): report of a case and review of the literature. *Med Oral Patol Oral Cir Bucal.* 2005;10:11-2;9-11.
4. Arava-Parastatidis M, Alawi F, Stoopler TE. Multifocal pigmentation of the oral cavity. *JADA.* 2011;142:53-6.
5. Krahl D, Altenburg A, Zouboulis CC. Reactive hyperplasias, precancerous and malignant lesions of the oral mucosa. *J Dtsch Dermatol Ges.* 2008;6:217-32.
6. Galindo P, Padial M, Gómez M, Aneiros J, Mesa F, O'Valle F. Multifocal oral melanoacanthoma and melanotic macula after dental implants surgery. *JADA.* 2011;142:817-24.
7. Tapia JL, Quezada D, Gaitan S, Hernández JC, Paez C, Aguirre A. Gingival melanoacanthoma: case report and discussion of its clinical relevance. *Quintessence Int.* 2011;42:253-8.
8. Andrews BT, Trask DK. Oral melanoacanthoma: a case report, a review of the literature, and a new treatment option. *Ann Otol Rhinol Laryngol.* 2005;114:677-80.
9. Zemtsov A, Bergfeld WF. Oral melanoacanthoma with prominent spongiotic intraepithelial vesicles. *J Cutan Pathol.* 1989;16:365-9.
10. Horlick HP, Walther RR, Zegarelli DJ, Silvers DN, Eliezri YD. Mucosal melanotic macule, reactive type: a simulation of melanoma. *J Am Acad Dermatol.* 1988;19:786-91.
11. Gondak RO, da Silva-Jorge R, Jorge J, Lopes MA, Vargas PA. Oral pigmented lesions: Clinicopathologic features and review of the literature. *Med Oral Patol Oral Cir Bucal.* 2012;17:e919-24.
12. Simon P, Requena L, Sánchez-Yus E. How rare is melanoacanthoma? *Arch Dermatol.* 1991;127:583-4.
13. Lawrence LM, Farquharson A, Brown RS, Vatanka HO. Oral tissue irritants in toothpaste: a case report. *J Clin Pediatr Dent.* 2013;38:75-8.
14. Sajid M, Ilyas M, Basheer C, Tariq M, Daud M, Baig N, et al. Impact of nanoparticles on human and environment: review of toxicity factors, exposures, control strategies, and future prospects. *Environ Sci Pollut Res Int.* 2015;22:4122-43.
15. Cvikl B, Lussi A, Gruber R. The in vitro impact of toothpaste extracts on cell viability. *Eur J Oral Sci.* 2015;123:179-85.
16. Whitt JC, Jennings DR, Arendt DM, Vinton JR. Rapidly expanding pigmented lesion of the buccal mucosa. *J Am Dent Assoc.* 1988;117:620-2.
17. Sexton FM, Maize JC. Melanotic macules and melanoacanthomas of the lip. A comparative study with census of the basal melanocyte population. *Am J Dermatopathol.* 1987;9:438-44.
18. Yarom N, Hirshberg A, Buchner A. Solitary and multifocal oral melanoacanthoma. *Int J Dermatol.* 2007;46:1232-6.
19. Goode RK, Crawford BE, Callihan MD, Neville BW. Oral melanoacanthoma. Review of the literature and report of ten cases. *Oral Surg Oral Med Oral Pathol.* 1983;56:622-8.
20. Bouquot JE, Koeppen RG, Haddad Y. Oral and maxillofacial pathology. Case of the month. Toothpaste-induced mucosal etching (TIME). *Tex Dent J.* 2014;131:574-6,610-2.
21. Brooks JK, Sindler AJ, Scheper MA. Oral melanoacanthoma in an adolescent. *Pediatric Dermatol.* 2010;27:384-7.
22. Brooks JK, Sindler AJ, Papadimitriou JC, Francis LA, Scheper MA. Multifocal melanoacanthoma of the gingiva and hard palate. *J Periodontol.* 2009;80:527-32.
23. Zina AM, Bundino S, Pippione MG. Pigmented hidroacanthoma simplex with porocarcinoma. Light and electron microscopic study of a case. *J Cutan Pathol.* 1982;9:104-12.
24. Schneider LC, Mesa ML, Haber SM. Melanoacanthoma of the oral mucosa. *Oral Surg Oral Med Oral Pathol.* 1981;52:284-7.
25. Mishima Y, Pinkus H. Benign mixed tumor of melanocytes and malpighian cells. Melanoacanthoma: Its relationship to Bloch's benign non-nevoid melanoepithelioma. *Arch Dermatol.* 1960;81:539-50.
26. Pérez-Oliva N, Toribio J, Quiñones PA. Histologic aspects of seborrheic keratosis. *Med Cutan Ibero Lat Am.* 1990;18:70-7.
27. Schlappner OL, Rowden G, Philips TM, Rahim Z. Melanoacanthoma. Ultrastructural and immunological studies. *J Cutan Pathol.* 1978;5:127-41.

## Conflict of Interest

The article have not any conflict of interests.