

# Thromboembolism and bleeding in systemic amyloidosis: a review

Martin Nicol<sup>1,2\*</sup>, Virginie Siguret<sup>2,3,4</sup>, Giuseppe Vergaro<sup>5</sup>, Alberto Aimo<sup>5</sup>, Michele Emdin<sup>5</sup>, Jean Guillaume Dillinger<sup>1,2</sup>, Mathilde Baudet<sup>1</sup>, Alain Cohen-Solal<sup>1,2</sup>, Camille Villesuzanne<sup>6</sup>, Stephanie Harel<sup>6</sup>, Bruno Royer<sup>6</sup>, Bertrand Arnulf<sup>2,6</sup> and Damien Logeart<sup>1,2</sup>

<sup>1</sup>Cardiology department, Lariboisière Hospital, APHP, 2 rue Ambroise Paré, Paris, France; <sup>2</sup>Université de Paris, Paris, France; <sup>3</sup>INSERM UMR-S-1140 University of Paris, Paris, France; <sup>4</sup>Laboratory of Hematology, Lariboisière Hospital, APHP, Paris, France; <sup>5</sup>Division of Cardiology and Cardiovascular Medicine, Fondazione Toscana Gabriele Monasterio, Pisa, Italy; and <sup>6</sup>Immuno-hematology Department, Saint Louis Hospital, APHP, Paris, France

## Abstract

The assessment of both thromboembolic and haemorrhagic risks and their management in systemic amyloidosis have been poorly emphasized so far. This narrative review summarizes main evidence from literature with clinical perspective. The rate of thromboembolic events is as high as 5–10% amyloidosis patients, at least in patients with cardiac involvement, with deleterious impact on prognosis. The most known pro-thrombotic factors are heart failure, atrial fibrillation, and atrial myopathy. Atrial fibrillation could occur in 20% to 75% of systemic amyloidosis patients. Cardiac thrombi are frequently observed in patients, particularly in immunoglobulin light chains (AL) amyloidosis, up to 30%, and it is advised to look for them systematically before cardioversion. In AL amyloidosis, nephrotic syndrome and the use of immunomodulatory drugs also favour thrombosis. On the other hand, the bleeding risk increases because of frequent amyloid digestive involvement as well as factor X deficiency, renal failure, and increased risk of dysautonomia-related fall.

**Keywords** Amyloidosis; Thromboembolism; Bleeding; Anticoagulative therapy

Received: 24 July 2021; Revised: 18 September 2021; Accepted: 29 October 2021

\*Correspondence to: Martin Nicol, Cardiology Department, Lariboisière Hospital, APHP, 2 rue Ambroise Paré, Paris, France. Tel: 0033149958674.

Email: martin.nicol@aphp.fr

## Introduction

Systemic amyloidosis is due to amyloid fibril deposits that involve numerous organs. More than 30 proteins are currently considered to be ‘amyloidogenic’, but the two most common forms of amyloidosis are variant (vATTR) or wild-type transthyretin (wtATTR) and immunoglobulin light-chain (AL).<sup>1,2</sup> The incidence of AL amyloidosis is about 12 cases per million persons per year.<sup>3</sup> TTR amyloidosis is more frequent (prevalence: 13% of heart failure with preserved ejection fraction (HFpEF),<sup>4</sup> 5% of all hypertrophic cardiomyopathies).<sup>5</sup> Amyloidosis can involve numerous organs, such as kidney, nerves, heart, digestive tract, liver, bone or joints, each of these leading to specific complications. Among amyloidosis-related complications are thrombotic and bleeding events<sup>6,11</sup> whose prediction and management is particularly challenging. So far, there is no specific guideline about the use of antithrombotic treatment in amyloidosis.

The objectives of this narrative review are (i) to specify current epidemiological data on thrombotic and bleeding risks, (ii) to analyse main determinants and predictors of these two risks, and (iii) to review current evidence about anti-thrombotic treatment in amyloidosis.

## Frequency and severity of thromboembolic events in amyloidosis

For 20 years, thrombotic events (TEs) have been described in amyloidosis and more particularly in patients with cardiac amyloidosis (CA).<sup>7,8,9,10,11</sup> Indeed, cardiac involvement is particularly frequent (60–70%). TTR CA is estimated to be as high as 13% of patients with HFpEF.<sup>4</sup> Cappelli *et al.*<sup>12</sup> published the largest cohort including 406 patients with CA (134 AL, 73 vATTR, and 199 wtATTR) with a median follow-up of

19 months. The incidence of arterial TE was 7.6% (Table 1). Most events (29 out of 31) were cerebrovascular events (21 ischaemic strokes and 8 transient ischaemic attacks). TEs were the first disease manifestations in 10 patients. Eleven per cent of patients with CA and atrial fibrillation (AF) had a TE. The incidence rate of TE in patients with CA and AF was 3.2 per 100 patients per year. The only predictor of TE in Cox analysis was CHADS<sub>2</sub>-VAsc score  $\geq 3$  [hazard ratio 2.84, 95% confidence interval (CI) 1.02–7.92,  $P = 0.05$ ] especially in patients with sinus rhythm. The rate of events in sinus rhythm without history of AF was 32% (10 events).

Other types of TE occur in amyloidosis and appear always associated with poor prognosis. In a Mayo Clinic's study<sup>13</sup> involving 40 AL amyloidosis patients with TE, the authors reported that (i) 29 patients had deep vein thrombosis (73%) and 11 had arterial thrombosis (28%); (ii) embolic event preceded the diagnosis of amyloidosis in 11 patients (28%); (iii) TE were associated with a poor prognosis with death occurring in 8 patients 1 month after the event and 18 deaths in the year following the TE.

### Stroke as the first manifestation of cardiac amyloidosis

A retrospective Mayo Clinic study<sup>14</sup> carried out in 40 patients with systemic amyloidosis (37 AL and 3 ATTR) and stroke revealed that ischaemic stroke was the initial manifestation in 13 patients (33%). The median survival of patients in whom

stroke was the first manifestation was 7 months. Stroke occurred 9.6 months before the diagnosis of amyloidosis. In most cases, the stroke was hemispherical (73%) and in a single vascular territory (68%). Amyloidosis, and particularly CA should therefore be considered in stroke patients, especially in the presence of features suggestive of transthoracic echocardiography (TTE) (left ventricular hypertrophy, dilated left atrium, restrictive filling pattern, pericardial effusion, aortic stenosis,<sup>15</sup> and elevated cardiac biomarkers).<sup>16</sup>

### Evidence for cardioembolic cause of thromboembolic events and mechanisms

If recurrent cerebral embolism was described in amyloidosis patients even in the absence of AF or symptomatic heart failure, it is admitted that most are cardioembolic events. Feng *et al.* published<sup>6</sup> a large study involving 116 autopsies of patients who had biopsy-proven CA (55 AL, 55 wtTTR, 4 AA-serum amyloid A protein and 2 vTTR). The prevalence of intracardiac thrombi in patients with CA was 33%. Patients with AL type CA were younger and had fewer supraventricular arrhythmias but had more frequent intracardiac thrombi than those with other types of CA (51% vs. 16%,  $P < 0.001$ ). AF and AL subtype were associated with a very high risk of thromboembolism (odds ratio 55; 95% CI

**Table 1** Prevalence of thromboembolic events in systemic amyloidosis

Study, date	Population	Prevalence	Thromboembolic events details	Favouring factors
Capelli <i>et al.</i> , 2020 <sup>12</sup>	$N = 262$ 134 AL, 73 vTTR, 199 wtTTR	7.6% Prevalence of clinical events	21 ischaemic stroke 8 TIA 2 peripheral events: 1 mesenteric and 1 femoral embolism	AF LVEF <50% CHADS <sub>2</sub> VASC > 2 Chronic kidney disease
Mitrani <i>et al.</i> , 2020 <sup>21</sup>	$N = 290$ TTR	6% Prevalence of clinical events, all had AF	9 stroke 8 TIA	AF
Donnellan <i>et al.</i> , 2020 <sup>22</sup>	$N = 382$ TTR 111wtTTR, 271 vTTR	16% 20% with AF vs 9% without AF	Cerebrovascular events	Increased CHADS <sub>2</sub> VASC score No anticoagulation therapy
Feng <i>et al.</i> , 2007 <sup>6</sup>	$N = 116$ autopsies 55 AL, 55 wtTTR, 4 AA	33%	Intracardiac thrombi by autopsy	AL subtype AF
Feng <i>et al.</i> , 2009 <sup>17</sup>	$N = 156$ 80 AL, 73 TTR, 3 AA	27%	Intracardiac thrombi by ultrasound	AL subtype Low systolic pressure Low atrial emptying velocity Diastolic dysfunction Biventricular systolic dysfunction
Martinez-Naharro <i>et al.</i> , 2019 <sup>18</sup>	$N = 324$ , 166 TTR, 155 AL	6.2%	Intracardiac thrombi by CMR	Atrial dilation Higher ECV AF AL subtype
Em Al <i>et al.</i> , 2019 <sup>24</sup>	$N = 58$	28%	Intracardiac thrombus (TEE)	AF

AF, atrial fibrillation; AL, immunoglobulin light chain amyloidosis; CMR, cardiac magnetic resonance; TTR: transthyretin; wtTTR, wild type transthyretin; vTTR: variant transthyretin; TEE, transesophageal echocardiography; TIA: transient ischaemic attack.

8–1134). TEs were a significant cause of death in patients with CA. Indeed, 19/23 emboli were considered to be fatal (14/53: 26% in the AL CA subgroup vs 5/59: 8% in the other types of CA,  $P < 0.001$ ). The same team studied the prevalence of intracardiac thrombi by transthoracic (TTE) and transoesophageal (TEE) echocardiography<sup>17</sup> in all CA patients who underwent cardiac ultrasound in the Mayo Clinic database (from 1999 to 2007). One hundred fifty-six patients (80 AL, 73 ATTR, and 3 AA type) were studied; 58 thrombi were found in 42 patients (prevalence = 27%). The prevalence of intracardiac thrombi was higher in AL amyloidosis than ATTR or AA: 35% vs. 18%,  $P = 0.02$ . The prevalence of intracardiac thrombi assessed by cardiac magnetic resonance is 6.2% in a recent study of Martinez-Naharro *et al.* including 324 amyloidosis patients (166 TTR and 155 AL). Favouring factors of TE were biventricular systolic dysfunction, atrial dilation, AF, higher extracellular volume, and AL subtype.<sup>18</sup>

Comprehensive cardiac imaging should be considered in all patients with amyloidosis and TE events. Cardiac imaging could start with TTE and use of contrast agent in case of insufficient echogenicity. If there is no evidence of thrombus with this first examination, patients should be considered for TEE and/or computed tomography scan and/or cardiac magnetic resonance.

This high risk of cardiac thrombi and subsequent embolic events can be also related to supraventricular arrhythmia and also to specific involvement of atria by amyloidosis, that has been so-called atria myopathy.

### Supraventricular arrhythmia in amyloidosis

Systemic amyloidosis increases the occurrence of AF or atrial flutter through several mechanisms: amyloid infiltration, impairment of ventricular and atrial compliance and relaxation with subsequent increase in left ventricular filling pressures resulting in LA enlargement and remodelling.

In published cohorts, the reported rate of AF varies between 20% and 75% (Table 2). Sanchis *et al.*<sup>19</sup> reported AF prevalence as up to 44% in 238 patients with amyloid heart disease: 71% in wtATTR, 26% in AL and 19% in vATTR amy-

loidosis. Longhi *et al.*<sup>20</sup> reported AF in 15% of 262 patients with CA: 40% in wtTTR, 9% in AL, and 11% in vATTR. Mitrani *et al.*<sup>21</sup> reported the rate of AF as high as 74% of 290 patients with ATTR cardiomyopathy, higher in the wtATTR group than in the vTTR group (85% and 52%, respectively). In addition, Mitrani *et al.* reported a rate of 17 embolic events in 15 patients; all embolic events occurred in patients with AF. In a recent study including 382 patients with ATTR cardiomyopathy, Donellan *et al.* reported AF in 69% cases.<sup>22</sup> Older age, male gender, history of heart failure, and advanced cardiac involvement were strongly associated with the risk of AF.<sup>20,22,23</sup> AF was not associated with an increased mortality in most studies.

El-Am *et al.*<sup>24</sup> studied AF-related thromboembolic risk through the comparison of TEE data between a cohort of 58 patients with CA and 114 patients without amyloidosis. All patients had AF, and the TEE was planned before electrical cardioversion. After TEE, the electrical cardioversion was cancelled in 16/58 (28%) CA patients vs 8/114 (7%) non-amyloid patients,  $P < 0.001$ . The main cause of cardioversion cancellation was intracardiac thrombus in 13/46 (28%) patients with CA. Among these 13 patients, 2 patients were in AF from less than 48 h, and 4 had had an INR in the therapeutic range for more than 3 weeks. This study suggests that AF in amyloid cardiomyopathy is associated with a higher risk of atrial thrombosis. The authors advised for systematic TEE before cardioversion in patients with amyloidosis. They also observed more complications from cardioversion in patients with CA: 6/42 (14%) vs. 2/106 (2%),  $P = 0.007$  including 2 ventricular arrhythmias and 2 severe brady-arrhythmias requiring permanent pacemakers.

### Evidence of atrial amyloid myopathy

Thirty years ago, Dubrey *et al.*<sup>25</sup> reported three cases of patients with CA, sinus rhythm and atrial thrombi. These authors suggested that lack of atria mechanical function irrespective of sinus rhythm favoured intra-atrial thrombi. Indeed, they observed a very low velocity of the A wave suggesting that atrial contraction could be impaired by amyloid

**Table 2** Prevalence of AF in AL and TTR amyloidosis in most recent studies

Study, date	Population	Overall prevalence	Prevalence in TTR	Prevalence in AL
Longhi <i>et al.</i> , 2015 <sup>20</sup>	$N = 262$ 123 AL, 94 hTTR, 45 wtTTR	15%	35%	9%
Mints <i>et al.</i> , 2018 <sup>23</sup>	$N = 146$ wtTTR	70%	70%	—
Sanchis <i>et al.</i> , 2019 <sup>19</sup>	$N = 238$ , 115 AL, 97 wtTTR, 26 hTTR	44%	60%	26%
Martinez-Naharro <i>et al.</i> , 2019 <sup>18</sup>	$N = 324$ , 166 TTR, 155 AL	—	46%	14%
Mitrani <i>et al.</i> , 2020 <sup>21</sup>	$N = 290$ TTR	75%	75%	—
Donellan <i>et al.</i> , 2020 <sup>22</sup>	$N = 265$ , 205 wt, 60 vTTR	69%	69%	—

AL, immunoglobulin light chain amyloidosis; TTR, transthyretin; vTTR, variant transthyretin; wtTTR: wild type transthyretin.

tissue infiltration. Other evidence of left atrial dysfunction in patients with CA is reported below.

In a large pathological study, appendages were removed during cardiac surgery in 245 patients (median age 63 years old) and analysed by both Congo red staining and immunohistochemistry: amyloid deposits were found in up to 16% of patients.<sup>26</sup> Such atrial amyloidosis was independently associated with the occurrence of AF.

In their pathological studies, Feng *et al.* observed that predictors of intracardiac thrombi were severe diastolic dysfunction, low atrial emptying velocity in TEE, low systolic blood pressure, and the AL subtype.<sup>10,17</sup> In other words, these studies suggested that the increase in thromboembolic risk was due to amyloid infiltration leading to impairment of atrial contractility and blood stasis, and the strong endothelial cytotoxicity of amyloid light-chains.

Several studies based on cardiac imaging highlighted the high rate and the role of atrial dysfunction in amyloidosis. Henein *et al.* showed that the LA strain rate during atrial contraction phase was the only predictor of the occurrence of AF on Holter-ECG recordings, independently of atrial size, in 46 patients with ATTR amyloidosis.<sup>29</sup> Brand *et al.* showed that atrial mechanics assessed by strain were decreased in amyloidosis with a high accuracy for the diagnosis of CA in unexplained LV hypertrophy.<sup>27</sup> Mohty *et al.* showed that impaired atrial function, assessed by TTE strain 3D<sup>28</sup> and cardiac magnetic resonance imaging LA emptying function,<sup>29</sup> worsened the prognosis of patients with AL amyloidosis. Indeed, 2 year survival was significantly reduced in patients with an LA emptying fraction <16% and that was associated with the prognostic classification of the Mayo Clinic.

However, no study has shown the predictive role of atrial dysfunction *per se* in the occurrence of thromboembolic events so far.

## Non-cardiac factors associated with thromboembolic events in amyloidosis

Besides AF and CA, number of others causes or favouring factors can explain the high risk of TE in amyloidosis: nephrotic syndrome leading to urinary loss of natural anticoagulants factors (antithrombin, protein S) and increased synthesis of procoagulant factors (factor V, VII, fibrinogen), decreased mobility and chemotherapy. Hausfater *et al.*<sup>30</sup> studied the causes of TE in a small cohort of patients with AL amyloidosis where 9 of the 15 patients had a TE: 3 strokes, 2 transient ischaemic attacks, 1 peripheral arterial embolism, 1 iliac thrombosis, 1 mesenteric ischaemia, and 1 ocular ischaemia. All patients were in sinus rhythm and only one patient had an intracardiac thrombus. The factors associated with TEs were oestrogen contraception, thalidomide, and growth factors. The authors postulated that all the elements of Virchow's

triad were implied, specifically the endothelial injury by endocardial amyloid deposits leading to parietal injury and valvular amyloid deposits, the stasis by restrictive cardiomyopathy characterized by slow diastolic filling and arrhythmias, and plasma hypercoagulability by a nephrotic syndrome, thrombocytosis related to hyposplenism, blood viscosity related to circulating monoclonal component. In the study of Haligan *et al.*,<sup>13</sup> the main predictive factors of thrombosis were nephrotic syndrome, immobilization, heart failure, and tobacco use.

In AL amyloidosis, circulating levels of free light-chains and of  $\beta$ 2-microglobulin were shown to be associated with TE risk.<sup>31</sup> Plasma D-dimer level was also associated with a worse prognosis.<sup>32</sup> An impairment of the thrombin–antithrombin (AT) pathway has also been evidenced in AL patients, with lower AT activity than AT antigen associated with reduced binding capacity to heparin, thus leading to a hypercoagulable state.<sup>33</sup>

The use of immunomodulatory drugs (IMiDs) also increases the risk of venous thromboembolism. Current recommendations advise the prescription of prophylactic antithrombotic treatment (vitamin K antagonist, low molecular weight heparin, or aspirin) in patients receiving IMiD-based chemotherapy.<sup>34,35</sup> An increased risk of thalidomide related TE has been shown in multiple myeloma and AL amyloidosis.<sup>36,37</sup>

## Amyloidosis and bleeding risk

The most frequently reported bleedings are ecchymosis and purpura; bleedings from the gastrointestinal tract and the renal tract are also common<sup>38,39,40,41</sup> (*Table 3*). Amyloid deposits can be found in digestive and mucous membranes. Perivascular amyloidosis deposits can lead to amyloid angiopathy that increases capillary fragility and impairs capillary vasomotion. Gastrointestinal bleeding is explained by amyloid deposits causing fragility of the vascular wall, muscle infiltration leading to increased vulnerability of the mucosa and/or intestinal ischaemia.<sup>42,33,43</sup>

Bleeding complications can also occur after an invasive procedure, such as biopsy. Laboratory characteristics reflect the clinical diversity in cohort studies<sup>44,45,46,47</sup> (*Table 4*). Different clotting abnormalities have been described, as shown in *Table 4*. In a study including 337 patients with AL-amyloidosis, Mumford *et al.*<sup>44</sup> reported in 51% of patients at least one abnormality in the semi-global clotting times, namely thrombin time (TT), prothrombin time (PT) or activated partial prothrombin time (aPTT), with substantial variation in the nature and magnitude of the defects. These results were confirmed in further studies.<sup>45,46,47</sup> TT prolongation was potentially related by Mumford *et al.* to abnormal glycosylated fibrinogen resulting in dysfibrinogenemia combined with se-

**Table 3** Prevalence of bleeding events in systemic amyloidosis

Study, date	Population	Prevalence of bleeding	Bleeding description	Favouring factors
Yood <i>et al.</i> , 1983 <sup>37</sup>	100 AL amyloidosis	41/100 = 41% (3% cause of death)	23% petechia and ecchymoses 18% gastrointestinal tract bleeding 8% after procedure 3% haematuria 2% haemoptysis	
Mumford <i>et al.</i> , 2000 <sup>43</sup>	337 AL amyloidosis	28%	18% cutaneous bleeding 5% gastrointestinal bleeding 1% post procedure	Prolongation of thrombin time (32%)
Kumar <i>et al.</i> , 2001 <sup>40</sup>	45 AL amyloidosis treated with blood stem cell	20%	7% of lower GI tract bleeding 9% of upper	Multiorgan involvement haemodialysis
Choufani <i>et al.</i> , 2001 <sup>45</sup>	368 AL amyloidosis	5%, all with FX deficiency	Frequency and severity worse with the lowest levels of FX	FX deficiency < 50%
Mitrani <i>et al.</i> , 2020 <sup>21</sup>	290 ATTR	7% (all had anticoagulant therapy)		Labile INR

AL, immunoglobulin light chain amyloidosis; GI, gastrointestinal; TTR, transthyretin; wTTR, wild type transthyretin; vTTR, variant transthyretin.

**Table 4** Main studies investigating coagulation abnormalities in patients with AL-amyloidosis since 2000

Reference	Study design	Number of patients/sex ratio (male/female)	Median age (years)	Coagulation abnormalities <sup>a</sup> and relationships with clinical features
Mumford AD <i>et al.</i> , 2000 <sup>41</sup>	Retrospective single-centre cohort study	337/0.54	61.2	-TT prolongation (32% of patients) associated with hepatic amyloid deposits ( $P < 10^{-4}$ ), 24-h proteinuria ( $P < 10^{-3}$ ), and hypoalbuminaemia ( $P < 10^{-5}$ ) -PT prolongation (24% of patients) associated with abnormal bleeding ( $P 0.0012$ ) -aPTT prolongation (14% of patients) -FX:C deficiency (<70 IU/dL): 22/154 (14%), of whom 7 (5%) < 20 IU/dL -FX:Ag/FX:C 2.5 in patients with FX deficiency vs FX:Ag/FX:C 0.96 in patients without ( $P < 10^{-4}$ ) -Mild FVII:C deficiency in 2 patients (44 and 23 IU/dL) -Absence of FX inhibitor
Gamba G <i>et al.</i> , 2000 <sup>42</sup>	Prospective	36/2.0	NA	-TT prolongation (85% of patients) -PT prolongation (22% of patients) -aPTT prolongation (65% of patients) - FX:C deficiency (< 65 IU/dL)(27% of patients)
Choufani EB <i>et al.</i> , 2001 <sup>43</sup>	Prospective clinical trial	368/1.5 <sup>b</sup>	58.0 <sup>b</sup>	-FX:C deficiency (< 50 IU/dL): 32/368 (8.7% <sup>a</sup> ) of whom 12 < 25 IU/dL (9 with bleeding complications) -Frequency and severity worse in the patients with the lowest levels of FX
Patel G <i>et al.</i> , 2019 <sup>44</sup>	Retrospective single-centre cohort study	104/0.54	63.4	-FX:C deficiency (<50 IU/dL): 10/104 (9.6% <sup>a</sup> ) of whom 2 < 25 IU/dL

<sup>a</sup>Patients receiving vitamin K antagonist were excluded.

<sup>b</sup>Sex ratio and median age of patients with FX deficiency; TT: thrombin time.

aPTT: activated partial prothrombin time; Ag, antigen; F, factor; FX:C, FX clotting activity; NA, non-available; PT, prothrombin time.

vere hypoalbuminaemia, and subsequent abnormal fibrin polymerization, especially in patients with nephrotic syndrome, who represented 28% of patients in this cohort.<sup>44</sup>

The PT and aPTT prolongation were associated with acquired FX:C deficiency, more rarely FV deficiency. Overall,

FX levels are reduced to below 20 to 50 IU/dL in a relatively small proportion of patients (5% to 10%) with systemic amyloidosis. The frequency of FX deficiency in AL amyloidosis varies across studies. Greipp *et al.*<sup>48</sup> reported a frequency of FX below 20 IU/dL in 6 patients out of 95 patients

(7.6%). Mumford *et al.*<sup>44</sup> reported a frequency of 14% (< 70 IU/dL), of whom 7 (5%) were 20 IU/dL. In a cohort of 368 patients with AL-amyloidosis,<sup>46</sup> 32 patients (7.8%) had an FX level below 50 IU/dL, of whom 18 (56%) had bleeding complications, mostly in those with an FX level below 25 IU/dL. Notably, aggressive chemotherapy combined with autologous haematopoietic cell transplantation improved the amyloid-related FX deficiency.<sup>46</sup> More recently, Patel *et al.* reported an FX deficiency frequency of 9.6% (< 50 IU/dL), with only two patients (2%) with FX < 10 IU/dL.<sup>47</sup> Compared with patients with normal FX activity, patients with FX deficiency were more likely to have a worse disease stage ( $P = 0.05$ ), elevated higher biomarkers (NT-proBNP,  $P = 0.002$ ; cardiac troponin T, cTNT,  $P = 0.03$ ). Remarkably, all patients with the acquired FX deficiency had cardiac involvement, as compared with 70% in the other group ( $P = 0.06$ ).<sup>47</sup> No bleeding occurred in the 10 patients with FX deficiency in the first 12 months of follow-up after FX was measured. (Table 2).

One hypothesis to explain FX deficiency is that FX is eliminated from the circulation by selective binding to amyloid deposits, especially in the perivascular tissues in the spleen. The correction of FX deficiency after splenectomy in some case reports supports this hypothesis.<sup>49</sup> However, this simple FX adsorptive model cannot explain the discrepancy between circulating FX antigen and FX coagulant activity observed in some patients in Mumford's cohort. Additional mechanisms may be involved in FX functional impairment. Recently, the group of Christophe *et al.* have discovered new partners regulating FX circulating levels: they have identified scavenger

receptor class A member 1 (SR-AI) as a receptor for FX at the macrophage surface and pentraxin-2 (PTX2), which forms a ternary complex with SR-AI and FX.<sup>50</sup> PTX2 is essential to prevent internalization of FX by SR-AI. Like FX, PTX2 may be targeted to amyloid plaques. Because SR-AI/PTX2/FX complex is necessary to maintain normal plasma levels of FX and PTX2, a disequilibrium in the complex may contribute to a depletion in FX in systemic AL-amyloidosis.

## Antithrombotic drugs in amyloidosis

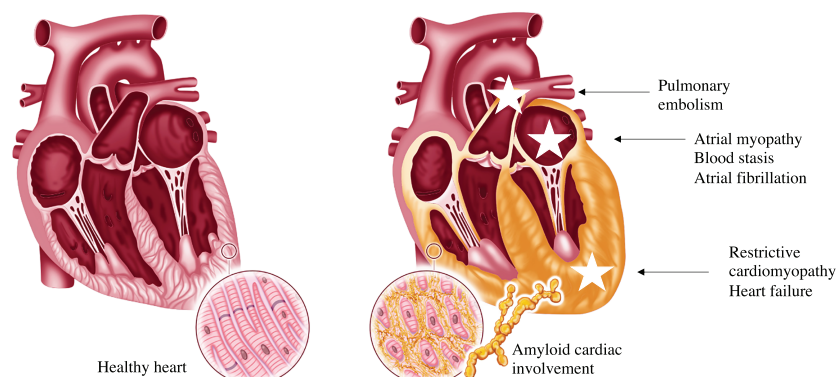
Currently, the main indications of anticoagulation in secondary prevention are AF, regardless of CHADS2-VaSC score, deep vein thrombosis and/or pulmonary embolism, nephrotic syndrome with hypoalbuminaemia <20 g/L and unexpected intracardiac thrombus diagnosed during cardiac imaging (echocardiography, computed tomography scan, and magnetic resonance imaging)<sup>18</sup> (Figure 1).

The situations that are to be considered for prescribing prophylactic anticoagulation are the prescription of IMiDs, heart failure hospitalization, a history of arterial thrombosis (stroke with presumed embolic origin, TIA) in the absence of a curable cause, a nephrotic syndrome with albuminaemia >20 g/L.

The contraindications to anticoagulant treatment are less well established. The most common are active digestive bleeding requiring blood transfusion (especially if linked to diffuse amyloid digestive involvement), coagulation disorder

**Figure 1** Main determinants of thromboembolism and bleeding in systemic amyloidosis.

Pros and Cons of prescribing antithrombotic therapy in cardiac amyloidosis	
Pros	Cons
<ul style="list-style-type: none"> <li>- History of venous thromboembolism or stroke</li> <li>- Atrial fibrillation</li> <li>- Atrial myopathy</li> <li>- Heart failure</li> <li>- Nephrotic syndrome in AL amyloidosis</li> <li>- IMiD based chemotherapy in AL amyloidosis</li> </ul>	<ul style="list-style-type: none"> <li>- Digestive involvement causing bleeding</li> <li>- FX deficiency, especially if &lt; 50%</li> <li>- Severe cytopenias</li> <li>- Liver amyloidosis involvement</li> <li>- Dysautonomia leading to fall</li> </ul>



ders, especially FX < 50 IU/dL. Other risky situations that do not represent absolute contraindications to anticoagulant therapy are cytopenia, hepatic amyloid damage and renal failure.

There are important differences between AL and TTR amyloidosis (Table 5). Indeed, AL amyloidosis seems associated with a greater risk of haemorrhage because digestive involvement is more often present, association with a myeloma can lead to cytopenia, FX deficiency is associated with AL amyloidosis, renal failure is more common. There are also more interactions between anticoagulants and the treatments for AL amyloidosis (corticosteroids, chemotherapy: proteasome inhibitors, IMiDs, daratumumab). Conversely, tafamidis, the only approved treatment for ATTR cardiomyopathy, does not appear to interact with cytochrome CYP3A4.

## Vitamin K antagonists

Vitamin K antagonist (VKA) response is marked by inter-patient and intra-patient variability. Acute illnesses, deterioration in chronic comorbidities or changes in associated drugs may dramatically impact anticoagulation control. Especially, VKAs interact with chemotherapy in AL amyloidosis. Thus, managing patients with amyloidosis may be challenging requiring a close monitoring of international normalized ratio (INR). INR takes the advantage of being widely available and cheap. In addition, there is an easy-to-use antidote for overdose. Finally, VKA is an inexpensive treatment that can be used in patients with severe renal failure (Figure 1). In the study by Mitrani *et al.*, which included only TTR cardiomyopathies, INR lability was noted in 87% of patients. The event rate of major bleeds was 3.7 per 100 person years in this study as compared to 2.2–3.9 in the general population.<sup>51</sup>

## Direct oral anticoagulants (DOACs)

The pharmacokinetics of the 3 most used direct oral anticoagulants (DOACs) are very different.<sup>52</sup> Dabigatran has predominantly renal clearance (80%) and hepatic clearance (20%)

and is not metabolized by cytochrome CYP3A4. Rivaroxaban and apixaban have predominantly hepatic clearance (65% and 73%, respectively). They also are both metabolized by CYP3A4.

The main advantages of DOACs are their easy use, rapid efficacy within a few hours after introduction, oral administration, and a wide therapeutic window. The data published in venous thrombosis in cancer patients have shown the efficacy and safety of DOACs.<sup>53,54</sup> There are few safety data concerning apixaban use for venous thrombotic prevention in multiple myeloma treated with IMiD-based chemotherapy<sup>55</sup>; indeed, no signal of ineffectiveness (little or no thrombosis) or higher risk of bleeding has been reported. Mitrani *et al.*<sup>21</sup> have published the only available data on the use of DOACs in ATTR cardiomyopathy. There was no difference in thrombotic or haemorrhagic events compared to VKA treatment.

One of the main drawbacks of DOACs use is the management of patients with life-threatening bleedings or in emergency situations. The use of specific antidotes is expensive and may expose patients to an increased risk of thrombotic complications. Secondly, there are drug interactions with chemotherapies used in AL amyloidosis. For example, dexamethasone (CYP3A4 inducer) may decrease DOAC levels and lead to lower levels of anticoagulation. There is also an increased risk of gastrointestinal bleeding especially with dabigatran and rivaroxaban.<sup>56,57</sup> However, the Amplify study<sup>53</sup> showed the benefit of apixaban in major bleeding as compared with controls thanks to a decrease in gastrointestinal bleeding in cancer patients. In the general population, the rate of major bleeding in patients treated with DOAC is 2.9 to 4 per 100 person years.<sup>51,58</sup> In Mitrani *et al.* data<sup>21</sup> (TTR anticoagulated amyloidosis), this event rate was 5.2 per 100 patient years. Finally, xabans and dabigatran are contra-indicated in severe renal failure with creatinine clearance <15 and 30 mL/min, respectively, and 60% of AL amyloidosis patients have renal involvement. Furthermore, 10% to 15% of patients have liver damage which may also limit their prescription.

Direct oral anticoagulants could be used safely in TTR amyloidosis in the absence of severe renal failure. During the administration of chemotherapy containing dexamethasone,

**Table 5** Specific thrombotic and bleeding risks according to the type of amyloidosis

Type of amyloidosis	Prothrombotic risk factors	Bleeding risk factors
AL	<ul style="list-style-type: none"> <li>• Nephrotic syndrome</li> <li>• Use of IMiD</li> <li>• Heart failure</li> <li>• Higher free light chains and beta-2 microglobulin level</li> <li>• Atrial fibrillation</li> </ul>	<ul style="list-style-type: none"> <li>• Digestive involvement</li> <li>• Liver involvement</li> <li>• FX deficiency</li> <li>• Drug interactions (chemotherapy and oral anticoagulants)</li> </ul>
TTR	<ul style="list-style-type: none"> <li>• Atrial fibrillation</li> <li>• Heart failure</li> <li>• Atrial myopathy</li> </ul>	<ul style="list-style-type: none"> <li>• Age</li> <li>• Risk of fall (dysautonomia, conductive disorder)</li> <li>• Renal failure, haemodialysis</li> </ul>

AL, immunoglobulin light chain amyloidosis; IMiD, immunomodulatory drugs; TTR: transthyretin.

anticoagulant therapy with low molecular weight heparin is preferred. On the other hand, once the patient is in remission and no longer receiving chemotherapy, anticoagulation by DOACs may be considered. Apixaban has shown a reduction in digestive bleeding in cancer patients with venous thromboembolism.<sup>53</sup>

Finally, the MYELAXAT<sup>59</sup> study has tested the protective effect of apixaban (2.5 mg twice daily) for 6 months in multiple myeloma patients (all with creatinine clearance >30 mL/min) and treated with IMiD (thalidomide and/or lenalidomide). In this non-controlled and non-randomized study, 104 patients were included. Two patients experienced a TE (the incidence of TE was 0.38 patient-months in the entire population, 95% CI 0.05–1.4). Neither arterial cardiovascular event, nor pulmonary embolism, and no death due to venous TE was observed. Eleven patients experienced bleeding: 10 clinically relevant non major bleedings [incidence 1.9% patient-months (95% CI 0.9–3.5)] and one major bleeding requiring blood transfusion [incidence 0.19% patient-months (95% CI 0.04–1.1)]. These preliminary data suggest the safety of this DOAC in myeloma patients.

### Low molecular weight heparins

Low molecular weight heparin (enoxaparin and tinzaparin) are widely used. These treatments are easy to handle with a short half-life making it possible to stop them in case of bleeding. There are few drug interactions, especially with chemotherapy. However, low molecular weight heparin need subcutaneous injection and are contraindicated if creatinine renal clearance is below 15–20 mL/min. Moreover, a substan-

tial decrease of AT activity may lead to a suboptimal effect of heparin derivatives.

### Left atrial appendage closure

Some CA patients with AF with or without previous cardioembolic event have a history of severe bleeding, such as diffuse digestive bleeding. In these cases, a left atrial appendage closure has to be considered in order to stop or to avoid anticoagulation.

## Conclusions

Thromboembolic and haemorrhagic events are frequent and major issues in cardiac AL and TTR amyloidosis. Physicians should systematically look for factors favouring thromboembolism such as heart failure, atrioopathy, supraventricular arrhythmias, history of a previous thromboembolic event, nephrotic syndrome, and thrombotic risk related to chemotherapy. The thrombotic risk has to be weighed with the haemorrhagic risk that is increased by amyloid digestive or liver involvement, coagulation disorders such as FX deficiency, renal failure, thrombopathy. Prospective studies are needed to specify when and how to prescribe preventive antithrombotic therapy in this specific population.

## Conflict of interest

Nothing to declare.

## References

- Falk RH. Diagnosis and management of the cardiac amyloidoses. *Circulation* 2005; **112**: 2047–2060.
- Rapezzi C, Merlini G, Quarta CC, Riva L, Longhi S, Leone O, Salvi F, Ciliberti P, Pastorelli F, Biagini E, Coccolo F, Cooke RMT, Bacchi-Reggiani L, Sangiorgi D, Ferlini A, Cavo M, Zamagni E, Fonte ML, Palladini G, Salinaro F, Musca F, Obici L, Branzi A, Perlini S. Systemic cardiac amyloidoses: disease profiles and clinical courses of the 3 main types. *Circulation* 2009; **120**: 1203–1212.
- Gertz MA, Dispenzieri A. Systemic amyloidosis recognition, prognosis, and therapy: a systematic review. *JAMA* 2020 07; **324**: 79–89.
- González-López E, Gallego-Delgado M, Guzzo-Merello G, de Haro-Del Moral FJ, Cobo-Marcos M, Robles C, Bornstein B, Salas C, Lara-Pezzi E, Alonso-Pulpon L, Garcia-Pavia P. Wild-type transthyretin amyloidosis as a cause of heart failure with preserved ejection fraction. *Eur Heart J* 2015; **36**: 2585–2594.
- Damy T, Costes B, Hagège AA, Donal E, Eicher J-C, Slama M, Guellich A, Rappeneau S, Gueffet JP, Logeart D, Planté-Bordeneuve V. Prevalence and clinical phenotype of hereditary transthyretin amyloid cardiomyopathy in patients with increased left ventricular wall thickness. *Eur Heart J* 2016 14; **37**: 1826–1834.
- Feng D, Edwards WD, Oh JK, Chandrasekaran K, Grogan M, Martinez MW, Syed II, Hughes DA, Lust JA, Jaffe AS, Gertz MA, Klarich KW. Intracardiac thrombosis and embolism in patients with cardiac amyloidosis. *Circulation* 2007; **116**: 2420–2426.
- Bøtker HE, Rasmussen OB. Recurrent cerebral embolism in cardiac amyloidosis. *Int J Cardiol* 1986; **13**: 81–83.
- Santarone M, Corrado G, Tagliagambe LM, Manzillo GF, Tadeo G, Spata M, Longhi M. Atrial thrombosis in cardiac amyloidosis: diagnostic contribution of transesophageal echocardiography. *J Am Soc Echocardiogr Off Publ Am Soc Echocardiogr* 1999; **12**: 533–536.
- Cools FJ, Kockx MM, Boeckxstaens GE, Heuvel PV, Cuykens JJ. Primary systemic amyloidosis complicated by massive thrombosis. *Chest* 1996; **110**: 282–284.
- Willens HJ, Levy R, Kessler KM. Thromboembolic complications in cardiac amyloidosis detected by transesophageal echocardiography. *Am Heart J* 1995; **129**: 405–406.
- Browne RS, Schneiderman H, Kayani N, Radford MJ, Hager WD. Amyloid heart disease manifested by systemic arterial thromboemboli. *Chest* 1992; **102**: 304–307.
- Cappelli F, Tini G, Russo D, Emdin M, Del Franco A, Vergaro G, Di Bella G,



- Mazzeo A, Canepa M, Volpe M, Perfetto F. Arterial thrombo-embolic events in cardiac amyloidosis: a look beyond atrial fibrillation. *Amyloid Int J Exp Clin Investig Off J Int Soc Amyloidosis* 2020; **28**: 1–7.
13. Halligan CS, Lacy MQ, Vincent Rajkumar S, Dispenziera A, Witzig TE, Lust JA, Fonseca R, Gertz MA, Kyle RA, Pruthi RK. Natural history of thromboembolism in AL amyloidosis. *Amyloid Int J Exp Clin Investig Off J Int Soc Amyloidosis* 2006; **13**: 31–36.
  14. Zubkov AY, Rabinstein AA, Dispenziera A, Wijdicks EFM. Primary systemic amyloidosis with ischemic stroke as a presenting complication. *Neurology* 2007; **69**: 1136–1141.
  15. Nitsche C, Scully PR, Patel KP, Kammerlander AA, Koschutnik M, Dona C, Wollenweber T, Ahmed N, Thornton GD, Kelion AD, Sabharwal N, Newton JD, Ozkor M, Kennon S, Mullen M, Lloyd G, Fontana M, Hawkins PN, Pugliese F, Menezes LJ, Moon JC, Mascherbauer J, Treibel TA. Prevalence and outcomes of concomitant aortic stenosis and cardiac amyloidosis. *J Am Coll Cardiol* 2021; **77**: 128–139.
  16. Vergaro G, Aimo A, Barison A, Genovesi D, Buda G, Passino C, Emdin M. Keys to early diagnosis of cardiac amyloidosis: red flags from clinical, laboratory and imaging findings. *Eur J Prev Cardiol* 2020; **27**: 1806–1815.
  17. Feng D, Syed IS, Martinez M, Oh JK, Jaffe AS, Grogan M, Edwards WD, Gertz MA, Klarich KW. Intracardiac thrombosis and anticoagulation therapy in cardiac amyloidosis. *Circulation* 2009; **119**: 2490–2497.
  18. Martinez-Naharro A, Gonzalez-Lopez E, Corovic A, Mirelis JG, Baksi AJ, Moon JC, Garcia-Pavia F, Gillmore JD, Hawkins PN, Fontana M. High prevalence of intracardiac thrombi in cardiac amyloidosis. *J Am Coll Cardiol* 2019 09; **73**: 1733–1734.
  19. Sanchis K, Cariou E, Colombat M, Ribes D, Huart A, Cintas P, Fournier P, Rollin A, Carrié D, Galinier M, Maury P, Duparc A, Lairez O, Toulouse Amyloidosis Research Network collaborators. Atrial fibrillation and subtype of atrial fibrillation in cardiac amyloidosis: clinical and echocardiographic features, impact on mortality. *Amyloid Int J Exp Clin Investig Off J Int Soc Amyloidosis* 2019; **26**: 128–138.
  20. Longhi S, Quarta CC, Milandri A, Lorenzini M, Gagliardi C, Manuzzi L, Bacchi-Reggiani ML, Leone O, Ferlini A, Russo A, Gallelli I, Rapezzi C. Atrial fibrillation in amyloidotic cardiomyopathy: prevalence, incidence, risk factors and prognostic role. *Amyloid Int J Exp Clin Investig Off J Int Soc Amyloidosis* 2015; **22**: 147–155.
  21. Mitrani LR, De Los Santos J, Driggin E, Kogan R, Helmke S, Goldsmith J, Biviano AB, Maurer MS. Anticoagulation with warfarin compared to novel oral anticoagulants for atrial fibrillation in adults with transthyretin cardiac amyloidosis: comparison of thromboembolic events and major bleeding. *Amyloid Int J Exp Clin Investig Off J Int Soc Amyloidosis* 2020; **28**: 30–34.
  22. Donnellan E, Wazni OM, Hanna M, Elshazly MB, Puri R, Saliba W, Kanj M, Vakamudi S, Patel DR, Baranowski B, Cantillon D, Dresing T, Jaber WA. Atrial fibrillation in transthyretin cardiac amyloidosis: predictors, prevalence, and efficacy of rhythm control strategies. *JACC Clin Electrophysiol* 2020; **6**: 1118–1127.
  23. Mints YY, Doros G, Berk JL, Connors LH, Ruberg FL. Features of atrial fibrillation in wild-type transthyretin cardiac amyloidosis: a systematic review and clinical experience. *ESC Heart Fail* 2018; **5**: 772–779.
  24. El-Am EA, Dispenziera A, Melduni RM, Ammash NM, White RD, Hodge DO, Noseworthy PA, Lin G, Pislaru SV, Egbe AC, Grogan M. Direct current cardioversion of atrial arrhythmias in adults with cardiac amyloidosis. *J Am Coll Cardiol* 2019 12; **73**: 589–597.
  25. Dubrey S, Pollak A, Skinner M, Falk RH. Atrial thrombi occurring during sinus rhythm in cardiac amyloidosis: evidence for atrial electromechanical dissociation. *Br Heart J* 1995; **74**: 541–544.
  26. Röcken C, Peters B, Juenemann G, Saeger W, Klein HU, Huth C, Roessner A, Goette A. Atrial amyloidosis: An arrhythmogenic substrate for persistent atrial fibrillation. *Circulation* 2002; **106**: 2091–2097.
  27. Brand A, Frumkin D, Hübscher A, Dreger H, Stangl K, Baldenhofer G, Knebel F. Phasic left atrial strain analysis to discriminate cardiac amyloidosis in patients with unclear thick heart pathology. *Eur Heart J Cardiovasc Imaging* 2021; **22**: 680–687.
  28. Mohty D, Petitalot V, Magne J, Fadel BM, Boulogne C, Rouabhia D, el Hamel C, Lavergne D, Damy T, Aboyans V, Jaccard A. Left atrial function in patients with light chain amyloidosis: a transthoracic 3D speckle tracking imaging study. *J Cardiol* 2018; **71**: 419–427.
  29. Mohty D, Boulogne C, Magne J, Varroud-Vial N, Martin S, Ettaif H, Fadel BM, Bridoux F, Aboyans V, Damy T, Jaccard A. Prognostic value of left atrial function in systemic light-chain amyloidosis: a cardiac magnetic resonance study. *Eur Heart J Cardiovasc Imaging* 2016; **17**: 961–969.
  30. Hausfater P, Costedoat-Chalumeau N, Amoura Z, Cacoub P, Papo T, Grateau G, Leblond V, Godeau P, Piette JC. AL cardiac amyloidosis and arterial thromboembolic events. *Scand J Rheumatol* 2005; **34**: 315–319.
  31. Park H, Kim J-W, Youk J, Koh Y, Lee J-O, Kim KH, Bang SM, Kim I, Park S, Yoon SS. Serum free light chain difference and  $\beta 2$  microglobulin levels are risk factors for thromboembolic events in patients with AL amyloidosis. *Clin Lymphoma Myeloma Leuk* 2018; **18**: 408–414.
  32. Pudusseri A, Sanchorawala V, Sloan JM, Bever KM, Doros G, Kataria S, Sarosiek S. Prevalence and prognostic value of D-dimer elevation in patients with AL amyloidosis. *Am J Hematol* 2019; **94**: 1098–1103.
  33. Sattianayagam PT, Hawkins PN, Gillmore JD. Systemic amyloidosis and the gastrointestinal tract. *Nat Rev Gastroenterol Hepatol* 2009; **6**: 608–617.
  34. Larocca A, Cavallo F, Bringhen S, Di Raimondo F, Falanga A, Evangelista A, Cavalli M, Stanevsky A, Corradini P, Pezzatti S, Patriarca F. Aspirin or enoxaparin thromboprophylaxis for patients with newly diagnosed multiple myeloma treated with lenalidomide. *Blood* 2012; **119**: 933–939 quiz 1093.
  35. Palumbo A, Cavo M, Bringhen S, Zamagni E, Romano A, Patriarca F, Rossi D, Gentilini F, Crippa C, Galli M, Nozzoli C, Ria R, Marasca R, Montefusco V, Baldini L, Elice F, Callea V, Pulini S, Carella AM, Zambello R, Benevolo G, Magarotto V, Tacchetti P, Pescosta N, Cellini C, Polloni C, Evangelista A, Caravita T, Morabito F, Offidani M, Tosi P, Boccadoro M. Aspirin, warfarin, or enoxaparin thromboprophylaxis in patients with multiple myeloma treated with thalidomide: a phase III, open-label, randomized trial. *J Clin Oncol Off J Am Soc Clin Oncol* 2011; **29**: 986–993.
  36. Catovsky D, Ikoku NB, Pitney WR, Galton DA. Thromboembolic complications in myelomatosis. *Br Med J* 1970; **3**: 438–439.
  37. Osman K, Comenzo R, Rajkumar SV. Deep venous thrombosis and thalidomide therapy for multiple myeloma. *N Engl J Med* 2001; **344**: 1951–1952.
  38. Yood RA, Skinner M, Rubinow A, Talarico L, Cohen AS. Bleeding manifestations in 100 patients with amyloidosis. *JAMA* 1983; **249**: 1322–1324.
  39. Tanaka Y, Hosotani K, Fukushima M. A case of amyloid light-chain amyloidosis presenting with submucosal hematoma and bleeding in the upper gastrointestinal tract. *Clin Gastroenterol Hepatol Off Clin Pract J Am Gastroenterol Assoc* 2020; **18**: e158–e159.
  40. Sundaram S, Rathod R. Gastric amyloidosis causing nonvariceal upper gastrointestinal bleeding. *ACG Case Rep J* 2019; **6**: 3–4.
  41. Kumar S, Dispenziera A, Lacy MQ, Litzow MR, Gertz MA. High incidence of gastrointestinal tract bleeding after autologous stem cell transplant for primary systemic amyloidosis. *Bone Marrow Transplant* 2001; **28**: 381–385.
  42. Gould M, Zarrin-Khameh N, Sellin J. Small bowel amyloidosis. *Curr Gastroenterol Rep* 2013; **15**: 350.
  43. Cowan AJ, Skinner M, Seldin DC, Berk JL, Lichtenstein DR, O'Hara CJ, Doros G, Sanchorawala V. Amyloidosis of the gastrointestinal tract: a 13-year, single-

- center, referral experience. *Haematologica* 2013; **98**: 141–146.
44. Mumford AD, O'Donnell J, Gillmore JD, Manning RA, Hawkins PN, Laffan M. Bleeding symptoms and coagulation abnormalities in 337 patients with AL-amyloidosis. *Br J Haematol* 2000; **110**: 454–460.
  45. Gamba G, Montani N, Anesi E, Palladini G, Lorenzutti F, Perfetti V, Merlini G. Abnormalities in thrombin-antithrombin pathway in AL amyloidosis. *Amyloid Int J Exp Clin Investig Off J Int Soc Amyloidosis* 1999; **6**: 273–277.
  46. Choufani EB, Sanchorawala V, Ernst T, Quillen K, Skinner M, Wright DG, Seldin DC. Acquired factor X deficiency in patients with amyloid light-chain amyloidosis: incidence, bleeding manifestations, and response to high-dose chemotherapy. *Blood* 2001; **97**: 1885–1887.
  47. Patel G, Hari P, Szabo A, Rein L, Kreuziger LB, Chhabra S, Dhakal B, D'Souza A. Acquired factor X deficiency in light-chain (AL) amyloidosis is rare and associated with advanced disease. *Hematol Oncol Stem Cell Ther* 2019; **12**: 10–14.
  48. Greipp PR, Kyle RA, Bowie EJ. Factor-X deficiency in amyloidosis: a critical review. *Am J Hematol* 1981; **11**: 443–450.
  49. Rosenstein ED, Itzkowitz SH, Penziner AS, Cohen JI, Mornaghi RA. Resolution of factor X deficiency in primary amyloidosis following splenectomy. *Arch Intern Med* 1983; **143**: 597–599.
  50. Muczynski V, Aymé G, Regnault V, Vasse M, Borgel D, Legendre P, Bazaa A, Harel A, Loubière C, Lenting PJ, Denis CV, Christophe OD. Complex formation with pentraxin-2 regulates factor X plasma levels and macrophage interactions. *Blood* 2017; **129**: 2443–2454.
  51. van Walraven C, Hart RG, Singer DE, Laupacis A, Connolly S, Petersen P, Koudstaal PJ, Chang Y, Hellemons B. Oral anticoagulants vs aspirin in nonvalvular atrial fibrillation: an individual patient meta-analysis. *JAMA* 2002; **288**: 2441–2448.
  52. Steffel J, Verhamme P, Potpara TS, Albaladejo P, Antz M, Desteghe L, Haeusler KG, Oldgren J, Reinecke H, Roldan-Schilling V, Rowell N, Sinnaeve P, Collins R, Camm AJ, Heidbüchel H, ESC Scientific Document Group, Lip GYH, Weitz J, Fauchier L, Lane D, Boriani G, Goette A, Keegan R, MacFadyen R, Chiang CE, Joung B, Shimizu W. The 2018 European Heart Rhythm Association practical guide on the use of non-vitamin K antagonist oral anticoagulants in patients with atrial fibrillation. *Eur Heart J* 2018; **39**: 1330–1393.
  53. Agnelli G, Becattini C, Meyer G, Muñoz A, Huisman MV, Connors JM, Cohen A, Bauersachs R, Brenner B, Torbicki A, Suevo MR, Lambert C, Gussoni G, Campanini M, Fontanella A, Vescovo G, Verso M. Apixaban for the treatment of venous thromboembolism associated with cancer. *N Engl J Med* 2020; **382**: 1599–1607.
  54. Khorana AA, Soff GA, Kakkar AK, Vadhan-Raj S, Riess H, Wun T, Streiff MB, Garcia DA, Liebman HA, Belani CP, O'Reilly EM, Patel JN, Yimer HA, Wildgoose P, Burton P, Vijapurkar U, Kaul S, Eikelboom J, McBane R, Bauer KA, Kuderer NM, Lyman GH. Rivaroxaban for thromboprophylaxis in high-risk ambulatory patients with cancer. *N Engl J Med* 2019; **380**: 720–728.
  55. Cornell RF, Goldhaber SZ, Engelhardt BG, Moslehi J, Jagasia M, Harrell S, Rubinstein SM, Hall R, Wyatt H, Piazza G. Primary prevention of venous thromboembolism with apixaban for multiple myeloma patients receiving immunomodulatory agents. *Br J Haematol* 2020; **190**: 555–561.
  56. Schulman S, Kearon C, Kakkar AK, Mismetti P, Schellong S, Eriksson H, Baanstra D, Schnee J, Goldhaber SZ. Dabigatran versus warfarin in the treatment of acute venous thromboembolism. *N Engl J Med* 2009; **361**: 2342–2352.
  57. EINSTEIN-PE Investigators, Büller HR, Prins MH, Lensin AWA, Decousus H, Jacobson BF, Minar E, Chlumsky J, Verhamme P, Wells P, Agnelli G, Cohen A. Oral rivaroxaban for the treatment of symptomatic pulmonary embolism. *N Engl J Med* 2012; **366**: 1287–1297.
  58. Lamberts M, Staerk L, Olesen JB, Fosbøl EL, Hansen ML, Harboe L, Lefevre C, Evans D, Gislason GH. Major bleeding complications and persistence with oral anticoagulation in non-valvular atrial fibrillation: contemporary findings in real-life Danish patients. *J Am Heart Assoc* 2017; **6**: e004517.
  59. Pegourie B, Karlin L, Benboubker L, Orsini-Piocelle F, Tiab M, Auger-Quittet S, Rodon P, Royer B, Leleu X, Bareau B, Cliquennois M, Fuzibet JG, Voog E, Belhadj-Merzoug K, Decaux O, Rey P, Slama B, Leyronnas C, Zarnitsky C, Boyle E, Bosson JL, Pernod G, for the IFM Group. Apixaban for the prevention of thromboembolism in immunomodulatory-treated myeloma patients: Myelaxat, a phase 2 pilot study. *Am J Hematol* 2019; **94**: 635–640.