

Osseous involvement in rhinosporidiosis

Atin Kumar Kundu, Satyendra Phuljhele, Mantu Jain, Raman Kumar Srivastava

ABSTRACT

Rhinosporidiosis is a chronic granulomatous disease caused by *Rhinosporidium seeberi*. It usually affects the mucocutaneous tissue of the nose. Bone involvement is rare. We report a case of Rhinosporidiosis of the nasopharynx which later involved the right little finger where ray amputation was performed.

Key words: Rhinosporidiosis, osseous involvement, little finger

INTRODUCTION

Rhinosporidiosis is a chronic granulomatous disease caused by *Rhinosporidium seeberi*. It is found both in man and animals and is mostly transmitted by direct contact with spores through dust, infected clothing or fingers and bathing in stagnant water.¹ The usual site of affection is the nasopharyngeal mucous membrane followed by ocular involvement; other sites like bones are rare.² We report a case of osseous spread of rhinosporidiosis involving the hand in a patient with a previous surgery for nasal polyp.

CASE REPORT

A 23 year male, farmer by profession of Raipur District, Chhattisgarh, India presented with 1 year history of progressive swelling over ulnar aspect of the right hand. He could not recollect any history of trauma. The mass caused occasional discomfort. It had ulcerated with bleeding 1 month ago. He had since earlier been operated thrice for nasal polyp in past 5 years, which was however confirmed as Rhinosporidiosis on biopsy.

Clinical examination revealed the swelling to be warm, circumscribed, firm, measuring 5 cm × 4 cm and largely

confined to ulnar aspect of hand [Figure 1a and b]. The swelling had multiple ulcerations with friable tissue and bleeding points. Movements of hand were almost full with slight restriction of movement of 4th and 5th fingers. Examination of the nose revealed a small polyp in right antrum [Figure 2]. He also had a swelling of the right lacrimal gland. Radiograph of the hand revealed soft-tissue swelling with destruction of the distal part of 5th metacarpal and whole of proximal phalanx. There was no periosteal reaction or soft tissue calcification [Figure 3]. Magnetic resonance imaging scan of the hand confirmed the roentographic findings [Figure 4a and b]. Hematological examinations revealed a total white cell count of 8,400/mm³; the differential count was: 64% Neutrophils, 4% eosinophils, 24% lymphocytes and 8% monocytes. The erythrocyte sedimentation rate was 40 mm/1st hour. A clinicoradiological diagnosis of osseous rhinosporidiosis was made. A biopsy was taken to confirm the diagnosis.

Cytology showed sporangia with ruptured walls containing spores of varying sizes [Figure 5a]. Histopathological examination revealed multiple sporangia harboring numerous endospores, with the intervening stroma containing moderate infiltrates of lymphocytes, plasma cells and histiocytes. The diagnosis of rhinosporidiosis was established [Figure 5b].

The patient was counselled for ray amputation and prognosis discussed at length. A racket shaped incision was made and wide margin excision was carried out. The patient had an uneventful recovery postoperatively and received tab Dapsone (100 mg bid) for 6 months. The patient had subsequently polypectomy and dacrocystectomy carried out for nasal and eye problems respectively. Biopsy reports of both were consistent with rhinosporidiosis. Patient was doing well without any signs of recurrence at one year followup [Figure 6].

Department of Orthopedics, Pt. JNM Medical College, Raipur, Chhattisgarh, India

Address for correspondence: Dr. Mantu Jain,
347/J, Janta Colony, Gudiyari, Raipur - 492 011, Chhattisgarh, India.
E-mail: montu_jn@yahoo.com

Access this article online	
Quick Response Code:	Website: www.ijoonline.com
	DOI: 10.4103/0019-5413.118212

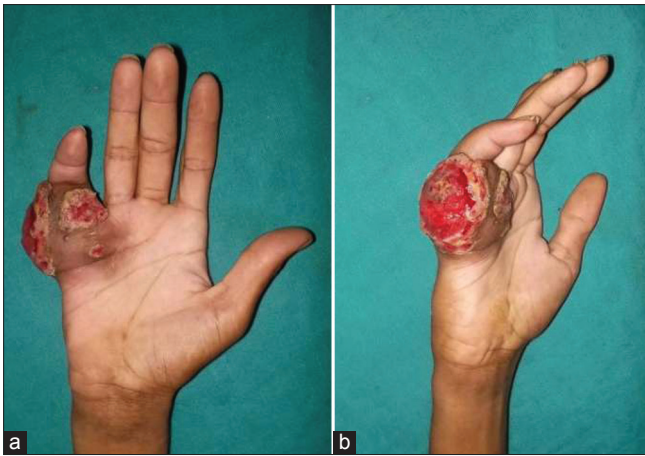


Figure 1: Clinical photograph of hand (a) volar view (b) ulnar oblique view showing the swelling with ulceration

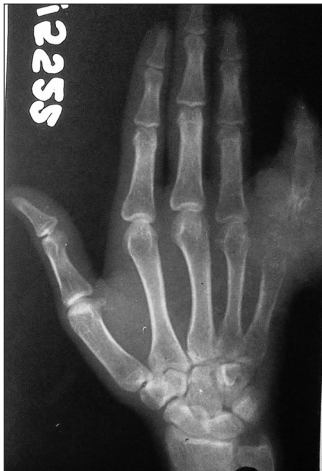

Figure 3: X-ray of the hand (anteroposterior view) showing osteolytic lesion involving the proximal phalanx and part of 5th metacarpal. There is no periosteal reaction

DISCUSSION

The disease rhinosporidiosis, caused by *R. seeberi*, has been described in humans and animals since 1892. The organism has never been isolated *in vitro* and its taxonomic position remains debatable with recent inclusion into a new class the *Mesomycetozoea*.³ Rhinosporidiosis has been reported from about 70 countries with diverse geographical features although the highest incidence has been from South Asia namely Srilanka and India. In India, the distribution is largely subtropical with Chhattisgarh being an endemic area.⁴

It is more common in adult men and is possibly transmitted to humans by direct contact with spores through dust, infected clothing or fingers and bathing in stagnant waters.¹ Other modes of transmission include autoinoculation and hematogenous.⁵ Though rhinosporidiosis is an infective disease; it is not infectious as no transmission has ever

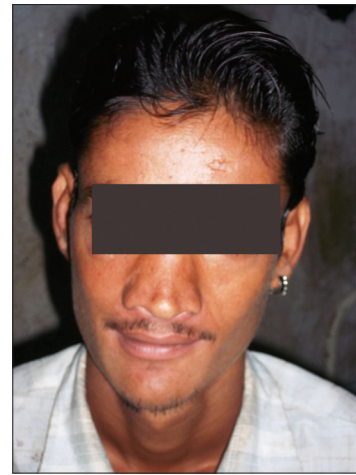

Figure 2: Flaring of the nose and swelling of right lacrimal gland partly obscured under black band

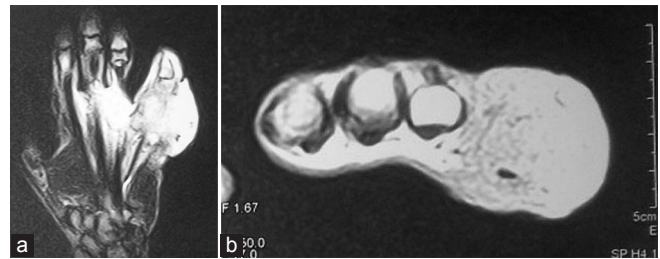


Figure 4: MRI (Rt) hand (a) coronal T2W image of the hand showing the lesion; (b) axial T1W image at the site of lesion

been documented of cross-infection between members of the same family or between animals and humans.⁶

Rhinosporidiosis frequently involves the nasopharynx (70%)² presenting as a painless, friable, polypoidal growth that are pink or purple-red and studded with minute white dots, which are sporangia containing the spores. Extra nasal involvement of the conjunctiva and lacrimal sac are common. Occasionally, rhinosporidiosis affects the lips, palate, uvula, maxillary antrum, epiglottis, larynx, trachea, bronchus, ear, scalp, vulva, vagina, penis, rectum and the skin.² Bony involvement is rare. Isolated osteolytic lesions have been reported involving the talus,⁷ tibia,^{8,9} femoral condyle,^{2,10} hand and feet,¹¹ calcaneum,¹² and clavicle.¹³ Dissemination to anatomically unrelated sites is mainly attributed to hematogenous spread.⁵ Direct implantation by contaminated nasal secretions either during trauma or surgery can also implant the spores and cause secondary lesions.⁵

Differential diagnosis includes tumorous conditions such as giant cell tumor,¹¹ chondrosarcoma,⁸ other sporoidal infections and granulomatous conditions, which have to be excluded by histopathology. The sporangium of *R. seeberi* is larger and has thicker walls (diameter of 50-100 mm vs. 20-80 mm) as compared with *Coccidioides immitis*. The size

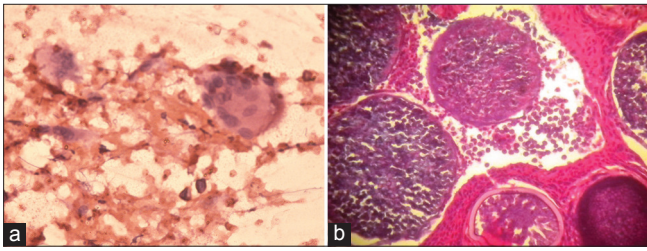


Figure 5: (a) Photomicrographs of cytology smear showing ruptured sporangium with dispersed endospores (H and E, $\times 400$); (b) Photomicrographs of histopathological section showing the multiple sporangia with endospores (H and E, $\times 100$)

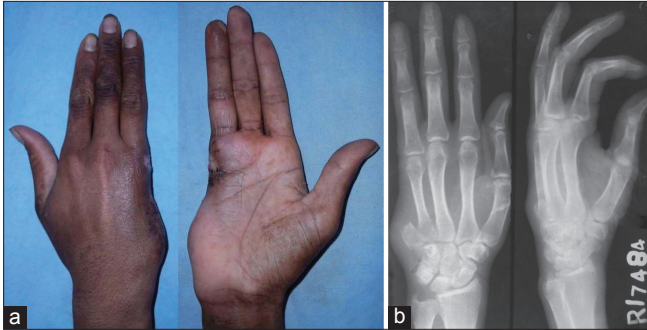


Figure 6: (a) Followup clinical photograph of hand showing ray amputation of little finger (b) X-ray of the hand (anteroposterior and oblique views) at one year followup showing that there are no signs of recurrence

and number of endospores on sporangia of *R. seeberi* is also greater than those of *C. immitis*.¹⁰ *C. immitis* is cultivable and stains with mucicarmine. Further, paucity of eosinophils or eosinophilic precipitates (*Splenderr-Hoeppli phenomenon*) contrasts rhinosporidiosis with opportunistic, mycelial or deep mycosis.^{14,15}

Surgical excision of the mass with wide margins by diathermy is the treatment of choice whenever possible to prevent recurrence. Dapsone has been the gold standard antimicrobial agent to prevent recurrence, but its effectiveness has been debatable owing to impenetrability of the sporangial wall.¹⁶ In osseous lesions with pathological breach of the cortex and soft tissue involvement, salvage is difficult. Therefore, in the present case 5th ray amputation was performed.

Osseous dissemination of rhinosporidiosis is rare and can mimic primary bone tumor and it requires a high degree of clinical suspicion with proper pathological support owing to paucity of radiological clues. Team of surgeons is often required as in present case with appropriate antimicrobial drugs to prevent recurrence.

ACKNOWLEDGMENT

The Author would like to thank the patient for providing

consent to use his photograph in this article.

REFERENCES

1. Kumari R, Laxmisha C, Thappa DM. Disseminated cutaneous rhinosporidiosis. *Dermatol Online J* 2005;11:19.
2. Gokhale S, Ohri VC, Subramanya H, Reddy PS, Sharma SC. Subcutaneous and osteolytic rhinosporidiosis. *Indian J Pathol Microbiol* 1997;40:95-8.
3. Herr RA, Ajello L, Taylor JW, Arseculeratne SN, Mendoza L. Phylogenetic analysis of *Rhinosporidium seeberi*'s 18S small-subunit ribosomal DNA groups this pathogen among members of the protocistan *Mesomycetozoa* clade. *J Clin Microbiol* 1999;37:2750-4.
4. Sudarsan K, Saify AA, Siddique D, Sudarsan V, Agrawal S. Rhinosporidiosis of first metatarsal a case report. *Indian J Orthop* 1979;13:172-75.
5. Capoor MR, Khanna G, Rajni, Batra K, Nair D, Venkatchalam VP, et al. Rhinosporidiosis in Delhi, north India: Case series from a non-endemic area and mini-review. *Mycopathologia* 2009;168:89-94.
6. Arseculeratne SN. Recent advances in rhinosporidiosis and *Rhinosporidium seeberi*. *Indian J Med Microbiol* 2002;20:119-31.
7. Amritanand R, Nithyananth M, Cherian VM, Venkatesh K, Shah A. Disseminated rhinosporidiosis destroying the talus: A case report. *J Orthop Surg (Hong Kong)* 2008;16:99-101.
8. Aravindan KP, Viswanathan MK, Jose L. Rhinosporidioma of bone: A case report. *Indian J Pathol Microbiol* 1989;32:312-3.
9. Adiga BK, Singh N, Arora VK, Bhatia A, Jain AK. Rhinosporidiosis. Report of a case with an unusual presentation with bony involvement. *Acta Cytol* 1997;41:889-91.
10. Dash A, Satpathy S, Devi K, Das BP, Dash K. Cytological diagnosis of rhinosporidiosis with skeletal involvement: A case report. *Indian J Pathol Microbiol* 2005;48:215-7.
11. Chatterjee PK, Khatua CR, Chatterjee SN, Dastidar N. Recurrent multiple rhinosporidiosis with osteolytic lesions in hand and foot. A case report. *J Laryngol Otol* 1977;91:729-34.
12. Mitra K, Maity PK. Cutaneous rhinosporidiosis. *J Indian Med Assoc* 1996;94:84.
13. Suryawanshi PV, Rekhi B, Desai S, Desai SM, Juvekar SL, Jambhekar NA. Rhinosporidiosis isolated to the distal clavicle: A rare presentation clinicoradiologically mimicking a bone tumor. *Skeletal Radiol* 2011;40:225-8.
14. Morelli L, Polce M, Pisciole F, Del Nonno F, Covello R, Brenna A, et al. Human nasal rhinosporidiosis: An Italian case report. *Diagn Pathol* 2006;1:25.
15. França GV Jr, Gomes CC, Sakano E, Altemani AM, Shimizu LT. Nasal rhinosporidiosis in children. *J Pediatr (Rio J)* 1994;70:299-301.
16. Job A, Venkateswaran S, Mathan M, Krishnaswami H, Raman R. Medical therapy of rhinosporidiosis with dapsone. *J Laryngol Otol* 1993;107:809-12.

How to cite this article: Kundu AK, Phuljhele S, Jain M, Srivastava RK. Osseous involvement in rhinosporidiosis. *Indian J Orthop* 2013;47:523-5.

Source of Support: Nil, **Conflict of Interest:** None.