

## Case report

### Isolated radial volar dislocation of the fifth carpometacarpal joint :a rare injury

**Khalid Ibn El Kadi<sup>1,\*</sup>, Mohcine Sbiyaa<sup>1</sup>, Badr Alami<sup>1</sup>, Ilyass Rabhi<sup>1</sup>, Amine Marzouki<sup>1</sup>, Kamal Lahrach<sup>1</sup>, Fawzi Boutayeb<sup>1</sup>**

<sup>1</sup>Department of Orthopedic Surgery (A), UH Hassan II, Fes, Morocco

<sup>\*</sup>Corresponding author: Khalid Ibn El Kadi, Boulevard Almadina Lmounaoura, Résidence Bilal, N°10, Hay Amal, Narjiss, Fes, Morocco

Key words: Volar dislocation, carpometacarpal, diagnosis

Received: 13/08/2013 - Accepted: 06/10/2013 - Published: 10/11/2013

#### Abstract

Isolated palmar dislocation of the fifth carpometacarpal joint is an uncommon injury and classified as radio-palmar or ulno-palmar according to the direction of displacement of the fifth metacarpal base . This very rare injury is often difficult to recognize. A careful neurologic assessment of the patient is a necessity, as well as obtaining proper radiographs of the hand. The purpose of this report is to present a patient with a pure isolated volar dislocation of the fifth carpometacarpal joint that was satisfactorily treated with closed reduction and casting. A review of the literature is presented.

#### Pan African Medical Journal. 2013 16:90

This article is available online at: <http://www.panafrican-med-journal.com/content/article/16/90/full>

© Khalid Ibn El Kadi et al. The Pan African Medical Journal - ISSN 1937-8688. This is an Open Access article distributed under the terms of the Creative Commons Attribution License (<http://creativecommons.org/licenses/by/2.0>), which permits unrestricted use, distribution, and reproduction in any medium, provided the original work is properly cited.

## Introduction

---

Volar dislocation of the fifth carpometacarpal joint is an uncommon injury. Only few cases previously had been described in the consulted English literature [1-4]. We report a case of volar dislocation of the base of fifth carpometacarpal joint satisfactorily treated with closed reduction and casting. The mechanism of this injury, clinical presentation and treatment options are discussed, with a review of the literature.

## Patient and observation

---

A 25-year-old man complained of severe pain on his right hand after a fall when he suffered a direct traumatism over ulnar-dorsal side of the hand. Physical examination showed localised tenderness and moderate swelling over the fifth metacarpal and along the ulnar side of the hand. The little finger presented a marked deformity with mild abduction and external rotation. There was a palpable prominence in the volar hypothenar region. Subjectively, sensation was intact in the median and ulnar nerve distributions. Also, vascular exploration of the hand was normal. Standard plain radiographs revealed a palmar and radial dislocation of the fifth carpometacarpal joint without other lesions or fractures on the others digits or the wrist (**Figure 1**).

Immediately, under local anaesthesia, we performed a closed reduction by longitudinal traction and direct pressure over volar base of the metacarpal. The reduction was stable and was confirmed by X-rays control (**Figure 2**).

After the wrist and the metacarpophalangeal joint of the little finger were immobilized in a cast for 6 weeks. After this period of immobilization, the patient had been working with physical therapy and using his hand for daily activities. Six months following injury the patient had full range of movement of the little finger and normal grip strength, the radiographs showed the reduction to be maintained (**Figure 3**).

## Discussion

---

The normal fifth carpometacarpal joint is supported by a sturdy pisometacarpal ligament, dorsal and palmar carpometacarpal ligaments, and an intermetacarpal ligament [5,6]. The intermetacarpal ligament reportedly constitutes the primary restraint. Also, the extensor carpi ulnaris and the flexor carpi ulnaris tendons insert into the base of the fifth metacarpal.

Carpometacarpal (CMC) joint dislocations are relatively uncommon injury and they occur in less than 1% of hand injuries [7]. Carpometacarpal joint dislocation is classified as dorsal and volar (so named palmar too) dislocations, and they may be associated to fractures of adjacent metacarpal or carpal bones. Dorsal dislocations of the carpometacarpal joints occur more frequent than volar, mainly affect to fourth and fifth fingers [8]. Dislocations of the fifth carpometacarpal joint associated with hamate fractures [9-11] or fractures of the base of the fifth metacarpal or with another metacarpal joint dislocations types are more frequent than isolated dislocations [4, 12-14]. Divergent simultaneous carpometacarpal joint dislocation involving different digits is another rare type of lesion described by some authors [15]. Saleemi [16] reported a variety of these injuries and he described an isolated unilateral fifth CMC joint dislocation to the ulnar side, only seen in the postero-anterior (PA) view of hand X-ray.

Isolated volar or palmar dislocation of the fifth carpometacarpal joint is an uncommon injury that was first reported in 1918 by McWhorter [12]. In 1965 Nalebuff [6] classified the volar

dislocations into two groups according to the direction of the displacement of the fifth metacarpal base: radial palmar and ulnopalmar. At the first one the fifth metacarpal base is completely denuded of any ligaments or tendon attachments. At the second type the pisometacarpal ligament and tendon attachments are intact [6, 7].

Although, it is more difficult for the patients to remember the exact traumatism suffered, the mechanism of this injury have been seemed a direct blow transmitted to the dorsal and ulnar aspect of the base of the fifth metacarpal. This injury caused a rupture of all ligaments and tendon attachments of the base of the fifth metacarpal [7].

The physical findings in this dislocation are pain and swelling about the base of fifth metacarpal and axial deformity of the little finger. It is possible to observe an apparent shortening of the affected metacarpal.

A careful neurologic evaluation must be performed. The deep motor branch of the ulnar nerve lies volar to the fifth CMC joint as it courses around the hook of the hamate. It is vulnerable to injury in both dorsal [17, 18] and volar [19] CMC dislocations.

Even though the simple radiology findings are usually enough to diagnose these lesions in the ulnar dislocations several authors reported that the radiograph diagnosis is often difficult and these lesions may be overlooked [10, 20]. Careful attention to the parallel lines of the carpometacarpal articular surfaces can help avoid this pitfall. The key of a correct X-ray diagnosis is a 30° pronated lateral view in which the fifth carpometacarpal joint is projected in profile to demonstrate the displacement [21]. Yamakado [20] described a case diagnosed correctly by simple stress X-rays (traction and axial compression stress views). Like own case, in radial palmar dislocation the X-ray diagnosis is easier due to the several displacement.

The treatment of ulnopalmar dislocation has evolved along the years: in previous publications none surgical treatment was applied with unsuccessful results [13]. Later, the close reduction and fixation with two K-wires before [4, 16], and only with one after [14], demonstrated good results. Finally, in 1986, Berg reported [1] the first successful case treated with none surgical methods: close reduction and maintenance of the reduction with a plaster. Since there, this treatment method was applied with successful results in other cases [22].

Typically, one would assume that this injury pattern would need some form of surgical intervention, as is the case with most radial volar CMC dislocations. We believe that timely diagnosis, adequate sedation with muscle relaxation, followed by gentle reduction maneuvers allowed us to achieve near-anatomic and stable reduction of the fracture dislocation, which was adequately treated conservatively. Steinberg [23] has published in 2013 a case of Acute closed radial dislocation of the second through fourth carpometacarpal joints treated conservatively with good results. Our patient demonstrated excellent functional results at 6-month follow-up and the anatomical reduction was maintained.

Remember that in this type of dislocation, all ligaments and tendons attachments of the base of fifth metacarpal results tearing and that might explain the instability which required surgical treatment by percutaneous pinning or open reduction and internal fixation [7]. However, as demonstrated in our case, correct diagnosis during the acute setting and timely intervention can potentially keep these patients out of the operating room. If this approach is chosen, close follow-up and serial radiographic evaluation is recommended to ensure maintenance of reduction and recovery of hand function.

## Conclusion

In conclusion, isolated radial palmar dislocation of the fifth carpometacarpal joint is an uncommon lesion. Its intrinsic instability required surgical treatment. Conservative treatment is indicated if the closed reduction is stable.

## Competing interests

The authors declare no competing interests.

## Authors' contributions

All the authors cited in this article have contributed in the management of the patient or write-up of the manuscript. All the authors have read and approved the final version of the manuscript.

## Figures

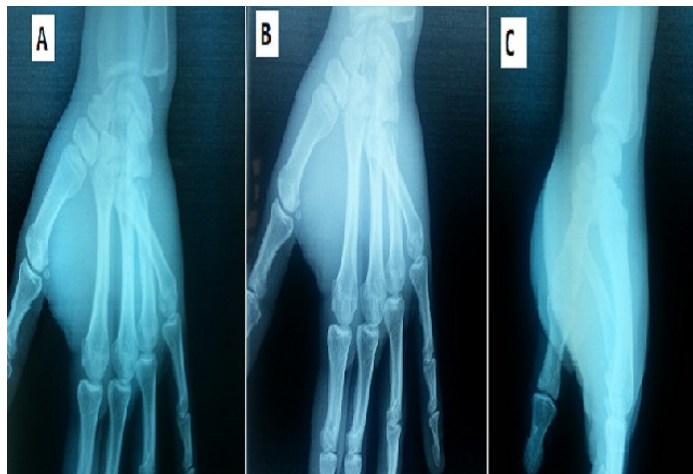
**Figure 1:** Anteroposterior (A), oblique (B) and lateral (C) X-rays showing radiopalmar dislocation of the fifth carpometacarpal joint  
**Figure 2:** Post reduction of 5th CMC-joint: Anteroposterior view (A), oblique view (B) and lateral (C) view  
**Figure 3:** 6-month follow-up: Reduction maintained. (A) AP view and (B) pronation view

## References

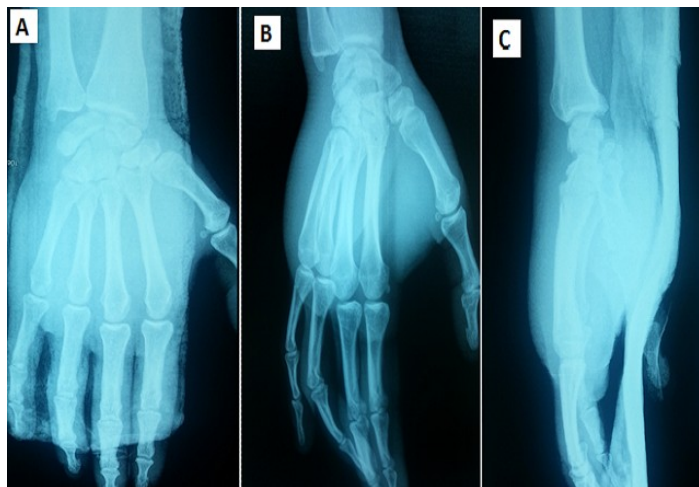
1. Berg EE, Murphy DF. Ulnopalmar dislocation of the fifth carpometacarpal joint-successful closed reduction: review of the literature and anatomic reevaluation. *J Hand Surg.* 1986;11(4):521-525. [PubMed](#) | [Google Scholar](#)
2. Buzby BF. Palmar carpometacarpal dislocation of the fifth metacarpal. *Ann Surg.* 1934;100:555-557. [PubMed](#) | [Google Scholar](#)
3. Chen VT. Dislocation of carpometacarpal joint of the little finger. *J Hand Surg.* 1987;12(2):260-263. [PubMed](#) | [Google Scholar](#)
4. Dennyson WG, Stother IG. Carpometacarpal dislocation of the little finger. *Hand.* 1976;8(2):161-164. [PubMed](#) | [Google Scholar](#)
5. Garcia-Elias M, Rossignani P, Cots M. Combined fracture of the hook of the hamate and palmar dislocation of the fifth carpometacarpal joint. *J Hand Surg.* 1996;21(4):446-450. [PubMed](#) | [Google Scholar](#)
6. Nalebuff EA. Isolated anterior carpometacarpal dislocation of the fifth finger: classification and case report. *J Trauma.* 1968;8(6):1119-1123. [PubMed](#) | [Google Scholar](#)
7. Anna Domingo, Lluís Font, Lázaro Saz, José M Arandes. Isolated radial palmar dislocation of the fifth carpometacarpal joint with ulnar neuropathy associated: successful treatment with closed reduction and internal fixation. *Eur J Orthop Surg Traumatol.* 19(2):101-107. [PubMed](#) | [Google Scholar](#)
8. Fisher MR, Rogers LF, Hendrix RW. Systematic approach to identifying fourth and fifth carpometacarpal joint dislocations. *AJR Am J Roentgenol.* 1983;140(2):319-324. [PubMed](#) | [Google Scholar](#)
9. Cain JE Jr, Shepler TR, Wilson MR. Hamatometacarpal fracture-dislocation: classification and treatment. *J Hand Surg.* 1987 12(5 Pt 1):762-67. [PubMed](#) | [Google Scholar](#)
10. De SL. Fracture-dislocation of the hamatometacarpal joint: A case report. *Acta Orthop Belg.* 1993; 59(1):106-108. [PubMed](#) | [Google Scholar](#)
11. Syed AA, Agarwal M, Giannoudis PV, Matthews SJ. Dorsal hamatometacarpal fracture-dislocation in a gymnast. *Br J Sports Med.* 2002;36(5):380-382. [PubMed](#) | [Google Scholar](#)
12. McWhorter GL. Isolated and complete dislocation of the fifth carpometacarpal joint: open operation. *Surg Clin Chic.* 1918; 2:793-796. [PubMed](#) | [Google Scholar](#)
13. Roberts N, Holland CT. Isolated dislocation of the base of the fifth metacarpal. *Br J Surg.* 1936;23:567-571. [PubMed](#) | [Google Scholar](#)
14. Tountas AA, Kwok JM. Isolated volar dislocation of the fifth carpometacarpal joint: Case report. *Clin Orthop Relat Res.* 1984; 187:172-175. [PubMed](#) | [Google Scholar](#)
15. Busa R, Internullo G, Caroli A. Divergent dislocation of the fourth and fifth carpometacarpal joints. *J Hand Surg.* 1998; 23(3):529-531. [PubMed](#) | [Google Scholar](#)
16. Saleemi AJ, Iqbal MJ. Ulnar dislocation of fifth carpometacarpal joint. *Hand Surg.* 2005;10(1):87-90. [PubMed](#) | [Google Scholar](#)
17. Peterson P, Sacks S. Fracture-dislocation of the base of the fifth metacarpal associated with injury to the deep motor branch of the ulnar nerve: a case report. *J Hand Surg.* 1986; 11(4):525-528. [PubMed](#) | [Google Scholar](#)
18. Young TB. Dorsal dislocation of the metacarpal base of the little and ring fingers with ulnar nerve compression. *Injury.* 1987;18(1):65-73. [PubMed](#) | [Google Scholar](#)
19. O'Rourke PJ, Quinlan W. Fracture dislocation of the fifth metacarpal resulting in compression of the deep branch of the ulnar nerve. *J Hand Surg.* 1993;18(2):190-191. [PubMed](#) | [Google Scholar](#)
20. Yamakado K, Hashimoto F, Nagata S, Higuchi M. Isolated palmar dislocation of the fifth carpometacarpal joint diagnosed by stress X-rays. *Arch Orthop Trauma Surg.* 2000;120(9):529-530. [PubMed](#) | [Google Scholar](#)
21. Bora FW Jr, Didizian NH. The treatment of injuries to the carpometacarpal joint of the little finger. *J Bone Joint Surg.* 1974; 56(7):1459-1463. [PubMed](#) | [Google Scholar](#)

22. Peidro L, Arandes JM, Del Valle M. Riduzione stabile di lussazione volare-ulnare della V articolazione carpo-metacarpale. *G Ital Ortop Traumatol.* 1995;21:199-202. **PubMed** | **Google Scholar**

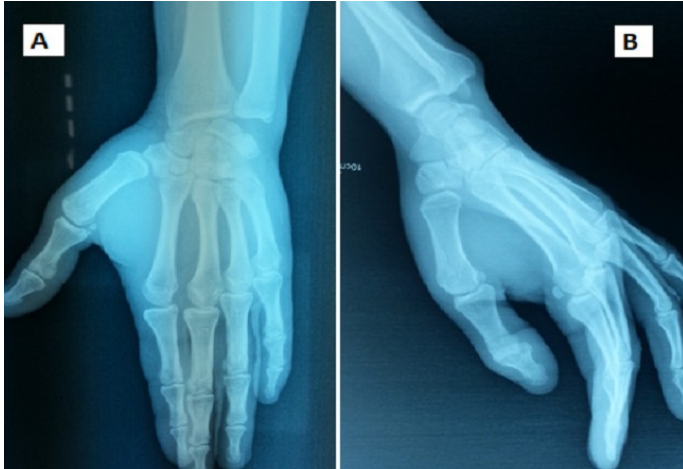23. John G, Horneff III, Min Jung Park, David R, Steinberg. Acute closed dislocation of the second through fourth carpometacarpal joints: satisfactory treatment with closed reduction and immobilization. *Hand.* 2013 ;8(2):227-231. **PubMed** | **Google Scholar**



**Figure 1:** Anteroposterior (A) ,oblique (B) and lateral(C) X-rays showing radiopalmar dislocation of the fifth carpometacarpal joint



**Figure 2:** Post reduction of 5th CMC-joint : Anteroposterior view (A) ,oblique view (B) and lateral(C) view



**Figure 3:** 6-month follow-up: Reduction maintained. (A) AP view and (B) pronation view