

## CASE REPORT

# Laugier–Hunziker syndrome: a report of three cases and literature review

Wen-Mei Wang<sup>1</sup>, Xiang Wang<sup>1</sup>, Ning Duan<sup>1</sup>, Hong-Liu Jiang<sup>1</sup> and Xiao-Feng Huang<sup>2</sup>

**Laugier–Hunziker syndrome (LHS) is an acquired pigmentary condition affecting lips, oral mucosa and acral area, frequently associated with longitudinal melanonychia. There is neither malignant predisposition nor underlying systemic abnormality associated with LHS. Herein, we present three uncommon cases of LHS with possibly new feature of nail pigmentation, which were diagnosed during the past 2 years. We also review the clinical and histological findings, differential diagnosis, and treatment of the syndrome in published literature.**

*International Journal of Oral Science* (2012) 4, 226–230; doi:10.1038/ijos.2012.60; published online 23 November 2012

**Keywords:** differential diagnosis; Laugier–Hunziker syndrome; longitudinal melanonychia; oral pigmentation

## INTRODUCTION

In 1970, Laugier and Hunziker reported five cases of an unusual acquired macular hyperpigmentation with no underlying disease and two of these patients also displayed longitudinal pigmented streaks on the nails.<sup>1</sup> From the original description to date, more than 180 cases have been reported world wide, mostly in Whites and published in the dermatological field.

Almost all authors supported that there is no malignant predisposition associated with Laugier–Hunziker syndrome (LHS).<sup>1–8</sup> The etiology of this disorder is still unknown. It appears that there is no a familial factor or systemic abnormality associated with the syndrome.

We present three Chinese cases of LHS with possibly new feature of nail pigmentation, which were diagnosed during the past 2 years. We also review the clinical and histological findings, differential diagnosis and treatment of the syndrome.

## CASE REPORT

### Case 1

A 45-year-old female patient was referred to the Department of Oral Medicine for lip and nail pigmentation. She remembered these asymptomatic macules had 15-year duration and they became gradually progressive. Physical examination revealed extensive diffuse pigmentation on the lower lip, as well as multiple macules over oral mucosa (Figure 1a–1c). A double longitudinal pigmented band was present on the fingernail of the right thumb. Pseudo-Hutchinson's sign was negative. Pseudo-Hutchinson's sign refers to pigmentation around the proximal nail fold. A faint brown macule appeared on the finger pulp of the right thumb. Notably, two irregular brown spots with smooth and flat surface were observed on the left first toenail

(Figure 1d–1f). Potassium hydroxide examination and fungus culture were negative for hyphae and spores.

The patient was a non-smoker and did not take any medication causing the pigmentation. She denied a history of trauma on the fingernail or toenail. Familial history of pigmentary disorders and digestive polyposis or tumors was negative. Her hepatic and renal functions were normal and serum triiodothyronine (T3), tetraiodothyronine (T4) and thyrotropin (TSH) were all within normal limits. Hormonal assessment revealed normal pituitary–adrenal axis function. The serology tests for human immunodeficiency virus (HIV) gave negative results. She had received upper gastrointestinal endoscopy and colonoscopy, which all showed normal results.

The histopathologic finding for the pigmented lesion of lower lip was not specific. An accumulation of melanin was confined to the basal layer. Few melanophages were seen in the upper lamina propria (Figure 2). A diagnosis of LHS was made on the basis of the clinical and histopathologic findings.

### Case 2

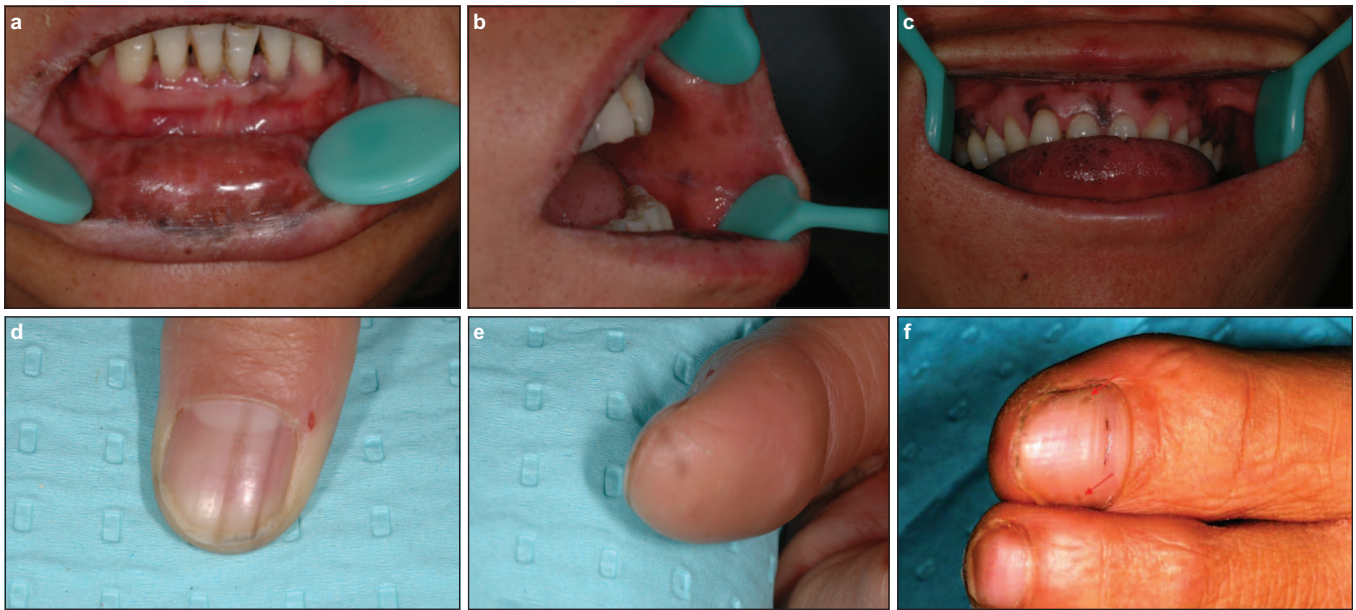
A 40-year-old non-smoking man presented with a 22-year history of progressive blackish pigmentation of upper and lower gums and 10-year history of brownish-black pigmentation of several fingernails. Physical examination revealed extensively diffuse pigmentation distributed over his gums (Figure 3a). The longitudinal pigmented band was present on parts of his fingernails (Figure 3b). Notably, there was irregular or stippled pigmentation with smooth and flat appearance affecting the nails of his right thumb and index finger (Figure 3c). Potassium hydroxide examination and fungus culture were negative for hyphae and spores. In addition, a brown macule was noted on his left conjunctiva (Figure 3d). Further ophthalmic examination

<sup>1</sup>Department of Oral Medicine, Institute and Hospital of Stomatology, Nanjing University Medical School, Nanjing, China and <sup>2</sup>Department of Oral Pathology, Institute and Hospital of Stomatology, Nanjing University Medical School, Nanjing, China

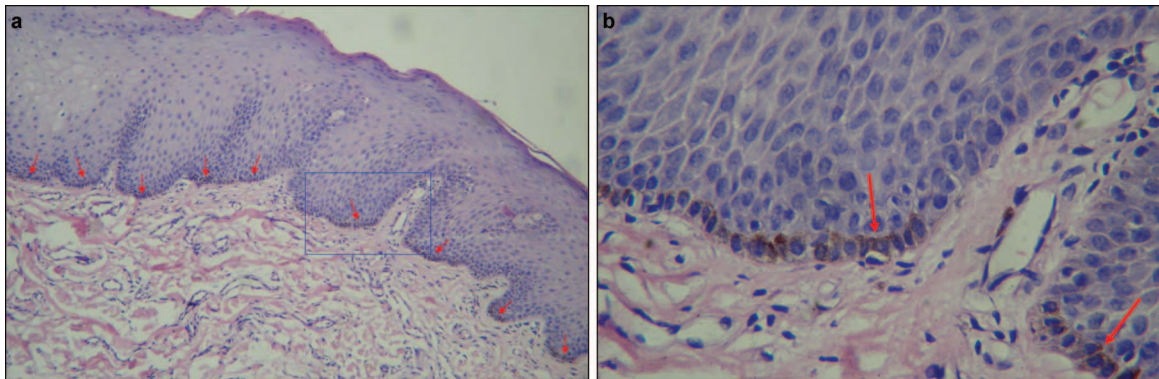
Correspondence: Professor WM Wang, Department of Oral Medicine, Institute and Hospital of Stomatology, Nanjing University Medical School, 30 Zhongyang Road, Nanjing 210008, China

E-mail: wenmei-wang@hotmail.com

Received 3 January 2012; accepted 24 June 2012



**Figure 1 Clinical photographs in case 1.** Extensive diffuse brownish to black pigmentation on vermilion and mucosa of the lower lip (a); multiple, discrete, well-defined, lenticular or irregularly shaped, faint brown to dark macules distributed over the buccal mucosa (b), the gingiva and the dorsum of tongue (c). A double longitudinal pigmented band was present on the fingernail of the right thumb (d) and a faint brown macule appeared on the fingertip of the right thumb (e). Two irregular brown spots with flat and smooth surface were noted on the left first toenail (arrows). A transverse black streak of the same toenail, associated with groove, was not pigmentary change of LHS due to the atrophy of nail plate (f).



**Figure 2 Histopathological features in case 1.** An accumulation of melanin is confined to the basal layer, especially affecting the tips of epithelial rete pegs (arrows). (a and b) Hematoxylin and eosin staining, a,  $\times 100$ ; b,  $\times 400$ .

disclosed several inframillimetric conjunctival brown macules of the inferior nasal quadrant of the left eye.

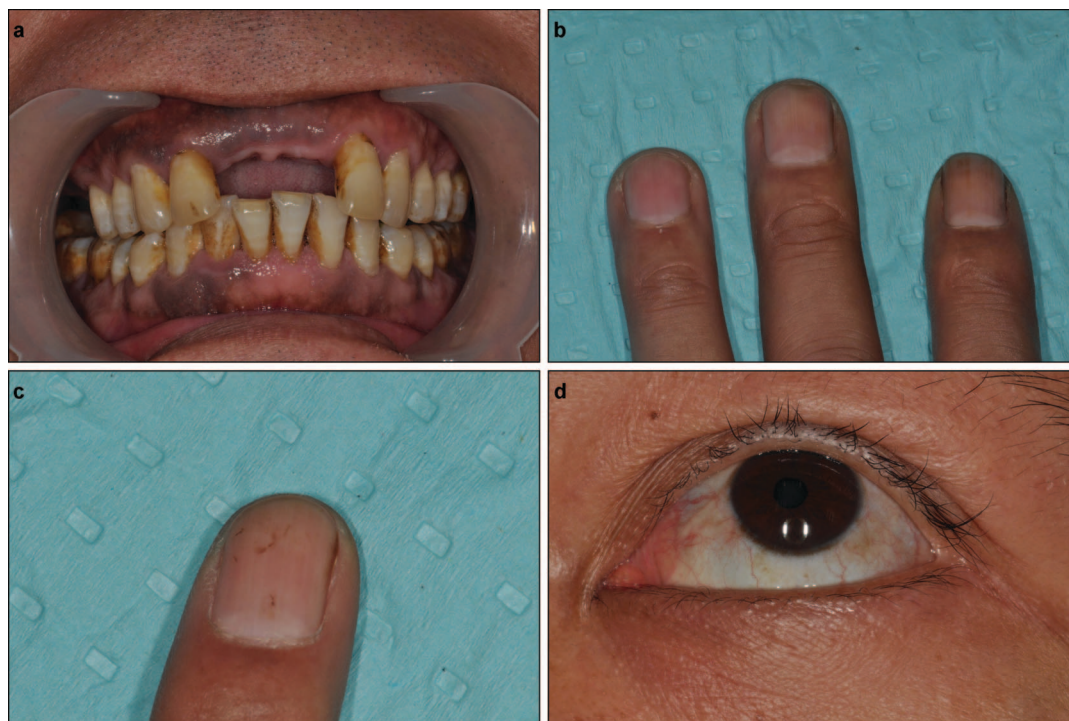There was no relevant drug history. The patient denied a history of trauma or hemorrhage of his fingernails. Familial history of pigmentary disorders and digestive polyposis or tumors was negative. The patient had a history of intestinal functional disorder and underwent an upper gastrointestinal study, barium enema and colonoscopy, which showed no evidence of polyps. Serum cortisol and adrenocorticotropic hormone levels were within normal limits. The serology tests for HIV gave negative results. A diagnosis of LHS was made.

### Case 3

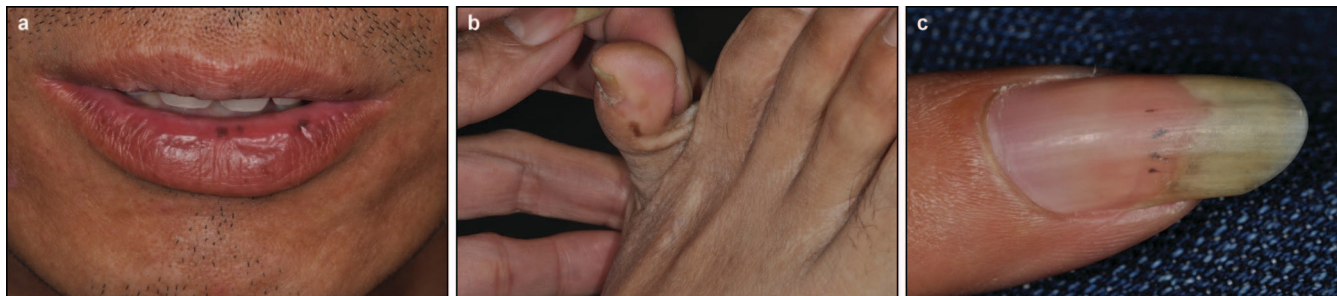A 36-year-old non-smoking man presented to our clinic with multiple melanotic macules on her lips and pigmentary change affecting several fingernails. The exact onset of these pigmentary changes is difficult to establish, but they are of at least 10 years' duration. Physical examina-

tion showed multiple macules on his lips (Figure 4a). A brownish macule was observed on the interdigital area of the left little toe (Figure 4b). Some irregularly shaped or stippled pigmentation with smooth and flat appearance was noted on the nails of his left thumb and left little finger, although no longitudinal pigmented band was found on his fingernails or toenails (Figure 4c). Potassium hydroxide examination and fungus culture gave negative result.

He denied a history of previous or current exposure to systemic or topical medications. He also denied a history of trauma or hemorrhage of his fingernails. Moreover, there was no family history of mucocutaneous pigmentation or intestinal polyps. Laboratory data showed that the levels of adrenocorticotropic hormone and cortisol were all within normal limits. Panendoscopy and colonoscopy revealed no polyposis. Because he was in good health, no further examinations were conducted. According to these findings, the diagnosis of LHS was made.



**Figure 3 Clinical photographs in case 2.** Extensively diffuse pigmentation distributed over the upper and lower gums (a). A single longitudinal pigmented band or multiple longitudinal pigmented bands were present on parts of the fingernails (b). There was irregular or stippled pigmentation on the nail of index finger (c). An ill-defined 3 mm×2 mm brown macule was noted in the inferior temporal quadrant of the left conjunctiva (d).



**Figure 4 Clinical photographs in case 3.** Multiple, round- to ovoid-shaped, blackish macules were present on his lips (a). A brownish macule was observed on the interdigital area of the left little toe (b). Some irregularly shaped or stippled pigmentation was noted on parts of his fingernails (c).

## TREATMENT

LHS is known to be an entirely benign disorder with no systemic manifestations. Therefore, no treatment was performed for the current cases and a wait-and-see strategy was adopted.

## DIFFERENTIAL DIAGNOSIS

Most important differential diagnosis of LHS is Peutz–Jeghers syndrome (PJS). PJS shares some clinical features with LHS, but PJS is an autosomal dominant inherited disease characterized by mucocutaneous pigmentation associated with hamartomatous gastrointestinal polyposis.<sup>9</sup> In cases of PJS, there is often a family history and an association with hamartomatous polyposis, mainly colonic. In cases of LHS, gastrointestinal hamartomatous polyposis is not observed, nor is a familial history.<sup>2</sup> The pigmented macules in PJS usually occur in infancy or early childhood, reaching a maximum at puberty.<sup>9</sup> The lesions of LHS, however, are progressively acquired after puberty. In addition, pigmentary macules in PJS also could be present surround-

ing the mouth, nose and eyes. A pigmented nail band rarely occurs in cases of PJS.

Addison's disease is also an important differential diagnosis of LHS. The disease is an endocrine disease caused by insufficient production of cortisol and aldosterone by the adrenal glands. Addison's disease is characterized by hyperpigmentation of the skin areas subject to increased pressure, such as the knuckles or skin creases. Associated features include decreased pubic and axillary hair in women, hypotension and abdominal pain.<sup>3</sup> The oral hyperpigmentation may be the first sign of Addison's disease.

Other differential diagnosis includes McCune–Albright syndrome, drug-induced pigmentation, effects of smoking, heavy metal exposure, lichen planus and acquired immune deficiency syndrome (AIDS).

Our patients neither had a history of chronic drug use nor had familial history of pigmentary disorders and digestive polyposis or tumors. The upper gastrointestinal endoscopy, colonoscopy and

pituitary–adrenal function tests of all the cases showed normal results. Therefore, most systemic disorders were ruled out and the diagnosis of LHS was made.

The nail pigmentation in LHS need to be distinguished from pigmentations caused by other disorders, which include subungual hemorrhage, candida onychomycosis, tinea unguium, lichen planus, post-trauma pigmentation, extrinsic staining, chemotherapy, AIDS, malignant melanoma, etc.

Blood is by far the most frequent cause of dark nail pigmentation. Subungual hematomas due to a single acute and heavy trauma have a typical history, and in case of a hammer blow or a crash injury from a door, there is often a leukonychotic area over the hematoma.<sup>10</sup>

Bacterial nail pigmentation, most commonly due to *Pseudomonas aeruginosa* or *Proteus*, have a greenish or grayish hue and the discoloration is often confined to the lateral edge of the nail.<sup>10</sup> The onychomycosis may commonly present as nail discoloration and abnormalities of the nail plate surface. White, yellow, green, or black changes are due to fungal pigment that imbues the nail plate. The abnormalities of the nail plate surface mainly include onychauxis, onychorrhexis, onycholysis and longitudinal splitting. The microscopic examination and culture of fungus are especially important for the diagnosis of candida onychomycosis and tinea unguium.

Long-standing inflammatory skin diseases, particularly lichen planus, can cause nail pigmentation. Multiple longitudinal melanonychia may occur in patients with lichen planus, commonly accompanied with nail plate thinning, onychatrophy, onychorrhexis, longitudinal splitting and longitudinal grooves or ridges of nail plate.

Most exogenous brown to black pigmentation due to dirt, tobacco, potassium permanganate, tar, etc. do not present as a longitudinal streak. Most of them can easily be scratched off.<sup>10</sup> Several chemotherapeutic agents, such as hydroxyurea and cyclophosphamide, can cause nail pigmentation, which may manifest as longitudinal brownish-black bands.

Brown or black discoloration spreading from under the nail or proximal to nail fold into the surrounding skin, referred to as Hutchinson's sign, should be a reason to rule out malignant melanoma. Malignant longitudinal melanonychia is usually wider than 5 mm and expanding variable color/shaped streaks may occur in ungual melanoma. Nail erosion, nail dystrophy and a bleeding mass strongly suggest malignancy.<sup>10</sup>

Our patients denied a history of trauma or hemorrhage on the fingernail or toenail. There were not longitudinal grooves or ridges of nail plate in three cases. Moreover, the nail pigmentation in all three cases remained stable during follow up and no changes of the distribution and the shape of nail pigmentation could be observed with nail elongation. Microscopic examination and culture of fungus gave negative results. All the patients were non-smokers and did not take any medication causing the pigmentation. Hutchinson's sign of all the patients were negative. Therefore, most disorders causing nail pigmentation were ruled out and nail pigmentation of LHS was diagnosed.

## DISCUSSION

In China, LHS has not been reviewed very well, and 42 cases, including the present three cases, have been reported in the literature.<sup>5,7–8</sup> All the reports were published in the field of dermatology. To our knowledge, the current report is the only one in the area of Chinese oral sciences. In China, LHS affects patients in the range of 18–84 years old, with an average age of 46 years. There is a female preponderance, with an overall female/male ratio of 5:1.

Pigmentary changes of cases with LHS do not disappear naturally. The most common sites for the lesions are the lips, especially the lower lip, and the oral cavity, particularly the buccal mucosa. Increased pigmentation occurs on the tongue, gingivae, palate and they can also be seen in the palmoplantar area and the genital region. However, it is extremely rare for pigmentation to be observed on the floor of the mouth.<sup>4,11</sup> Pigmentation lesions of some cases have also been described with atypical localization, namely, the neck,<sup>12</sup> thorax,<sup>12</sup> abdomen,<sup>12</sup> pretibial area,<sup>13</sup> sclera,<sup>4</sup> eyebrow site<sup>14</sup> and esophagus.<sup>15</sup> The typical cutaneous or mucosal lesions manifest as gray, brown, blue-black or black hyperpigmented macules with a flat, smooth surface and relatively well-defined or indistinct margins, which are 2 to 5 mm in diameter, and lenticular, oval or irregular in shape. These lesions are either single or multiple and are sometimes confluent.<sup>14–16</sup>

Extensive diffuse hyperpigmentation has been reported in buccal and palatal mucosa,<sup>6</sup> lower lip<sup>8,17</sup> and pretibial area.<sup>13</sup> In case 1 and case 2 of the current report, extensive diffuse macular pigmentation was found on lower lip and gums, respectively. The particular pattern of pigmentation is notable because it is distinguished with typical discrete lenticular or lentiginous hyperpigmentation in LHS. Oral pigmentation is either focal or diffuse. Although focal lesions may be more worrying, and may require a biopsy for an accurate diagnosis, diffuse lesions often have no specific histological features, but may be the first sign of an underlying systemic disease.<sup>6</sup> When evaluating a patient with oral pigmentation, the nails and other mucosal and cutaneous surfaces must be examined. PJS must be ruled out in case of diffused oral pigmentation, because patients with PJS have an increased incidence of gastrointestinal carcinoma, as well as genital and mammary tumors.<sup>9</sup> Addison disease is characterized by diffuse hyperpigmentation of the skin and mucosa, with a predilection for some areas subject to trauma.<sup>4</sup> Diffuse oral pigmentation may also be associated with systemic intake of drugs. The most common drugs which are associated with oral pigmentation are tetracyclines, especially minocycline, antimalarials (chloroquine, hydroxychloroquine), amiodarone, chemotherapeutics, clofazamine, oral contraceptives, phenothiazines, azidothymidine, zidovudine and ketoconazole. Drug-induced oral pigmentation usually occurs following long-term use over months and years and often resolves after discontinuation of the causative drug.<sup>5</sup>

Not all patients have both oral and nail involvement, the incidence of a pigmented nail band in cases of LHS is 44%–60%.<sup>2,18</sup> In China, longitudinal pigmented bands of nails are observed in 45% of reported LHS cases. Racial factors are clearly important. Physiologic pigmentation of the oral mucosa is well known in the Asian, Black and other dark-skinned races and may resemble that seen in LHS.<sup>6,11</sup> Longitudinal melanonychia, which is distinctly uncommon in white patients, has been reported to occur in 77%–96% of blacks and 11% of Asians.<sup>19</sup> Given the high incidence of oral or nail pigmentation in Asian population, we believe that LHS can more confidently be diagnosed only when both oral and nail (or skin) involvement are present.

The nail pigmentation, classified by Baran,<sup>18</sup> can involve three main types: a single 1 to 2 mm wide longitudinal streak, a double 2 to 3 mm wide longitudinal streaks on the lateral parts of the nail plate and a homogeneous pigmentation of the radial or ulnar half of the nail. Veraldi *et al.*<sup>16</sup> added the fourth possibility—complete pigmentation of the nail. All four types of nail involvement may simultaneously involve one or more fingernails and/or toenails and the degree of pigmentation does not correspond to different stages of the syndrome. The fingernails are more frequently involved than the toenails.<sup>16</sup> It is also possible to observe pseudo-Hutchinson's sign. To the best of our knowledge, irregular or stippled pigmentation affecting the nail has

not been reported in cases of LHS. The special pigmentation of nails in all three cases remained stable during follow-up. The irregular or stippled pigmentation appears to be possibly new feature of nail pigmentation associated with LHS. Further follow-up of current cases and more new cases with similar features are needed to verify the hypothesis. Moreover, speculum of fungus and dermoscopic examination will be useful for the differential diagnosis in further study.

In general, the histopathological examination of pigmented lesions in LHS shows an accumulation of melanin in the basal layer of the epithelium or epidermis. Melanocytes are normal in number, morphology and distribution. These features show that the condition is due to increased melanocytic activity rather than to an increased number of melanocytes.<sup>11</sup> An atypical report described an increased number and cellular atypia of intraepidermal melanocytes.<sup>20</sup> In the present study, we observed an interesting phenomenon, namely the accumulation of melanin was confined to tips of epithelial rete pegs. It could also be observed through reviewing the histopathologic findings in some reported cases.<sup>5,16</sup> The reason for this phenomenon is unclear and needs further investigation.

Treatment for the hyperpigmented macules in LHS is sought mainly for cosmetic reasons and includes cryosurgery, Q-switched Nd:YAG and Q-switched alexandrite laser therapy. Sun protection is important to prevent reoccurrence.<sup>3</sup>

LHS is probably more common than is generally recognized.<sup>2</sup> We should be more familiar with the disorder.

#### ACKNOWLEDGEMENTS

The authors would like to thank Dr Nick Boyd from Department of Oral Medicine, University of Western Australia School of Dentistry for careful grammar and lexical modification. The authors would also thank Dr Wen-Lei Wu in Department of Periodontics and Dr Wen-Hui Jiang in Department of Oral Pathology of our hospital for their kind technical assistance.

This work was supported by the National Natural Scientific Foundation of China (No. 81070839) and Jiangsu Province's Outstanding Medical Academic Leader program (No. LJ201110).

- 2 Yago K, Tanaka Y, Asanami S. Laugier–Hunziker–Baran syndrome. *Oral Surg Oral Med Oral Pathol Oral Radiol Endod* 2008; **106**(2): e20–e25.
- 3 Sachdeva S, Sachdeva S, Kapoor P. Laugier–Hunziker syndrome: a rare cause of oral and acral pigmentation. *J Cutan Aesthet Surg* 2011; **4**(1): 58–60.
- 4 Began D, Mirowski G. Perioral and avral lentiginos in an African American man. *Arch Dermatol* 2000; **136**(3): 419, 422.
- 5 Zuo YG, Ma DL, Jin HZ *et al*. Treatment of Laugier–Hunziker syndrome with the Q-switched alexandrite laser in 22 Chinese patients. *Arch Dermatol Res* 2010; **302**(2): 125–130.
- 6 Siponen M, Salo T. Idiopathic lenticular mucocutaneous pigmentation (Laugier–Hunziker syndrome): a report of a case. *Oral Surg Oral Med Oral Pathol Oral Radiol Endod* 2003; **96**(3): 288–292.
- 7 Ko JH, Shih YC, Chiu CS *et al*. Dermoscopic features in Laugier–Hunziker syndrome. *J Dermatol* 2011; **38**(1): 87–90.
- 8 Ma DL, Vano-Galvan S. Hyperpigmentation in Laugier–Hunziker syndrome. *CMAJ* 2011; **183**(12): 1402.
- 9 Lampe AK, Hampton PJ, Woodford-Richens K *et al*. Laugier–Hunziker syndrome: an important differential diagnosis for Peutz–Jeghers syndrome. *J Med Genet* 2003; **40**(6): e77.
- 10 Haneke E, Baran R. Longitudinal melanonychia. *Dermatol Surg* 2001; **27**(6): 580–584.
- 11 Mignogna MD, Lo Muzio L, Ruoppo E *et al*. Oral manifestations of idiopathic lenticular mucocutaneous pigmentation (Laugier–Hunziker syndrome): a clinical, histopathological and ultrastructural review of 12 cases. *Oral Dis* 1999; **5**(1): 80–86.
- 12 Sartoris S, Pippone M, de Paoli MA *et al*. [Pigmentazione melanica idiopatica]. *Giorn Min Derm* 1975; **110**: 382–385. Italian.
- 13 Aliagaoglu C, Yanik ME, Albayrak H *et al*. Laugier–Hunziker syndrome: diffuse large hyperpigmentation on atypical localization. *J Dermatol* 2008; **35**(12): 806–807.
- 14 Gerbig AW, Hunziker T. Idiopathic lenticular mucocutaneous pigmentation or Laugier–Hunziker syndrome with atypical features. *Arch Dermatol* 1996; **132**(7): 844–845.
- 15 Yamamoto O, Yoshinaga K, Asahi M *et al*. A Laugier–Hunziker syndrome associated with esophageal melanocytosis. *Dermatology* 1999; **199**(2): 162–164.
- 16 Veraldi S, Cavicchini S, Benelli C *et al*. Laugier–Hunziker syndrome: a clinical histopathologic and ultrastructural study of four cases and review of literature. *J Am Acad Dermatol* 1991; **25**(4): 632–636.
- 17 Sabesan T, Ramchandani PL, Peters WJ. Laugier–Hunziker syndrome: a rare cause of mucocutaneous pigmentation. *Br J Oral Maxillofac Surg* 2006; **44**(4): 320–321.
- 18 Baran R. Longitudinal melanotic streaks as a clue to Laugier–Hunziker syndrome. *Arch Dermatol* 1979; **115**(12): 1448–1449.
- 19 Aytakin S, Alp S. Laugier–Hunziker syndrome associated with actinic lichen planus. *J Eur Acad Dermatol Venereol* 2004; **18**(2): 221–223.
- 20 Moore RT, Chae KA, Rhodes AR. Laugier and Hunziker pigmentation: a lentiginous proliferation of melanocytes. *J Am Acad Dermatol* 2004; **50**(5 Suppl): S70–S74.

1 Laugier P, Hunziker N. [Pigmentation mélanique lenticulaire, essentielle, de la muqueuse jugale et des lèvres.] *Arch Belg Dermatol Syphiligr* 1970; **26**: 391–399. French.



This work is licensed under a Creative Commons Attribution-NonCommercial-NoDerivative Works 3.0 Unported License. To view a copy of this license, visit <http://creativecommons.org/licenses/by-nc-nd/3.0>