

[CASE REPORT]

Pulmonary Hypertension Associated with Pulmonary Veno-occlusive Disease in Patients with Polycythemia Vera

Takayoshi Tachibana^{1,2}, Naoki Nakayama³, Ayako Matsumura¹, Yuki Nakajima¹,
Hiroyuki Takahashi¹, Takuya Miyazaki¹ and Hideaki Nakajima¹

Abstract:

A 65-year-old man was diagnosed with polycythemia vera (PV) and treated with hydroxyurea. Three years later, he was admitted to our institution for severe hypoxia. Right heart catheterization revealed that the patient had pulmonary hypertension (PH). In addition, radiographic findings and resistance to pulmonary vasodilators led to the diagnosis of PH associated with pulmonary veno-occlusive disease. The administration of ruxolitinib improved his hematopoiesis and respiratory failure. While the disease is relatively common in Europe and the United States, limited data exist regarding myeloproliferative neoplasm complicated with PH in Japan. PH should be considered a potential complication and screened during the clinical care of patients with myeloproliferative neoplasms.

Key words: pulmonary hypertension, pulmonary veno-occlusive disease, polycythemia vera, ruxolitinib

(Intern Med 56: 2487-2492, 2017)

(DOI: 10.2169/internalmedicine.8629-16)

Introduction

Pulmonary hypertension (PH) is an intractable disease with various factors that can lead to persistently elevated pulmonary artery pressure. Although PH is associated with several hematological diseases, it is predominantly managed in the Department of Cardiology, and hematologists have limited opportunities to examine patients with the condition.

We herein report the case of a patient with polycythemia vera (PV) who developed PH associated with pulmonary veno-occlusive disease (PH-PVOD). In Japan, reports of patients with a myeloproliferative neoplasm (MPN) complicated by PH are rare, although they are relatively common in Europe and the United States. Hematologists should understand how to detect PH in patients with hematological diseases and report cases of patients with MPN complicated by PH.

Case Report

In 2011, a 65-year-old-man developed cerebral infarction

and was diagnosed with polycythemia. His medical history was unremarkable except for cholangitis. The peripheral blood laboratory values showed a white blood cell count of $17.5 \times 10^3/\mu\text{L}$, a red cell count of $686 \times 10^4/\mu\text{L}$, hemoglobin concentration of 19.8 g/dL, hematocrit of 57.6%, mean corpuscular volume of 84.0 fL, platelet count of $61.8 \times 10^4/\mu\text{L}$, and lactate dehydrogenase of 401 IU/L. Neither the liver nor spleen were palpable. A Janus kinase 2 (*JAK2/V617F*) mutation was identified, and he was diagnosed with PV. Hydroxyurea at a dose of 1,000 mg/day was administered. However, both the white cell and platelet counts were slowly increased, while the hemoglobin was decreased due to intestinal hemorrhaging. From the summer of 2014, he presented with dyspnea on effort and, in December, was admitted to the Department of Cardiology. The diagnosis was acute heart failure, but the patient's condition did not improve despite furosemide administration. In September of 2015, he was referred to our hospital and admitted to the Department of Cardiology.

Severe hypoxia was found, with pulse oximetry results of 88% during a physical examination, and a high volume of oxygen was administered. In this condition, the partial pres-

¹Department of Hematology and Clinical Immunology, Yokohama City University Hospital, Japan, ²Department of Hematology, Kanagawa Cancer Center, Japan and ³Department of Cardiology, Yokohama City University Hospital, Japan

Received: November 30, 2016; Accepted: January 24, 2017; Advance Publication by J-STAGE: August 21, 2017

Correspondence to Dr. Takayoshi Tachibana, tcbn@kcch.jp

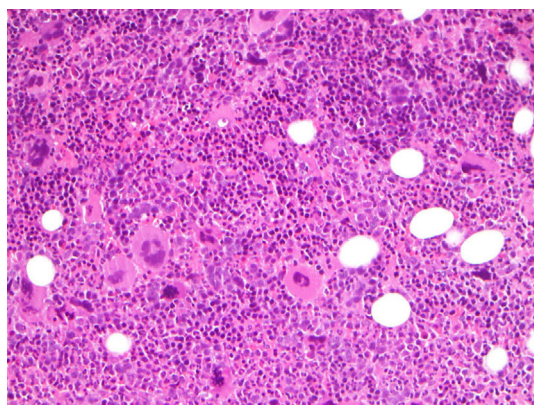


Figure 1. A bone marrow biopsy by Hematoxylin and Eosin staining. The bone marrow biopsy revealed hypercellularity with mild fibrosis, findings that were compatible with polycythemia vera.

ures of oxygen and carbon dioxide in arterial blood were 55.7 and 22.3 mmHg, respectively. Despite severe hypoxia, the patient's performance status was 2, his respiratory rate was 24 breaths/min, and he could slowly walk on foot. The spleen was palpable 15 cm below the costal arch. Laboratory values showed a white blood cell count of $31.7 \times 10^3/\mu\text{L}$ (myeloblast 0.5%, myelocyte 0.5%, segmented neutrophil 86.0%, eosinophil 3.5%, basophil 4.5%, monocyte 1.5%, lymphocyte 3.5%), hemoglobin concentration of 10.8 g/dL, mean corpuscular volume of 64.0 fL, platelet count of $60.8 \times 10^4/\mu\text{L}$, lactate dehydrogenase of 407 IU/L, creatinine of 1.95 mg/dL, C-reactive protein of 0.23 mg/dL, brain natriuretic peptide of 594 pg/mL, erythropoietin of 7.4 mIU/mL, ferritin of 10 ng/mL, iron of 64 $\mu\text{g}/\text{dL}$, total iron-binding capacity of 187 $\mu\text{g}/\text{dL}$, transferrin of 144 mg/dL, haptoglobin of 5 mg/dL, and D-dimer of fibrin degradation product of 0.66 $\mu\text{g}/\text{mL}$. The nuclear cell and megakaryocyte count of the bone marrow was $10.6 \times 10^4/\mu\text{L}$ and $6/\mu\text{L}$, respectively. A bone marrow biopsy revealed progression of hematopoiesis, and the findings were compatible with PV (Fig. 1). A chromosomal analysis showed a normal karyotype, and the *JAK 2/V617F* mutation was re-confirmed (1).

To determine the cause of hypoxia, chest radiography was performed, which showed cardiomegaly, protrusion of the right second aortic arches, and ground-glass opacity (Fig. 2A). Chest computed tomography (CT) indicated thickening of the interlobular septum, granular shadow, wall thickening of bronchial branch, and ground-glass opacity (Fig. 2B). Cardiac ultrasonography indicated dilation of the right ventricle and compression of the left ventricle wall, suggesting an overburdened right heart system (Fig. 2C). Right heart catheterization was immediately performed. The mean pulmonary artery pressure and right ventricular systolic pressure was 34 and 49 mmHg, respectively, while the pulmonary artery wedge pressure was normal. These findings led to the diagnosis of PH (2-4).

The clinical course is shown in Fig. 3. A clinical evaluation suggested that the patient had exacerbated right heart

failure associated with PH. Pulmonary vasodilators, including endothelin-receptor antagonist or phosphodiesterase type 5 inhibitor, intravenous epoprostenol (prostacyclin), and furosemide, were used. However, these pulmonary vasodilators induced pulmonary edema. The patient's hypoxia worsened, and he became dependent on hyperoxygenation by heated humidified high-flow therapy in the intensive- or coronary-care unit. Characteristic CT findings and the clinical course including the resistance to pulmonary vasodilators led to the clinical diagnosis of PH-PVOD (5, 6). A lung biopsy was too invasive to perform because of severe respiratory failure.

For the refractory PV, ruxolitinib was administered at 5 mg twice a day. With the suppression of hematopoiesis, the respiratory and heart failure were slowly improved. His pulmonary pressure decreased from 34 to 27 mmHg, suggesting the effectiveness of ruxolitinib treatment. After long-term systemic and intensive rehabilitation, including the restoration of his respiratory, motor, and swallowing function, the patient was successfully discharged with home oxygen therapy. Although both PV and PH-PVOD were controlled without exacerbation with ruxolitinib, he died suddenly of an unknown cause 10 months after the PH-PVOD diagnosis.

Discussion

We herein report a case of PV complicated by PH-PVOD. PH is an intractable disease where elevation of pulmonary artery pressure occurs because of various factors. Disease progression can be complicated by right heart or respiratory failure, and the prognosis is unfavorable. Although hematologists are aware of this rare complication in paroxysmal nocturnal hemoglobinuria or sickle cell disease, we have limited opportunities to study its details (7, 8). Therefore, we should be aware of the characteristics of PH, including its manifestation and screening methods, and bear it in mind as a differential diagnosis.

In this report, we address PV and PH-PVOD from a hematologist's point of view. PH is a condition of high blood pressure in the arteries of the lungs. Pulmonary blood pressure is separate from the systemic blood pressure and controls the pressure of the blood flow in the lungs. Pulmonary blood pressure is lower than systemic blood pressure, and normal pulmonary-artery pressure is approximately 14 mmHg at rest. If the pressure in the pulmonary artery is >25 mmHg, it is considered abnormally high and called PH (2-4). PVOD represents a rare form of PH and is characterized by the preferential involvement of the pulmonary venous system (5, 6). The pathological hallmark of the condition is the obliteration of small pulmonary veins by fibrous intimal thickening and patchy capillary proliferation (9). Therefore, PVOD is a distinct entity from idiopathic pulmonary arterial hypertension (PAH). Indeed, patients with PVOD typically demonstrate a poor response to PAH therapy, and such treatment may lead to life-threatening pulmonary edema (10).

Clinically, PH is divided into 5 broad categories accord-

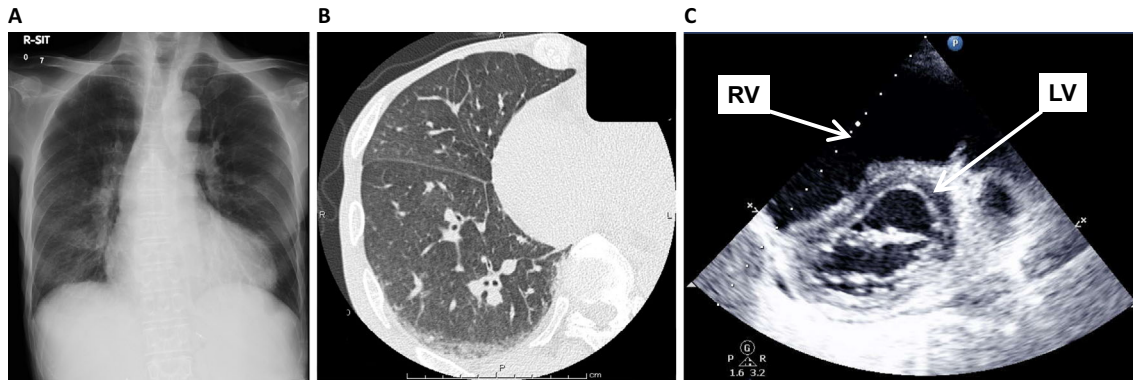


Figure 2. (A) Radiographic findings of chest X-ray. Chest X-ray showed cardiomegaly, the protrusion of the right second aortic arches, and ground-glass opacity, suggesting overburden of the right heart system. (B) Radiographic findings of chest computed tomography. Chest computed tomography indicated thickening of the interlobular septum, granular shadow, wall thickening of the bronchovascular bundle, and ground-glass opacity, findings that were characteristic of pulmonary veno-occlusive disease. (C) Findings of cardio-ultrasonography. The dilation of the right ventricle (RV) and compression of the left ventricle (LV) wall suggested overburden of the right heart system.

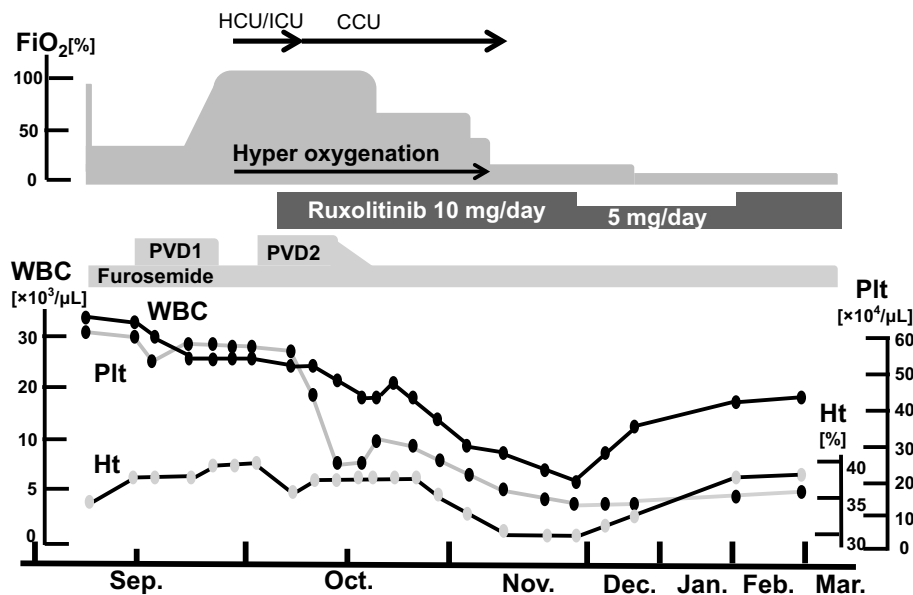


Figure 3. The patient's clinical course. FiO₂: fraction of inspiratory oxygen, HCU: high care unit, ICU: intensive care unit, CCU: coronary care unit, WBC: white blood cell, Ht: hematocrit, Plt: platelet count, PVD1: pulmonary vasodilator, including endothelin-receptor antagonist or phosphodiesterase type 5 inhibitor, PVD2 includes intravenous epoprostenol

ing to the Fifth World Symposium on Pulmonary Hypertension of 2013 (Table 1). PVOD is categorized in Group 1, which also includes PAH and its various subtypes; PVOD belongs to a special subgroup 1' (11, 12). Despite similar clinical presentations, it is important to differentiate PVOD from PAH for the reasons previously mentioned. PH due to blood disease is categorized in Group 5, which is defined as PH with unclear or multifactorial mechanisms. Therefore, some of the conditions in Group 5 may derive from PH-PVOD, and new evidence or knowledge may result in the revision of this ambiguous category in the future.

PH in MPN is relatively well known in Europe and the United States and occurs in 5% to 48% of patients with

MPN, according to previous reports (Table 2) (13-18). However, this condition is relatively rare in Japan. No comments on PH have been documented according to a large cohort study in Japan, although several case reports have been published in domestic journals (19-24). A lack of information including these clinical reports or communication with cardiologists may be one of the reasons for this situation. Furthermore, no useful predictive factors have yet been established. Careful medical care and further investigation are therefore important.

A PH diagnosis is established based on a mean pulmonary artery pressure ≥ 25 mmHg at rest (2-4), and right heart catheterization needs to be performed by a cardiologist. Us-

Table 1. Clinical Classification of Pulmonary Hypertension (NICE, 2013).

Table 2. Epidemiology of PH Associated with MPN.

Reference	Number	Diagnosis	Method for PH	Number of PH
[13]	30	18PV, 8ET, 4AMM	RVSP>35 mmHg	4(13%)
[14]	24	14ET, 6AMM, 2PV, 2CML	RVSP>35 mmHg	10(42%)
[15]	46	46ET	RVSP>35 mmHg	22(48%)
[16]	25	14ET, 9PV, 2CML	RVSP>35 mmHg	12(48%)
[17]	36	22PMF, 7MF post PV, 7MF post ET	RVSP>35 mmHg	13(36%)
[18]	103	32CML, 27ET, 15MF, 26PV, 3other	RVSP>35 mmHg	5(5%)

PH: pulmonary hypertension, MPN: myeloproliferative neoplasm, RVSP: right ventricular systolic pressure by echocardiography, PV: polycythemia vera, ET: essential thrombocythemia, AMM: agnogenic myeloid metaplasia, CML: chronic myelogenous leukemia, PMF: primary myelofibrosis, MF: myelofibrosis

ing invasive and professional techniques, it is important for a hematologist to suspect PH and consult with cardiologists regarding the usual clinical care. One way to detect PH is by identifying one of its symptoms, such as dyspnea, fatigue, or syncope; these are also common in MPNs such as myelofibrosis. Other simple tests such as pulse oximetry, chest radiography, and electrocardiography can also be used to detect PH. Echocardiography is the most critical noninvasive method of screening for PH. Measuring the tricuspid regurgitation velocity and estimating the right atrial pressure is typically considered a valid method of estimating the systolic pulmonary artery pressure (25). Other findings such as the enlargement of the right-sided chambers or right ventricular systolic dysfunction may also indicate right heart overload due to PH. In several previous hematological reports, PH was suspected based on the right ventricular systolic pressure (>35 mmHg) (13-18). Chest CT is also useful for diagnosing PVOD, and the distinctive radiological findings include interstitial edema, ground-glass opacity, interlobular septal thickening, enlarged central pulmonary arteries, and a normal caliber of pulmonary veins (25).

MPNs are characterized by a thrombophilic state, which may lead to microcirculatory disturbances and arterial or venous thrombosis (26). Pathophysiologically, a tumor microembolism, which consists of the translocation of megakaryocytes producing embolism in pulmonary vessels, may be associated with PVOD (27-29). Indeed, an increase in the levels of circulating megakaryocytes and myeloid progenitor cells, which are poorly deformable and larger than the alveolar capillary diameter, has been observed in patients with MPN. As a result, these cells may occlude the pulmonary microvasculature and secrete vasoactive cytokines, eventually leading to the development of PVOD. A histological ex-

amination of the lung revealed obstruction of the small vessels by conglomerates of megakaryocytes (30, 31). PVOD can only be reliably confirmed by a lung biopsy, but video-assisted thoracic surgery or a transbronchial lung biopsy are too invasive to perform in patients with severe respiratory failure or hemorrhagic conditions. Recently, a clinical diagnosis combining characteristic radiographic findings or clinical events has gained acceptance among experts of PVOD (5). According to the PVOD criteria specified by the Ministry of Health, Labor and Welfare in Japan, characteristic radiologic manifestations, such as centrilobular ground-glass opacities, septal lines on CT, and patients' resistance to pulmonary vasodilators, can also lead to a clinical diagnosis of PH-PVOD.

In the present case, the patient developed acute respiratory failure and exacerbation of right heart failure due to PH after he was admitted. Indeed, the use of several pulmonary vasodilators had no effect on the patient's condition, but his pulmonary artery pressure and peripheral blood count decreased. His hypoxia and heart failure stabilized after ruxolitinib was administered. Although splenomegaly and radiographic findings showed little improvement, the decrease in the PAH might have helped improve the patient's acute respiratory and heart failure. The clinical course of this patient therefore suggests that ruxolitinib may be effective for the treatment of patients with PV complicated by PH. Tabaroki et al. described 15 patients with myelofibrosis and PH treated with ruxolitinib and noted that 66% experienced improvement in their pulmonary artery pressure and right ventricle function as measured by echocardiography (32). Ruxolitinib also reduced the plasma levels of N-terminal pro-brain natriuretic peptide, von Willebrand antigen, ristocetin-cofactor activity, and uric acid and increased the

nitric oxide levels.

Another concern is the onset of PH-PVOD. In the present case, the diagnosis was made at the progressive stage of PV. However, the clinical course of PH could not be clarified because the patient was transferred. The accumulation of further cases and careful care for patients with MPN following their diagnosis may be important in the future.

In the course of hospital care, several difficulties were encountered after the respiratory and heart failure were improved. The patient had a history of cerebral infarction complicated by bilateral hemiplegia and respiratory muscle paralysis. Therefore, systemic and long-term rehabilitation was required for the recovery of activities of daily living. At discharge, a variety of medical staff, including cardiologists, hematologists, physiatrists, home physicians, nurses, pharmacists, social workers, and the patient's wife, attended a conference and discussed the patient's medical and daily living problems. In patients with MPN related to PH, a systemic medical condition should be screened, and medical or social support should be considered.

In conclusion, in the clinical care in MPN, the complication of PH should be screened using a non-invasive and simple examination, such as echocardiography; furthermore, cardiologists should be consulted if PH is suspected. Many details of PH in patients with MPN are still unknown—particularly in Japan—so it is important to spread information, accumulate cases, and perform a comprehensive survey, including assessments of the incidence, pathophysiology, treatment, prognosis, and risk factors.

The authors state that they have no Conflict of Interest (COI).

References

- Tefferi A, Thiele J, Orazi A, et al. Proposals and rationale for revision of the World Health Organization diagnostic criteria for polycythemia vera, essential thrombocythemia, and primary myelofibrosis: recommendations from an ad hoc international expert panel. *Blood* **110**: 1092-1097, 2007.
- Seeger W, Adir Y, Barberà JA, et al. Pulmonary hypertension in chronic lung diseases. *J Am Coll Cardiol* **62** (25 Suppl): D109-D116, 2013.
- Badesch DB, Champion HC, Sanchez MA, et al. Diagnosis and assessment of pulmonary arterial hypertension. *J Am Coll Cardiol* **54** (1 Suppl): S55-S66, 2009.
- Singh I, Ma KC, Berlin DA. Pathophysiology of pulmonary hypertension in chronic parenchymal lung disease. *Am J Med* **129**: 366-371, 2016.
- Montani D, Lau EM, Dorfmueller P, et al. Pulmonary veno-occlusive disease. *Eur Respir J* **47**: 1518-1534, 2016.
- Montani D, Price LC, Dorfmueller P, et al. Pulmonary veno-occlusive disease. *Eur Respir J* **33**: 189-200, 2009.
- Devalet B, Mullier F, Chatelain B, Dogné JM, Chatelain C. Pathophysiology, diagnosis, and treatment of paroxysmal nocturnal hemoglobinuria: a review. *Eur J Haematol* **95**: 190-198, 2015.
- Gordeuk VR, Castro OL, Machado RF. Pathophysiology and treatment of pulmonary hypertension in sickle cell disease. *Blood* **127**: 820-828, 2016.
- Pietra GG, Capron F, Stewart S, et al. Pathologic assessment of vasculopathies in pulmonary hypertension. *J Am Coll Cardiol* **43** (12 Suppl S): 25S-32S, 2004.
- Montani D, O'Callaghan DS, Savale L, et al. Pulmonary veno-occlusive disease: recent progress and current challenges. *Respir Med* **104** (Suppl 1): S23-S32, 2010.
- Galiè N, Hoeper MM, Humbert M, et al; Task Force for Diagnosis and Treatment of Pulmonary Hypertension of European Society of Cardiology (ESC), European Respiratory Society (ERS), International Society of Heart and Lung Transplantation (ISHLT). Guidelines for the diagnosis and treatment of pulmonary hypertension. *Eur Respir J* **34**: 1219-1263, 2009.
- Simonneau G, Gatzoulis MA, Adatia I, et al. Updated clinical classification of pulmonary hypertension. *J Am Coll Cardiol* **62** (25 Suppl): D34-D41, 2013.
- Garypidou V, Vakalopoulou S, Dimitriadis D, Tziomalos K, Sfikas G, Perifanis V. Incidence of pulmonary hypertension in patients with chronic myeloproliferative disorders. *Haematologica* **89**: 245-246, 2004.
- Altintas A, Karahan Z, Pasa S, et al. Pulmonary hypertension in patients with essential thrombocythemia and reactive thrombocytosis. *Leuk Lymphoma* **48**: 1981-1987, 2007.
- Chebrek S, Aïssi K, Francès Y, et al. Pulmonary hypertension in patients with chronic myeloproliferative neoplasms. *Leuk Lymphoma* **55**: 223-225, 2014.
- Reisner SA, Rinkevich D, Markiewicz W, Tatarsky I, Brenner B. Cardiac involvement in patients with myeloproliferative disorders. *Am J Med* **93**: 498-504, 1992.
- Gupta R, Perumandla S, Patsiornik Y, Niranjana S, Ohri A. Incidence of pulmonary hypertension in patients with chronic myeloproliferative disorders. *J Natl Med Assoc* **98**: 1779-1782, 2006.
- Cortelezzi A, Gritti G, Del Papa N, et al. Pulmonary arterial hypertension in primary myelofibrosis is common and associated with an altered angiogenic status. *Leukemia* **22**: 646-649, 2008.
- Okamura T, Kinukawa N, Niho Y, Mizoguchi H. Primary chronic myelofibrosis: clinical and prognostic evaluation in 336 Japanese patients. *Int J Hematol* **73**: 194-198, 2001.
- Dan K, Yamada T, Kimura Y, et al; Japanese Elderly Leukemia and Lymphoma Study Group. Clinical features of polycythemia vera and essential thrombocythemia in Japan: retrospective analysis of a nationwide survey by the Japanese Elderly Leukemia and Lymphoma Study Group. *Int J Hematol* **83**: 443-449, 2006.
- Shimomoto H, Imaizumi K, Mizoguchi K, Ikeda T. A case of essential thrombocythemia with pulmonary hypertension and bilateral pleural effusions. *Nihon Kyobu Shikkan Gakkai Zasshi (Jpn J Thorac Dis)* **28**: 504-510, 1990 (in Japanese, Abstract in English).
- Yanagawa K, Yamane M, Okada T, et al. Marked pulmonary atherosclerosis in polycythemia vera associate with severe pulmonary hypertension. *Nihon Naika Gakkai Zasshi (J Jpn Soc Inter Med)* **94**: 969-972, 2005 (in Japanese).
- Inoue H, Nakada S, Ishikawa T, Miyawaki H, Saitou K, Kimura J. Essential thrombocythemia complicated with pulmonary hypertension. *Nihon Naika Gakkai Zasshi (J Jpn Soc Inter Med)* **95**: 133-135, 2006 (in Japanese).
- Tanaka M, Shimizu T, Onoue N, Baba S, Tanikawa T, Shinozaki T. A case of pulmonary hypertension associated with primary myelofibrosis. *Heart* **40**: 548-553, 2008.
- Pyxaras SA, Pinamonti B, Barbati G, et al. Echocardiographic evaluation of systolic and mean pulmonary artery pressure in the follow-up of patients with pulmonary hypertension. *Eur J Echocardiogr* **12**: 696-701, 2011.
- Holcomb BW Jr, Loyd JE, Ely EW, Johnson J, Robbins IM. Pulmonary veno-occlusive disease: a case series and new observations. *Chest* **118**: 1671-1679, 2000.
- Landolfi R, DiGennaro L, Falanga A. Thrombosis in myeloproliferative disorders: pathogenetic facts and speculation. *Leukemia* **22**: 2020-2028, 2008.

28. Adir Y, Elia D, Harari S. Pulmonary hypertension in patients with chronic myeloproliferative disorders. *Eur Respir Rev* **24**: 400-410, 2015.
29. Willems E, Canivet JL, Ghaye B, et al. Pulmonary veno-occlusive disease in myeloproliferative disorder. *Eur Respir J* **33**: 213-216, 2009.
30. Dot JM, Sztrymf B, Yaïci A, et al. Pulmonary arterial hypertension due to tumor emboli. *Rev Mal Respir* **24** (3 Pt 1): 359-366, 2007.
31. Halank M, Marx C, Baretton G, Müller KM, Ehninger G, Höffken G. Severe pulmonary hypertension in chronic idiopathic myelofibrosis. *Onkologie* **27**: 472-474, 2004.
32. Tabarrok A, Lindner DJ, Visconte V, et al. Ruxolitinib leads to improvement of pulmonary hypertension in patients with myelofibrosis. *Leukemia* **28**: 1486-1493, 2014.

The Internal Medicine is an Open Access article distributed under the Creative Commons Attribution-NonCommercial-NoDerivatives 4.0 International License. To view the details of this license, please visit (<https://creativecommons.org/licenses/by-nc-nd/4.0/>).

© 2017 The Japanese Society of Internal Medicine
Intern Med 56: 2487-2492, 2017