








Surgical treatment of type III acromioclavicular dislocation: Bosworth technique versus hook plating

 Seyit Ali Gumustas,¹  Fevzi Saglam,²  Baran Komur,³  Ahmet Guray Batmaz,⁴
 Ismail Yukunc,⁵  Haci Bayram Tosun,⁶  Halil Ibrahim Bekler⁷

¹Department of Orthopaedics and Traumatology, Dr. Lutfi Kirdar Kartal Training and Research Hospital, Istanbul, Turkey

²Department of Orthopaedics and Traumatology, Sultanbeyli State Hospital, Istanbul, Turkey

³Department of Orthopaedics and Traumatology, Kanuni Sultan Suleyman Training and Research Hospital, Istanbul, Turkey

⁴Department of Orthopaedics and Traumatology, Istanbul Medipol University Faculty of Medicine, Istanbul, Turkey

⁵Department of Orthopaedics and Traumatology, Yavuz Selim Bone disease and Rehabilitation Hospital, Trabzon, Turkey

⁶Department of Orthopaedics and Traumatology, Adiyaman University Faculty of Medicine, Adiyaman, Turkey

⁷Department of Orthopaedics and Traumatology, VM Medical Park Kocaeli Hospital, Kocaeli, Turkey

ABSTRACT

OBJECTIVE: In this study, it was compared the clinical results of the Bosworth technique and hook plating in acromioclavicular (AC) dislocations.

METHODS: 44 patients are retrospectively evaluated in this study whom diagnosed as type III AC dislocations and treated by two different surgical methods in two different clinics. The patients were 30 males and 14 females with a mean age of 44 years (range, 18–80 years). The patients were divided into 2 groups according to the applied surgical technique. Group I comprised 25 patients to whom coracoclavicular fixation was applied by using the Bosworth technique. Group II comprised 19 patients to whom acromioclavicular fixation was applied by using hook plate. All patients are evaluated by The University of California at Los Angeles Shoulder Score (UCLA) and The disabilities of the arm, shoulder and hand (DASH) scoring system.

RESULTS: The mean follow-up period was 23 months (range, 12–42 months). A statistically significant difference was determined between the surgical groups in respect of the modified UCLA scale ($p=0.012$) and Quick DASH score ($p=0.008$). Hook plating group had better clinical results according to Bosworth group in terms of both UCLA and DASH score. A statistically highly significant negative correlation was determined between the UCLA and DASH scores ($r=0.677$, $p=0.000$).

CONCLUSION: Although hook plating had better clinic outcomes compared to Bosworth technique, there is not seen difference between two groups in terms of the time of return to work. Treatment of the AC dislocation should perform early reconstruction for better reduction, fewer complications and higher levels of patient satisfaction.

Keywords: Acromioclavicular dislocation; bosworth technique; fixation; hook plating; results.

Cite this article as: Gumustas SA, Saglam F, Komur B, Batmaz AG, Yukunc I, Tosun HB, et al. Surgical treatment of type III acromioclavicular dislocation: Bosworth technique versus hook plating. *North Clin Istanbul* 2018;5(4):334–340.

As one of the most important joints around the shoulder, injuries to the acromioclavicular joint (AC) are very important, as depending on the degree of injury, they cause restrictions to the daily life of the patient and work-force losses. Although several treatment methods have

been described in literature, it has not been fully clarified which type of treatment is recommended for which type of dislocation [1–6]. The degree of injury and the functional expectations of the patient are the primary indicators. In type III AC joint injuries, there is a severe trauma



Received: November 05, 2017 Accepted: December 29, 2017 Online: December 29, 2017

Correspondence: Dr. Haci Bayram TOSUN. Adiyaman Universitesi Tip Fakultesi, Ortopedi ve Travmatoloji Klinigi, Adiyaman, Turkey.
Tel: +90 533 449 76 99 e-mail: bayramtosun@hotmail.com

© Copyright 2018 by Istanbul Northern Anatolian Association of Public Hospitals - Available online at www.kuzeyklinikleri.com

TABLE 1. General characteristics of the patients according to the surgical group

	Hook	Bosworth	p	Total
Age	46.05±7.28	40.80±9.09	0.053	43.06±8.67
Gender				
Female	10 (52.6)	4 (16)	0.01*	14 (31.8)
Male	9 (47.4)	21 (84)		30 (68.2)
Side				
Left	4 (21.1)	11 (44)	0.11	15 (34.1)
Right	15 (78.9)	14 (56)		29 (65.9)
Dominant side				
Left	2 (10.5)	5 (20)	0.68	7 (15.9)
Right	17 (89.5)	20 (80)		37 (84.1)
Trauma type				
Sport	4 (21.1)	6 (24)		10 (22.7)
Traffic accident	5 (26.3)	4 (16)	0.70	9 (20.5)
Fall	10 (52.6)	15 (60)		25 (56.8)
Preoperative period (days)	2.57±1.01	4.32±1.49	0.001*	3.56±1.56
Hospitalization (days)	4.68±1.15	5.36±1.49	0.11	5.06±1.38
Follow-up (months)	20.84±7.04	25.12±9.72	0.16	23.27±8.84

*p<0.05

with joint dislocation from tears of the AC ligament and capsule and tears of the coracoclavicular (CC) ligament. If evaluation is only made radiologically without making a thorough physical examination, there is a high possibility that these types of injuries will be overlooked [2, 6–8].

In radiological comparison with the contralateral side, the CC ligament may be displaced by a distance of between 25%–100% [7, 9]. If adequate treatment is not applied to patients with type III AC injuries, it may be seen undesirable results such as pain, restricted movement of the shoulder joint, weakness around the shoulder, arthrosis in the AC joint, subluxation and re-dislocation, restriction of daily activities and sporting activities of the patient in the future. Therefore, it must be obtained stability of the AC joint without disrupting the movements and strength of the shoulder in the ideal treatment [7].

In this study, we retrospectively evaluated the clinical results of Bosworth technique and hook plating in acromioclavicular (AC) dislocations.

MATERIALS AND METHODS

In this study, a retrospective examination was made of a total of 44 patients who were surgically treated for type III acromioclavicular joint dislocation. All patients were

given detailed information about this surgery, and approval was obtained. The patients were 30 males and 14 females with a mean age of 44 years (range, 18–80 years). Group I comprised 25 patients to whom coracoclavicular fixation was applied using malleolar screw in the Bosworth technique [6, 10]. Group II comprised 19 patients to whom acromioclavicular fixation was applied using hook plate with the AO technique [11]. The mechanism of injury was a fall in 25 cases, a sports injury in 10 and a traffic accident in 9. The injury was on the right side in 29 patients and on the left in 15 and the mean time to surgery was 4 days (range, 1–8 days). Exclusion criteria were conservative treatment, concomitant clavicular fractures, chronic cases and those who had less than 1 year of follow-up (Table 1).

Postoperative functional evaluation was made using modified The University of California at Los Angeles Shoulder Score (UCLA) scale [12] and The disabilities of the arm, shoulder and hand (Quick DASH) scoring system [13]. In the modified UCLA scale 18–20 points was evaluated as very good, 15–17 points as good, 12–14 points as fair and <11 points as poor.

The patients in group I were operated on under general anaesthesia in the semi-seated position by the same orthopaedic surgeon (SAG). The skin layers over the

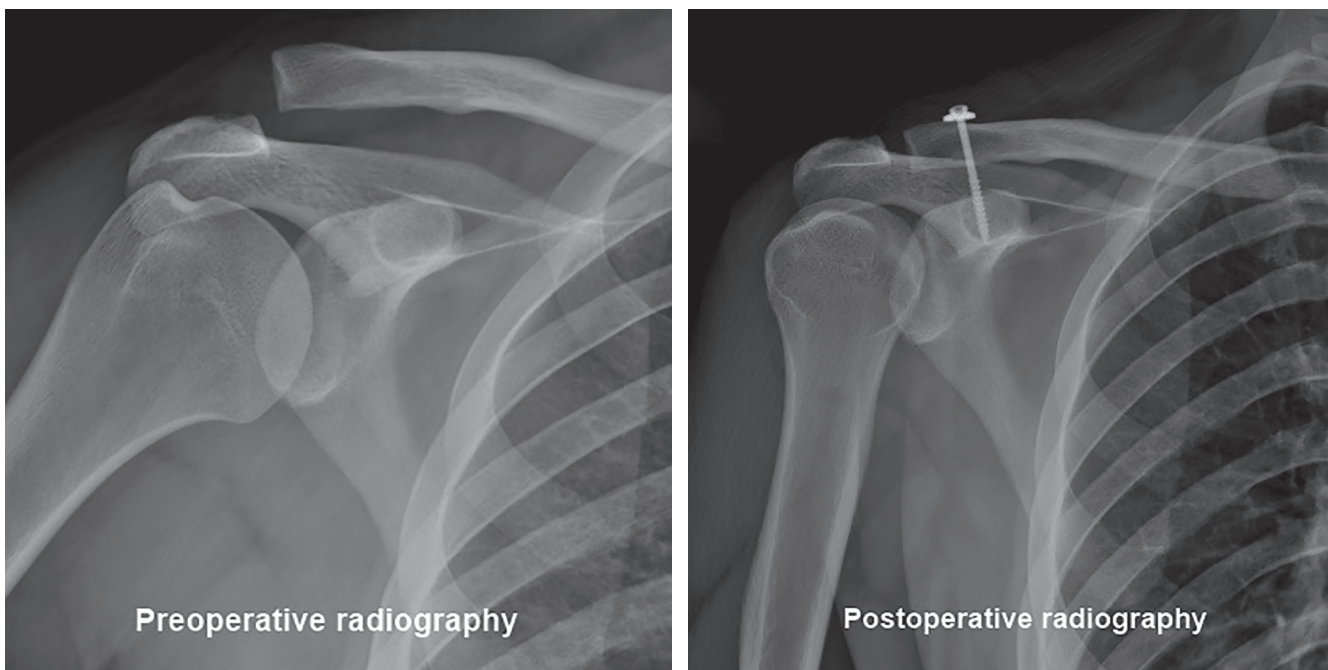


FIGURE 1. Bosworth technique radiography.

clavicle were entered with a parallel incision. After reduction of the AC joint, the clavicle and coracoid were drilled with a 3.2 mm drill. Only the superior cortex of the clavicle was hollowed with a 4.5 mm drill. Fixation was applied with one semi-cannulated spongious screw (malleolar screw) of appropriate size and a washer (Fig. 1). In 3 patients, as there was a torn or subluxated disc which was preventing reduction of the AC joint, the disc was excised by extending the incision. It was not applied the CC ligament repair in any patient.

The patients in group II were operated on under general anaesthesia by another orthopaedic surgeon (İY). Entry was made with a straight incision of 5–6 cm starting from the distal of the clavicle and extending to the AC joint. After reduction of the joint by excision of the meniscus, fixation was applied with placement of a hook plate of appropriate size (Fig. 2).

Postoperative rehabilitation protocols were not applied the same for each groups and patients. A shoulder-arm sling was used the all patients in the both groups for post-

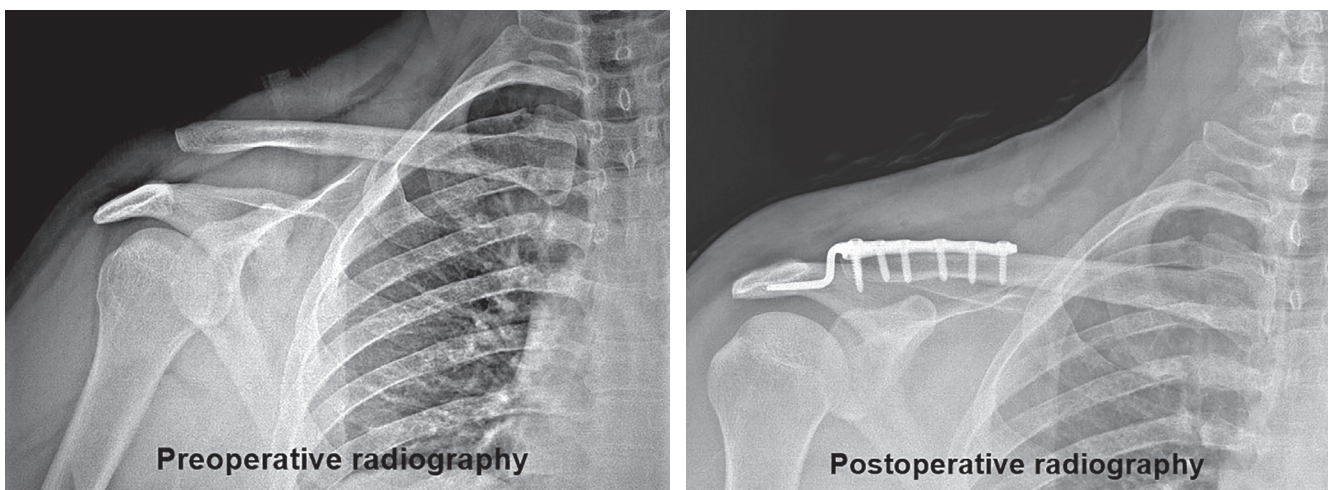


FIGURE 2. Hook plate technique.

operative 3 weeks, but it was allowed to remove the sling 4 or 5 times a day to do pendulum exercises. All patients were referred for physical therapy and passive and active joint range of movement exercises were started. It was not allowed to weight lift any objects over 1–2 pounds and to elevate of operated arm above 90 degrees in any plane for a period of first 6 weeks. However, it was not allowed to elevate of operated arm above 90 degrees in any plane for patients in hook plate groups. The patients applied hook plate in contrast to Bosworth technique are not recommended the arm abduction over 90 degrees till implant removal. After 3 months, activities requiring strength were permitted. Complaints of excessive pain in the shoulder or restricted movement were considered to be due to the implant or insufficient material and after at least 6 months, all of the implants were removed.

Statistical analysis of the data was made using SPSS 17.5 statistics software program. In the comparison of categorical variables, the Chi-square test was used. Continuous variables with normal distribution were compared with the T-test and those not with normal distribution with the Mann Whitney U-test. A value of $p < 0.05$ was considered statistically significant.

RESULTS

The mean follow-up period was 23 months (range, 12–42 months). The general distribution and according to the surgical groups is shown in Table 1. Postoperatively, the mean modified UCLA scale value was 16.6 (range, 14–19), the mean Quick DASH score was 14.5 (range, 2.2–26.8). According to the modified UCLA scale, 17 (38.6%) patients were evaluated as very good, 22 (50.0%) patients as good and 5 (11.4%) patients as moderate (Table 2). No poor results were obtained in any patient. A statistically significant difference was determined between the surgical groups in respect of the modified UCLA scale ($p = 0.012$) and Quick DASH score ($p = 0.008$). Hook plating group had better clinical results according to Bosworth group in terms of both modified UCLA and DASH score. A statistically highly significant negative correlation was determined between the UCLA and DASH scores ($r = 0.677$, $p = 0.000$) (Table 3).

Mean time for return to work of all the patients was 3.3 months (range, 2–6 months). No statistically significant difference was determined between the two groups in respect of the return to work ($p = 0.58$). Removal of the fixation material was applied at mean 4.6 months (4.2 months for Bosworth technique, 5.1 months for Hook plating). At the final physical examination, all patients

TABLE 2. Comparison of modified UCLA scale in Group I and Group II

UCLA	Group		
	Hook	Bosworth	Total
Very Good			
Count	10	7	17
% within group	52.6%	28.0%	38.6%
Good			
Count	6	16	22
% within group	31.6%	64.0%	50.0%
Moderate			
Count	3	2	5
% within group	15.8%	8.0%	11.4%
Total			
Count	19	25	44
% within group	100.0%	100.0%	100.0%

UCLA: The University of California at Los Angeles Shoulder Score.

TABLE 3. Comparison between both groups of functional outcomes and time of return to work

	Hook plating	Bosworth technique	p
UCLA	17.42±1.80	16.12±1.26	0.012*
DASH	9.22±8.61	18.58±4.30	0.008*
Return to work (month)	3.42±1.26	3.24±0.72	0.58

UCLA: The University of California at Los Angeles Shoulder Score; DASH: The disabilities of the arm, shoulder and hand; * $p < 0.05$; A highly significant negative correlation was determined between the UCLA and DASH scores ($r = -0.677$, $p = 0.000$).

were observed to have full shoulder joint range of movement. During surgery, no complications such as vascular or nerve damage were encountered in any patient. A change in working or sporting activities had to be made in 3 (6.8%) patients. We observe 1 hook plate breaking and 1 superficial wound infection that treated by antibiotic therapy. We observe 5 AC arthritis (4 was in hook plate group) and 3 reduction loss (2 in Bosworth group).

DISCUSSION

In this study, we compared the clinical outcomes of patients who underwent hook plating and Bosworth technique for type III AC dislocation. Hook plating group

had better clinical results according to Bosworth group in terms of both modified UCLA ($p=0.012$) and DASH score ($p=0.008$). No statistically significant difference was determined between both groups in respect of the return to work ($p=0.58$). At the final physical examination after removal of implant, all patients were observed to have full shoulder joint range of movement.

Typically, acromioclavicular injuries result from direct trauma to the shoulder from a fall or in contact sports when the arm is in an adducted position. The force pushes the acromion inferiorly while the clavicle maintains its anatomic position, resulting in a variable disruption of the acromioclavicular and coracoclavicular ligaments [12]. Treatments are based on one of three types of fixation: acromioclavicular, coracoclavicular, and dynamic muscle transfer. These procedures can all be combined with ligament augmentation and/or resection of the distal clavicle [4]. Some authors have advocated conservative treatment in cases of acute Type III dislocations and recommend 2–8 weeks immobilization following reduction in these patients [14, 15].

There are some studies reported that results of conservative treatment were better than those of surgical treatment [16, 17]. However, in young active patients with severe AC displacement of >2 cm, surgical treatment was recommended [6]. Galpin et al. [18] compared the conservative treatment method with surgical treatment using the Bosworth technique. They reported that the results of both techniques were reported to be similar even though there was a slight delay in return to work, sports and activity in the patients of the conservative treatment group [18]. Inadequate treatment results have been reported from conservative treatment characterized by pain, loss of strength and restricted movement in 20% of conservatively-treated patients with difficulties in tolerance and the development of cosmetic problems [6, 7, 15, 19, 20]. Therefore, many authors have advocated surgery in the treatment of acute AC dislocations [5–8]. Previous studies have shown the superiority of surgical treatment according to conservative treatment [14]. The basic aim of surgery is to obtain anatomic reduction and stable fixation. The disadvantages of surgery are the requirement for anaesthesia, the risk of infection and the possibility of degenerative arthritis [7, 20]. Superficial wound site infection following AC joint luxation has been reported in literature at rates of 0%–53% [1–3]. In our study, we carried out surgery for all Type III dislocations and observed one superficial infection whom healing by antibiotherapy.

When patients with AC dislocation are performed early reconstruction, it will be obtained better reduction, fewer complications and higher levels of patient satisfaction [21]. Weinstein et al. reported that worse results were obtained in cases where a period of more than 3 months had elapsed before surgery [22]. In our study, surgical treatment was applied to patients who presented within 10 days of the trauma and were evaluated as an acute injury. We carried out surgery for acute dislocations when patients applied to us and we exclude the patients whom undergone for late surgery.

Fukuda et al. emphasized that it is important the effects on stabilization and clinical outcomes of the ligament repair [23]. Ligament repair with the Bosworth technique is an effective technique in obtaining adequate shoulder functions with ease of application, a low complication rate and low rates of acromioclavicular joint arthritis [2, 3, 24]. The most common complication of surgical treatment is loss of reduction in the joint because of problems such as breakage or loosening of the screw [3, 6, 25]. Bektaser et al. [2] reported that it is seen recurrence of dislocation in only 8.8% of patients treated with the modified Bosworth technique [2]. Although it has been reported that there may be mild pain and discomfort in the follow-up of cases with subluxation, the results of most of these cases have been good, and no relationship has been determined between the amount of subluxation and the outcome [3, 26]. In our study, we didn't apply coracoclavicular ligament repair to any patient. We observed reduction loss in 2 patients who was performed Bosworth technique. For this reason, we think ligaments repair is important at stability and re-dislocation.

The rates of arthritis in the Bosworth technique are extremely low [3], but AC arthritis has been reported to be seen more often in cases where reduction could not be achieved [27]. Taft et al. [19] reported that in patients where anatomic reduction could not be achieved, although degenerative changes are generally seen radiographically, insufficient anatomic restoration did not effect the clinical results or patient satisfaction [19]. In our study, as there were complaints of excessive pain in one patients who developed arthritis following the Bosworth procedure, the material was removed. At 3 months post-operatively, the complaints of these patients were seen to have completely recovered. We observed AC arthritis in five patients but we did not perform acromioplasty to any patient.

A limitation of the modified Bosworth technique is

the need for a second intervention to remove the screw [28]. A good balance must be struck between early removal of the screw to prevent breakage and the risk of deformity developing again. Otherwise, the recurrence of deformity may be seen at the high rate of 35% in literature (3/3). It is usually recommended that the screw is removed in the 8th week [6]. In our study, the screw was removed after the 3rd month (3–7 months).

The hook-plate is a useful device for the treatment of unstable injuries in the acromioclavicular region. Although the main concern in the application of hook plate is subacromial impingement, good results have been obtained in many studies without this complication [29]. Koukakis et al. [30] suggested that extraction of the osteosynthetic material within 3 months because of the possibility of subacromial impingement. In our study, the plate was removed in one patient with pain due to the development of AC arthritis after hook plating, and the complaints were seen to recover.

Biomechanical complications can be observed in both techniques. Kienast et al. [31] reported that it was developed complications in 24 (10.6%) of 225 patients, and the most common complication was reported to be redislocation after removal of the hook plate. Baets et al. [11] reported that despite AC joint changes and an increased CC distance compared to the healthy side, excellent and good clinical results after surgery were obtained. The clinical results of their study were reported to be better than the radiological results.

Kezunović et al. [5] have compared these two techniques in 28 patients with AC dislocation. They reported that postoperative complications were seen in 8 of the 16 patients in the Bosworth group and seen in only 2 of the 12 patients in hook plate group, but it was not statistically significant difference. However, the patient satisfaction and Constant scores of the hook plate group were determined to be statistically significantly high. Broos et al. [27] reported that it was no statistically significant difference between the Bosworth technique and hook plating in a long-term study of 87 patients with AC dislocation. In their study, high complication rates (16% implant failure, 25% redislocation, 39% calcification, 41% arthritis) and low success rates (60% very good and good results) were obtained. In our study, better functional results were obtained in the hook plate group without additional soft tissue interventions.

Previous studies have been generally recommended the application of a shoulder-arm sling for 1–4 weeks,

but early functional motion is important and must avoid from limitations of shoulder motion [1, 3, 24]. In our study, a shoulder-arm sling was routinely applied for a period of 3 weeks postoperatively. During this period, shoulder pendulum exercises and wrist and elbow active exercises were permitted.

Limitations of this study are lack of long-term results and there is no control group of conservative. Also, the groups were not randomised and the design of the study was retrospective.

In conclusion, although hook plating had better clinic outcomes compared to Bosworth technique, there is no statistically significant difference between two groups in terms of the time of return to work. Treatment of the AC dislocation should perform early reconstruction for better reduction, fewer complications and higher levels of patient satisfaction. A good balance should be struck between the time of removal of the implants to prevent breakage of implant and recurrence of deformity.

Conflict of Interest: No conflict of interest was declared by the authors.

Financial Disclosure: The authors declared that this study has received no financial support.

Authorship Contributions: Concept – S.A.G., I.Y.; Design – S.A.G., I.Y.; Supervision – S.A.G., I.Y.; Materials – S.A.G., F.S., B.K., A.G.B., I.Y.; Data collection &/or processing – S.A.G., F.S., B.K., A.G.B., I.Y.; Analysis and/or interpretation – S.A.G., B.K., I.Y., H.B.T.; Writing – S.A.G., F.S., B.K., A.G.B., H.B.T.; Critical review – S.A.G., F.S., I.Y., H.B.T.

REFERENCES

1. Mardani-Kivi M, Mirbolook A, Salariyeh M, Hashemi-Motlagh K, Saheb-Ekhtiari K. The comparison of Ethibond sutures and semitendinosus autograft in the surgical treatment of acromioclavicular dislocation. *Acta Orthop Traumatol Turc* 2013;47:307–10.
2. Bektaşer B, Bozkurt M, Oçgüder A, Solak S, Oğuz T. Surgical treatment of type III acromioclavicular joint dislocations by a modified Bosworth technique. *Ulus Travma Acil Cerrahi Derg* 2004;10:245–9.
3. Esenyel CZ, Öztürk K, Bülbül M, Ayanoğlu S, Ceylan HH. Coracoclavicular ligament repair and screw fixation in acromioclavicular dislocations. *Acta Orthop Traumatol Turc* 2010;44:194–8.
4. Basyoni Y, El-Ganainy AE, Aboul-Saad M. Acromioclavicular joint reconstruction using anchor sutures: surgical technique and preliminary results. *Acta Orthop Belg* 2010;76:307–11.
5. Kezunović M, Bjelica D, Popović S. Comparative study of surgical treatment of acromioclavicular luxation. *Vojnosanit Pregl* 2013;70:292–7.
6. Bannister GC, Wallace WA, Stableforth PG, Hutson MA. The management of acute acromioclavicular dislocation. A randomised prospective controlled trial. *J Bone Joint Surg Br* 1989;71:848–50.
7. Kaplan H, Kiral A, Kuskucu M, Arpacioğlu MO, Sarioglu A, Rodop O. Report of eight cases of humeral fracture following the throwing of

- hand grenades. *Arch Orthop Trauma Surg* 1998;117:50–2.
8. Li X, Ma R, Bedi A, Dines DM, Altchek DW, Dines JS. Management of acromioclavicular joint injuries. *J Bone Joint Surg Am* 2014;96:73–84.
 9. Rockwood CA Jr. Injuries to the acromioclavicular joint. In: Rockwood CA Jr, Green DP. *Fractures in adults*. Vol 1. 2nd ed. Philadelphia: JB Lippincott; 1984. p 860–910.
 10. Bosworth BM. Acromioclavicular separation: New method of repair. *Surg Gynecol Obstet* 1941;73:866–71.
 11. De Baets T, Truijen J, Driesen R, Pittevels T. The treatment of acromioclavicular joint dislocation Tossy grade III with a clavicle hook plate. *Acta Orthop Belg* 2004;70:515–9.
 12. Algarín JR, Salcedo JD, Rodríguez JO, Bello AG, Sancho FB. Grade III acromioclavicular dislocation treated with a minimally invasive approach. [Article in Spanish]. *Acta Ortop Mex* 2010;24:317–23.
 13. Gummesson C, Ward MM, Atroshi I. The shortened disabilities of the arm, shoulder and hand questionnaire (QuickDASH): validity and reliability based on responses within the full-length DASH. *BMC Musculoskelet Disord* 2006;7:44.
 14. Darrow JC Jr, Smith JA, Lockwood RC. A new conservative method for treatment of Type III acromioclavicular separations. *Orthop Clin North Am* 1980;11:727–33.
 15. Schlegel TF, Burks RT, Marcus RL, Dunn HK. A prospective evaluation of untreated acute grade III acromioclavicular separations. *Am J Sports Med* 2001;29:699–703.
 16. Glick JM, Milburn LJ, Haggerty JF, Nishimoto D. Dislocated acromioclavicular joint: follow-up study of 35 unreduced acromioclavicular dislocations. *Am J Sports Med* 1977;5:264–70.
 17. Dias JJ, Steingold RF, Richardson RA, Tesfayohannes B, Gregg PJ. The conservative treatment of acromioclavicular dislocation. Review after five years. *J Bone Joint Surg Br* 1987;69:719–22.
 18. Galpin RD, Hawkins RJ, Grainger RW. A comparative analysis of operative versus nonoperative treatment of grade III acromioclavicular separations. *Clin Orthop Relat Res* 1985:150–5.
 19. Taft TN, Wilson FC, Oglesby JW. Dislocation of the acromioclavicular joint. An end-result study. *J Bone Joint Surg Am* 1987;69:1045–51.
 20. Lancaster S, Horowitz M, Alonso J. Complete acromioclavicular separations. A comparison of operative methods. *Clin Orthop Relat Res* 1987:80–8.
 21. Rolf O, Hann von Weyhern A, Ewers A, Boehm TD, Gohlke F. Acromioclavicular dislocation Rockwood III-V: results of early versus delayed surgical treatment. *Arch Orthop Trauma Surg* 2008;128:1153–7.
 22. Weinstein DM, McCann PD, McIlveen SJ, Flatow EL, Bigliani LU. Surgical treatment of complete acromioclavicular dislocations. *Am J Sports Med* 1995;23:324–31.
 23. Fukuda K, Craig EV, An KN, Cofield RH, Chao EY. Biomechanical study of the ligamentous system of the acromioclavicular joint. *J Bone Joint Surg Am* 1986;68:434–40.
 24. Weitzman G. Treatment of acute acromioclavicular joint dislocation by a modified Bosworth method. Report on twenty-four cases. *J Bone Joint Surg Am* 1967;49:1167–78.
 25. Pavlik A, Csépai D, Hidas P. Surgical treatment of chronic acromioclavicular joint dislocation by modified Weaver-Dunn procedure. *Knee Surg Sports Traumatol Arthrosc* 2001;9:307–12.
 26. Graupe F, Dauer U, Eysel M. Late results of surgical treatment of Tossy III acromioclavicular joint separation with the Balsler plate. [Article in German]. *Unfallchirurg* 1995;98:422–6.
 27. Broos P, Stoffelen D, Van de Sijpe K, Fourneau I. Surgical management of complete Tossy III acromioclavicular joint dislocation with the Bosworth screw or the Wolter plate. A critical evaluation. [Article in German]. *Unfallchirurgie* 1997;23:153–9.
 28. Law KY, Yung SH, Ho PY, Chang HT, Chan KM. Coracoclavicular ligament reconstruction using a gracilis tendon graft for acute type-III acromioclavicular dislocation. *J Orthop Surg (Hong Kong)* 2007;15:315–8.
 29. Faraj AA, Ketzler B. The use of a hook-plate in the management of acromioclavicular injuries. Report of ten cases. *Acta Orthop Belg* 2001;67:448–51.
 30. Koukakis A, Manouras A, Apostolou CD, Lagoudianakis E, Papadima A, Triantafillou C, et al. Results using the AO hook plate for dislocations of the acromioclavicular joint. *Expert Rev Med Devices* 2008;5:567–72.
 31. Kienast B, Thietje R, Queitsch C, Gille J, Schulz AP, Meiners J. Mid-term results after operative treatment of rockwood grade III-V acromioclavicular joint dislocations with an AC-hook-plate. *Eur J Med Res* 2011;16:52–6.