

## ORIGINAL ARTICLE

# Clinical Features of Ulnar Tunnel Syndrome and the Diagnostic Value of Nerve Conduction Measurements

Shingo Nobuta, MD, PhD<sup>a</sup> Hiroshi Okuno, MD, PhD<sup>a</sup> Taku Hatta, MD, PhD<sup>a</sup> Ryo Sato, MD, PhD<sup>a</sup>  
and Eiji Itoi, MD, PhD<sup>b</sup>

**Objectives:** The purposes of this study were to assess the clinical features of ulnar tunnel syndrome (UTS) and to investigate the diagnostic value of nerve conduction measurements for UTS. **Methods:** Eighteen patients with UTS were reviewed retrospectively. Fifteen patients had intrinsic muscle atrophy and motor weakness, and 15 had numbness with hypesthesia. The compound muscle action potentials (CMAPs) from the first dorsal interosseous (FDI) muscle and the abductor digiti minimi (ADM) muscle and the sensory nerve action potential (SNAP) from the little finger were recorded and analyzed. All patients underwent ulnar tunnel release surgery and neurolysis. Static two-point discrimination test results and pinch strengths were assessed before and after surgery. **Results:** Before surgery, FDI-CMAP was recorded in 17 patients, and ADM-CMAP in 16, and all showed delayed latency and/or low amplitude. SNAP was recorded in eight patients and two showed delayed latency. The causes of ulnar nerve lesions were ganglion in five patients, traumatic adhesion in four, ulnar artery aberrancy in four, pisohamate arch in three, anomalous muscle in one, and ulnar vein varix in one. The sites of the lesions were in zone 1 of the ulnar tunnel anatomy in 12 patients, in zone 2 in 2, and in zones 1 and 2 in 4. After surgery, all patients obtained recovery of motor function and sensation; however, postoperative FDI-CMAP and ADM-CMAP did not improve to the normal range. **Conclusions:** The causes of UTS were ganglion, traumatic adhesion, ulnar artery aberrancy, and pisohamate arch. Both FDI-CMAP and ADM-CMAP were valuable for electrophysiological diagnosis of UTS.

**Key Words:** abductor digiti minimi; first dorsal interosseous; nerve conduction measurement; ulnar nerve lesion; ulnar tunnel syndrome

## INTRODUCTION

Ulnar tunnel syndrome (UTS) is an uncommon form of ulnar entrapment neuropathy at the wrist that can be caused by several intrinsic or extrinsic factors.<sup>1-4</sup> A review of the literature indicated the following possible causes of UTS: ganglions,<sup>5-16</sup> traumatic neuropathies,<sup>8</sup> anomalous muscle or fibrous bands,<sup>10,17,18</sup> ulnar artery thromboses or aberrancy,<sup>7,10</sup> wrist fracture,<sup>5</sup> carpal osteoarthritis,<sup>8</sup> pisohamate arch,<sup>11</sup> and idiopathic.<sup>3</sup> Most previous reports have dealt with a small number of cases,<sup>5-7,11-18</sup> and we previously

reported five cases of UTS caused by ganglion.<sup>16</sup> In 1861, Guyon<sup>19</sup> reported the anatomy of the ulnar area and predicted that problems could occur with entrapment of the ulnar nerve, and in 1908 Hunt<sup>20</sup> described three patients with occupational neuritis. Seddon<sup>5</sup> and Richmond<sup>6</sup> reported ulnar nerve palsy caused by a carpal ganglion. In 1965, Dupont et al.<sup>7</sup> used the term ulnar tunnel syndrome and reported four cases. An exact clinical diagnosis of UTS and detection of the location of the causative lesion are difficult, and electrophysiological diagnosis may help to confirm the diagnosis.<sup>2-4,11,13-16,21-25</sup> The purposes of this study were to assess

Received: October 16, 2020, Accepted: January 27, 2021, Published online: February 13, 2021

<sup>a</sup> Department of Orthopaedic Surgery, Tohoku Rosai Hospital, Sendai, Japan

<sup>b</sup> Department of Orthopaedic Surgery, Tohoku University School of Medicine, Sendai, Japan

Correspondence: Shingo Nobuta, MD, PhD, Department of Orthopaedic Surgery, Tohoku Rosai Hospital, 4-3-21 Dainohara, Aoba-ku, Sendai, Miyagi 981-8563, Japan, E-mail: s-nobuta@tohokuh.johas.go.jp

Copyright © 2021 The Japanese Association of Rehabilitation Medicine



This is an open-access article distributed under the terms of the Creative Commons Attribution Non-Commercial No Derivatives (CC BY-NC-ND) 4.0 License. <http://creativecommons.org/licenses/by-nc-nd/4.0/>

**Table 1.** Details and test results for eighteen ulnar tunnel syndrome patients

Case	Age	Sex	Side	Duration of symptoms	Hypesthesia	TPD (mm)	Pinch (kg)	Follow up		
								m	TPD (mm)	Pinch (kg)
1.	34	F	L	7 m	p, d	40	0	6	35	0.3
2.	38	M	R	1 m	p, d	15	0	6	5	2.0
3.	36	M	R	2 m	p, d	20	2.8	6	5	4.5
4.	41	F	R	84 m	none	5	2.5	13	5	3.3
5.	80	F	R	5 m	p, d	45	1.8	17	10	3.2
6.	33	F	R	8 m	p, d	15	2.6	9	7	3.4
7.	76	F	R	2 m	p, d	30	0.8	6	10	3.4
8.	68	M	L	5 m	p, d	30	1.5	8	7	3.5
9.	57	M	R	5 m	p, d	10	2.4	54	7	4.2
10.	44	F	R	24 m	p	15	2.3	7	7	3.5
11.	58	M	R	1 m	p	40	2.8	10	15	4.5
12.	54	F	R	1 m	p	10	4.2	12	5	4.5
13.	61	M	R	5 m	p, d	25	4.2	48	10	4.5
14.	45	F	R	5 m	p	10	2.0	5	5	4.0
15.	56	F	L	3 m	p	5	0.5	7	5	3.6
16.	66	F	L	2 m	none	7	1.3	10	5	4.2
17.	64	M	R	3 m	p	25	4.0	7	20	7.0
18.	56	M	R	1 m	none	5	2.1	6	5	7.4

F, female; M, male; L, left; R, right; m, months; p, palmar side; d, dorsal side; TPD, two-point discrimination; Pinch, pulp pinch strength.

the clinical features of UTS and to investigate the diagnostic value of nerve conduction measurements for UTS.

## PATIENTS AND METHODS

Eighteen hands from 18 patients with UTS treated between May 2008 and July 2016 were reviewed after a mean follow-up of 11 months (range, 5–54 months). Details of the 18 cases are shown in **Table 1**. The ages of the patients (8 men and 10 women) at surgery ranged from 33 to 80 years, with a mean age of 53 years. The right side was affected in 14 patients, and the dominant extremity was involved in 12 patients. The mean duration of symptoms was 9 months (range, 1–84 months). UTS was diagnosed based on clinical symptoms, electrophysiological evaluations, and magnetic resonance imaging (MRI) findings. Written informed consent was obtained from each patient. All patients except for three (cases 12, 13, and 17) had motor weakness and atrophy of the intrinsic muscles with a positive Froment's sign and a claw finger deformity of the little finger. Fifteen patients had numbness and hypesthesia in the ulnar nerve distribution; hypesthesia was seen only on the palmar side in six patients

and on both the palmar and dorsal sides in nine (**Table 1**). A Tinel-like sign at the ulnar tunnel was not seen in any of these patients. The intrinsic muscles included the first dorsal interosseous (FDI) and the abductor digiti minimi (ADM). The results of the static two-point discrimination (TPD) test on the little finger ranged from 5 to 45 mm, with a mean of 19.6 mm. The pulp pinch strength ranged from 0 to 4.2 kg, with a mean of 2.1 kg (**Table 2**). T1-weighted MRI of the wrist in 17 patients demonstrated a soft tissue mass in 5 patients<sup>16)</sup> (cases 12,14–16, and 18), a high-signal area in 8 (cases 1–4, 6, 8, 9, and 17), and normal findings in 4 (cases 5, 7, 10, and 13).

Nerve conduction measurements were performed before and after surgery. The compound muscle action potentials (CMAPs) from the FDI and ADM and the sensory nerve action potential (SNAP) from the little finger were recorded and analyzed. We used a Nicolet Viking electromyography system (Nicolet Instruments, Madison, WI, USA) and a 10-mm silver disc. The palmar skin temperature was not allowed to fall below 32°C. FDI-CMAP and ADM-CMAP were recorded by supramaximal stimulation of the ulnar nerve at the wrist. The stimulus duration was 0.2–0.5 ms. SNAP was

**Table 2.** Overall results before and after surgery for UTS

	Preoperative	Final follow-up	P value
Static TPD test on little finger (mm) (SD)	19.6 (13.0)	9.3 (7.6)	<0.05
Pinch strength (kg) (SD)	2.1 (1.3)	3.9 (1.5)	<0.001
Detection of FDI-CMAP (hands)	17	18	
Latency (ms) (SD)	6.7 (3.6)	4.6 (0.9)	<0.02
Amplitude (mV) (SD)	1.6 (2.6)	3.1 (3.5)	NS
Detection of ADM-CMAP (hands)	16	17	
Latency (ms) (SD)	5.1 (3.1)	3.7 (0.8)	NS
Amplitude (mV) (SD)	1.3 (1.5)	2.8 (2.1)	NS
Detection of SNAP (hands)	8	3	
Latency (ms) (SD)	3.5 (2.3)	3.2 (1.7)	NS
Amplitude ( $\mu$ V) (SD)	9.1 (8.9)	21.0 (23.5)	NS

TPD, two-point discrimination; SD, standard deviation; FDI, first dorsal interosseous muscle; CMAP, compound muscle action potential; ADM, abductor digiti minimi muscle; SNAP, sensory nerve action potential; NS, not significant.

recorded with ring electrodes by minimal stimulation of the ulnar nerve at the wrist. According to the measurements for 20 healthy subjects at our institute, the mean  $\pm$ 2SD indicated the normal values of latency and amplitude. The normal values were: FDI-CMAP latency <4.2 ms with an amplitude >6.6 mV, ADM-CMAP latency <2.9 ms with an amplitude >5.3 mV, and SNAP peak latency <3.5 ms with an amplitude >3.4  $\mu$ V. We diagnosed delayed latency and low amplitude for CMAPs and SNAP based on these criteria. Furthermore, to rule out cubital tunnel syndrome, FDI-CMAP and ADM-CMAP were recorded by stimulating the ulnar nerve at the elbow to confirm no conduction delay at the cubital tunnel.

Surgery was indicated when motor weakness and atrophy of the intrinsic muscles were present or there was severe numbness or pain in the ulnar nerve distribution (cases 12, 13, and 17). All patients underwent ulnar tunnel release by surgical division of the volar carpal ligament and ulnar nerve neurolysis with release of the pisohamate arch (tendinous arch). At surgery, we confirmed the site of the lesion within the ulnar tunnel and classified them into 3 zones.<sup>12)</sup> Zone 1 is the area proximal to the bifurcation of the ulnar nerve, zone 2 encompasses the motor branch of the nerve after bifurcation, and zone 3 surrounds the superficial or sensory branch of the ulnar nerve. As part of the outpatient rehabilitation program, after surgery, patients were instructed to perform the pulp pinch motion exercise under the supervision of a physiotherapist twice a week for 4 weeks. Static TPD test results on the little finger, the pinch strength, and Froment's sign were evaluated after surgery. The presence of complications such as infection, hematoma, and nerve injury were also assessed.

This research passed the Tohoku Rosai Hospital Ethics

Committee review (approval number Tohoku-Rin 20–20). The data were analyzed using Student's *t*-test and the Mann-Whitney U test. P values less than 0.05 were considered statistically significant.

## RESULTS

Before surgery, FDI-CMAP was recorded in 17 patients but was unrecordable in 1, and ADM-CMAP was recorded in 16 patients but was unrecordable in 1 (**Tables 2 and 3**). FDI-CMAP showed delayed latency in 14 patients (mean: 6.7 ms) and low amplitude in 16 (mean: 1.6 mV), whereas ADM-CMAP revealed delayed latency in 14 patients (mean: 5.1 ms) and low amplitude in 16 (mean: 1.3 mV). SNAP was recorded in eight patients and two showed delayed latency. At surgery, the causes of ulnar nerve compression were ganglion in five patients, traumatic adhesion in four, ulnar artery aberrancy (aberrant branch) in four, pisohamate arch in three, anomalous muscle in one, and ulnar vein varix in one. A ganglion rising from the triquetrohamate joint in five patients was traced to its origin and excised. Histologic examination confirmed the diagnosis of ganglion. Traumatic adhesion in four patients was caused by blunt trauma. The pisohamate arch was cut, and the anomalous muscle located at the volar carpal ligament as a palmaris longus muscle was excised. The aberrant ulnar artery branch and the ulnar vein varix were excised. The site of compression was in zone 1 in 12 cases, zone 2 in 2, and zones 1 and 2 in 4, whereas there was no case of compression in zone 3 (**Table 3**). Infection, hematoma, and nerve injury are possible complications of surgery for UTS, but there were no complications in our 18

**Table 3.** Details of causes, zone, and nerve conduction measurements in UTS patients

Case	Cause	Zone	Parameter measurements before / after surgery					
			FDI-CMAP		ADM-CMAP		SNAP	
			Lat. (ms)	Amp. (mV)	Lat. (ms)	Amp. (mV)	Lat. (ms)	Amp. ( $\mu$ V)
1.	ua	1	<u>3.4/2.6</u>	0.9/1.7	<u>2.4/2.6</u>	1.5/2.3		nr
2.	am	1	<u>3.8/4.7</u>	1.0/1.5	3.9/4.6	0.3/5.0	4.2/nr	2.0/nr
3.	uv	1	<u>6.0/3.9</u>	1.3/2.1	6.6/4.5	0.2/2.3	8.9/nr	1/nr
4.	ta	2	<u>3.9/4.0</u>	4.4/2.9	3.0/ <u>2.4</u>	<u>3.8/6.2</u>		nr
5.	ta	1	<u>17.0/3.7</u>	0.05/0.2	ur/3.6	ur/0.5		nr
6.	ua	1	4.5/4.4	3.5/6.5		nr	<u>2.0/nr</u>	<u>5.0/nr</u>
7.	ua	1	ur/6.3	ur/0.5	12.7/4.1	0.1/0.6		nr
8.	pa	1, 2	6.5/5.1	0.1/1.3	3.1/3.2	0.6/0.4		nr
9.	pa	1, 2	7.5/5.7	0.5/0.6	3.5/5.4	0.6/1.0		nr
10.	pa	1, 2	5.1/4.2	0.7/0.7	4.9/3.7	0.3/1.2		nr
11.	ta	1	10.3/6.1	0.1/1.5	6.2/4.2	0.1/4.1	<u>3.1/5.0</u>	2.0/ <u>5.0</u>
12.	gl	1	5.6/5.0	<u>10.7/10.3</u>	6.0/4.1	2.1/1.8	<u>2.5/1.7</u>	<u>25/48</u>
13.	ta	1	5.2/4.7	0.8/0.9	3.8/3.1	5.0/3.3		nr
14.	gl	1, 2	12.6/5.3	0.1/4.0	11.8/3.9	0.2/4.4	<u>2.6/2.8</u>	<u>10/10</u>
15.	gl	2	6.5/4.9	0.6/ <u>6.8</u>	3.1/3.1	3.6/ <u>5.6</u>		nr
16.	gl	1	4.4/ <u>3.7</u>	0.1/0.8	3.5/2.9	0.5/0.4	<u>2.0/nr</u>	<u>8.0/nr</u>
17.	ua	1	4.8/ <u>3.7</u>	1.3/1.1	4.5/4.5	0.7/1.7		nr
18.	gl	1	6.4/4.2	1.5/ <u>12.2</u>	<u>2.6/2.7</u>	0.5/6.6	<u>2.6/nr</u>	<u>20/nr</u>

Underlined data are within the normal range.

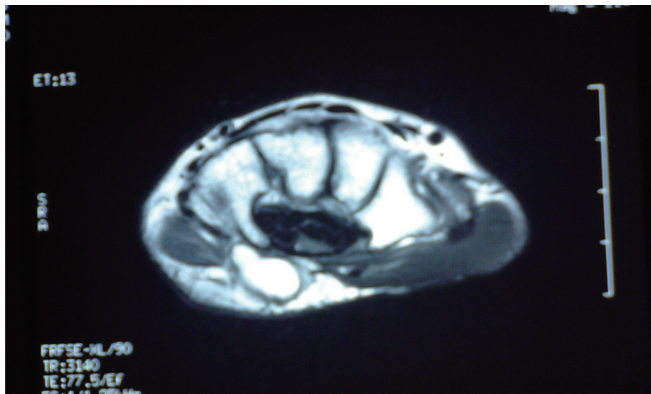
ua, ulnar artery aberrancy; am, anomalous muscle; uv, ulnar vein varix; ta, traumatic adhesion; pa, pisohamate arch; gl, ganglion; Lat., latency; Amp., amplitude; nr, normal range.

patients.

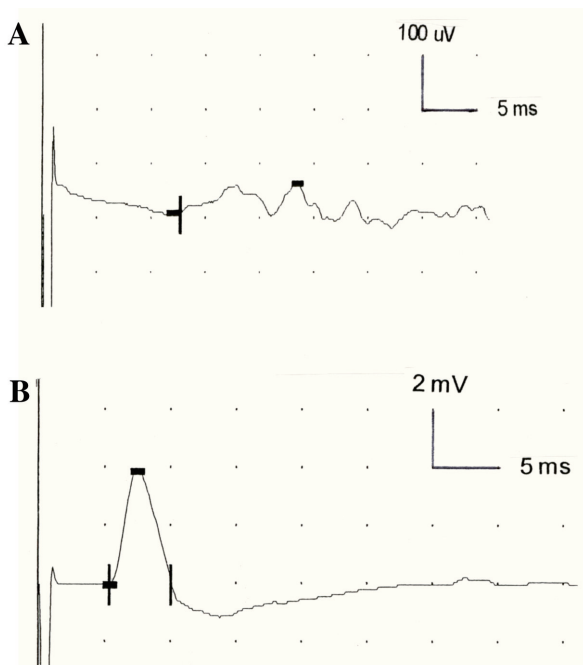
After surgery, all patients recovered motor function and sensation. The mean TPD improved from 19.6 to 9.3 mm ( $P < 0.05$ ), and the mean pinch strength increased from 2.1 to 3.9 kg at final follow-up ( $P < 0.001$ , **Table 3**). As a result of rehabilitation, the mean pinch strength increased to 3.1 kg (SD 1.4) at 2 months after surgery ( $P < 0.05$ ). Except for cases 1 and 17, patients showed a negative Froment's sign at the final follow-up. Evaluation of postoperative FDI-CMAP showed a shortening of latency (mean: 4.6 ms,  $P < 0.02$ ) and an increase in amplitude (mean: 3.1 mV). Postoperative ADM-CMAP also revealed a shortening of latency (mean: 3.7 ms) and an increase of amplitude (mean: 2.8 mV). FDI-CMAP latency recovered to the normal range in six patients and the amplitude recovered in three, whereas ADM-CMAP latency improved to the normal range in three patients and the amplitude recovered in two (**Tables 2 and 3**). In almost all cases, residual delayed latency and low amplitude were seen at the final follow-up.

### Case Presentation

A 45-year-old right-hand-dominant woman (case 14) presented with a 5-month history of onset and intrinsic weakness of her right hand. The right hand showed intrinsic muscle atrophy and weakness with a positive Froment's sign and clawing of the little finger. Mild numbness and hypesthesia were evident in the little finger and ring finger. TPD was 10 mm, and the pinch strength was 2.0 kg. Axial T1-weighted MRI showed a cystic mass lesion at the ulnar tunnel (**Fig. 1**). FDI-CMAP exhibited markedly delayed latency and low amplitude (**Fig. 2A**), and ADM-CMAP also showed delayed latency and low amplitude (**Fig. 3A**). In contrast, SNAP indicated normal latency and amplitude (**Fig. 4**). Intra-operatively, after division of the volar carpal ligament, a 22/14/10 mm ganglion was found to be mainly compressing the motor branch of the ulnar nerve in zones 1 and 2 (**Fig. 5A**). The ganglion, which arose from the triquetrohamate joint (**Fig. 5B**), was excised, and histology confirmed the diagnosis (**Fig. 6**). Five months after surgery, motor function and sensation had recovered and the patient had a pinch strength of 4.0 kg and a TPD of 5 mm; FDI-



**Fig. 1.** Axial T1-weighted MRI showed a cystic mass lesion at the ulnar tunnel (arrow) in case 14.

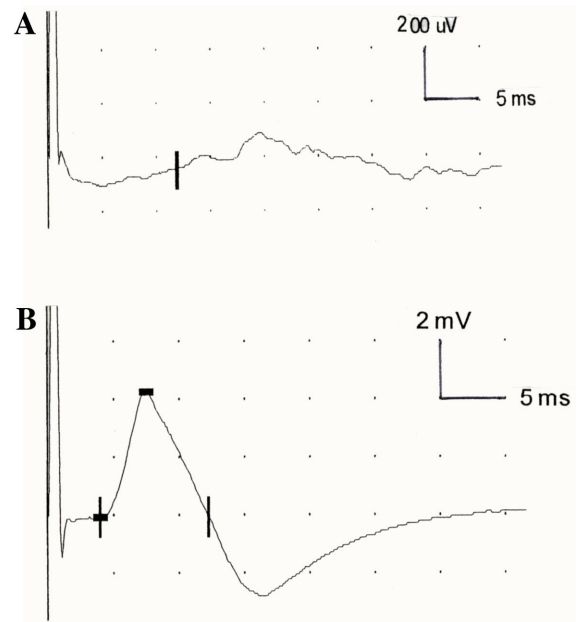


**Fig. 2.** FDI data for case 14. (A) Preoperatively, FDI-CMAP latency was 12.6 ms with an amplitude of 0.1 mV. (B) Five months after surgery, latency was 5.3 ms with an amplitude of 4.0 mV.

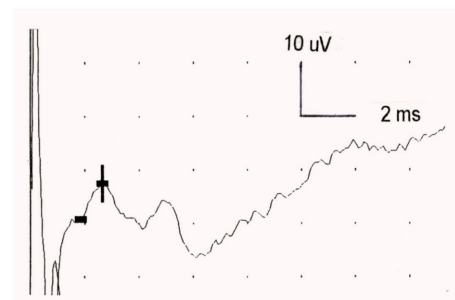
CMAP and ADM-CMAP revealed a shortened latency and an increased amplitude (Figs. 2B, 3B).

### DISCUSSION

The ulnar tunnel is anatomically classified into three zones<sup>12</sup>: zone 1 is the area proximal to the bifurcation of the ulnar nerve, zone 2 encompasses the motor branch of the ulnar nerve (except the branch to the ADM) after it has

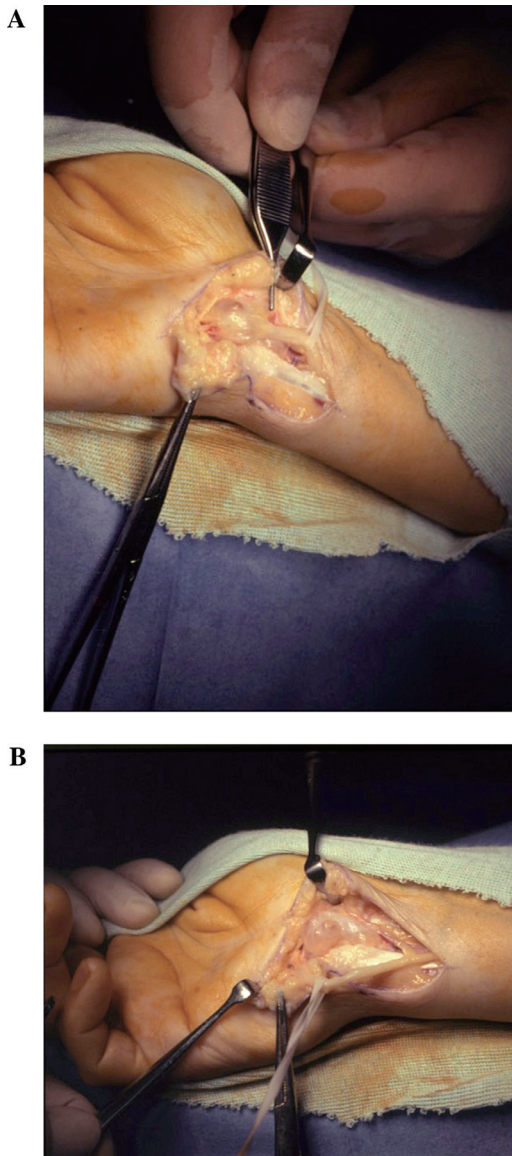


**Fig. 3.** ADM data for case 14. (A) Preoperatively, ADM-CMAP latency was 11.8 ms with an amplitude of 0.1 mV. (B) Five months after surgery, latency was 3.9 ms with an amplitude of 4.4 mV.



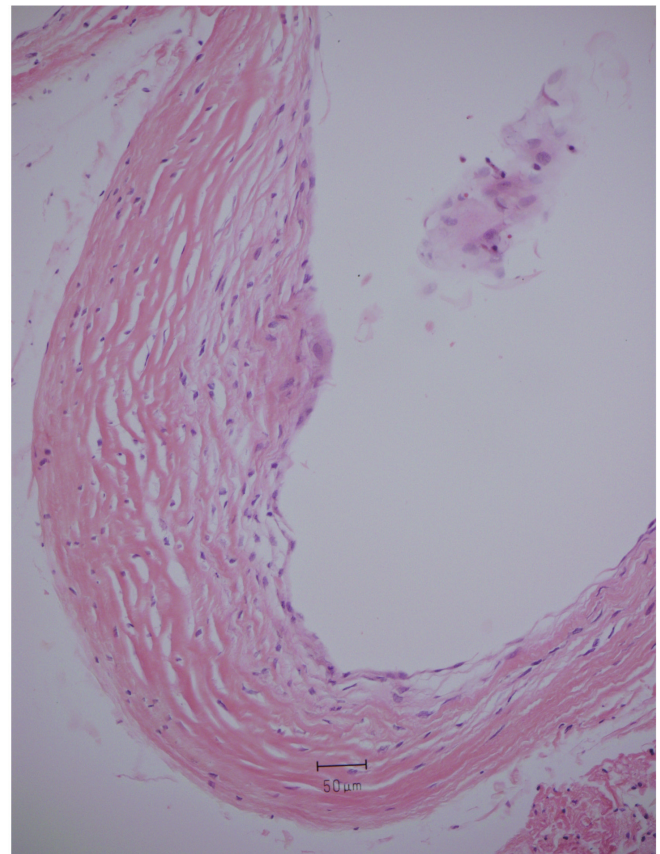
**Fig. 4.** SNAP data for case 14 showed normal latency (2.6 ms) and amplitude (8  $\mu$ V).

bifurcated, and zone 3 surrounds the superficial or sensory branch of the ulnar nerve. Depending on the site of compression, clinically, the lesion may be in the motor, sensory, or mixed branch,<sup>15</sup> whereas the sensory branch on the dorsal ulnar side is normal in UTS.<sup>4</sup> However, if paresthesia is seen on the dorsal ulnar side of the hand, the likely lesion site is the cubital tunnel.<sup>4</sup> In our series, compression involved zone 1 in 16 cases (89%; 12 cases in zone 1 only and 4 cases in zones 1 and 2) and zone 2 in 6 cases (2 cases in zone 2 only and 4 cases in zones 1 and 2). For the two cases with compression in zone 2 only, case 4 showed no sensory loss and case 15 showed palmar side hypesthesia. Hypesthesia



**Fig. 5.** (A) Intraoperative photograph of a ganglion which was mainly compressing the motor branch of the ulnar nerve at zones 1 and 2 (arrow) in case 14. (B) The ganglion arose from triquetrohamate joint.

was seen only on the palmar side in six patients, and both on the palmar and dorsal sides in nine patients. These heterogeneous findings underline the fact that an exact clinical diagnosis of UTS and detection of the location of the lesion are often difficult. A possible explanation for the nine patients who had hypesthesia both on the palmar and dorsal sides is the presence of an aberrant dorsal sensory branch of the ulnar nerve which diverged with the palmar sensory branch in the ulnar tunnel. Murata et al.<sup>3)</sup> reported that 90% of cases with UTS were in zone 1. A previous report stated



**Fig. 6.** Photomicrograph (hematoxylin-eosin stain, original magnification  $\times 20$ ) showing the ganglion cyst with a thick-walled cystic space and focal myxoid change in the surrounding matrix in case 14.

that ulnar nerve lesion in zones 1 and 2 are likely caused by ganglions or fractures of the hamate, and that lesions in zone 3 are caused by vascular lesions resulting from thrombosis or aneurysm.<sup>12)</sup> However, in our series, the causes of zone 1 lesions were ganglions, ulnar artery aberrancy, traumatic adhesion, anomalous muscle, and ulnar vein varix. Murata et al.<sup>3)</sup> stated that surgical exploration is the only reliable way to clarify the site of compression.

The expected theoretical symptoms of compressions in the three anatomical zones are: zone 1 lesions – delayed ADM latency and FDI latency and diminished SNAP amplitude; zone 2 compression – delayed FDI latency according to the site of compression, although ADM latency may be normal; and zone 3 lesions – diminished SNAP amplitude and normal ADM-CMAP and FDI-CMAP.<sup>4)</sup> In our series of 18 cases, there were 16 cases of zone 1 compression; of these, 14 showed delayed FDI latency, 15 showed low FDI amplitude, 14 had delayed ADM latency, and 14 had low ADM

amplitude. Of the eight patients who underwent SNAP, the results were normal in six (**Table 3**). Consequently, both FDI-CMAP and ADM-CMAP were valuable for a definite electrodiagnosis of UTS; however, SNAP was not useful for confirming the diagnosis. Cases 12, 13, and 17 showed adequate pinch strengths (4.2, 4.2, and 4.0 kg, respectively), but cases 13 and 17 had low FDI-CMAP amplitudes. These two cases originally had adequate pinch strengths on the normal side (5.4 and 5.2 kg, respectively); therefore, the decrease in pinch strength before surgery and rehabilitation was small. Surgery was indicated for these cases with severe numbness and pain in the ulnar nerve distribution.

Lumbrical-interossei motor studies<sup>21</sup> and short segment incremental studies (SSIS, inching method) of FDI-CMAP have been reported and indicated that SSIS was valuable for diagnosis of the precise localization of UTS.<sup>22–25</sup> Nevertheless, SSIS is somewhat time-consuming and technically difficult,<sup>24</sup> particularly stimulating a site on the palmar side. Accordingly, we performed traditional nerve conduction measurements of CMAPs and SNAP. Murata et al.<sup>3</sup> reported normal values for ADM-CMAP latency of <3.5 ms with an amplitude >2.5 mV, and a SNAP latency of <2.2 ms with an amplitude >15  $\mu$ V. In the current series, based on our criteria, we identified delayed latencies and low amplitudes for CMAPs and SNAPs.

Nerve conduction measurements for UTS have been reported,<sup>2,3,10,11,13–16</sup> and they all indicated delayed conduction at the wrist. However, few studies have examined nerve conduction before and after surgery.<sup>2,11,14</sup> Uriburu et al.<sup>11</sup> reported three cases of UTS and found that FDI-CMAP was recordable in one case after surgery. Moreover, postoperatively, FDI latency was shortened from 7 to 4 ms in one patient and from 24 to 4 ms in another. Ebeling et al.<sup>2</sup> described nine cases of UTS and found that FDI latency was shortened postoperatively. Erkin et al.<sup>14</sup> reported a patient with a ganglion and found that the FDI latency was shortened from 3.5 to 3.2 ms and the FDI amplitude increased from 2.1 to 5.4 mV postoperatively. Inaparthi et al.<sup>15</sup> reported that the time for hypothenar muscles to recover to the normal range was 12 to 14 weeks in their patients. In our series of 18 patients, after rehabilitation, the mean pinch strength increased from 2.1 to 3.1 kg at 2 months after surgery. In a previous report, we described five cases of UTS caused by ganglion and found that both FDI-CMAP and ADM-CMAP were valuable for electrophysiological diagnosis<sup>16</sup>; however, the current study describes 18 cases of UTS with various causes, including ganglion, and the results were incidentally similar to those of the past report. In our current series, FDI-CMAP

and ADM-CMAP did not improve to the normal range, and residual delayed latency and low amplitude were seen despite recovery of the intrinsic muscles (**Tables 2 and 3**). In these cases, from the viewpoint of neurophysiology, myelination and axonal regeneration of fibers in the FDI and ADM branches were insufficient, notwithstanding a mean follow-up of 11 months.

There were several limitations to this study. First, we did not investigate the relationship between MRI findings and the causes of UTS. Second, we could not clarify the relationship between the electrophysiological data and the recovery time for intrinsic muscles. Third, to detect further improvement of FDI-CMAP and ADM-CMAP, longer follow-up is needed.

## CONCLUSIONS

The causes of UTS in our series were ganglion, traumatic adhesion, ulnar artery aberrancy, or pisohamate arch. Both FDI-CMAP and ADM-CMAP were valuable for electrophysiological diagnosis of UTS. Delayed latency and low amplitudes were seen at the final follow-up despite the recovery of intrinsic muscles.

## ACKNOWLEDGMENTS

The authors are grateful to Ms. Yumi Watabe, Ms. Hiromi Takeda, Ms. Yoko Kusakari, Pathologist Noriyuki Iwama, MD, Fumie Nakayama, MD, and Honorary Director Katsumi Sato, MD, Tohoku Rosai Hospital, for assisting in the manuscript preparation.

## CONFLICTS OF INTEREST

The authors declare that there are no conflicts of interest.

## REFERENCES

1. Shea JD, McClain EJ: Ulnar-nerve compression syndromes at and below the wrist. *J Bone Joint Surg Am* 1969;51:1095–1103. DOI:10.2106/00004623-196951060-00004, PMID:5805411
2. Ebeling P, Gilliatt RW, Thomas PK: A clinical and electrical study of ulnar nerve lesions in the hand. *J Neurosurg Psychiatry* 1960;23:1–9. DOI:10.1136/jnnp.23.1.1, PMID:13819155

3. Murata K, Shih JT, Tsai TM: Causes of ulnar tunnel syndrome: a retrospective study of 31 subjects. *J Hand Surg Am* 2003;28:647–651. DOI:10.1016/S0363-5023(03)00147-3, PMID:12877855
4. Chen SH, Tsai TM: Ulnar tunnel syndrome. *J Hand Surg Am* 2014;39:571–579. DOI:10.1016/j.jhsa.2013.08.102, PMID:24559635
5. Seddon HJ: Carpal ganglion as a cause of paralysis of the deep branch of the ulnar nerve. *J Bone Joint Surg Br* 1952;34-B:386–390. DOI:10.1302/0301-620X.34B3.386, PMID:12999919
6. Richmond DA: Carpal ganglion with ulnar nerve compression. *J Bone Joint Surg Br* 1963;45-B:513–515. DOI:10.1302/0301-620X.45B3.513, PMID:14058327
7. Dupont C, Cloutier G, Prévost Y, Dion MA: Ulnar-tunnel syndrome at the wrist. *J Bone Joint Surg Am* 1965;47:757–761. DOI:10.2106/00004623-196547040-00010, PMID:14299666
8. Vanderpool DW, Chalmers J, Lamb DW, Whiston TB: Peripheral compression lesions of the ulnar nerve. *J Bone Joint Surg Br* 1968;50-B:792–803. DOI:10.1302/0301-620X.50B4.792, PMID:4303276
9. Hayes JR, Mulholland RC, O'Connor BT: Compression of the deep palmar branch of the ulnar nerve. Case report and anatomical study. *J Bone Joint Surg Br* 1969;51-B:469–472. DOI:10.1302/0301-620X.51B3.469, PMID:5820788
10. Kleinert H, Hayes JE: The ulnar tunnel syndrome. *Plast Reconstr Surg* 1971;47:21–24. DOI:10.1097/00006534-197101000-00005, PMID:4320782
11. Uriburu IJ, Morchio FJ, Marin JC: Compression syndrome of the deep motor branch of the ulnar nerve. (Piso-Hamate Hiatus syndrome). *J Bone Joint Surg Am* 1976;58:145–147. DOI:10.2106/00004623-197658010-00032, PMID:1249106
12. Gross MS, Gelberman RH: The anatomy of the distal ulnar tunnel. *Clin Orthop Relat Res* 1985;238–247. DOI:10.1097/00003086-198506000-00033, PMID:3995823
13. Kuschner SH, Gelberman RH, Jennings C: Ulnar nerve compression at the wrist. *J Hand Surg Am* 1988;13:577–580. DOI:10.1016/S0363-5023(88)80100-X, PMID:3418064
14. Erkin G, Uysal H, Keleş I, Aybay C, Özel S: Acute ulnar neuropathy at the wrist: a case report and review of the literature. *Rheumatol Int* 2006;27:191–196. DOI:10.1007/s00296-006-0166-8, PMID:16896989
15. Inaparthi PK, Anwar F, Botchu R, Jähnich H, Katchburiar MV: Compression of the deep branch of the ulnar nerve in Guyon's canal by a ganglion: two cases. *Arch Orthop Trauma Surg* 2008;128:641–643. DOI:10.1007/s00402-008-0636-4, PMID:18509691
16. Nobuta S, Sonofuchi K, Itoi E: Electrophysiological features of ulnar tunnel syndrome caused by ganglion – a descriptive study. *Int J Phys Med Rehabil* 2018;06:496. DOI:10.4172/2329-9096.1000494
17. Hirooka T, Hashizume H, Nagoshi M, Shigeyama Y, Inoue H: Guyon's canal syndrome. A different clinical presentation caused by an atypical fibrous band. *J Hand Surg Am* 1997;22:52–53. DOI:10.1016/S0266-7681(97)80016-2, PMID:9061525
18. Spinner RJ, Lins RE, Spinner M: Compression of the medial half of the deep branch of the ulnar nerve by an anomalous origin of the flexor digiti minimi. A case report. *J Bone Joint Surg Am* 1996;78:427–430. DOI:10.2106/00004623-199603000-00015, PMID:8613451
19. Guyon F: Note sur une disposition anatomique propre a la face anterieure de la region du poignet et non encore decrite. *Bull Soc Anat Paris* 1861;6:184–186.
20. Hunt JR: Occupation neuritis of the deep palmar branch of the ulnar nerve. *J OF Nerv Ment Dis* 1908;35:673–689. DOI:10.1097/00005053-190811000-00001
21. Kothari MJ, Preston DC, Logigian EL: Lumbrical-interossei motor studies localize ulnar neuropathy at the wrist. *Muscle Nerve* 1996;19:170–174. DOI:10.1002/(SICI)1097-4598(199602)19:2<170::AID-MUS7>3.0.CO;2-B, PMID:8559165
22. Hatori M, Sakurai M, Miyasaka Y, Nobuta S: Electrodiagnosis of ulnar tunnel syndrome by inching technique. *J Jpn Soc Surg Hand* 1989;6:346–350.
23. McIntosh KA, Preston DC, Logigian EL: Short-segment incremental studies to localize ulnar nerve entrapment at the wrist. *Neurology* 1998;50:303–306. DOI:10.1212/WNL.50.1.303, PMID:9443503
24. Cowdery SR, Preston DC, Herrmann DN, Logigian EL: Electrodiagnosis of ulnar neuropathy at the wrist: conduction block versus traditional tests. *Neurology* 2002;59:420–427. DOI:10.1212/WNL.59.3.420, PMID:12177377
25. Seror P: Electrophysiological pattern of 53 cases of ulnar nerve lesion at the wrist. *Neurophysiol Clin* 2013;43:95–103. DOI:10.1016/j.neucli.2012.11.037, PMID:23540258