

# Pleural effusion resulting from bronchial tuberculosis

## A case report

Xuchun Liu, MD<sup>a,\*</sup>, Litao Xu, BMed<sup>a</sup>, Guohua Jiang, BMed<sup>a</sup>, Shubin Huang, MM<sup>b</sup>

### Abstract

**Rationale:** The clinical manifestations in patients with bronchial tuberculosis (BTB) are nonspecific and may pose a great diagnostic challenge.

**Patient concerns:** Here we describe the case of a 57-year-old man presented with right chest pain, chest tightness, and discomfort for 2 days.

**Diagnosis:** Bronchoscopic biopsy was performed which revealed subepithelial and epithelioid cell granuloma of Langerhans cell structure. The definitive diagnosis was BTB with pleural effusion.

**Interventions:** Treatment with a quadruple combinational antituberculous therapy was initiated.

**Outcomes:** Two months later, the patient's chest distress and discomfort significantly decreased. Repeat chest radiograph revealed that the pleural fluid had been absorbed. The patient recovered after 15 months of antituberculosis treatment.

**Lessons:** The patient exemplifies the difficulty of diagnosing BTB, particularly the low reliability of imaging modalities. The diagnosis of BTB currently relies on bronchoscopy as well as bacteriological or pathological evidence. This report will help to lower the incidences of misdiagnosis of this disease.

**Abbreviations:** ADA = adenosine deaminase, BTB = bronchial tuberculosis, CRP = C-reactive protein, CT = computed tomography, MTB = mycobacterium tuberculosis, TB = tuberculosis.

**Keywords:** bronchial tuberculosis, imaging, misdiagnosis, pleural effusions

## 1. Introduction

Tuberculosis (TB) is a disease of poverty, affecting the most vulnerable groups of the world's population: more than half of TB-related deaths occur in Asia, while the greatest TB burden as percentage of population is in Africa.<sup>[1]</sup> Bronchial tuberculosis (BTB) is a particular clinical type of this disease that falls within the category of lower respiratory tract TB. The clinical manifestations in patients with BTB are nonspecific, and imaging examinations are sometimes of limited diagnostic use.<sup>[2]</sup> Pleural effusion is not commonly the primary clinical manifestation in patients with BTB; moreover, pleural fluid tests lack specificity and can readily lead to misdiagnosis or missed diagnosis.<sup>[3,4]</sup> The

patient we report here sought medical attention due to chest pain, chest tightness, and discomfort, and was found to have pleural effusion detected via a chest computed tomography (CT) scan. He was initially misdiagnosed with inflammatory pleural effusion, which resulted in prolonging his condition. Finally, a definite diagnosis of BTB was made following tracheoscopy. After aggressive anti-TB treatment, the pleural effusion was absorbed and the symptoms improved.

## 2. Case report

The 57-year-old man, a farmer living in a rural area of Chizhou, Anhui Province, China, was admitted to our hospital after experiencing right chest pain, chest tightness, and discomfort for 2 days. Auscultation revealed reduced breath sounds in the lower lobe of the right lung. A routine blood routine revealed the following: white blood cell count,  $5.57 \times 10^9/L$ ; neutrophils, 75.91%, lymphocytes, 12.62%; red blood cell count,  $4.47 \times 10^{12}/L$ ; hemoglobin, 123 g/L; platelets,  $227 \times 10^9/L$ ; erythrocyte sedimentation rate, 46 mm/h; and C-reactive protein (CRP), 54.64 mg/L. The plasma D-dimer level was 2168 ng/mL; tumor markers and autoimmune antibodies were normal. The patient was negative for *Mycoplasma pneumoniae*; the T-SPOT T-cell test for TB infection as well as purified protein derivative tests for TB were also negative, as were repeated sputum analyses for acid-fast bacilli.

Chest CT revealed atelectasis of the lower lobes of the right lung, right-sided pleural effusion, and enlarged lymph nodes in the mediastinum (Fig. 1). Upon the patient's request, a pleural biopsy was not performed. However, a paracentesis was performed on the right thoracic cavity and a routine pleural

Editor: N/A.

Ethical approval: This study was approved by the Ethics Committee of Chizhou People's Hospital.

The authors have no conflicts of interest to disclose.

<sup>a</sup> Department of Respiratory Medicine, Chizhou People's Hospital, <sup>b</sup> Department of Pathology, Chizhou People's Hospital, Chizhou, Anhui, China.

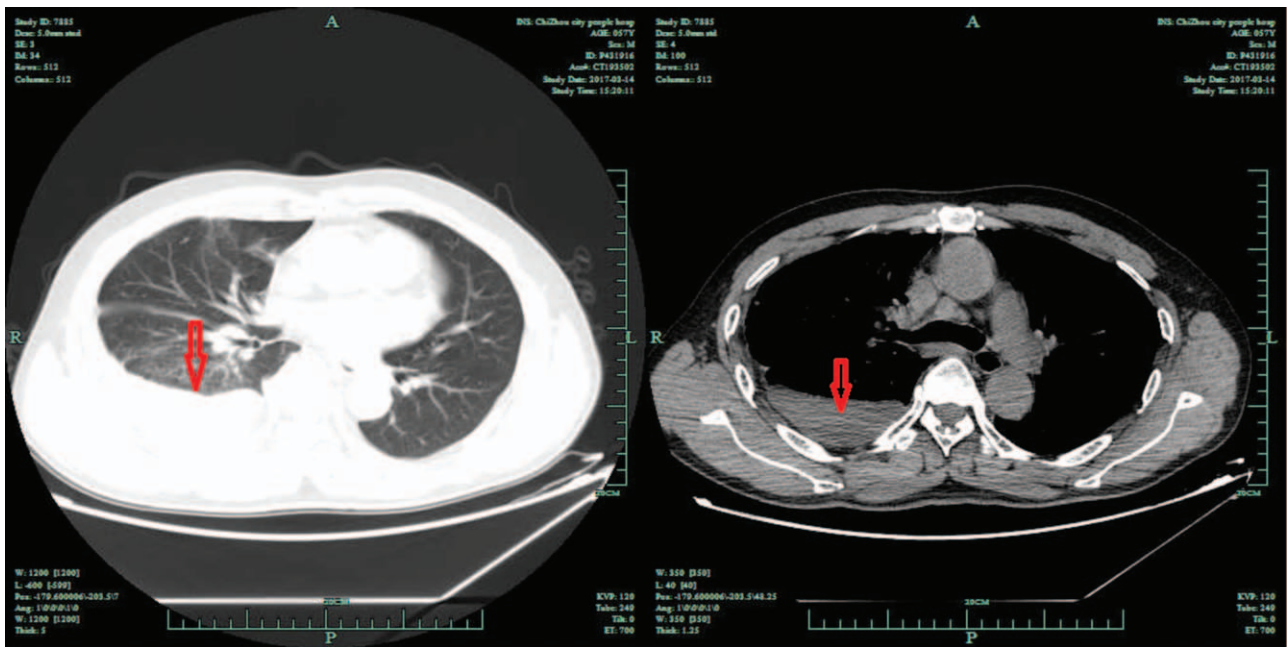
\* Correspondence: Xuchun Liu, Chizhou People's Hospital, Chizhou, Anhui, China (e-mail: liuxu0832@sina.com).

Copyright © 2018 the Author(s). Published by Wolters Kluwer Health, Inc. This is an open access article distributed under the terms of the Creative Commons Attribution-Non Commercial-No Derivatives License 4.0 (CCBY-NC-ND), where it is permissible to download and share the work provided it is properly cited. The work cannot be changed in any way or used commercially without permission from the journal.

Medicine (2018) 97:40(e12713)

Received: 24 May 2018 / Accepted: 10 September 2018

<http://dx.doi.org/10.1097/MD.00000000000012713>

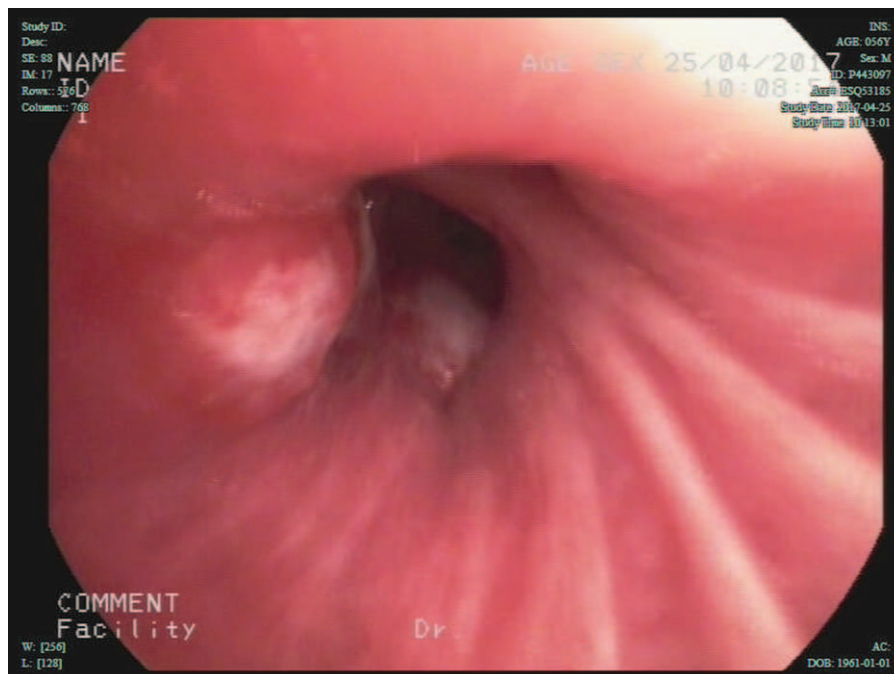


**Figure 1.** Chest computed tomography. Atelectasis of the lower lobes of the right lung is observed, along with right-sided pleural effusion and enlarged lymph nodes in the mediastinum.

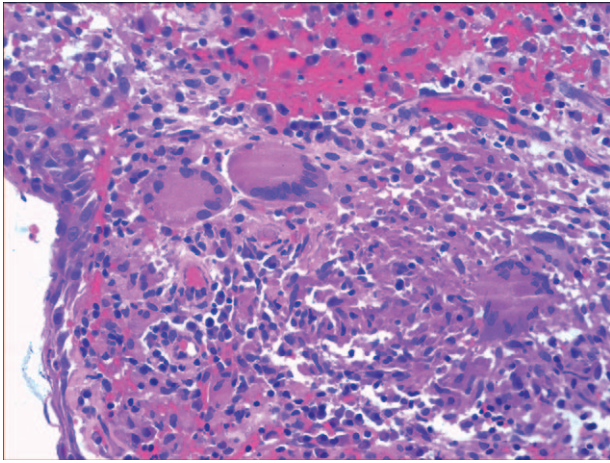
fluid test was conducted. Rivalta test was positive. The pleural fluid pH was 7.32 (reference: 6.8–7.6), while the lactate dehydrogenase level was 285 U/L (reference: 0–200 U/L). The adenosine deaminase (ADA) level was 25 U/L (reference: 0–40 U/L), and carcinoembryonic antigen level was 1.03 ng/mL (reference: 0–6.5 ng/mL). Pleural fluid TB antibodies were negative, and a retest of the pleural fluid showed an ADA level of 23 U/L. Repeated pleural fluid cytological examinations showed a

distribution of lymphocytes and neutrophils, and the pleural fluid culture was negative. The patient was thus diagnosed with inflammatory pleural effusion.

After admission, 0.2% levofloxacin (300 mL intravenously, qd) was administered as an antiinflammatory therapy for 2 weeks, after which a repeat test showed normal CRP levels and a significantly decreased pleural fluid volume. The patient was then discharged. During a follow-up visit 1 month later, the



**Figure 2.** Bronchoscopy results. Granulomatous protruding neoplasm(s) and partial blockage of the lumen in the right main bronchus are observed.



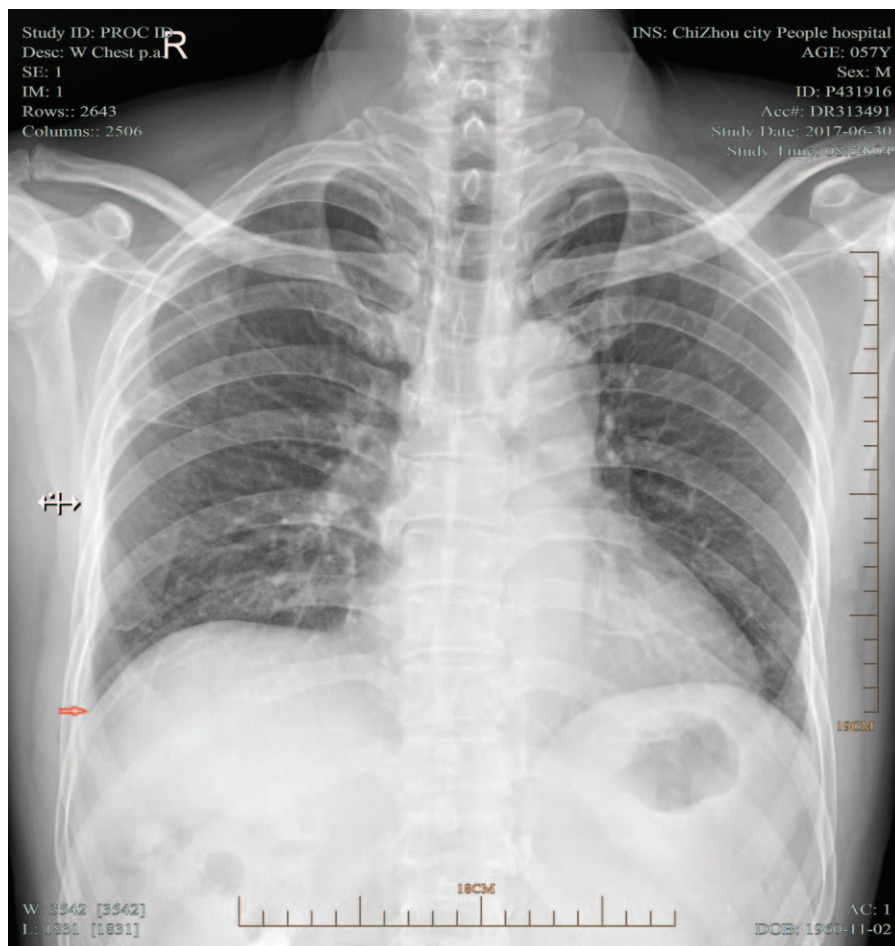
**Figure 3.** Pathological examination of the upper lobe of the right lung. The bronchial surface epithelial metaplasia, subepithelial and epithelioid cell granuloma of Langerhans cell structure, which was considered to be tuberculosis (hematoxylin and eosin staining; magnification  $\times 400$ ).

patient reported a recurrence of chest discomfort. A repeat chest CT revealed encapsulated effusion and mild pleural thickening in the right thoracic cavity. Further bronchoscopy revealed granulomatous protruding neoplasms and partial blockage of the

lumen (Fig. 2). Pathological examination of the biopsy sample from the upper lobe of the right lung revealed the bronchial surface epithelial metaplasia, subepithelial and epithelioid cell granuloma of Langerhans cell structure, which was considered to be TB (Fig. 3). The diagnosis was amended to right-sided BTB with pleural effusion. A quadruple combination antituberculous therapy consisting of rifampicin 0.45g qd, isoniazid 0.3g qd, ethambutol 0.75g qd, and pyrazinamide 0.5g tid was administered orally. Two months later, the patient's chest distress and discomfort significantly improved. Repeat chest radiograph revealed that the pleural fluid had been absorbed (Fig. 4). The patient recovered after 15 months of anti-TB treatment.

### 3. Discussion

BTB refers to TB occurring in the mucosa, submucosa, smooth muscle, cartilage, and epithelium of the bronchus.<sup>[5]</sup> The detection rate of BTB has significantly increased in the recent years.<sup>[6]</sup> Data show that 5% to 10% of patients have no tuberculous lesions in their lungs; they only experience invasion of their trachea and bronchi. BTB mostly occurs in young and middle-aged women, with a male-to-female ratio of 1:2–1:3.<sup>[7,8]</sup> As bronchoscopy is an invasive procedure and not routine, it is difficult to perform an epidemiological investigation of BTB; however, the pulmonary function impairment caused by BTB has become a problem that cannot be overlooked.



**Figure 4.** Chest radiograph. The pleural fluid had been absorbed. Informed written consent was obtained from the patient for publication of this case report and accompanying images.



As the clinical manifestations in patients with BTB often lack specificity, and since imaging examinations have inherent limitations, the diagnosis of BTB currently relies on bronchoscopy as well as bacteriological or pathological evidence.<sup>[9]</sup> The screening of patients who seek medical attention after they experience relevant symptoms is currently the main approach for detecting BTB. Typical clinical manifestations include an irritative cough, expectoration, hemoptysis, dyspnea, and other respiratory symptoms.<sup>[10]</sup> Some patients may experience systemic symptoms such as fever, night sweats, weight loss, and irregular menstruation. Patients may also experience allergic reactions such as reactive arthritis and conjunctivitis. A small portion of patients will have slight or no discomfort, and BTB will be found during auxiliary examinations for pulmonary TB or other diseases. Due to the lack of specificity or even the absence of clinical manifestations in patients with BTB, definite diagnoses cannot be made based on signs and symptoms alone.<sup>[9]</sup> Imaging studies not only assess whether a bronchoscopy is necessary for clinical diagnosis, but can also provide an important reference for the establishment of an intratracheal intervention plan after diagnosis. However, this is associated with high rates of misdiagnosis and missed diagnosis.<sup>[11]</sup> Positive results of sputum smear and mycobacterium tuberculosis (MTB) tests are the gold standards for the diagnosis of TB. For patients without tuberculous lesions in their lungs, a positive sputum bacteria test is highly suggestive of BTB, but further examinations are still required to arrive at definite diagnoses. A negative sputum bacteria test cannot exclude the presence of BTB, especially in patients with typical clinical manifestations of TB. The low positive rate of sputum acid-fast bacilli in patients with BTB,<sup>[12]</sup> together with the long incubation periods of MTB and over-reliance on the sputum bacteria test, often delay the diagnosis of BTB or lead to misdiagnosis or missed diagnosis. Therefore, bronchoscopy should be performed as early as possible.

Bronchoscopy is an indispensable approach for the definitive diagnosis of BTB. Direct observation is accomplished through a bronchoscope, samples such as relevant smears and lavage fluids are obtained for MTB-related examinations, and biopsy samples are obtained for pathological and other examinations in order to confirm the diagnosis of BTB.<sup>[13]</sup> By using bronchoscopy, lesions in the bronchi can be observed directly; their types, locations, scopes, severities, and etiologies can thus be determined, and the occurrences and degrees of airway stenosis, occlusion, and softening can be assessed. Bronchial lesion tissue samples can be obtained through bronchoscopy to test for histopathological manifestations such as exudation, hyperplasia, and degeneration. Detection of epithelioid cells, Langhans giant cells, and caseous necrosis can assist in the diagnosis of BTB, while detection of acid-fast bacilli supports this diagnosis as well.<sup>[14]</sup>

The incidence of pleural effusion in BTB is low and rarely reported clinically, so we cannot reach any conclusion regarding the likelihood that BTB patients might have pleural effusion.<sup>[4,15]</sup> In the present case, the patient had an exudate. The mechanism of its occurrence remains unclear, and it is possible that the disease itself may lead to pleural disruption, thus causing exudative pleurisy; however, there is a lack of histological evidence to support this concept. Pleural biopsies can easily miss the location

of the lesion, since they can only collect a relatively small amount of the sample, and they may be prone to false negative results.<sup>[16]</sup> The mechanism of pleural effusion in BTB patients still need to be further investigated.<sup>[6,17]</sup>

In conclusion, our patient exemplifies the fact that the clinical manifestations of BTB lack specificity, and imaging examinations are limited in their diagnostic utility. We presented a patient with BTB who exhibited pleural effusion that was diagnosed by tracheoscopy, and was successfully treated with anti-TB agents. This case ought to improve clinicians' understanding of this disease and therefore reduce the likelihood of misdiagnosis.

## Author contributions

**Investigation:** Xuchun Liu, Litao Xu.

**Resources:** Xuchun Liu, Litao Xu.

**Validation:** Guohua Jiang, Shubin Huang.

**Writing—original draft:** Xuchun Liu.

**Writing—review & editing:** Xuchun Liu, Guohua Jiang, Shubin Huang.

## References

- Casali L, Crapa ME. Women, immigration, poverty and tuberculosis. *Multidiscip Resp Med* 2010;5:398–400.
- Casali L, Crapa ME. Endobronchial tuberculosis: a peculiar feature of TB often underdiagnosed. *Multidiscip Resp Med* 2012;7:35.
- Siow WT, Lee P. Tracheobronchial tuberculosis: a clinical review. *J Thorac Dis* 2017;9:E71–7.
- Villena Garrido V, Cases Viedma E, Fernández Villar A, et al. Recommendations of diagnosis and treatment of pleural effusion. Update. *Arch Bronconeumol* 2014;50:235–49.
- Pathak V, Shepherd RW, Shojaee S. Tracheobronchial tuberculosis. *J Thorac Dis* 2016;8:3818–25.
- Kashyap S, Solanki A. Challenges in endobronchial tuberculosis: from diagnosis to management. *Pulm Med* 2014;2014:594806.
- Chung HS, Lee JH. Bronchoscopic assessment of the evolution of endobronchial tuberculosis. *Chest* 2000;117:385–92.
- Jung SS, Park HS, Kim JO, et al. Incidence and clinical predictors of endobronchial tuberculosis in patients with pulmonary tuberculosis. *Respirology* 2015;20:488–95.
- Shahzad T, Irfan M. Endobronchial tuberculosis—a review. *J Thorac Dis* 2016;8:3797–802.
- Ahmadi Hoseini SH, Ghalenavi E, Amini M. Clinical and para-clinical presentations of endobronchial tuberculosis. *J Cardiothorac Med* 2015;3:371–4.
- Lee JY, Yi CA, Kim TS, et al. CT scan features as predictors of patient outcome after bronchial intervention in endobronchial TB. *Chest* 2010;138:380–5.
- Qingliang X, Jianxin W. Investigation of endobronchial tuberculosis diagnoses in 22 cases. *Eur J Med Res* 2010;15:309–13.
- Xue Q, Wang N, Xue X, et al. Endobronchial tuberculosis: an overview. *Eur J Clin Microbiol Infect Dis* 2011;30:1039–44.
- Singla R, Kumar A, Chauhan D, et al. Endobronchial tuberculosis presenting as tumorous mass. *Indian J Chest Dis Allied Sci* 2007;49:45–7.
- Ozkaya S, Bilgin S, Findik S, et al. Endobronchial tuberculosis: histopathological subsets and microbiological results. *Multidiscip Resp Med* 2012;7:34.
- Wang Z, Xu L-L, Wu Y-B, et al. Diagnostic value and safety of medical thoracoscopy in tuberculous pleural effusion. *Respir Med* 2015;109:1188–92.
- Kim HJ, Kim SD, Shin DW, et al. Relationship between bronchial anthracofibrosis and endobronchial tuberculosis. *Korean J Intern Med* 2013;28:330–8.