



CASE REPORT

An unusual presentation of a patient with advanced prostate cancer, massive ascites and peritoneal metastasis: Case report and literature review



Dimitrios Petrakis ^a, George Pentheroudakis ^a, Sevasti Kamina ^b, Lambrini Pappa ^b, Evangelos Papadiotis ^b, Vassiliki Malamou-Mitsi ^b, Nicholas Pavlidis ^{a,*}

^a Department of Medical Oncology, Ioannina University Hospital, S. Niarchos Avenue, Ioannina 45500, Greece

^b Department of Pathology-Cytology, Ioannina University Hospital, S. Niarchos Avenue, Ioannina 45500, Greece

ARTICLE INFO

Article history:

Received 6 March 2014

Received in revised form 9 May 2014

Accepted 9 May 2014

Available online 17 May 2014

Keywords:

Prostate cancer

Ascites

Peritoneal metastases

Case report

ABSTRACT

We describe the case of a patient with prostate cancer, ascites, omental and bone metastases, an extremely rare clinical variant that warrants further investigation, and review the relevant literature.

© 2014 Production and hosting by Elsevier B.V. on behalf of Cairo University.

Introduction

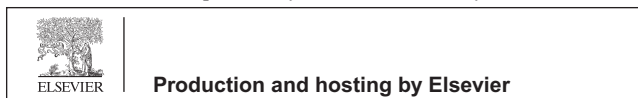
Prostate cancer is the second cause of cancer related deaths in men, despite a decrease in incidence and mortality rates in the

United States by 2.4% from 2001 to 2005 [1]. Hematogenous metastases are present in 35% of patients with prostate cancer, with most frequent involvement sites being bone (90%), lung (46%), liver (25%), pleura (21%), and adrenals (13%) [2–4]. The risk of systemic dissemination increases sharply in the presence of regional and para-aortic lymph node involvement. The peritoneum is an extremely rare metastatic site for prostatic adenocarcinoma, with only a few cases published to date. We present a rare case of a patient who presented to our department with peritoneal disease, massive ascites and locally advanced prostate cancer. A review of the literature was also performed.

* Corresponding author. Tel./fax: +30 26510 99394.

E-mail address: npavlid@uoi.gr (N. Pavlidis).

Peer review under responsibility of Cairo University.



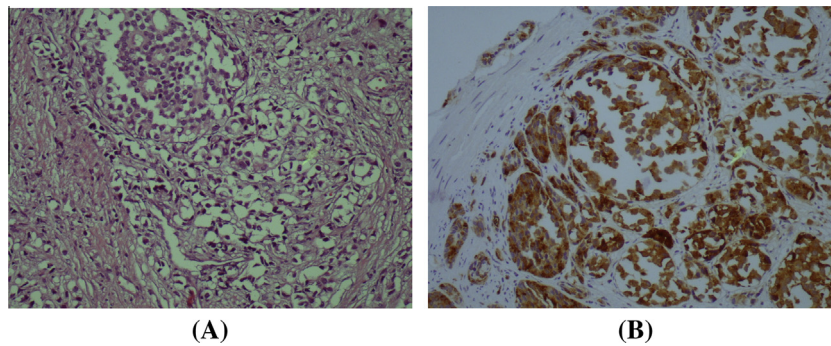


Fig. 1 Prostate biopsy (A) and Prostate-specific antigen (PSA) immunohistochemistry (B). (A) Histology of prostate obtained after prostatectomy showing neoplastic cells arranged in diffuse and rarely in cribriform pattern. Cytoplasm is pale to clear and contain oval nuclei with prominent nucleoli. H + E. (B) Prostate-specific antigen (PSA) immunohistochemistry.

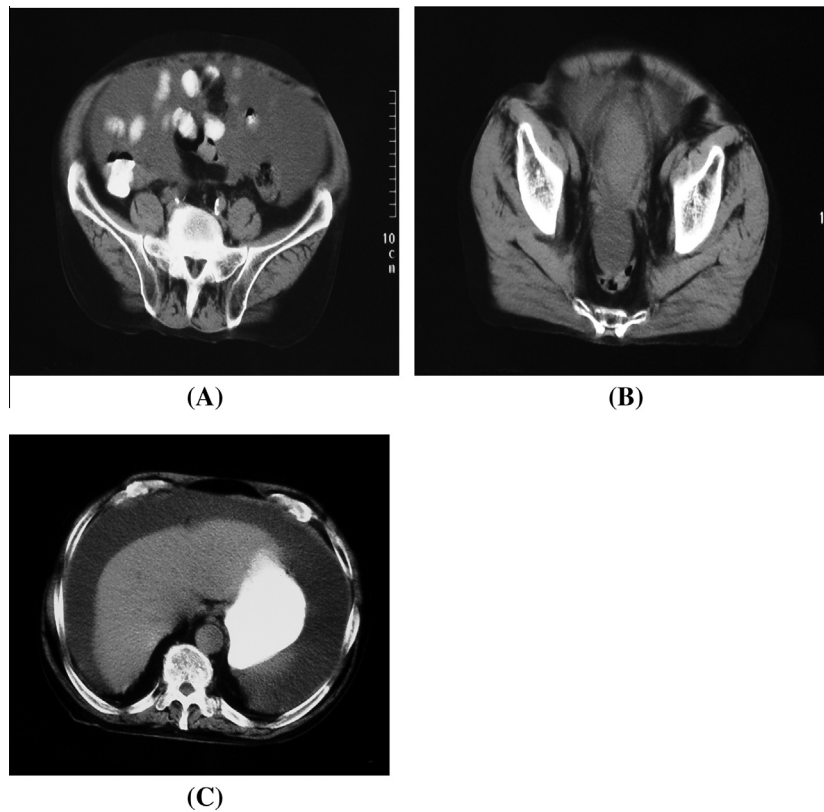


Fig. 2 (A) Abdominal CT scan showing peritoneal/omental thickening, (B) enlarged prostate gland and (C) ascites.

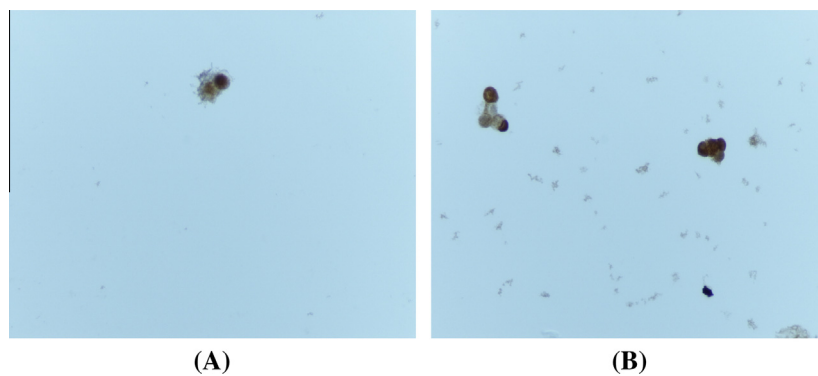


Fig. 3 Cytology of ascitic fluid and prostate acid phosphatase (PAP) test. Material with moderate cellularity and atypical, small-sized cells positive to (A) PSAP and (B) PAP.

Table 1 Review of the Literature of 16 cases with prostate cancer and ascites.

Author/year	Age	Other metastases (apart of peritoneal or omentum)	Treatment		Response of ascites to treatment	Outcome
			Pre-ascites	After-ascites		
Rapoport et al./1968 [6]	76	Lymph nodes	NM	5FU + thiotepa (intraperitoneal)	Progression	Death at 3 months
	45	None	NM	Orchiectomy	NM	Death
Megalli et al./1973 [7]	58	None	None	RT, Diethylstilbestrol	Remission	Alive at 6 months
Biegel et al./1990 [8]	29	Bones	Refusal of therapy		Progression	Death at 1 month
Disdier et al./1990 [9]	78	None	None	Nilutamide	Remission	NM
Catton et al./1992 [10]	63	Visceral, lymph nodes	Orchiectomy		Remission	Death at 13 months
Saif et al./1999 [11]	70	None	RT, leuprolide, leutamide, bicalutamide, thalidomide	NM	Progression	Disease progression
Tsai et al./2001 [12]	68	Rectal wall	Toremifene	Interferon	Progression	Death at 16 weeks
Amin et al./2002 [13]	83	Lymph nodes	Antiandrogens	Hormonal withdrawal	Progression	Death at 6 weeks
Kehinde et al./2002 [14]	76	None	None	TURP, Orchiectomy	Remission	18 months post-orchietomy with no recurrent ascites
Lapoile et al./2004 [15]	80	Bones, others	RT, triptorelin, aminoglutethimide and hydrocortisone	None	Progression	Death at 12 weeks
Appalaneni et al./2004 [16]	60	Bones, lymph nodes	RT, LHRH agonist, antiandrogen	None	Progression	Death at 6 weeks
Brehmer et al./2007 [17]	75	Lymph nodes (no ascites present)	Bicalutamide	Goserelin, Bicalutamide	Remission	14 months no recurrence
Madaan et al./2007 [18]	75	Lymph nodes	Goserelin	Diethylstilboestrol, ASA	Progression	Death within 4 months
Zagouri et al./2009 [19]	75	None	Goserelin, bicalutamide and docetaxel estramustine	Docetaxel	Remission	NM
Benedict et al./2010 [20]	67	None	Hormonal therapy	Docetaxel	Remission	NM
Ani et al./2013 [21]	57	Lymph nodes, Bones	Bicalutamide LHRH agonist	–	Stable disease	NM
Present case	76	Lymph nodes	TURP + Goserelin, bicalutamide	Docetaxel	Remission	Alive at 6 months

NM: not mentioned, RT: radiotherapy, TURP: transurethral resection of the prostate, ASA: acetylsalicylic acid.

Case report

A 76 year old patient was admitted to our department in February 2010, for investigation of massive ascites. A diagnosis of prostatic adenocarcinoma had been made 16 years ago. At that time, the patient denied radical surgical or radiotherapeutic treatment and was managed with only transurethral resection and combined androgen blockade with bicalutamide and leuprolide. Seven months before the current admission bladder infiltration with the development of bilateral hydronephrosis and pelvic/para-aortic lymph node enlargement were documented on computerized tomography (CT), along with rise of serum PSA (286.4 ng/ml) as well as moderate renal dysfunction (serum creatinine 3.0 mg/dl). New prostatic biopsies were obtained (Fig. 1). Nephrostomies were placed in both kidneys and bicalutamide was withdrawn. Within the following weeks, episodes of hematuria and massive ascites, complicated by constipation and malaise, prompted the patient to visit our department.

Family history was remarkable for a brother with leukemia and a son with sarcoma. He was a smoker (30 pack/years), with no consumption of alcohol and no allergies. Physical examination confirmed the presence of massive ascites and a firm prostate enlargement on rectal exam. Both nephrostomies were functioning normally. Laboratory investigation showed increased serum PSA levels of 432.9 ng/ml and serum creatinine concentrations at 3.1 mg/dl. An abdominopelvic CT showed bladder infiltration, omental thickening and massive ascites (Fig. 2). Large volume paracentesis of the ascitic fluid confirmed the diagnosis of metastatic adenocarcinoma with the presence of atypical, small-sized cells positive for PSA and prostate-specific acid phosphatase (PSAP) (Fig. 3). Bone scintigraphy was positive for bone metastases. Intravenous docetaxel 60 mg/m² and daily oral prednisone 5 mg bid were commenced, resulting in symptomatic palliation, clinical improvement, resolution of ascites and a decrease of serum PSA levels (100 ng/ml). After having completed nine cycles of treatment, the patient is asymptomatic 10 months after initiation of therapy.

Discussion

Prostatic cancer is metastatic in 35% of cases, with a marked predilection for bony spread. Growth factors immobilized on bony matrix and adhesive molecules expressed in marrow stromal cells as well as production of PSA and urokinase-type plasminogen activator (u-PA) are some of the factors implicated for preferential homing of prostate cancer cells to the bones in 90% of metastatic cases [5]. Other less common sites are lung, liver, pleura and adrenals. Skin, optic nerve, mandible, testicles, penis, pituitary gland, thyroid, salivary glands are some of the uncommon sites reported in the literature. The omentum as metastatic site is extremely rare, with only 15 cases presented until now [6–21] (Table 1). The age of these patients at diagnosis ranged between 29 and 76 years, the majority of them had a high risk localized adenocarcinoma at diagnosis and only three presented with bone metastases. The time gap between diagnosis and ascites was from 1 to 16 years [6–21]. Ascites responded in 7 out of 16 cases, 4 to endocrine manipulations and 3 to chemotherapy. Responders survived up to 18 months while nonresponders died between 1 and 4 months. In our case the patient presented with similar

clinical findings, as he was treated for 16 years for localized disease and was stable until seven months before admission. We confirmed peritoneal involvement by cytology and abdominopelvic CT. Strikingly, the clinical, imaging and biochemical response to docetaxel/prednisone was remarkable already even after the 1st cycle of therapy. Clinicians should be aware of this rare clinical variant of prostate cancer which should be meticulously worked up in order to exclude other malignancies. Occasionally palliation can be achieved with hormonal treatment or chemotherapy regimens already used for metastatic prostate cancer.

Conclusions

With this article, we added an additional case of an unusual manifestation of advanced prostate cancer presented with peritoneal metastases and massive ascites. Oncologists should draw their attention to this rare clinical presentation of metastatic prostatic cancer.

Conflict of interest

The authors have declared no conflict of interest.

Compliance with ethics requirements

All procedures followed were in accordance with the ethical standards of the responsible committee on human experimentation (institutional and national) and with the Helsinki Declaration of 1975, as revised in 2008 (5). Informed consent was obtained from patient included in the study.

References

- [1] Jemal A, Siegel R, Ward E, Hao Y, Xu J, Thun MJ. Cancer statistics 2009. *CA Cancer J Clin* 2009;59(4):225–49.
- [2] Bubendorf L, Schöpfer A, Wagner U, Sauter G, Moch H, Willi N, et al. Metastatic patterns of prostate cancer: an autopsy study of 1,589 patients. *Hum Pathol* 2000;31(5):578–83.
- [3] Conti G, La Torre G, Cicalese V, Michaletti G, Ludovico MG, Cottonaro G, et al. Prostate cancer metastases to bone: observational study for the evaluation of clinical presentation, course and treatment patterns. Presentation of the METAURO protocol and of patient baseline features. *Arch Ital Urol Andro* 2008;80(2):59–64.
- [4] Saiton H, Hida M, Shimbo T, Nakamura K, Yamagata J, Satoh T. Metastatic patterns of prostatic cancer. Correlation between sites and number of organs involved. *Cancer* 1984;54(12): 3078–84.
- [5] Roodman GD. Mechanisms of bone metastasis. *N Engl J Med* 2004;350:1655–64.
- [6] Rapoport AH, Omenn GS. Dermatomyositis and malignant effusions: rare manifestation of cancer. *J Urol* 1968;100(2): 183–7.
- [7] Megalli MR, Gursel EO, Veenema RJ. Ascites as an unusual presentation of carcinoma of the prostate. *J Urol* 1973;110(2): 232–4.
- [8] Beigel Y, Zelikovski A, Shimoni S, Ekstein J, Melloul M, Mor C, et al. Chylous ascites as a presenting sign of prostate adenocarcinoma. *Lymphology* 1990;23(4):183–6.
- [9] Disdier P, Harle JR, Swiader L, Coulange C, Mongin M, Weiller PJ. Prostate carcinoma revealed by ascites with cachexia. *Presse Medicale* 1990;19(5):220.
- [10] Catton PA, Hartwick RW, Srigley JR. Prostate cancer presenting with malignant ascites: signet-ring cell variant of prostate adenocarcinoma. *Urology* 1992;39(5):495–7.

- [11] Saif MW, Figg WD, Hewitt S, Dahut W. Malignant ascites as only manifestation of metastatic prostate cancer. *Prostate Cancer Dis* 1999;2:290–3.
- [12] Tsai JY, Ling M, Chang VT, Hwang SS, Kasimis BS. Hemorrhagic ascites: an unusual manifestation of prostate carcinoma. *Am J Med* 2001;111(3):245–6.
- [13] Amin R. Chylous ascites from prostatic adenocarcinoma. *Urology* 2002;59(5):773.
- [14] Kehinde EO, Abdeen SM, Al-Hunayan A, Ali Y. Prostate cancer metastatic to the omentum. *Scand J Urol Nephrol* 2002;36(3):225–7.
- [15] Lapoile E, Bellaiche G, Choudat L, Boucard M, El Belachany G, Ley G, et al. Ascites associated with prostate cancer metastases: an unusual localization. *Gastroenterol Clin Biol* 2004;28(1):92–4.
- [16] Appalaneni V, Yellinedi S, Baumann MA. Diagnosis of malignant ascites in prostate cancer by measurem Jakse Gent of prostate specific antigen. *Am J Med Sci* 2004;327(5):262–3.
- [17] Brehmer B, Makris A, Wellmann A. Solitary peritoneal carcinomatosis in prostate cancer. *Actuelle Urol* 2007;38(5):408–9.
- [18] Madaan S, Palit V, Gudgeon P, Biyani CS. Omental metastasis with malignant ascites: an unusual manifestation of prostatic adenocarcinoma. *Can Urol Ass J* 2007;13:288–90.
- [19] Zagouri F, Papaefthimiou M, Chalazonitis AN, Antoniou N, Dimopoulos MA, Bamias A. Prostate cancer with metastasis to the omentum and massive ascites: a rare manifestation of a common disease. *Onkologie* 2009;32(12):758–61.
- [20] Benedict SP, Ahuja M, Mammen KJ. Hormone refractory carcinoma of prostate with peritoneal metastases and malignant ascites without skeletal involvement: a case report and review of literature. *Indian J Urol* 2010;26(2):287–8.
- [21] Ani I, Colstaldi M, Abouassaly R. Metastatic prostate cancer with malignant ascites: a case report and literature review. *Can Urol Assoc J* 2013;7:E248–50.