

# Radiotherapy-associated intra-abdominal angiosarcoma after prostatic adenocarcinoma: Case reports

DAVID PARADA DOMÍNGUEZ\* and KARLA B. PEÑA GONZALEZ\*

Pathology Service, University Hospital of Saint Joan, Faculty of Medicine, IISPV, 'Rovira i Virgili' University, Reus, 43204 Tarragona, Spain

Received October 25, 2017; Accepted July 13, 2018

DOI: 10.3892/mco.2018.1738

**Abstract.** Angiosarcoma is a rare soft tissue neoplasm, which accounts for <1% of all soft tissue tumours. It has been previously reported that the incidence rate of angiosarcomas increases following radiotherapy. The present study reports two cases of intra-abdominal angiosarcoma associated with previous radiotherapy treatment. To the best of our knowledge, these associations have not been previously described in English literature. The patients aged 71 and 83 years were admitted to the center for abdominal pain and diarrhea. Each patient had previously had treatment with radiotherapy for prostate adenocarcinoma. During their hospitalization, biopsies were obtained and the diagnosis of angiosarcoma was reached. In each patient the tumors had irregular proliferating vascular channels, lined by atypical endothelial cells, which varied from elongated and spindle-shaped to large and plump. Immunocytochemistry revealed that the tumor cells were positive for the cytoplasmic endothelial markers cluster of differentiation (CD)31 and CD34. The recognition of these associations is important and their occurrence in this rare type of neoplasm should not mislead the pathologist and cause a misdiagnosis of the sarcoma.

## Introduction

Angiosarcomas is a malignant tumour that recapitulate the functional and morphologic features of normal endothelium. Angiosarcomas are rare forms of soft tissue neoplasm, comprising less than 1% of all soft tissue tumours (1-3). The majority of these tumours develop as subcutaneous lesions, usually at head and neck region (1). Also, these vasoformative soft tissue tumours arise in a number of well-defined clinical

settings such as chronic lymphedema, usually post mastectomy (Stewart-Treves Syndrome) and rarely congenital lymphedema (Milroy's disease) or filarial lymphedema (4).

The risk of developing cancer is increased among persons who already have had cancer previously, which may be caused by both the joint causal factors for the first primary cancer and the treatment of the first cancer, as both chemotherapy and radiotherapy are known to increase the risk (5-9). Excess risks of developing soft tissue sarcoma have been reported in relation to radiation treatment for cancers such as of breast, ovary, cervix, and Hodgkin's and non-Hodgkin lymphoma. For breast and ovary cancer, during a follow-up of over 10 years, the soft tissue cancer risk increased to 8-25-fold, and latency time has varied between 2 and 40 years (5-9).

To our knowledge, we report the first two cases of intra-abdominal angiosarcoma eight and five years after therapeutic prostate adenocarcinoma radiation. We discuss previous literature regarding intra-abdominal angiosarcoma and radiation treatment.

## Case reports

*Case 1.* A 71-year-old man presented in June 2016 with diffuse abdominal pain. The patient's history was significant for pT2a prostatic adenocarcinoma (Gleason score 7) in 2011 treated with external radiation therapy (70 Gy) and hormonal treatment six months. In 2015 the patient was diagnosed with *in-situ* urothelial carcinoma treated with BCG six cycles. He received regular follow-up, and his latest serum prostate-specific antigen level (March 2016) was 0.0023 ng/ml (normal 0-0.04 ng/ml). His past medical history was not relevant. He had no history of exposure to chemicals. Physical examination revealed ascites and peritoneal fluid liquid was obtained. Computed tomographic scan of the abdominal cavity showed peritoneal carcinomatosis. An exploratory laparoscopy was performed with peritoneal biopsy. After diagnosis the patient received palliative chemotherapy with Paclitaxel. He died five months after the diagnostic. No autopsy was performed.

*Case 2.* An 82-year-old man presented in July 2016 with diarrhea and generalized weakness. The patient's history was significant for pT3a prostatic adenocarcinoma (Gleason score 7) in 2008 treated with external radiation therapy (75 Gy) and hormonal treatment. In 2012 the patient was diagnosed with

---

*Correspondence to:* Dr David Parada Domínguez, Pathology Service, University Hospital of Saint Joan, Faculty of Medicine, IISPV, 'Rovira i Virgili' University, 1 Avenue del Dr Joseph Laporte, Reus, 43204 Tarragona, Spain  
E-mail: dparada@grupsgassa.com

\*Contributed equally

**Key words:** angiosarcoma, radiotherapy, C-Myc, prostate adenocarcinoma

colonic adenocarcinoma pT4aN0 Mx. In 2016 the diagnosis of invasive high-grade urothelial carcinoma was performed, with posterior cystoprostatectomy. His past medical history revealed systemic arterial hypertension, type 2 diabetes mellitus, and chronic renal failure. He had no history of exposure to chemicals. Physical examination was unremarkable. After admission, abdominal CT was performed with compatible diagnosis of local recurrence at the sigmoid level by urothelial carcinoma, and laparoscopic resection was performed. He died seven days after the diagnostic. No autopsy was performed.

Peritoneal fluid liquid was processed by liquid cytology using ThinPrep 2000 System (Cytoc Corp, Marlborough, MA) and stained according to the Papanicolaou technique and hematoxylin-eosin staining (H&E). The surgical specimens from case 1 and 2 were fixed in 10% buffered formalin for at least 24 h. After fixation, biopsied sections from the peritoneal and sigmoidectomy were embedded in paraffin, cut at 2  $\mu$ m, and stained with H&E. In addition, 2- $\mu$ m sections were obtained from the paraffin-embedded samples and were placed in an automatic processor VENTANA<sup>®</sup> Benchmark ULTRA/LT immunohistochemistry, Ventana Medical Systems, USA, using the previously standardized protocol for CD31 (pre-diluted), CD34 (pre-diluted), FVIII (pre-diluted), cytokeratin AE1/AE3 (pre-diluted), calretinin (pre-diluted), Kaposi sarcoma herpes virus (pre-diluted) and c-Myc (pre-diluted), including retrieval solution pH9 and detection kit for Immunohistochemistry Optiview<sup>®</sup> DAB (VENTANA<sup>®</sup>). The primary antibodies (Roche Pharmaceutical, Inc) were incubated for 32 min. Finally, the immunohistochemical sections were revealed with Diaminobenzidine, contrasted with Meyer's hematoxylin. For each immunohistochemical study cecal appendix was used as positive and negatives control.

## Results

*Case 1.* The cytology sample consisted of 20 ml haemorrhagic fluid, which was processed for liquid cytology and cell block. The surgical biopsy specimen consisted of 20x15 mm of tan-yellow soft tissue mixed with clotted blood. The entire specimen was submitted for histopathologic examination. Cytological smears were cellular and showed a population of spindle and pleomorphic cells with ill-defined cell borders. The nuclei were oval and hyperchromatic with irregular nuclear membranes. Branching papillary clusters and pseudoacini or rosettelike groups were also seen. The tumour cells were positive by immunocytochemistry for cytoplasmic endothelial markers CD31 (Fig. 1), CD34 and factor VIII, confirming the endothelial origin of sarcoma (10). The tumor cells were negative for keratin and Kaposi sarcoma herpes virus. The tumour cells were also positive for c-Myc (Fig. 1).

Microscopically, the epiplon showed an irregular proliferating vascular channels, with nodular appearance, lined by atypical endothelial cells, which in turn were surrounded by spindle-shaped cells and epithelioid areas. The tumour cells varying from elongated and spindle-shaped to large and plump. The epithelioid morphology showed large rounded cells, arranged in small nests, cords or rudimentary vascular channels. Mitoses were fairly frequent and some were atypical. The tumour cells were positive by immunocytochemistry for cytoplasmic endothelial markers CD31 (Fig. 1), CD34 and

Table I. Cahan criteria for the development of radiotherapy-induced sarcomas and the present cases.

Cahan criteria <sup>a</sup>	Case 1	Case 2
Sarcoma in the area of irradiation	Hypogastrium	Sigmoid
Latent period	5 years	8 years
Sarcoma confirmed	Angiosarcoma	Angiosarcoma

<sup>a</sup>Reference (17).

factor VIII, confirming the endothelial origin of sarcoma (10). The tumor cells were negative for keratin and Kaposi sarcoma herpes virus. The tumour cells were also positive for c-Myc (Fig. 1).

*Case 2.* The surgical specimen consisted of a sigmoidectomy of 280 mm in length. The serosa showed congestive zones, alternating with necro-haemorrhagic areas and fibrin deposits. The mucosa presented oedematous aspect. Representative material was submitted for histopathologic examination. Microscopically, a neoplastic lesion located on the serous surface and affecting the colonic muscle layer was observed. Neoplasia consisted of vasoformative areas consist of ramifying channels lined by atypical endothelial cells forming intraluminal buds and focal papillar formations. The tumour cells were pleomorphic, varying from elongated and spindle-shaped to large and plump. The nuclei were large and pleomorphic with clumped chromatin and prominent nucleoli (Fig. 2). The tumour cells were positive by immunocytochemistry for cytoplasmic endothelial markers CD31 (Fig. 1), CD34 and factor VIII, confirming the endothelial origin of sarcoma. The tumor cells were negative for the Kaposi sarcoma herpes virus, keratin and calretinin. The tumour cells were also positive for c-Myc (Fig. 2).

## Discussion

Radiation therapy is a routinely used therapeutic modality for prostate cancer and may predispose to the appearance of secondary neoplasms such as bladder, lung and rectum cancer (10,11). It has also been reported that sarcomas increase their incidence after radiotherapy for prostate carcinoma, being 6% within the radiation field and 2% outside the radiation field (11). In this regard, few cases of angiosarcoma have been reported following radiotherapy for carcinoma of the prostate (12-16). To the best of our knowledge we describe the first two cases of intra-abdominal angiosarcomas secondary to radiotherapy treatment for prostate carcinoma.

Our cases met the suggested diagnostic criteria described by Cahan *et al* (17) for the development of radiotherapy-induced sarcomas (Table I), such as: the sarcoma should arise in the area previously subjected to irradiation, (2) a latent period (in years) must exist between the time of irradiation and development of the sarcoma and (3) the sarcoma must be confirmed histologically. In both cases, the latency period was 5 to 8 years, they were developed in the areas where the radiotherapy was

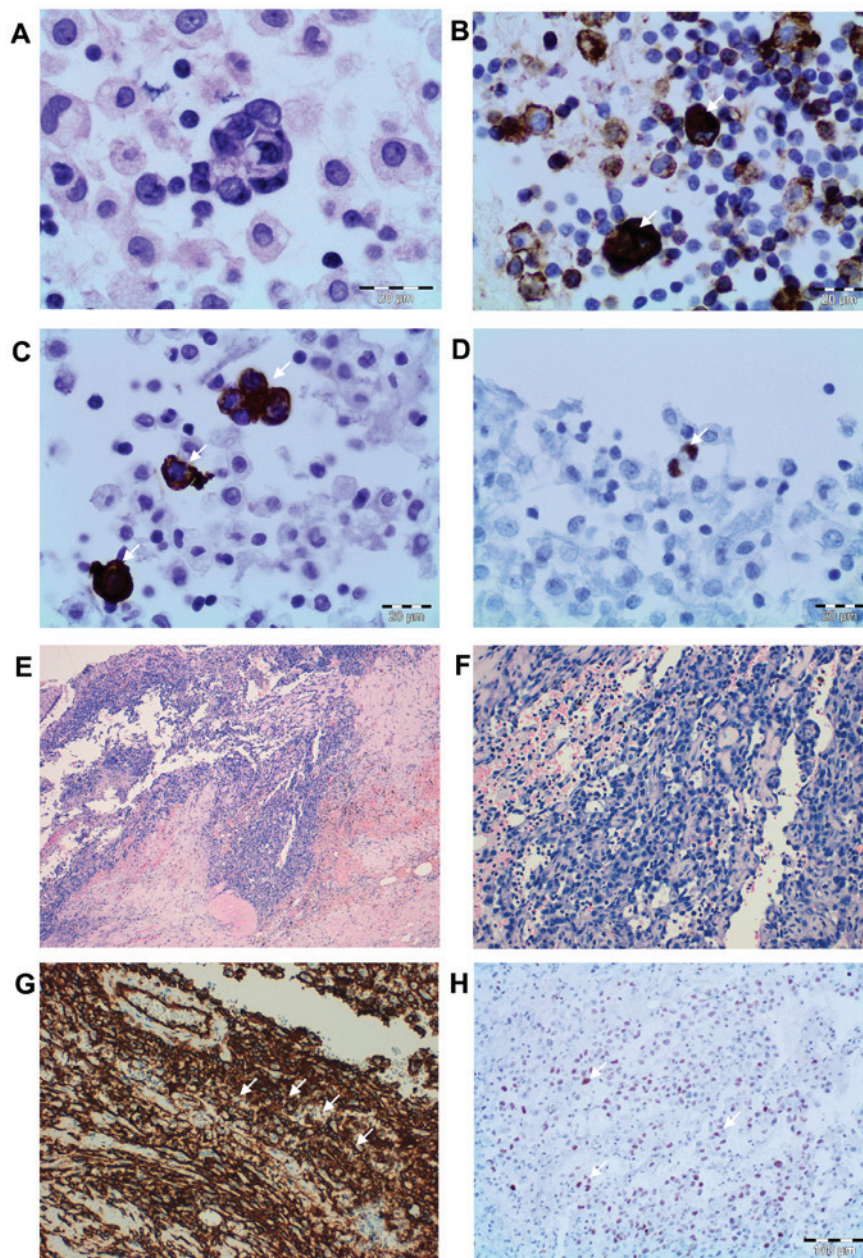


Figure 1. Cytologic and histopathologic findings. Peritoneal fluid cytologic smears revealing a population of atypical and pleomorphic cells with ill-defined cell borders. (A) The nuclei were oval and hyperchromatic with irregular nuclear membranes (H&E; magnification, x200). Tumor cells demonstrating positive immunocytochemistry for (B) CD34 and (C) CD31 (indicated by the white arrows) (DAB; magnification, x200), and (D) nuclear expression of c-Myc (indicated by the white arrow) (DAB; magnification, x200). Irregular proliferating vascular channels, with nodular appearance, lined by atypical endothelial cells and epithelioid areas at (E) magnification, x40 and (F) magnification, x100 (H&E). (G) The tumor cells were positive for CD31 as determined by immunocytochemistry (indicated by the white arrows) (DAB; magnification, x100) and (H) nuclear expression for c-Myc was present (indicated by the white arrows) (DAB; magnification, x100). H&E, hematoxylin and eosin staining; DAB, 3'-diaminobenzidine staining; CD, cluster of differentiation.

performed and finally, the diagnosis was confirmed from the cytological and histopathological points of view.

Additionally, one of the pathways related to the development of radiotherapy-induced angiosarcomas may be c-Myc. c-Myc is a well-established proto-oncogene, which when overexpressed drives cell proliferation, blocks cell differentiation, promotes angiogenesis and genetic instability (18-20). Some studies have shown that c-Myc amplification is a recurrent genetic alteration in secondary angiosarcomas, but not in primary angiosarcomas, suggesting distinct pathogenetic mechanisms between them (1,3,6,20-25). In our cases, the immunohistochemical expression of c-Myc could be correlated with genetic amplifica-

tions and this mechanism of c-myc c-Myc seems to be key for the development of secondary angiosarcomas. This finding supports the possibility of relating the angiosarcomas studied with the radiant pre-effect. To our knowledge, we describe two cases of intra-abdominal angiosarcoma with c-myc post-radiotherapy expression for prostatic adenocarcinoma.

After an exhaustive bibliographic review, we found no cases of secondary angiosarcomas located in the abdominal region in patients treated with prostate cancer radiotherapy. This indicates that the risk for the development of these sarcomas after radiotherapy in this group of patients with prostate cancer is practically absent. Thus, given the large number of patients

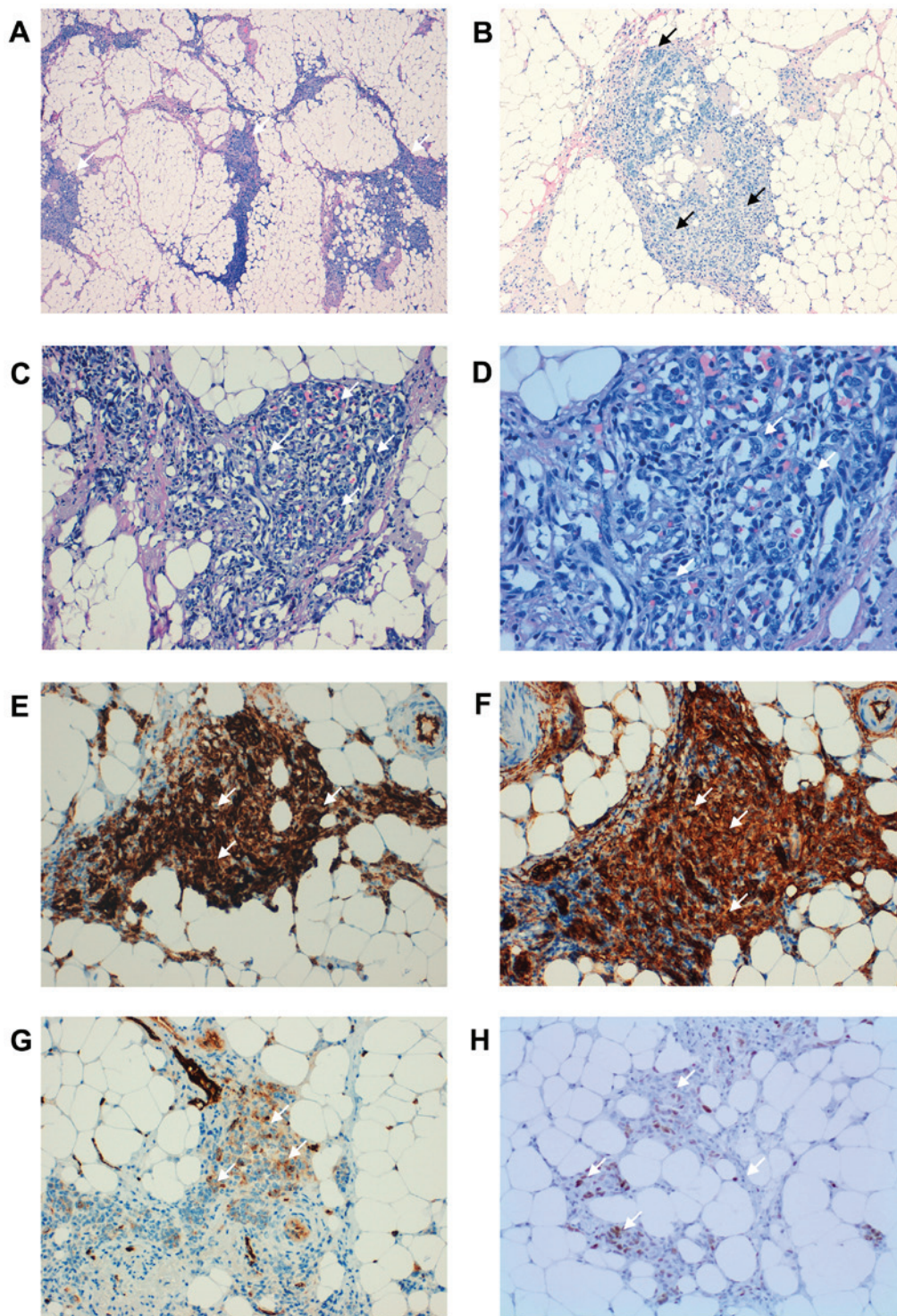


Figure 2. Histopathological findings. (A) A neoplastic lesion located on the serous surface, which affected the colonic muscle layer was observed (white arrows) (H&E; magnification, x40). Vasoformative areas consisted of ramifying channels lined by atypical endothelial cells forming (B) intraluminal buds (white arrows) and (C) focal papillations (white arrows) (H&E; magnification, x100). (D) Tumor cells varying from elongated and spindle-shaped to large and plump (white arrows) (H&E; magnification, x200). The tumor cells were positive for (E) CD34, (F) CD31 and (G) factor VIII (white arrows) (DAB; magnification, x100), supporting an endothelial origin. (H) The tumor cells were also positive for c-Myc (white arrows) (DAB; magnification, x100). H&E, hematoxylin and eosin staining; DAB, 3'-diaminobenzidine staining; CD, cluster of differentiation.

who can be cured or who receive palliative treatment with radiation therapy, concern regarding post irradiation sarcoma should not be a major factor influencing treatment decisions in patients with cancer (26). Different population studies have shown that the appearance of secondary angiosarcomas is frequently observed related to breast or gynaecological

cancers (5-9). This suggests an association between female hormonal factors and secondary angiosarcoma.

In summary, secondary angiosarcomas of the abdominal cavity are exceedingly rare. They may pose considerable diagnostic difficulty in a partial sampling or cytology study. Awareness of the possibility of angiosarcomas occurring in

this location, particularly with a history of prostate cancer radiation, and use of appropriate immunohistochemical studies are crucial to establish a correct diagnosis.

### Acknowledgements

Not applicable.

### Funding

No funding was received.

### Availability of data and materials

All data generated or analyzed during this study are included in this published article.

### Authors' contributions

DP and KP contributed to the cytological diagnosis and manuscript preparation. DP and KP performed the immunocytochemical and immunohistochemical staining and the histopathological diagnosis. DP contributed to the collection of patient data. The final version of the manuscript has been read and approved by all authors.

### Ethics approval and consent to participate

The authors obtained consent from the Ethics Committee of the Sant Joan University Hospital in Reus (registration no. CEIM: 034/2018) for publication of the case details.

### Patient consent for publication

Not applicable.

### Competing interests

The authors declare that they have no competing interests.

### References

- Doyle LA: Sarcoma classification: An update based on the 2013 World Health Organization classification of tumors of soft tissue and bone. *Cancer* 120: 1763-1774, 2014.
- Mastrangelo G, Coindre JM, Ducimetière F, Dei Tos AP, Fadda E, Blay JY, Buja A, Fedeli U, Cegolon L, Frasson A, *et al*: Incidence of soft tissue sarcoma and beyond: A population-based prospective study in 3 European regions. *Cancer* 118: 5339-5348, 2012.
- Antonescu C: Malignant vascular tumors-an update: *Mod Pathol* 27 (Suppl 1): S30-S38, 2014.
- Wolov RB, Sato N, Azumi N and Lack EE: Intra-abdominal 'angiosarcomatosis' report of two cases after pelvic irradiation. *Cancer* 67: 2275-2279, 1991.
- Kumar S: Second malignant neoplasms following radiotherapy. *Int J Environ Res Public Health* 9: 4744-4759, 2012.
- Sholl LM, Barletta JA and Hornick JL: Radiation-associated neoplasia: Clinical, pathological and genomic correlates. *Histopathology* 70: 70-80, 2017.
- Anzalone CL, Cohen PR, Diwan AH and Prieto VG: Radiation-induced angiosarcoma. *Dermatol Online J* 19: 2, 2013.
- Virtanen A, Pukkala E and Auvinen A: Incidence of bone and soft tissue sarcoma after radiotherapy: A cohort study of 295,712 Finnish cancer patients. *Int J Cancer* 118: 1017-1021, 2006.
- Virtanen A, Pukkala E and Auvinen A: Angiosarcoma after radiotherapy: A cohort study of 332,163 Finnish cancer patients. *Br J Cancer* 97: 115-117, 2007.
- Bhojani N, Capitanio U, Suardi N, Jeldres C, Isbarn H, Shariat SF, Graefen M, Arjane P, Duclos A, Lattouf JB, *et al*: The rate of secondary malignancies after radical prostatectomy versus external beam radiation therapy for localized prostate cancer: A population-based study on 17,845 patients. *Int J Radiat Oncol Biol Phys* 76: 342-348, 2010.
- Wallis CJ, Mahar AL, Choo R, Herschorn S, Kodama RT, Shah PS, Danjoux C, Narod SA and Nam RK: Second malignancies after radiotherapy for prostate cancer: Systematic review and meta-analysis. *BMJ* 352: i851, 2016.
- Wang G, Black PC, Skinnider BF, Hayes MM and Jones EC: Post-radiation epithelioid angiosarcoma of the urinary bladder and prostate. *Can Urol Assoc J* 10: E197-E200, 2016.
- Gupta A, Patnaik MM and Naina HV: Angiosarcoma of the prostate gland following brachytherapy for prostatic adenocarcinoma. *Curr Urol* 8: 109-112, 2015.
- Ojerholm E, Stripp D, Mamtani R, Van Arsdalen K and Tripp P: Angiosarcoma of the bladder following prostate radiotherapy. *Am J Med* 128: e11-e12, 2015.
- Chandan VS and Wolsh L: Postirradiation angiosarcoma of the prostate. *Arch Pathol Lab Med* 127: 876-878, 2003.
- Sakemi M, Sakemi R, Harada M, So S, Uchiyama D, Morimitsu Y, Kakiuchi S, Ishihara Y, Kubo Y, Matsugaki S, *et al*: A case of postirradiation angiosarcoma of the greater omentum with hemorrhage. *Clin J Gastroenterol* 4: 302-306, 2011.
- Cahan WG, Woodard HQ, *et al*: Sarcoma arising in irradiated bone; report of 11 cases. *Cancer* 1: 3-29, 1948.
- Wade MA, May FE, Onel K and Allan JM: Does radiation-induced c-MYC amplification initiate breast oncogenesis? *Mol Cell Oncol* 3: e1010950, 2015.
- Wade MA, Sunter NJ, Fordham SE, Long A, Masic D, Russell LJ, Harrison CJ, Rand V, Elstob C, Bown N, *et al*: c-MYC is a radio-sensitive locus in human breast cells. *Oncogene* 34: 4985-4994, 2015.
- Styring E, Seinen J, Dominguez-Valentin M, Domanski HA, Jönsson M, von Steyern FV, Hoekstra HJ, Suurmeijer AJ and Nilbert M: Key roles for MYC, KIT and RET signaling in secondary angiosarcomas. *Br J Cancer* 111: 407-412, 2014.
- Manner J, Radlwimmer B, Hohenberger P, Mössinger K, Küffer S, Sauer C, Belharazem D, Zettl A, Coindre JM, Hallermann C, *et al*: MYC high level gene amplification is a distinctive feature of angiosarcomas after irradiation or chronic lymphedema. *Am J Pathol* 176: 34-39, 2010.
- Fraga-Guedes C, André S, Mastropasqua MG, Botteri E, Toesca A, Rocha RM, Peradze N, Rotmensz N, Viale G, Veronesi P and Gobbi H: Angiosarcoma and atypical vascular lesions of the breast: Diagnostic and prognostic role of MYC gene amplification and protein expression. *Breast Cancer Res Treat* 151: 131-140, 2015.
- Fernandez AP, Sun Y, Tubbs RR, Goldblum JR and Billings SD: FISH for MYC amplification and anti-MYC immunohistochemistry: Useful diagnostic tools in the assessment of secondary angiosarcoma and atypical vascular proliferations. *J Cutan Pathol* 39: 234-242, 2012.
- Laé M, Lebel A, Hamel-Viard F, Asselain B, Trassard M, Sastre X and Kirova YM: Can c-myc amplification reliably discriminate postradiation from primary angiosarcoma of the breast? *Cancer Radiother* 19: 168-174, 2015.
- Mentzel T, Schildhaus HU, Palmedo G, Büttner R and Kutzner H: Postradiation cutaneous angiosarcoma after treatment of breast carcinoma is characterized by MYC amplification in contrast to atypical vascular lesions after radiotherapy and control cases: clinicopathological, immunohistochemical and molecular analysis of 66 cases. *Mod Pathol* 25: 75-85, 2012.
- Mark RJ, Poen J, Tran LM, Fu YS, Selch MT and Parker RG: Postirradiation sarcomas. A single-institution study and review of the literature. *Cancer* 73: 2653-2662, 1994.



This work is licensed under a Creative Commons Attribution-NonCommercial-NoDerivatives 4.0 International (CC BY-NC-ND 4.0) License.