

Primary care in early cleft lip and palate rehabilitation: A dental perspective

Amanda Nadia Ferreira, Godwin Clovis Da Costa

Department of Prosthodontics and Crown & Bridge, Goa Dental College and Hospital, Bambolim, Goa, India

ABSTRACT

Oro-facial clefts are among the most commonly occurring congenital defects. Surgical interventions are commonly carried out to treat these deformities. Some inadequacies however, like scarring of the nasolabial complex and multiple interventions to achieve desired results still persist. Presurgical Nasoalveolar molding (PNAM) technique can be carried out before surgical repair, to facilitate a reduction in the severity of the cleft by actively molding and repositioning the clefted alveolar segments and the associated soft tissues. This case series describes the successful rehabilitation of two unilateral mid-facial cleft babies using the PNAM technique in a step wise manner with a two year follow up.

Keywords: Alveolar cleft segments, cleft lip and palate, presurgical nasoalveolar molding

Introduction

An international survey on the prevalence of cleft palate states that it is noted in 1 in every 600 babies.^[1] Asia alone has reported about 0.82–4.04 cases per 1,000 live births.^[2] Babies born in underdeveloped and developing nations have restricted access to treatment and the majority receive no treatment at all.^[3] Orofacial clefts have a significant impact on the lives of those affected, particularly when left untreated.^[4] Grayson *et al.*^[5] described presurgical nasolaveolar molding (PNAM) as a simple cost-effective technique that lessens the severity of the cleft, thereby improving the outcome after the cleft lip and palate surgery.^[6-7]

Case 1

A 14-day old baby boy with a midfacial cleft was referred to the prosthodontic department for the fabrication of a feeding plate. Clinical examinations revealed a left unilateral cleft lip and palate,

which extended to the soft palate [Figure 1]. The parents were informed about their role in the PNAM procedure.

Treatment procedures

Impressions of the cleft were made using a low fusing impression compound (DPI Pinnacle, tracing sticks) placed on the handle of a stock tray [Figure 2]. The size of the cleft was measured to be 8.3 mm on the acquired cast. The clefted area on the cast was blocked out, and a base plate was fabricated in heat cure acrylic resin (DPI, Heat cure). It was then finished and polished and a self-cure acrylic retentive button was attached on the labial aspect of the base plate at an angle of 45° to the occlusal plane. In the baby, the intaglio surface of the plate was modified using a tissue conditioner (Viscogel, Dentsply) to apply selective pressure on the two clefted alveolar segments. Orthodontic elastic bands (Tru-Force latex elastic system) were looped around the acrylic button and hooked to elastic bands, which were attached to the Velcro strips on the tailor-made cloth head cap [Figure 3]. No more than 1 mm of molding was performed at every weekly visit. The molding procedure continued till the cleft was reduced to 5.3 mm at 2 months. Active nasal molding was initiated by first fabricating a nasal stent using a 19 gauge round stainless-steel looped wire

Address for correspondence: Dr. Amanda Nadia Ferreira,
Department of Prosthodontics and Crown & Bridge, Goa Dental
College and Hospital, Bambolim - 403 202, Goa, India.
E-mail: dr.amandaferreira@gmail.com

Received: 27-05-2021

Revised: 22-10-2021

Accepted: 07-12-2021

Published: 10-03-2022

Access this article online

Quick Response Code:



Website:
www.jfmpc.com

DOI:
10.4103/jfmpc.jfmpc_990_21

This is an open access journal, and articles are distributed under the terms of the Creative Commons Attribution-NonCommercial-ShareAlike 4.0 License, which allows others to remix, tweak, and build upon the work non-commercially, as long as appropriate credit is given and the new creations are licensed under the identical terms.

For reprints contact: WKHLRPMedknow_reprints@wolterskluwer.com

How to cite this article: Ferreira AN, Da Costa GC. Primary care in early cleft lip and palate rehabilitation: A dental perspective. *J Family Med Prim Care* 2022;11:1212-5.

and covering it with self-cure clear acrylic and a layer of the tissue conditioner to support the nostril [Figure 4]. Molding continued until the desired nasal cartilage and alveolar shape were achieved and the patient was put up for lip and nose surgery at 15 weeks. The patient was recalled after 6 months and 2 years [Figure 5].

Case 2

An 8-day old baby girl was referred from the department of plastic surgery for a PNAM appliance. Clinical examinations revealed nasal deformity and displaced alveolar segments. The columella and nasal septum were inclined to the cleft and the base deviated toward the non-cleft side [Figure 6].

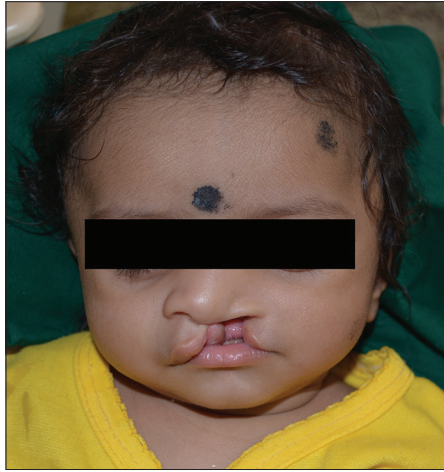

Figure 1: Preoperative image at 14 days

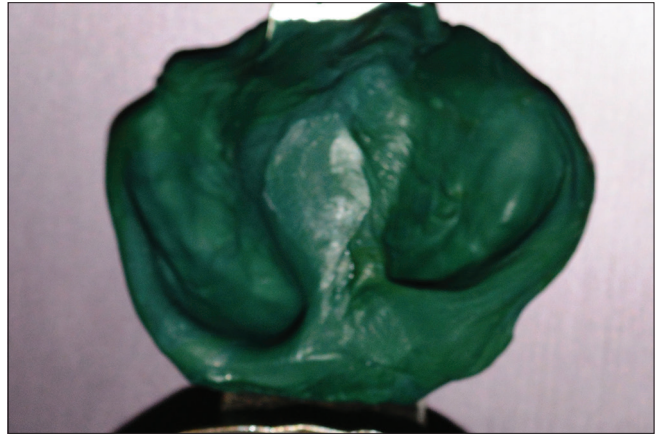


Figure 2: Impression made using the handle of a stock tray

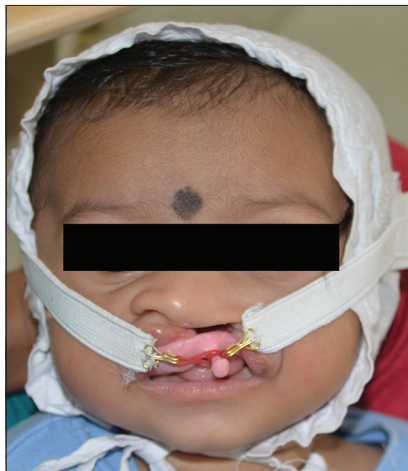

Figure 3: PNAM appliance *in situ*

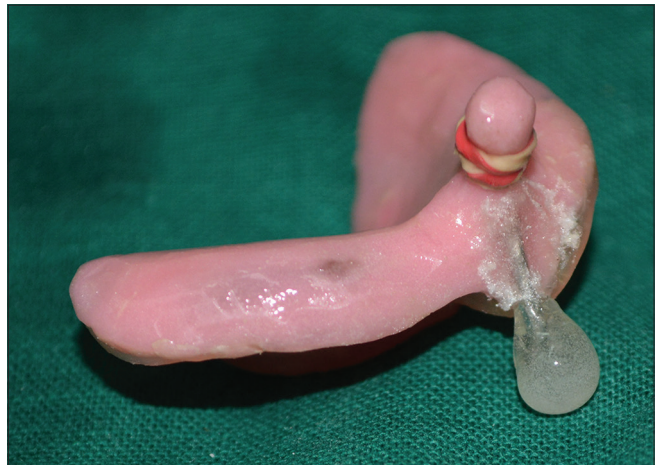

Figure 4: Nasal stent

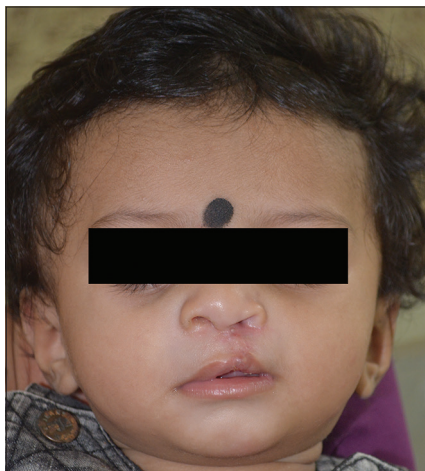

Figure 5: Follow-up at 2 years

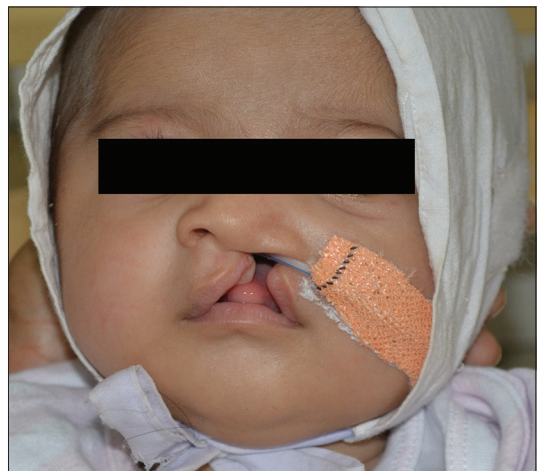

Figure 6: Preoperative image at 8 days

Treatment procedures

Impressions were made in a conventional manner by placing the baby in the caregiver's lap. The cleft measured 8 mm on the master cast [Figure 7]. The area of the cleft was blocked out and a base plate was fabricated. A 5 mm hole was incorporated in the appliance to allow breathing in case of accidental dislodgement. A retentive acrylic button was attached to the labial flange to secure the orthodontic wires [Figure 8]. The finished and polished appliance was tried in the baby's mouth, and the intaglio surface was molded. A tailor-made head cap with Velcro stripes at the side was used to secure the orthodontic elastic wires [Figure 9]. The molding procedure was repeated until the size of the cleft was reduced to 5.2 mm. A nasal stent was then incorporated into the appliance. At 15 weeks, the columella gradually elongated and the patient was scheduled for lip and nose surgery. After the surgery, it was observed that the nasal contour did not resemble the unaffected side [Figure 10]. A postsurgical external nasal

stent was fabricated by making an impression of the unaffected nostril using a tissue conditioner; it was used to mold the nasal contour on the cleft side [Figure 11]. Parents were advised to use it daily for 1 year. At the 2-year follow-up, an improvement in the nasal morphology was observed [Figure 12].

Discussion

This case series documented the reduction of the cleft with successful PNAM and lip and nose surgery with a 2-year follow-up, which showed both patients with pleasing esthetics,

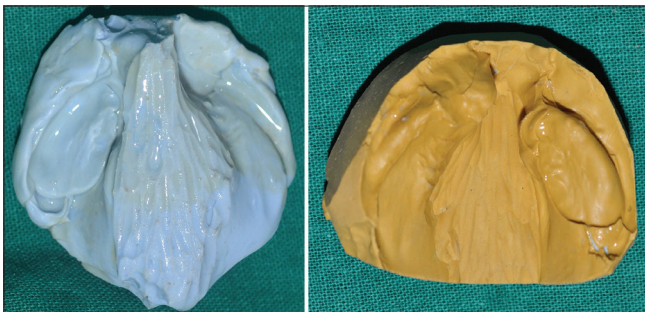


Figure 7: Impression with a master cast

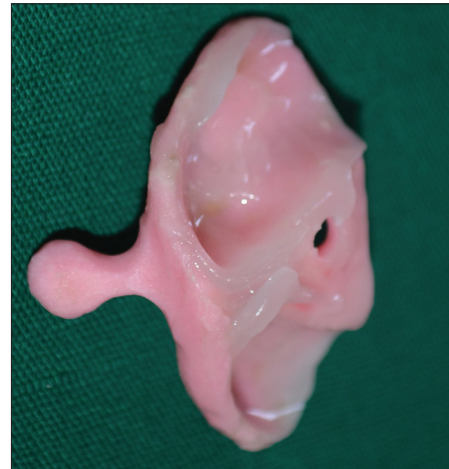


Figure 8: Breathing hole incorporated into the appliance

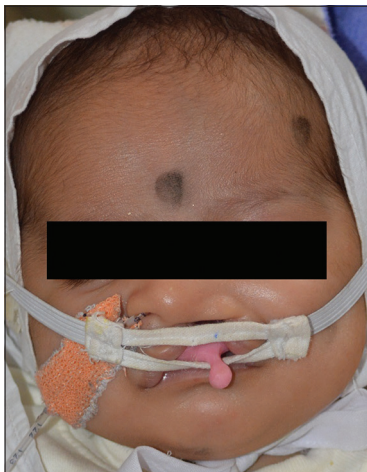

Figure 9: Appliance in baby's mouth

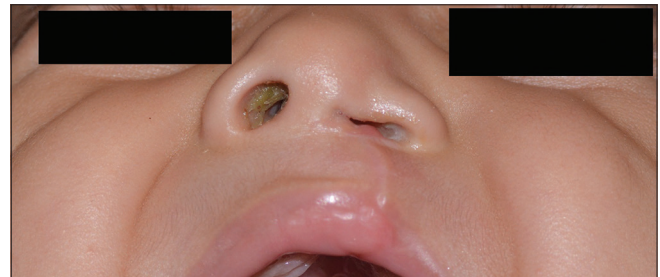

Figure 10: Postsurgical image

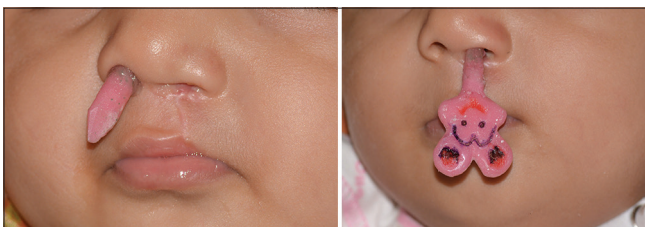

Figure 11: Postsurgical external nasal stent

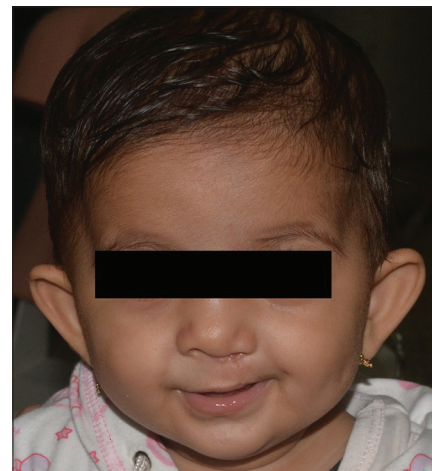

Figure 12: Follow up at 2 years

speech, and no difficulties while eating. While PNAME has proved to be advantageous, cleft lip and palate rehabilitation ultimately depends on the collaboration between various disciplines from birth till adulthood. The ideal timing and sequence of care are vital to rehabilitative success. PNAME should ideally be initiated during the first 3–4 months after birth as the high amount of circulating maternal estrogen causes an increase in the hyaluronic acid present in the fetal cartilage, rendering it plastic and ideal for active molding.^[8] Caregivers were instructed to make sure the baby wore the appliance continuously and was only removed for daily sanitization. The appliance enables breastfeeding as it promotes suckling and also aids nasal breathing as the cleft is blocked by the appliance. A tissue conditioner was applied selectively on the greater and lesser clefted alveolar segments such that the force was directed inward on the greater segment and outward on the lesser segment that would result in the approximation of the alveolar tissue.^[9] Controlled movement of the alveolar segments was simultaneously obtained by the tight positioning of the lip segments with a tape combined with the appliance.^[10] Only when the alveolar cleft width reduced to a size that was less than 6 mm, the nasal stent was added and nasal cartilage molding began. Any attempt to correct this deformity before reducing the cleft size may result in an undesirable increase in the lateral alar wall.^[5] Post-surgery, an additional external nasal stent can be given for 1 year to improve the nasal morphology and maintain the nasal correction if needed.^[11] PNAME therapy requires the full cooperation of the parents/caregivers. In such cases, primary care physicians play a vital role in bridging the gap between the family and cleft care team by educating, guiding, and assisting the caregivers and also providing prompt diagnosis and referral, and maintaining the overall health care of the patient.

Conclusion

PNAME appliance can be used effectively to successfully reduce the size of the clefted alveolar segments. It is a simple adjunctive therapy that aids in improving the contour of the columella-philtrum for better post-surgical success.

Ethical approval

All identifying features were duly covered hence, patient approval was not needed.

Financial support and sponsorship

Nil.

Conflicts of interest

There are no conflicts of interest.

References

1. Patel D, Goyal R, Puri T. Presurgical nasoalveolar moulding- An adjunct to facilitate surgical repair in infants with cleft lip and palate. *Mod Plast Surg* 2013;3:34-42.
2. Allam E, Stone C. Cleft lip and palate: Etiology, epidemiology, preventive and interventional strategies. *Anat Physiol* 2014;4:1-6.
3. Cubitt JJ, Hodges AM, Van Lierde KM, Swan MC. Global variation in cleft palate repairs: An analysis of 352,191 primary cleft repairs in low- to higher-middle-income countries. *Cleft Palate Craniofac J* 2014;51:553-6.
4. Roberts-Thomson K. Epidemiology of cleft lip and palate. In: Peres MA, Antunes JLF, Watt RG, Editors. *Oral Epidemiology. Textbooks in Contemporary Dentistry*. Cham: Springer; 2021.
5. Grayson BH, Cutting CB, Santiago PE, Brecht LE. Presurgical nasoalveolar moulding in infants with cleft lip and palate. *Cleft Palate Craniofac J* 1999;36:486-98.
6. Dinh TTN, Van Nguyen D, Dien VHA, Dong TK. Effectiveness of presurgical nasoalveolar molding appliance in infants with complete unilateral cleft lip and palate. *Cleft Palate Craniofac J* 2021;10556656211026493. doi: 10.1177/10556656211026493. Online ahead of print.
7. Thakur S, Jishad C, Singhal P, Chauhan D. Comparative clinical evaluation of modified and conventional Grayson's presurgical nasoalveolar molding technique in infants with complete unilateral cleft lip and palate. *Dent Res J (Isfahan)* 2021;18:68.
8. Matuso K, Hirose T. Preoperative nonsurgical overcorrection of cleft lip nasal deformity. *B J Plast Surg* 1991;44:5-11.
9. Sarin SP, Parkhedkar RD, Deshpande SS, Patil PG, Kothe S. Presurgical nasoalveolar moulding for a unilateral midfacial cleft: A case report. *J Indian Prosthodont Soc* 2010;10:67-70.
10. Doruk C, Kiliç B. Extraoral nasal molding in a newborn with unilateral cleft lip and palate: A case report. *Cleft Palate Craniofac J* 2005;42:699-702.
11. Bhutiani N, Tripathi T, Verma M, Bhandari PS, Rai P. Assessment of treatment outcome of presurgical nasoalveolar molding in patients with cleft lip and palate and its postsurgical stability. *Cleft Palate Craniofac J* 2020;57:700-6.