



ORIGINAL ARTICLE

# Analysis of association between periodontal disease and thickness of maxillary sinus mucosa using cone beam computed tomography – A retrospective study

Vrushali N. Lathiya, Abhay P. Kolte\*, Rajashri A. Kolte, Dhawal R. Mody

Department of Periodontics and Implantology, VSPM Dental College and Research Centre, Nagpur, India

Received 27 July 2018; revised 9 October 2018; accepted 7 November 2018  
Available online 13 November 2018

## KEYWORDS

Cone beam computed tomography;  
Maxillary sinus;  
Mucosal thickening;  
Periodontitis

**Abstract Purpose:** The aim of this study was to measure the thickness of the mucous membrane lining the maxillary sinus and to correlate this thickening of the Schneiderian membrane with the presence or absence of periodontal bone loss of adjacent teeth, by using cone beam computed tomography (CBCT).

**Methods:** 255 CBCT images were analyzed of which 140 images were selected for the study. Based upon the absence of radiographic periodontal bone loss and presence of 50% or more bone loss, these CBCT images were respectively divided into two groups *viz.* Group I (Healthy) and Group II (Periodontal Bone Loss Group), each group consisting of 70 images each. The thickening of the mucous membrane lining of the floor of maxillary sinus was measured at four points on the CBCT. These points were the anterior most point of the thickened mucosa, the posterior most point of the thickened mucosa, at the midpoint (MP) (point midway between the anterior most and the posterior most point) and the point of maximum thickness of the sinus mucosa.

**Results:** The age adjusted mean thickness for Group II was significantly greater than that of Group I ( $p < 0.001$ ) at all the four points. There was a positive association between presence of periodontal bone loss and thickening of Schneiderian membrane at the floor of the sinus. There was a weak positive association between age and mucosal thickness. Of all the four points measured, the maximum correlation between age and thickness was obtained at MP ( $r = 0.171$ ), which was statistically significant ( $p = 0.044$ ).

\* Corresponding author at: Department of Periodontics and Implantology, VSPM Dental College and Research Centre, Digdoh Hills, Hingna Road, Nagpur 440017, India.

E-mail address: [drabhaypkolte@gmail.com](mailto:drabhaypkolte@gmail.com) (A.P. Kolte).

Peer review under responsibility of King Saud University.



Production and hosting by Elsevier

*Conclusion:* The present study concluded that there is a positive association between presence of periodontal bone loss and thickening of mucosa of floor of maxillary sinus and also exhibited a weak positive relation between age and increased mucosal thickening of floor of maxillary sinus.  
© 2018 The Authors. Production and hosting by Elsevier B.V. on behalf of King Saud University. This is an open access article under the CC BY-NC-ND license (<http://creativecommons.org/licenses/by-nc-nd/4.0/>).

## 1. Introduction

Maxillary sinuses are pneumatic cavities in the maxillary bone. They are lined with a thin respiratory mucous membrane referred to as the Schneiderian membrane which adheres firmly to the periosteum and is about 0.8–1 mm thick (Goller-Bulut et al., 2015). Mucosal thickening of the maxillary sinuses is a routine radiographic finding detected in an otherwise asymptomatic individual with a prevalence ranging from 8% to 29% (Soikkonen and Ainamo, 1995). An infection or allergic process like chronic sinusitis may cause the inflammation of the mucosa, making it visible on the radiograph.

A relationship between maxillary sinusitis and dental infection has been established by many preliminary investigations (Brook, 2009). Maloney and Doku, (1968) have attributed 10–12% of the cases of maxillary sinusitis to odontogenic infections. Violation of the Schneiderian membrane due to conditions like periapical abscesses, periodontal diseases, dental trauma, tooth extractions or placement of dental implants tend to increase the risk of maxillary sinusitis (Bolger et al., 1991). Periodontitis has been thought to be one of the principal causes of odontogenic maxillary sinusitis and the subsequent thickening of the sinus mucosa associated with it (Goller-Bulut et al., 2015; Ren et al., 2015).

Bauer, (1943) explained that the vicinity of the roots of the maxillary molars and premolars to the maxillary sinus, as well as the multitudinous anastomoses between the blood and lymph vessels in the apical region of the teeth and the corresponding blood vessels of the sinus mucosa, are mechanisms that favor the spread of odontogenic infections to the maxillary sinus. The porosity of the maxillary bone permits the diffusion of pathogens and their pathogenic products to the sinus floor.

Panoramic radiography, Water's projection and intraoral radiography have been routinely used in the imaging of the maxillary sinus in dentistry (Burke et al., 1994). However, the complex anatomy of the oral and maxillofacial region causes the superimposition of the important anatomical features and are therefore difficult to visualize (Lofthag-Hansen et al., 2007). Moreover, the literature indicates that conventional radiographic techniques are less accurate in detection and measurement of the mucosal thickening of the maxillary sinus (Soikkonen and Ainamo, 1995; Vallo et al., 2010).

On the other hand, Computed tomography (CT), the gold standard for sinus diagnosis, allows the visualisation of both hard and soft tissues by providing multiple sections through the sinus at different planes. The recent introduction of Cone Beam Computed Tomography (CBCT) in dental and maxillofacial imaging, facilitates the diagnosis of delicate structures in multiplanar reconstructions. A lower radiation dose and an isotropic volume resolution gives an advantage to CBCT over other radiographic techniques in being extensively used for imaging of paranasal sinuses (Ruprecht and Lam, 2009). Therefore, the aim of this study was to measure the thickness

of the mucous membrane lining the maxillary sinus and to correlate this thickening of the Schneiderian membrane with the presence or absence of periodontal bone loss of adjacent teeth, by using CBCT.

## 2. Materials and methods

### 2.1. Study samples

The Institutional Ethics Committee of our institute, approved this study protocol which complied with the Helsinki Declaration of 2013. The CBCT images<sup>1</sup> taken from July 2015 to June 2016, were examined retrospectively. The individuals underwent CBCT imaging for dental treatment purposes, mostly for dental implant treatment planning. The CBCT images were included in the study only if they fulfilled the following criteria: (1) Good quality images with the occlusal plane parallel to the floor. (2) Presence of more than one maxillary posterior tooth below the sinus. (3) No signs of air fluid levels and complete opacification of the sinus indicating acute sinusitis. (4) No signs of a pulpal pathology or periapical infections like periapical radiolucency and root canal fillings.

Two hundred and fifty five CBCT images were analyzed. A total of 140 images were included in the study and based on the presence or absence of periodontal bone loss, the CBCT images of the patients were divided into two groups consisting of 70 images each. The data was anonymised and de-identified before the analysis.

Group I: Healthy group, showing no evidence of bone loss i.e. the level of alveolar crest not more than 2 mm below the CEJ (Hausmann et al., 1991).

Group II: Periodontal Bone Loss Group, showing moderate to severe periodontal bone loss as indicated by more than 50% bone loss of the total root length.

### 2.2. Analysis of CBCT images

Commercially available CBCT software<sup>2</sup> was used for the image analysis. The panoramic and cross-sectional views of the maxilla were reconstructed for evaluation and measurement. All images were reconstructed and measured by two examiners at two time points (VL and AK). For calibration and evaluation of intra- and inter-examiner reproducibility, twenty CBCT measurements were evaluated twice by each examiner.

### 2.3. Assessment of mucosal thickening

The floor of the maxillary sinus was traced in the area of mucosal thickness and this determined the total length of the

<sup>1</sup> KODAK 9000C 3D Extraoral Imaging System, Carestream Health, Inc, France.

<sup>2</sup> CS 3D Imaging Software, Carestream Dental, France.

thickened mucosa. Mucosal thickening was considered to be present when the thickness of the sinus mucosa was  $\geq 2$  mm. The thickness was measured in millimeters from the floor of the sinus to the highest border of the mucosa.

The thickness of the mucosal lining of the maxillary sinus was measured at the following points:

1. The anterior most point of the thickened mucosa (AP)
2. The posterior most point of the thickened mucosa (PP).
3. At the midpoint (a point midway between the anterior most and the posterior most point) (MP).
4. At the point of maximum thickness of the sinus mucosa (MT).

#### 2.4. Statistical analyses

The measurements of mucosal thickness at different points of maxillary sinus were obtained in Group I and Group II images, along with demographic parameters like age and gender of the respective patients. The intra- and inter-examiner reproducibility was determined using intra-class correlation coefficient (ICC). Descriptive statistics like mean and standard deviation were obtained for the dependent variable, i.e. thickness, at all the points for two groups and compared using *t*-test for independent samples. Since age acts as a covariate for the dependent variable, analysis of covariance (ANCOVA) was performed to adjust thickness measurements at all points, and the age-adjusted means were obtained. The age-adjusted mean thickness at each point was compared between the two groups. Further, the age-adjusted receiver operating characteristic curve (ROC) analysis was performed to obtain cut-off values for thickness measurement at each point. The primary interest behind cut-offs was to know the likely mucosal thickness in patients with periodontal bone loss at different points of maxillary sinus. All the analyses were performed using SPSS version 20.0.<sup>3</sup> Statistical differences with a *p* value  $< 0.05$  were considered significant.

### 3. Results

The CBCT images of 140 maxillary sinuses of 140 individuals (94 males and 46 females) were evaluated. Table 1 provides the descriptive statistics for demographic characteristics of subjects in the two groups. The mean age of subjects in Healthy group was  $39.90 \pm 9.27$  years, while that of Periodontal Bone Loss group was  $45.27 \pm 8.47$  years. The difference between two means was statistically significant ( $p = 0.0005$ ), indicating age bias between groups. To eliminate the bias of gender an equal number of males and females (47 males and 23 females) were included in each group. The gender difference was statistically insignificant between two groups ( $p = 0.999$ ).

The intra-examiner reproducibility coefficient (ICC) for the measurement of mucosal thickening of maxillary sinus was 0.99 (VL) and 0.97 (AK) for the two examiners, indicating excellent reproducibility of measurements. Also, the inter-examiner reproducibility coefficient obtained for first set of measurements resulted into a coefficient value of 0.967, indicating excellent agreement between the two examiners with regards to the measurements of maxillary sinus mucosal thickening.

**Table 1** Descriptive statistics for demographic characteristics of subjects included in two groups.

Parameter		Healthy Group (n = 70)	Periodontal Bone Loss Group (n = 70)
Age (years) [Mean $\pm$ SD]		39.90 $\pm$ 9.27	45.27 $\pm$ 8.47
Gender [No. (%)]	Male	47 (67.14%)	47 (67.14%)
	Female	23 (32.86%)	23 (32.86%)

The mean and standard deviations of the maxillary sinus mucosal thickness at AP, PP, MP and MT points of measurement for samples in Healthy and Periodontal Bone Loss group were obtained. There was a huge variation in the thicknesses measured at these four points in both the groups. In the Healthy group, the measurement of thickness ranged from (0.2–4.1 mm) at AP, (0.3–3.9 mm) at PP, (0.2–4.4 mm) at MP and (0.6–4.7 mm) at MT respectively. In the Periodontal Bone Loss group, the range was (1.1–4.6 mm), (1.1–4.8 mm), (1.7–5.6 mm), (2.4–5.8 mm) at these four points, respectively.

As the mean age in Periodontal Bone Loss group was significantly higher than Healthy group, and considering its relevance in bone loss, the mucosal thickness at each point was adjusted with age using analysis of covariance. Table 2 reveals the comparison of mucosal thickness at different points between the healthy and patients with periodontal bone loss, both unadjusted as well as adjusted with respect to age. The adjusted mean thickness for Periodontal Bone Loss group was significantly higher than that of Healthy group ( $p < 0.001$ ) at all the four points of maxillary sinus. However, the difference in the means of the total length of the thickened maxillary sinus mucous membrane between the two groups was statistically insignificant ( $p = 0.164$ ). The correlation of age-adjusted thickness at different points with age was obtained as shown through scatter plots in Fig. 1. At all the points, a weak positive relationship was noticed between age and mucosal thickness. Maximum correlation was obtained at midpoint ( $r = 0.171$ ,  $r$  is the correlation coefficient measuring the strength and direction of a linear relationship on the scatter plot), which was statistically significant ( $p = 0.044$ ). At AP, PP and at the MT, the relationships were insignificant.

Mucosal thickness at different points was analysed independently to obtain cut-off values that best discriminate Healthy and Periodontal Bone Loss groups. The age-adjusted Receiver Operating Characteristic Curve (ROC) analysis was performed; wherein adjusted mucosal thickness values at each point were considered for ROC analysis (Fig. 2). Table 3 shows the adjusted cut-off value of thickness at each point. The Area under the Curve (AUC) for cut-off values was 0.8 or above indicating their good classification ability. The validity of each cut-off point was expressed in terms of sensitivity and specificity. The sensitivity values close to 90% at each point suggests that patients with radiographic evidence of periodontal bone loss are more likely to have mucosal thickness value beyond the adjusted cut-offs of respective points. However, lower specificity values around 60% suggests that normal patients need not necessarily have mucosal thickness below the adjusted cut-offs of respective points.

<sup>3</sup> IBM Corp.

**Table 2** Comparison of mucosal thickness at different points of maxillary sinus between Healthy and Periodontal Bone Loss group.

Points of measurement	Groups	n	Unadjusted (in mm)		Adjusted <sup>†</sup> (in mm)		p-Value <sup>*</sup>
			Mean	SD	Mean	SD	
Anterior point (AP)	Healthy	70	1.06	1.07	1.29	0.84	< 0.001
	Periodontal Bone Loss	70	2.52	1.18	2.28	0.84	
Posterior point (PP)	Healthy	70	1.04	1.02	1.26	0.83	< 0.001
	Periodontal Bone Loss	70	2.56	1.18	2.34	0.83	
Midpoint (MP)	Healthy	70	1.31	1.24	1.58	0.92	< 0.001
	Periodontal Bone Loss	70	3.13	1.26	2.86	0.92	
Maximum Thickness (MT)	Healthy	70	1.91	1.79	2.18	1.16	< 0.001
	Periodontal Bone Loss	70	3.65	1.03	3.37	1.16	
Length	Healthy	70	29.02	2.84	28.97	2.76	0.164
	Periodontal Bone Loss	70	29.59	2.53	29.64	2.76	

All values presented as mean  $\pm$  SD (range).

<sup>†</sup> Parameters adjusted with respect to age.

<sup>\*</sup> Obtained using *t*-test for independent samples for adjusted values

#### 4. Discussion

In the present study we analysed the association of presence of radiographic evidence of periodontal bone loss on the mucosal membrane thickening of maxillary sinus and found a relatively increased mucosal thickening in the patients having presence of radiographic evidence of periodontal bone loss as compared to those without. This indicates a positive role of periodontitis in increasing the thickness of Schneiderian membrane further substantiating the possible role of periodontal disease in causing odontogenic sinusitis. These findings concur with those reported by [Phothikhun et al., \(2012\)](#) and [Sheikhi et al., \(2014\)](#) who have also reported mucosal thickening to be commonly associated with periodontal bone loss.

The presence of deep periodontal pockets may evoke a local reaction in the sinus mucosa, such as oedema, round cell infiltration, fibrosis or cystic degeneration, which might be a possible mechanism for the thickening of sinus mucosa. This response occurs even in those cases where a fairly thick layer of bone is separating the apical area of the infected tooth from the maxillary sinus ([Bauer, 1943](#)). Maxillary sinusitis resulting from periodontal infections can be caused by two mechanisms: either the spread of microorganisms and their products as well as the cytokines via the several anastomoses between the blood and lymph vessels in the apical region of the tooth and the corresponding vessels in the sinus mucosal lining or by a direct spread of infection through the porous maxillary bone and the supporting tissues. The findings of [Engström et al., \(1988\)](#) and [Falk et al., \(1986\)](#) further substantiates this relationship. They observed a resolution in the thickening of the maxillary sinus mucosa in response to a successful periodontal therapy.

In the present study, CBCT images have been used to assess the mucosal thickness of maxillary sinus while maximum of the previous studies have used conventional radiographic techniques ([Soikkonen and Ainamo, 1995](#); [Vallo et al., 2010](#)).

However, conventional radiographic techniques have numerous drawbacks like super-imposition of images and a greater rate of false negative results as compared to the three dimensional CBCT which has a higher resolution and provides a more accurate assessment of the mucosal thickening

([Brüllmann et al., 2012](#)). [Cymerman et al. \(2011\)](#) evaluated the use of CBCT for measurements of thickness of sinus membrane in a case series and concluded that the thickening of the sinus membrane was identified four times more often with CBCT than with conventional periapical radiographs, and that it was useful for differentiating the etiologic cause and extension of oral pathology with respect to maxillary sinus. Also, the differentiation between mucosal thickening due to infection, cysts and tumors can be difficult with two dimensional radiographic techniques ([Baykara et al., 2002](#)).

In the literature, limited data exists on the assessment of the dimensions and changes of the Schneiderian membrane based on radiographic imaging. Moreover, the location of the measurement point also varies greatly. Additionally, varied classifications and measurement scales have been utilized for the evaluation of maximum thickness ([Patel et al., 1996](#); [Rak et al., 1991](#)). For a detailed and meticulous understanding, the mucosal thickness of the maxillary sinus in our study was assessed at four different points *viz.* at AP, PP, MP and at the point of maximum thickness of the sinus mucosa. Also the total length of the thickened band was measured.

We considered the mucosal thickness of  $> 2$  mm as an evidence of mucosal thickening. This was consistent with previous reports ([Janner et al., 2011](#); [Lu et al., 2012](#); [Maillet et al., 2011](#)). The mean mucosal thickness in the Periodontal Bone Loss Group was found to be greater than 2 mm even after the covariate age was adjusted ([Table 2](#)). Different authors have considered different cut offs for the diagnosis of mucosal thickening. [Vallo et al. \(2010\)](#) defined the presence of mucosal thickening when there was a thick radiopaque band of 3–6 mm along the wall of the sinus. [Soikkonen and Ainamo \(1995\)](#) considered the presence of diffuse radiopacities along the wall of the sinus as an evidence of mucosal thickening. However, these studies have used two dimensional panoramic radiographs which does not allow the precise measurements of sinus mucosal thickness. Furthermore, early reports of thickness measurements revealed difficulty in visualizing normal mucoperiosteal structures in the paranasal sinuses through CT ([Min et al., 1994](#)) or MRI ([Patel et al., 1996](#)). The mucosa could be seen only at a thickness of 2 mm or above, and therefore historically 2 mm was considered a reliable threshold for pathological

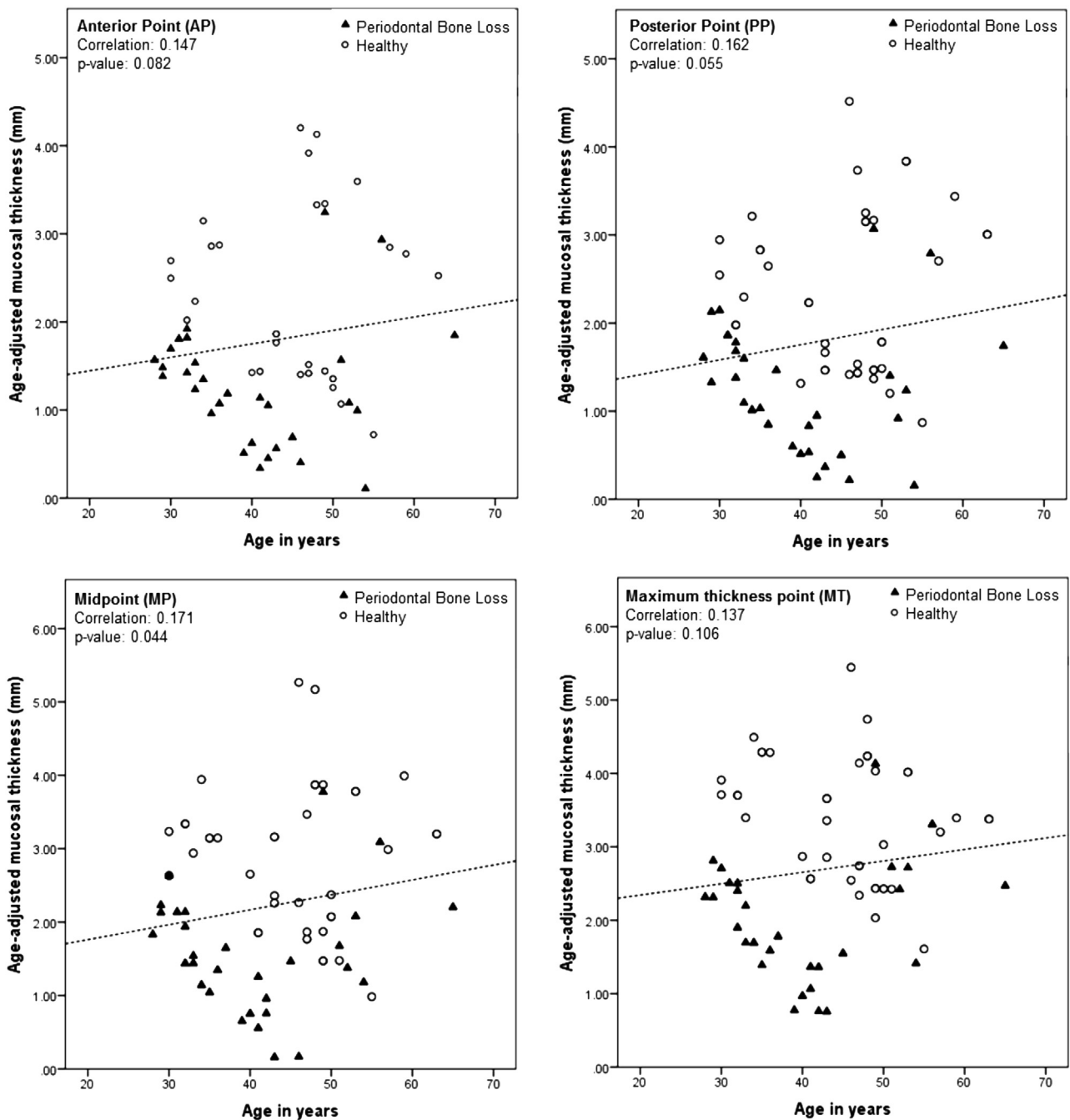
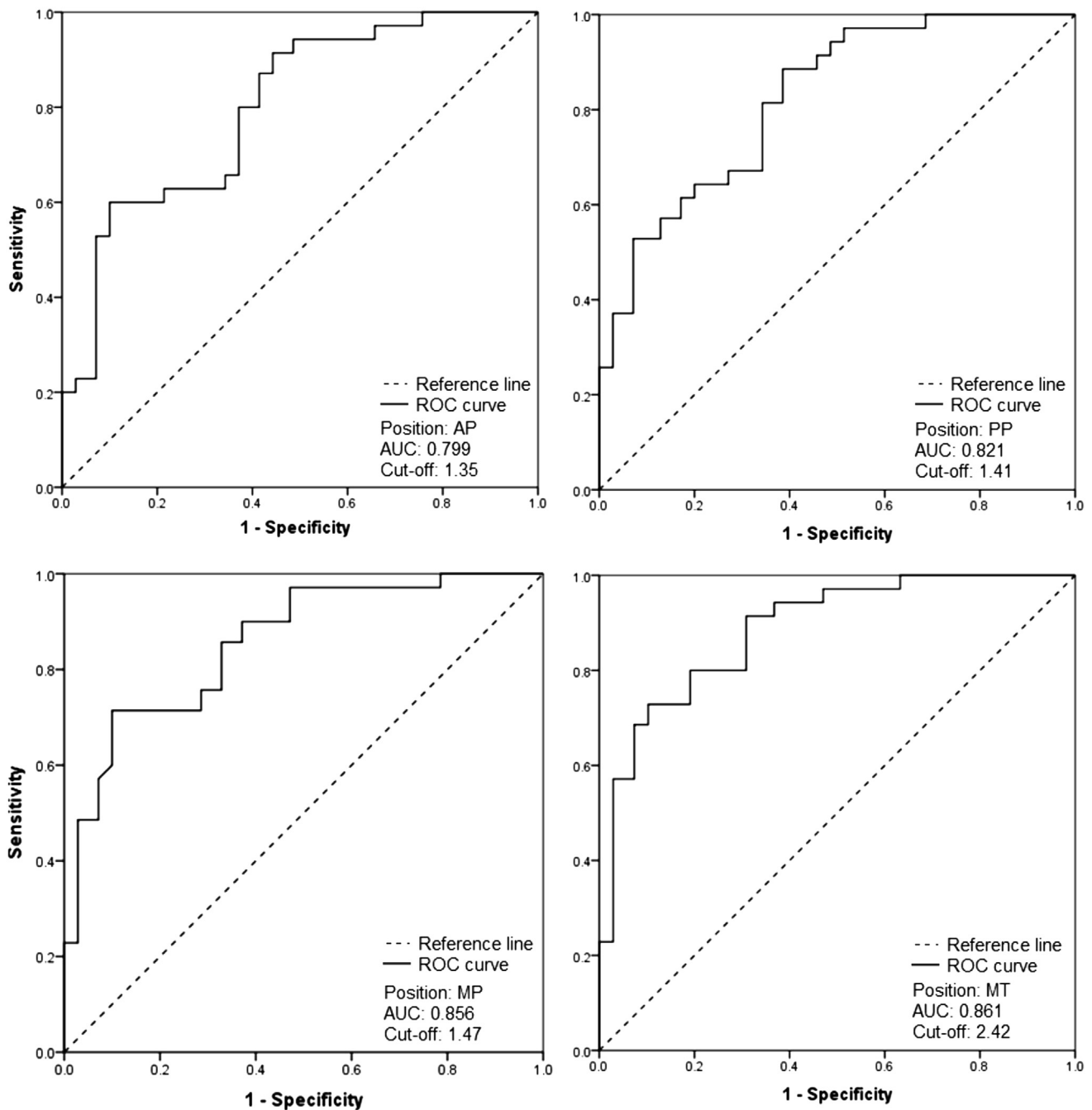


Fig. 1 Scatter plots showing relation of mucosal thickness with age (unadjusted) at different points.

mucosal swelling (Cagici et al., 2009). Previous reports have shown a positive relation of age and mucosal thickening (Iwabuchi et al., 1997; Vallo et al., 2010). In this study also, the effect of age on the maxillary mucosal thickness was investigated. As the mean age in Periodontal Bone Loss group was significantly higher than Healthy group, and considering its relevance in bone loss, the mucosal thickness at each point was adjusted with age, even though only a weak but yet positive correlation was noticed between age and mucosal thickness. The results of our study are in consistency with the study of Goller-Bulut et al. (2015) who evaluated CBCT

images of 410 maxillary sinuses and found that the prevalence of maxillary sinus mucosal thickening increased with an increase in age. The study done by Phothikhun et al., (2012) also showed results similar to our study; they found a higher prevalence of mucosal thickening among males and older age group (> 49-year-old). The weaker association obtained in our study can be attributed to a smaller sample size in comparison with other similar studies.

As the age advances, the process of pneumatization increases and favours the spread of infection through the porous maxillary bone to the maxillary sinus consequently causing



**Fig. 2** Age-adjusted Receiver Operating Characteristic Curve (ROC) plots for mucosal thickness at different points of maxillary sinus. AP-The anterior most point of the thickened mucosa. PP-The posterior most point of the thickened mucosa. MP-At the midpoint. (A point midway between the anterior most and the posterior most point) MT-At the point of maximum thickness of the sinus mucosa (MT). AUC – Area Under the Curve.

mucosal thickening. On the contrary, [Rege et al., \(2012\)](#) detected no influence of age on the occurrence of sinus abnormalities.

Currently, there is no consensus on the mucosal thickness that can be considered as pathologic. We tried to obtain an optimal cut off, of the sinus mucosal thickness at every point considered in our study. Our observations highlighted that sinus mucosal thickness at every point when below the cut off value, patient would be showing no evidence of bone loss

and adjudged as healthy. Patients having mucosal thickness above the cut off value would likely demonstrate periodontal bone loss. To the best of our knowledge, no data exists in the literature that has tried to devise such a threshold. However, the clinical significance of this value is required to be used with caution as future studies need to be conducted to validate this finding.

The findings of this study have significant clinical implications as well. Periodontal infection is an etiologic factor for

**Table 3** Validation parameters for unadjusted and adjusted cut-offs of mucosal thickness at different points of maxillary sinus.

Validation parameters		Points of measurement			
		Anterior Point	Posterior Point	Midpoint	Maximum Thickness
<b>Unadjusted</b>	AUC <sup>‡</sup>	0.882	0.886	0.871	0.837
	[95% CI] <sup>§</sup>	[0.819–0.944]	[0.824–0.947]	[0.808–0.935]	[0.762–0.912]
	p-Value	< 0.001	< 0.001	< 0.001	< 0.001
	Cut-off	1.05	1.05	1.85	2.1
	Sensitivity	100%	100%	92.90%	100%
	Specificity	79%	76%	78%	76%
<b>Adjusted<sup>  </sup></b>	AUC <sup>‡</sup>	0.799	0.821	0.856	0.861
	[95% CI] <sup>§</sup>	[0.726–0.871]	[0.755–0.888]	[0.794–0.917]	[0.798–0.923]
	p-Value	< 0.001	< 0.001	< 0.001	< 0.001
	Cut-off	<b>1.35</b>	<b>1.41</b>	<b>1.47</b>	<b>2.42</b>
	Sensitivity	91%	88.60%	97.10%	91.40%
	Specificity	56%	61.40%	53%	67.10%

All values presented as mean  $\pm$  SD (range).

<sup>‡</sup> AUC (Area under the Curve).

<sup>§</sup> CI (Confidence Interval).

<sup>||</sup> ROC (Receiver Operating Characteristic Curve) obtained after adjusting with age.

maxillary sinusitis which along with pulpal infections is the major cause of sinus mucosal thickening in symptomatic individuals. Mucosal thickening of maxillary sinus and other sinus pathologies may pose problems when a sinus augmentation surgery is planned. A sinus augmentation procedure done in cases of insufficient height of maxillary residual alveolar ridge may result in the obstruction of the sinus and also impair its drainage (Carmeli et al., 2011). Thus, periodontal treatment should be performed before sinus augmentation surgery to reduce the inflammation of the sinus mucosa. Also this, study establishes an association between age and increased mucosal thickening. Most of the patients requiring dental implant therapy and sinus augmentation are edentulous and demonstrate increased pneumatization and the associated increased mucosal thickening.

The present study does have certain confines and limits. Since this study retrospectively analysed the CBCT images, a clinical examination and recording a proper history about periodontal and sinus problems was not possible. Thus the presence of sinus pathologies in these patients cannot be completely ruled out although the images showing air fluid levels were excluded. In the present study, the patients with periapical infection or showing signs of endodontic treatment were excluded, however the clinical data regarding the patient's periodontal condition could not be obtained. Hence, possibility of a periodontal treatment and regression of mucosal thickening cannot be completely ignored. So a precise strength of association of periodontal infection and mucosal thickening cannot be very well ascertained.

## 5. Conclusion

From the finding of this study, it can be concluded that there is an association between radiographic presence of periodontal bone loss and maxillary sinus mucosal thickening. Also, there is positive relation between age and increased mucosal thickening of maxillary sinus. The retrospective design of this study presents with certain limitations and requires the design of

further prospective studies to establish an exact causal relationship.

## Ethical statement

The work has been approved by the appropriate ethical committees of VSPM Dental College and Research Centre, Nagpur.

## Informed consent

All the subjects participating in the clinical trial were informed about the procedure and materials to be used and a written informed consent was obtained.

## Acknowledgments

None.

## Funding

This research did not receive any specific grant from funding agencies in the public, commercial, or not-for-profit sectors.

## Declarations of interest

None.

## Conflict of interest

None.

## References

Baykara, M., Erdoğan, N., Öztürk, M., Erkan, M., 2002. Maxillary sinus aplasia. *Turk. J. Med. Sci.* 32, 273–275.

- Bauer, W.H., 1943. Maxillary sinusitis of dental origin. *Am. J. Orthod. Oral Surg.* 29 (3), B133–B151.
- Bolger, W.E., Butzin, C.A., Parsons, D.S., 1991. Paranasal sinus bony anatomic variations and mucosal abnormalities: CT analysis for endoscopic sinus surgery. *Laryngoscope.* 101 (1 Pt 1), 56–64.
- Brook, I., 2009. Sinusitis. *Periodontology* 2000 49 (1), 126–139.
- Brüllmann, D.D., Schmidtmann, I., Hornstein, S., Schulze, R.K., 2012. Correlation of cone beam computed tomography (CBCT) findings in the maxillary sinus with dental diagnoses: a retrospective cross-sectional study. *Clin. Oral. Investig.* 16 (4), 1023–1029.
- Burke, T., Guertler, A., Timmons, J., 1994. Comparison of sinus x-rays with computed tomography scans in acute sinusitis. *Acad. Emerg. Med.* 1 (3), 235–239.
- Cagici, C.A., Yilmazer, C., Hurcan, C., Ozer, C., Ozer, F., 2009. Appropriate interslice gap for screening coronal paranasal sinus tomography for mucosal thickening. *Eur. Arch. Otorhinolaryngol.* 266, 519–525.
- Carmeli, G., Artzi, Z., Kozlovsky, A., Segev, Y., Landsberg, R., 2011. Antral computerized tomography pre-operative evaluation: relationship between mucosal thickening and maxillary sinus function. *Clin. Oral. Implants.* 22 (1), 78–82.
- Cymerman, J.J., Cymerman, D.H., O'Dwyer, R.S., 2011. Evaluation of odontogenic maxillary sinusitis using cone-beam computed tomography: three case reports. *J. Endod.* 37 (10), 1465–1469.
- Engström, H., Chamberlain, D., Kiger, R., Egelberg, J., 1988. Radiographic evaluation of the effect of initial periodontal therapy on thickness of the maxillary sinus mucosa. *J. Periodontol.* 59 (9), 604–608.
- Falk, H., Ericson, S., Hugoson, A., 1986. The effects of periodontal treatment on mucous membrane thickening in the maxillary sinus. *J. Clin. Periodontol.* 13 (3), 217–222.
- Goller-Bulut, D., Sekerci, A.E., Köse, E., Sisman, Y., 2015. Cone beam computed tomographic analysis of maxillary premolars and molars to detect the relationship between periapical and marginal bone loss and mucosal thickness of maxillary sinus. *Med. Oral Pathol. Oral Cir. Bucal.* 20 (5), e572–e579.
- Hausmann, E., Allen, K., Clerehugh, V., 1991. What alveolar crest level on a bite-wing radiograph represents bone loss? *J. Periodontol.* 62 (9), 570–572.
- Iwabuchi, Y., Hanamure, Y., Ueno, K., Fukuda, K., Furuta, S., 1997. Clinical significance of asymptomatic sinus abnormalities on magnetic resonance imaging. *Arch. Otolaryngol. Head Neck Surg.* 123 (6), 602–604.
- Janner, S.F., Caversaccio, M., Dubach, P., Sendi, P., Buser, D., Bornstein, M.M., 2011. Characteristics and dimensions of the Schneiderian membrane: a radiographic analysis using cone beam computed tomography in patients referred for dental implant surgery in posterior maxilla. *Clin. Oral. Implants Res.* 22 (12), 1446–1453.
- Lofthag-Hansen, S., Huuonen, S., Gröndahl, K., Gröndahl, H.G., 2007. Limited cone-beam CT and intraoral radiography for the diagnosis of periapical pathology. *Oral Surg. Oral Med. Oral Pathol. Oral Radiol. Endod.* 103 (1), 114–119.
- Lu, Y., Liu, Z., Zhang, L., Zhou, X., Zheng, Q., Duan, X., Zheng, G., Wang, H., Huang, D., 2012. Associations between maxillary sinus mucosal thickening and apical periodontitis using cone-beam computed tomography scanning: a retrospective study. *J. Endod.* 38 (8), 1069–1074.
- Maillet, M., Bowles, W.R., McClanahan, S.L., John, M.T., Ahmad, M., 2011. Cone-beam computed tomography evaluation of maxillary sinusitis. *J. Endod.* 37 (6), 753–757.
- Maloney, P.L., Doku, H.C., 1968. Maxillary sinusitis of odontogenic origin. *J. Can. Dent. Assoc.* 34 (11), 591–603.
- Min, Y.G., Lee, J.W., Shin, J.S., 1994. Radiologic assessment of diseased mucosa of the maxillary sinus after functional endoscopic sinus surgery. *Acta Otolaryngol.* 114 (6), 657–662.
- Patel, K., Chavda, S.V., Violaris, N., Pahor, A.L., 1996. Incidental paranasal sinus inflammatory changes in a British population. *J. Periodontol.* 119 (7), 649–651.
- Phothikhun, S., Suphanantachat, S., Chuenchompoonut, V., Nisapakultorn, K., 2012. Cone-beam computed tomographic evidence of the association between periodontal bone loss and mucosal thickening of the maxillary sinus. *J. Periodontol.* 83 (5), 557–564.
- Rak, K.M., Newell II, J.D., Yakes, W.F., Damiano, M.A., Luethke, J. M., 1991. Paranasal sinuses on MR images of the brain: significance of mucosal thickening. *AJR. Am. J. Roentgenol.* 156 (2), 381–384.
- Ren, S., Zhao, H., Liu, J., Wang, Q., Pan, Y., 2015. Significance of maxillary sinus mucosal thickening in patients with periodontal disease. *Int. Dent. J.* 65 (6), 303–310.
- Rege, I.C., Sousa, T.O., Leles, C.R., Mendonça, E.F., 2012. Occurrence of maxillary sinus abnormalities detected by cone beam CT in asymptomatic patients. *BMC. Oral Health.* 12, 30.
- Ruprecht, A., Lam, E.W.N., 2009. Paranasal sinuses. In: White, S.C., Pharoah, M.J. (Eds.), *Oral Radiology: Principles and Interpretation.* sixth ed. Mosby Elsevier, St. Louis, pp. 506–525.
- Sheikhi, M., Pozve, N.J., Khorrami, L., 2014. Using cone beam computed tomography to detect the relationship between the periodontal bone loss and mucosal thickening of the maxillary sinus. *Dent. Res. J. (Isfahan)* 11 (4), 495–501.
- Soikkonen, K., Ainamo, A., 1995. Radiographic maxillary sinus findings in the elderly. *Oral Surg. Oral Med. Oral Pathol. Oral Radiol. Endod.* 80 (4), 487–491.
- Vallo, J., Suominen-Taipale, L., Huuonen, S., Soikkonen, K., Norblad, A., 2010. Prevalence of mucosal abnormalities of the maxillary sinus and their relationship to dental disease in panoramic radiography: results from the Health 2000 Health Examination Survey. *Oral Surg. Oral Med. Oral Pathol. Oral Radiol. Endod.* 109 (3), e80–e87.