

Reelevating the Mastectomy Flap: A Safe Technique for Improving Nipple-Areolar Complex Malposition after Nipple-Sparing Mastectomy

Shuhao Zhang, MD
Nadia P. Blanchet, MD

Summary: Nipple-areolar complex (NAC) malposition is one of the most common complications following nipple-sparing mastectomy with implant-based reconstruction. To maximize perfusion to the NAC, traditional methods of correcting NAC malposition limit undermining below the NAC. We demonstrate a series of cases in which improvement of NAC malposition was safely performed by reelevating the NAC and mastectomy flap to allow redraping of the soft tissue envelope over the implant and the overlying capsule. Thirty-four patients were identified in a span over 4 years where 44 NACs were repositioned using this method. There was zero incidence of postoperative ischemia or necrosis of the NAC or mastectomy flaps. There was noticeable improvement in the NAC position on the breast mound. Relevation of the mastectomy skin flap to correct malposition of the NAC after nipple-sparing mastectomy is a safe and effective option, avoids additional scars, and can be performed more than once to further improve positioning of the NAC. (*Plast Reconstr Surg Glob Open* 2017;5:e1426; doi: 10.1097/GOX.0000000000001426; Published online 24 July 2017.)

INTRODUCTION

Over the past decade, nipple-sparing mastectomy (NSM) has become increasingly popular.¹ Patients who undergo NSM and breast reconstruction report superior aesthetic results, improved psychosocial well-being, self-image, and sexual function.² Nonetheless, NSM is not without risks and a common complication related to NSM with reconstruction is malposition of the nipple-areolar complex (NAC). This disfiguring complication is present in up to 75% of NSM with implant-based reconstruction.³ The NAC is most commonly displaced laterally and superiorly due to relative skin excess of the medial and inferior breast. A number of operative strategies to manage NAC malposition after implant-based reconstruction have been published,³⁻⁸ all of which involve making additional breast scars. We propose a simple method to reposition the displaced NAC after implant-based reconstruction by reelevating and redraping the entire mastectomy flap.

This avoids a new visible breast incision and is safe and effective for mild-to-moderate malposition.

PATIENTS AND METHODS

This study was conducted in adherence with the guiding principles of the Declaration of Helsinki. A retrospective chart review of all patients undergoing NAC relocation in the senior author's practice from January 2012 through June 2016 was performed. All patients who had partial submuscular, acellular dermal matrix (ADM)-assisted implant-based reconstruction were included. All patients had signed informed consent for nipple repositioning as part of staged implant-based breast reconstruction. Patient demographics, breast/NAC characteristics, surgical outcomes, and complications were recorded.

Operative Technique

NAC reposition is performed simultaneously with tissue expander or implant exchange. After prosthetic exchange is completed and the capsule is closed, the subcutaneous plane is infiltrated with tumescent solution of dilute lidocaine with epinephrine. A variable area of mastectomy flap is elevated away from the underlying pectoralis muscle/

From the Division of Plastic Surgery, Virginia Commonwealth University, Richmond, Virginia.

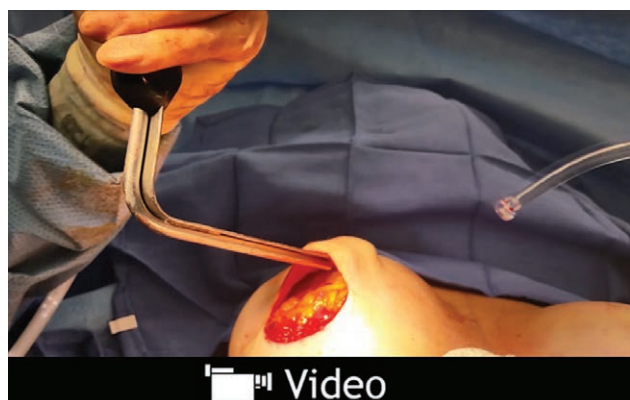Received for publication February 16, 2017; accepted June 9, 2017.

Copyright © 2017 The Authors. Published by Wolters Kluwer Health, Inc. on behalf of The American Society of Plastic Surgeons. This is an open-access article distributed under the terms of the Creative Commons Attribution-Non Commercial-No Derivatives License 4.0 (CCBY-NC-ND), where it is permissible to download and share the work provided it is properly cited. The work cannot be changed in any way or used commercially without permission from the journal.

DOI: 10.1097/GOX.0000000000001426

Disclosure: The authors have no financial interest to declare in relation to the content of this article. The Article Processing Charge was paid for by the authors.

Supplemental digital content is available for this article. Clickable URL citations appear in the text.



Video Graphic 1. Relevation of the mastectomy flap to allow mobilization of the NAC over the breast mound. This video is available in the “Related Videos” section of the Full-Text article on PRSGlobalOpen.com or available at <http://links.lww.com/PRSGO/A489>.

ADM (see video, Supplemental Digital Content 1, which demonstrates relevation of the mastectomy flap to allow mobilization of the NAC over the breast mound. This video is available in the “Related Videos” section of the Full-Text article on PRSGlobalOpen.com or available at <http://links.lww.com/PRSGO/A489>). The previous mastectomy incision or a new inframammary fold incision is used (Fig. 1). Patients early in the series underwent limited undermining, but as the safety of the technique became evident, undermining became more extensive. Currently, we prefer to reelevate the entire mastectomy flap as greater mobility is gained with more undermining. The deep surface of the mastectomy flap and NAC are then sutured to the pectoralis muscle or ADM at the desired location with multiple 2-0 absorbable quilting sutures at 2–3 cm intervals. The skin incision is closed without drains. In the last 15 patients, NAC position change was measured preoperatively and intraoperatively with the patient in the sitting position.

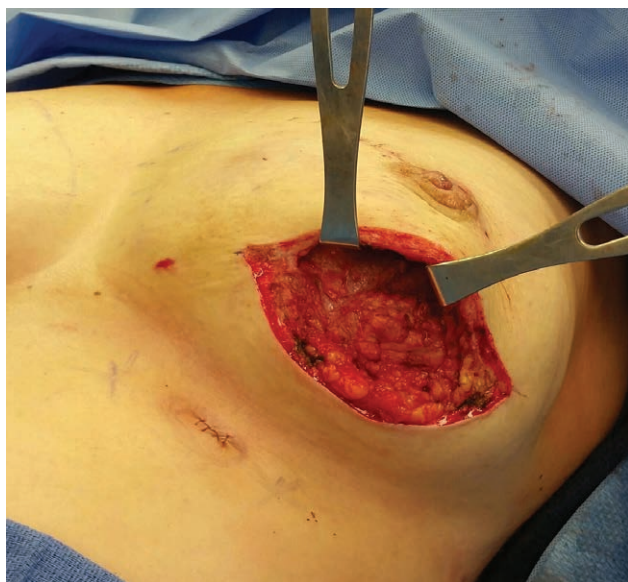


Fig. 1. Elevation of the mastectomy flap from underlying muscle and ADM. A new IMF incision is used to allow wider undermining.

Table 1. Patient and Mastectomy Flap/NAC Characteristics

Patient Characteristics (N = 34)	Value (%)
Age (y)	
Mean	46.3
Range	27–65
BMI (kg/m ²)	
< 25	21
25–30	10
> 30	3
ASA class	
1	31
2	3
Comorbidities	
Hypertension	5
Smoker	0
Mastectomy flap/NAC characteristics (N = 44)	
Incision type for flap elevation	
IMF	33 (75)
Other (Periareolar, lateral radial, supra areolar)	11 (25)
Number of NAC with prior delay procedure	19 (43.2)
Reconstructive surgery before NAC reposition	
Immediate tissue expander placement	40
Delayed tissue expander placement	3
Immediate direct to implant placement	1
Time between initial reconstruction and NAC reposition (d)	114.9
Final implant volume (cc)	
Mean	451
Range	255–650
Previous radiation	1

RESULTS

Thirty-four patients were identified, undergoing reposition of 44 NACs (Table 1). Except for 1 patient who underwent direct to implant reconstruction, all patients underwent 2-stage tissue expander to implant reconstruction. All patients were nonsmokers. Average time between nipple reposition and previous surgery was 115 days. Thirty-three breasts used inframammary fold incisions for nipple reposition and 37 had the entire flap undermined. Nineteen breasts had undergone a nipple delay procedure 2–3 weeks before mastectomy, as described by Jensen et al.⁹ and others.¹⁰

Mean follow-up was 421 days. There was no incidence of postoperative ischemia, necrosis, or seroma formation. No implants required explantation. In cases where NAC movement was measured, NAC could be reliably moved up to 3 cm. Two patients underwent this procedure twice, 1 year apart, to readvance 2 NACs. The aesthetic outcome was significantly improved in most patients (Figs. 2, 3), except in breasts with severe malposition or inelastic skin due to radiation.

DISCUSSION

NAC malposition can be a disappointing complication following NSM. Nonetheless, accurate nipple placement is sometimes elusive. The NAC position is dependent on the interaction between the skin envelope and the underlying breast mound and often migrates unpredictably during healing and the expansion process.

Other authors have described treatment of NAC malposition using crescentic mastopexy, transposition flaps, and free nipple grafts, all of which involve additional visible incisions.^{3–8} Our method treats the skin envelope as a

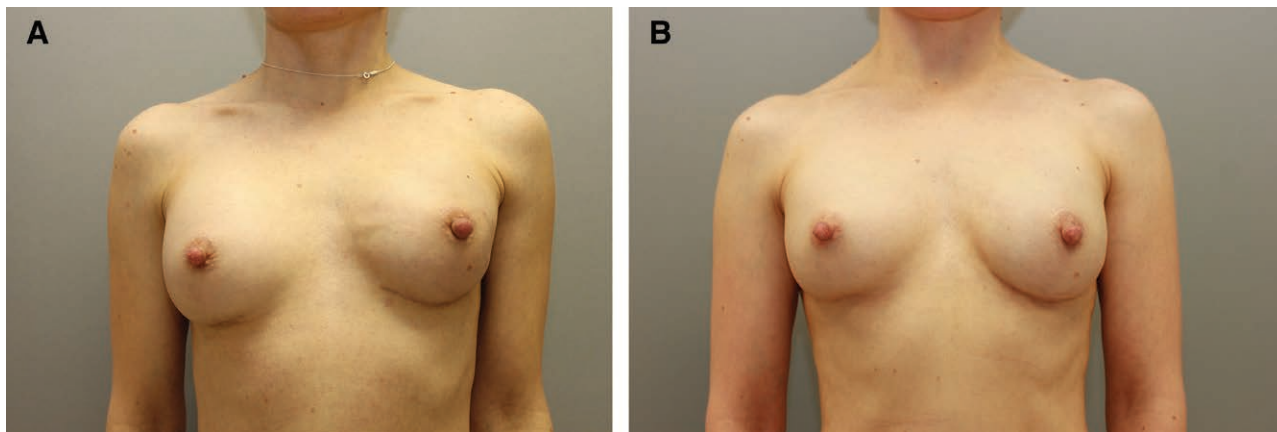


Fig. 2. A, A 41-year-old woman 2 months after left NSM with immediate tissue expander and ADM placement, with moderate (2 cm) superolateral displacement of the left NAC. B, Twelve (12) months after undergoing left tissue expander exchange for permanent gel implants with repositioning of left NAC by elevation of entire mastectomy flap. Note the left implant now sits lower in the breast, which typically raises the NAC position. By reelevating and redraping the left mastectomy flap, an improved NAC position can be achieved.

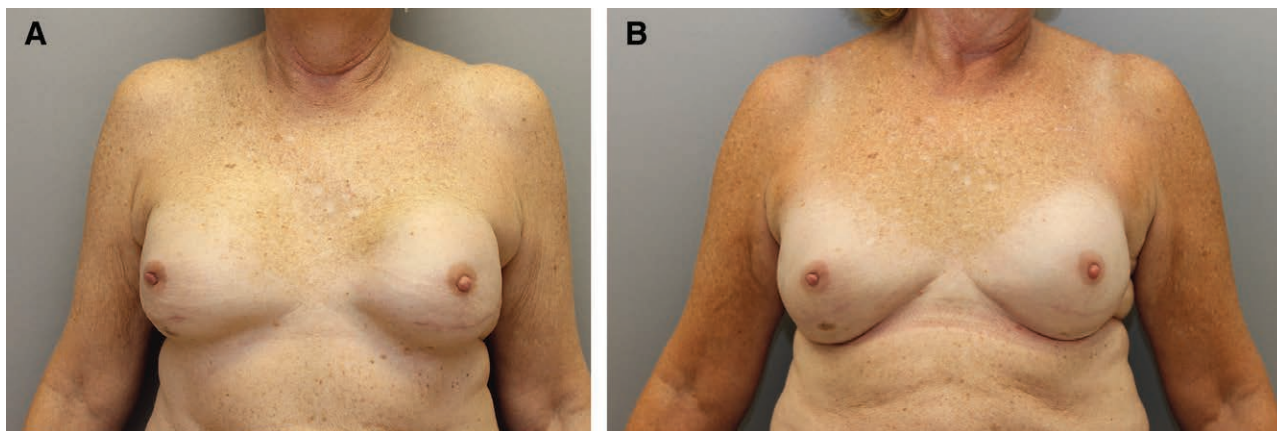


Fig. 3. A, A 65-year-old woman 3 months after bilateral NSM with immediate tissue expander and ADM placement, with severe (3 cm) lateral displacement of the right NAC. B, Twelve (12) months after undergoing left tissue expander exchange for permanent gel implants with repositioning of right NAC by elevation of entire mastectomy flap.

distinct, mobile entity and moves the NAC by redraping the mastectomy flap over the breast mound. This is typically performed during the second stage of a prosthesis-based reconstruction. In our experience, the NAC could be reliably moved up to 3 cm when the entire mastectomy flap was undermined. Repeating this procedure to gain more mobilization of the mastectomy flap is safe. Not all patients will obtain satisfactory results from this procedure. Those who have severe malposition or inelastic skin will need other alternative procedures. In mild-to-moderate cases of NAC malposition, this is a reasonable first-line procedure, since “no bridges are burned.”

Previous authors may have avoided undermining the NAC due to concerns regarding perfusion.⁶ We reason that a surgical “delay” is performed during the initial mastectomy, essentially creating a well-vascularized flap. The senior author works with 5 different oncologic breast surgeons with variable mastectomy skin flap thickness, so we believe this is universally safe. Reelevating the skin envelope several months postmastectomy does not result in

further ischemic insult. None of the breasts in our series developed ischemia or necrosis after undergoing NAC and mastectomy flap relevation. A formal nipple delay procedure had been performed 2–3 weeks before the mastectomy in 19 breasts. Although the rate of initial mastectomy flap necrosis postmastectomy was lower in the delay group, NAC repositioning did not cause ischemia in any of the breasts that did not initially undergo a nipple delay.

This study’s shortcomings are its retrospective, non-randomized nature and the variable degree of mastectomy flap elevation. Although this technique has not yet been performed in prepectoral implant reconstructions, we believe it is applicable as well.

CONCLUSIONS

Reelevating the mastectomy skin flap to correct malposition of the NAC after NSM is a safe and effective option and avoids additional scars. It allows redraping of the skin envelope over the implant and does not threaten perfusion of the nipple areolar complex. Its utility is limited by

the elasticity and availability of the skin envelope in the opposite vector of desired NAC movement. This technique can reliably move the NAC up to 3 cm and can be repeated to further improve NAC position.

Nadia P. Blanchet, MD

9210 Forest Hill Ave
Richmond
VA 23235

E-mail: nadia@nadiablanchet.com

REFERENCES

1. Sisco M, Kyrillos AM, Lapin BR, et al. Trends and variation in the use of nipple-sparing mastectomy for breast cancer in the United States. *Breast Cancer Res Treat.* 2016;160:111–120.
2. Metcalfe KA, Cil TD, Semple JL, et al. Long-term psychosocial functioning in women with bilateral prophylactic mastectomy: does preservation of the nipple-areolar complex make a difference? *Ann Surg Oncol.* 2015;22:3324–3330.
3. Spear SL, Albino FP, Al-Attar A. Repairing the high-riding nipple with reciprocal transposition flaps. *Plast Reconstr Surg.* 2013;131:687–689.
4. Spear SL, Albino FP, Al-Attar A. Classification and management of the postoperative, high-riding nipple. *Plast Reconstr Surg.* 2013;131:1413–1421.
5. Takayanagi S. Transposition of the malpositioned nipple-areola complex in breast reconstruction with implants. *Aesthetic Plast Surg.* 2010;34:52–58.
6. Small K, Kelly KM, Swistel A, et al. Surgical treatment of nipple malposition in nipple-sparing mastectomy device-based reconstruction. *Plast Reconstr Surg.* 2014;133:1053–1062.
7. Mohmand H, Naasan A. Double U-plasty for correction of geometric malposition of the nipple-areola complex. *Plast Reconstr Surg.* 2002;109:2019–2022.
8. Frenkiel BA, Pacifico MD, Ritz M, et al. A solution to the high-riding nipple-areola complex. *Aesthetic Plast Surg.* 2010;34:525–527.
9. Jensen JA, Lin JH, Kapoor N, et al. Surgical delay of the nipple-areolar complex: a powerful technique to maximize nipple viability following nipple-sparing mastectomy. *Ann Surg Oncol.* 2012;19:3171–3176.
10. Martinovic ME, Pellicane JV, Blanchet NP. Surgical delay of the nipple-areolar complex in high-risk nipple-sparing mastectomy reconstruction. *Plast Reconstr Surg Glob Open.* 2016;4:e760.