

Review

***Eustrongylides* (Nematoda: Dioctophymatidae): epizootology and special characteristics of the development biology**

S. L. HONCHAROV^{1*}, N. M. SOROKA¹, M. V. GALAT¹, O. V. ZHURENKO¹, A. I. DUBOVYI², V. I. DZHMLI³

¹*Faculty of Veterinary Medicine, National University of Life and Environmental Sciences of Ukraine, Kyiv, Ukraine,
*E-mail: sergeyvet85@ukr.net; ²Department of Molecular Medicine and Pathology, The University of Auckland, Auckland, New Zealand;
³Faculty of Veterinary Medicine, Bila Tserkva National Agrarian University, Bila Tserkva, Ukraine

Article info

Received January 14, 2022
Accepted May 19, 2022

Summary

Eustrongylides spp. are the nematodes from the Dioctophymatidae family which are potentially dangerous for the mammal's health. The first aim of the present research is to describe the biology, developmental characteristics and epizootology of the *Eustrongylides* spp. nematode. Eustrongylidosis is a parasitic disease commonly occurring in the countries with temperate continental, tropical and subtropical climate. The *Eustrongylides* spp. parasites are biohelminths with a complex life cycle. The development of the nematodes takes place in the aquatic environment and includes a vast range of intermediate, accidental and definitive hosts. It has also been reported in humans. The second aim of the research is to describe the clinical and pathomorphological changes in organs and tissues of the infected animals, and influence of biotic and abiotic factors on formation of the natural centers of spreading of eustrongylidosis; diagnostics of eustrongylidosis.

Keywords: *Eustrongylides*; eustrongylidosis; intermediate hosts; accidental hosts; definitive hosts

Introduction

Eustrongylides spp. are the nematodes of the *Eustrongylides* genus, substantiated by Jägerskiöld in 1909 on the material from the glandular stomach of ciconiiformes and waterfowls brought by the Swedish expedition from Egypt and Sudan (Jägerskiöld, 1909). Jägerskiöld concluded that this group of nematodes was not studied well enough. The author substantiated the new genus of *Eustrongylides* and several new species within the new genus based on the further research of the materials from Berlin, Genoa, Greifswald, and Vienna museums, and helminths received from birds in Finland (Jägerskiöld, 1909). Parasitic larvae on fish are often mentioned in the works of Rudolphi (Rudolphi, 1802). But their exact nature and localization of the mature nematodes in the glandular stomach of fish-eating birds was studied in 1868 by Leuckart (Leuckart, 1868).

According to Jägerskiöld, the new genus called *Eustrongylides* included 7 species: *E. tubifex*, *E. elegans*, *E. papillosus*, *E. africanus*, *E. excisus*, *E. ignotus*, *E. perpapillatus*, the four latter were the newly described ones. All these species, except *E. africanus*, were known to the scientists before, but they were mentioned under different names: *Strongylus* (Rudolphi, 1802), *Eustrongylus* (Diesing, 1861) and *Tropidocerca* (Linstow, 1899) (Rudolphi, 1802; Diesing, 1861; Linstow, 1899). Cram substantiated *E. mergorum* in 1927, which contradicted the species *E. elegans*, as it was later proven to be the same species (Cram, 1927). In 1960s, according to some researchers, the genus *Eustrongylides* included 14 species, mostly found in China, Japan and Australia. *E. gadopsis*, *E. galaxias*, *E. wenrichi* were described only on the basis of the larvae taken from fish, which did not allow considering their systematic position as substantiated (Yamaguti, 1961; Karmanova, 1968).

* – corresponding author

At the same time the data of modern molecular taxonomy based on molecular-genetic research methods show that there are only 3 species considered basic for the *Eustrongylides* genus: *E. tubifex*, *E. excisus* and *E. ignotus*. The rest are subpopulations of the above-mentioned groups that function in particular biotopes.

***Eustrongylides* nematode morphology**

According to the description made by Karmanova, the *Eustrongylides* nematode larvae have the following anatomic morphological characteristics: the body of the parasite widens to the middle and narrows to the ends; the head end is not swollen, the cuticle has no spines and its transverse outline becomes more noticeable at the ends (Karmanova, 1968). The mouth cavity is surrounded by 12 to 18 oral papillae, usually arranged in rows, 6 papillae in each, of which 2 are lateral and 4 submedian (Fig. 1). The parasite has 2 rows of lateral papillae located along the body. The esophagus is wide, it widens the most at the back part. The copulatory bursa of the male is muscular, thick-walled, and has no rib-like formations. The spicule is long and needle-shaped. The tail end of the female's body is blunt with no clearly defined tail. The vulva is close to the terminally located anus. The development involves fish. According to Karmanova, 1968, this genus is characterized by sex dimorphism: narrow-ended larvae develop into males and wide-ended – into females.

Biological characteristics of the *Eustrongylides* nematodes

Distribution of Eustrongylides spp.

Eustrongylidosis is registered on every continent except Antarctica and in every climate zone except arctic and subarctic zones. It has been noticed that the parasite is much more widespread in the temperate continental, tropical and subtropical climate zones (Barros *et al.*, 2010; Aydođdu *et al.*, 2011; Mierzejewska *et al.*, 2012). This parasite is biologically likely to form the centers of infection near the aquatic areas, mostly in fresh waters, less likely in saline waters and estuaries (Spalding & Forrester, 1993).

The nematode can invade not only fish and fish-eating birds. The accidental hosts can be amphibians (frogs), reptiles (turtles, snakes, caimans), mammals (rabbits, laboratory rats, seals), and humans. (Sloboda *et al.*, 2010; Švažas *et al.*, 2011; Shukerova *et al.*, 2011; Eberhard & Ruiz-Tiben, 2014; Ljubojevica *et al.*, 2015).

Life cycle of Eustrongylides spp.

The first detailed study of the *Eustrongylides* nematodes' biology was done by Ciurea. In 1924, while working in the Romanian part of the Danube delta, the author discovered nematode larvae in fishes: *Barbus fluviatilis*, *Lota lota*, *Perca fluviatilis*, *Esox Lucius*, and detected parasites in the glandular wall of cormorants (*Phala-*

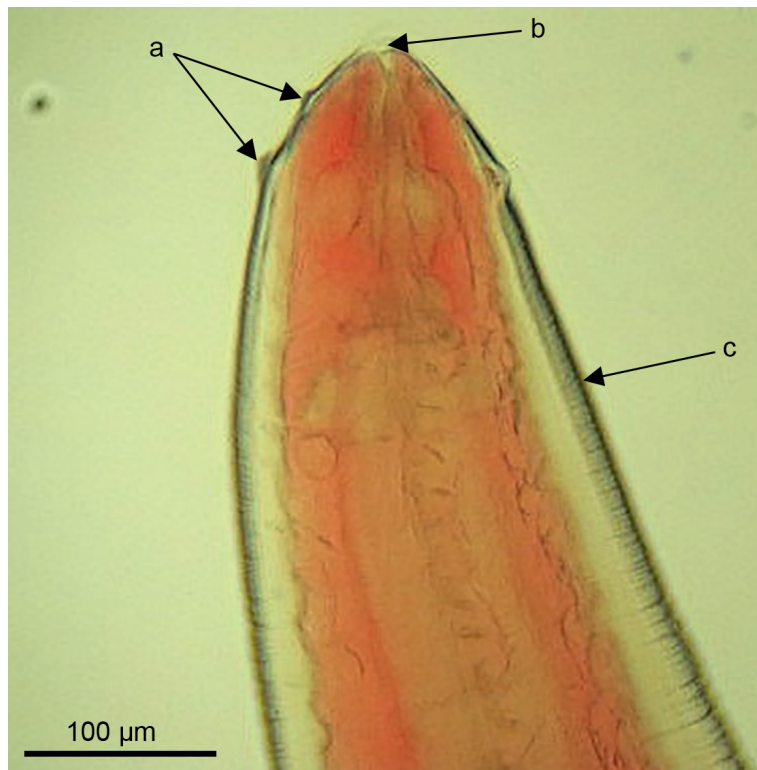


Fig. 1. The head end of *Eustrongylides excisus* larvae (L4). Visualised two rows of papillae (a) around the oral opening (b). The body of the larva is visibly striated (c) (Goncharov *et al.*, 2018)

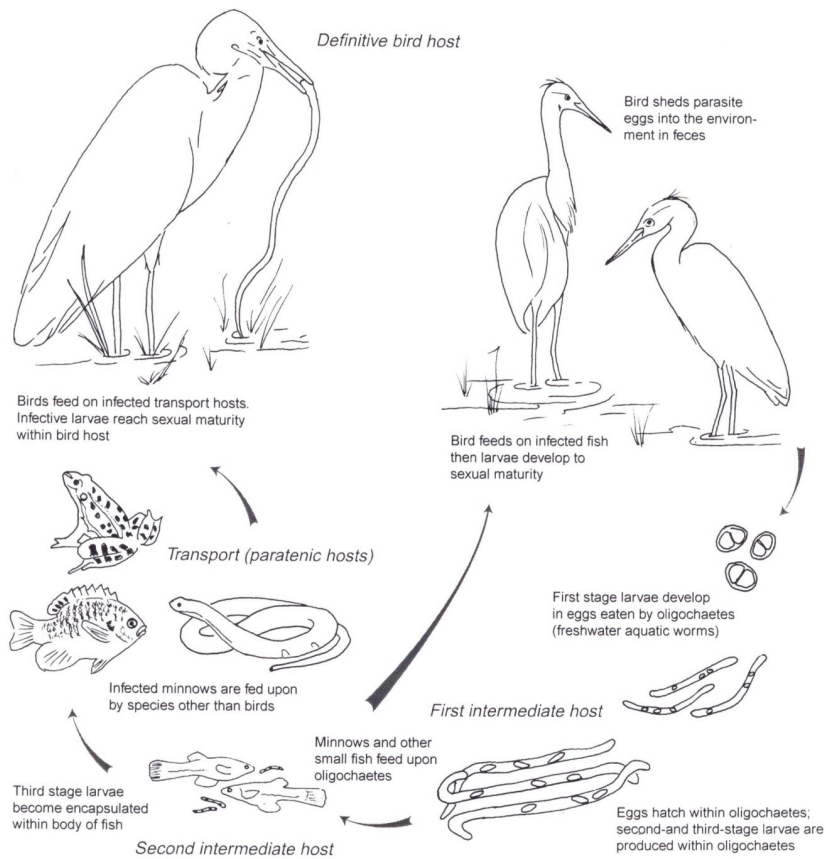


Fig. 2. Life cycle of *Eustrongylides* sp. (Cole, 1999)

crocorax carbo and *P. pygmaeus*), caught in the Danube and Dniester waters. This was the first attempt to model the life cycle of the *Eustrongylides* nematodes (Ciurea, 1924).

The life cycle of the nematodes of the *Eustrongylides* genus is directly connected to fresh, saline and estuarial aquatic areas where intermediate (oligochaetes, fishes), accidental (reptiles, amphibians, mammals) and definitive (fish-eating birds) hosts develop. (Lichtenfels & Stroup; 1985).

The *Eustrongylides* nematode has a complicated development cycle. The main definitive hosts are fish-eating birds of the *Ciconiiformes* family: *Anseriformes*, *Gaviiformes* and *Pelecaniformes*. Intermediate hosts are water oligochaetes of the *Tubificidae* and *Lumbriculidae* families, as well as *Limnodrilus* spp., in which the first and the second larval periods of the parasites are taking place. The second intermediate hosts are plankton-eating and bottom-feeding fishes. Predatory fishes, such as *Sander lucioperca*, *Perca fluviatilis*, *Esox lucius* can also be involved in the *E. excisus* development cycle (fig. 2) (Measures, 1988; Novakov *et al.*, 2013). *Eustrongylides* nematode development cycle starts when eggs reach the organism of the first intermediate host – oligochaete – where the larvae get out of the egg shell under the influence of

gastric juice and move to the lumen of the gastrointestinal tract (Karmanova, 1968; Paperna, 1974). Then the larva perforates the intestine wall moving to the host's body cavity. After reaching the first stage the larvae penetrate into the abdominal blood vessel of the oligochaete and with the blood flow they are transferred to the head end where they shed twice. After the second shed the larva becomes able to invade the second intermediate host – a fish (Karmanova, 1968).

Under the appropriate conditions the second shed is over after 82-85 days in the oligochaete's body. But depending on the conditions of the environment, the development of the *Eustrongylides* nematode in the oligochaete's body from the eggs getting into the organism with the invasive larva to formation of the larva able to invade the second intermediate host can take up to 5-5.5 months (Karmanova, 1968; Paperna, 1974).

The second intermediate host – fish – is infected during swallowing the infected oligochaetes. Larvae that enter the gastrointestinal tract of fish perforate the intestinal wall and enter the extraintestinal space (Karmanova, 1968). Then the *Eustrongylides* nematode larvae migrate along the body. The migrated larvae can locate in the muscular tissue, hepatopancreas and gonads of the fish. As

larvae stay in the body of the fish, they shed twice, reaching the 3rd and the 4th stages of development (L3 and L4). The larval stages of the nematode can be in the body of the first and second intermediate hosts – oligochaetes and freshwater fishes – for more than a year (Cole, 1999).

Definitive hosts – fish-eating birds- are infected as they eat fish infected with the *Eustrongylides* nematode larvae (Karmanova, 1968; Paperna, 1974). The parasite locates in the stomach wall 3-5 hours after getting into the organism. The larva becomes mature in the body of the fish-eating bird as a definitive host within 10-15 days after invading. But the parasite starts laying eggs after 20-25 days or later (Karmanova, 1968; Paperna, 1974).

Getting into the waters with the feces of the fish-eating birds, the eggs are able to maintain their vital function for 2-2.5 years (Bjeli-Cabrilo *et al*, 2013). The maturing of the eggs in an outer environment takes 19-21 days, 2-5 days later they reach the invasive stage. The free larvae have no living potential in an outer environment and they die fast (Karmanova, 1968). Thus the most appropriate conditions in an outer environment for the eggs is water saturated with organic material with a temperature 20 – 30° C (Cole, 1999).

Characteristics of the parasitic activity of the *Eustrongylides* spp. in other animal species

The Acipenseridae fishes can serve not only as an intermediate host but as a definitive one because the *Eustrongylides* spp. nematode is able to reach maturity in their bodies, which was confirmed by presence of eggs in the observed helminths (Mikailov *et al.*, 1992).

The parasitic activity of the *E. ignotus* (L4) was found in the gastrointestinal tract of the eels *Synbranchus bengalensis* in Eastern Java. The intestine wall was often perforated by the parasites (Subekti *et al.*, 2020). Similar results were gained observing the population of eels *Monopterus albus* in the waters of Banyuwangi regency, Eastern Java. The *E. ignotus* larvae were found in extraintestinal space, gastrointestinal tract, gonads and muscular tissue (Bakti *et al.*, 2020).

Two ways of invading *Gambusia holbrooki* were experimentally defined. The first one is direct infection of the fish with the eggs containing the *E. ignotus* larvae on the first stage of development. The eggs received from the uterus of the mature parasite were cultivated in the appropriate temperature for 17-28 days. The parasite reached stage L4 84 – 105 days after infection. The second way is invading the fish as they consume the infected oligochaetes in the bodies of which the larvae get mature for 35 – 77 days. In the organism of the fish the parasite reached the 4th stage for 127 – 184 days. In case of the first way the parasite reaches stage 4 78 – 156 days faster than in the second case (Coyner *et al.*, 2002). *Eustrongylides* nematode can use certain reptiles and amphibians as accidental hosts: lake frog (*Rana ridibunda*), giant toad (*Rhinella marina*), Eurasian marsh frog (*Pelophylax ridibundus*),

and water snake (*Natrix tasselata*). In the organisms of the latter the agent on the stages 3 and 4 localizes under the serous membrane of the gastrointestinal tract (Sloboda *et al.*, 2010; Melo *et al.*, 2015; León-Régagnon, 2019). As the garden snakes (*Thamnophis sirtalis parieyalis*) are fed with banded killifish (*Fundulus diaphanus*) selected in the natural environment and leopard toads (*Rana pipiens*), grown in the laboratory conditions and infected with the *Eustrongylides* spp. nematode it was noticed that the snakes got eustrongylidosis and died (Lichtenfels & Lavies, 1976).

To define the circle of the additional hosts of the *E. ignotus* nematode received from *Fundulus diaphanus*, Brant *et al.* conducted numerous experiments including fishes, frogs, alligators and turtles (Brant, 1944). In particular, *E. ignotus* larvae were injected orally, under the skin or directly into the intestine. In most experimentally infected predatory fishes the larvae were discovered in the body cavities alive. Carp was the only species of fishes researched not to have gotten eustrongylidosis. Grown frogs *Rana pipiens* were fed with 2 larvae each. As a result, the larvae were found in the abdominal wall muscles, on the tongue, mesentery, ovaries and in the thickness of the lymph node. The larvae taken from the amphibian *Necturus maculosus* were placed under the skin of *Amphiuma tridactylum* and found 42 days later: one was under the skin, the other one – in the thickness of muscles near the injection spot. 81 days after the oral infection of the *Alligator mississippiensis* the autopsy revealed parasites on the abdominal wall and under the pleura. Three (*Chrysemis picta*) turtles were successfully orally infected. The pathological anatomic autopsy revealed the larvae in the body cavities and on the stomach wall. Attempts to invade snakes *Thamnophis sirtalis* were unsuccessful (Brant, 1944). The results show that the circle of the accidental hosts for *E. ignotus* is wide.

Distribution of the larvae *Eustrongylides* in the host organism

Honcharov (2017b) studied the distribution of the *Eustrongylides* larvae in the organisms of predatory fishes in case of natural infection. They distributed as follows: 42.7 % of the total amount of parasites were found in the muscles of the costal wall; 26.8 % were in the ventral part of the abdominal muscles; 12.3 % located in the spinal muscles; 3.1 % - in gonads, 6.4 % - in hepatopancreas, 2.3 % freely located in the abdominal cavity and 1.9 % were found on the walls of the hollow organs. Franceschini *et al.*, (2022) studied the distribution of *Eustrongylides* spp. nematodes in the muscle tissues of perch (*Perca fluviatilis*), largemouth black bass (*Micropterus salmoides*), big-scale sand smelt (*Atherina boyeri*), eel (*Anguilla anguilla*), black bullhead (*Ictalurus melas*), carp (*Cyprinus carpio*), tench (*Tinca tinca*), and pumpkinseed sunfish (*Lepomis gibbosus*) in the Trasimeno Lake, Central Italy. There was no individual specific of distribution found in the studied fishes (pike, sander and perch), which is quite similar to the research of Menconi *et al.* (2020), observing *Lepomis gibbosus*, *Micropterus salmoides* and *Perca fluviatilis* in case of eustrongylidosis.

Helminths localizing directly in tissues cause the most noticeable reaction in the host's organisms, which can be shown as capsule formation, melanizing and isolation of the parasite (Feist & Longshaw, 2008; Mitchell *et al.*, 2009). Capsule formation is a key point of the parasitic strategy of balancing the dynamic parasite-host system for the parasite to avoid death or elimination (Parker *et al.*, 2009). Histology showed that regardless of the capsule formation the parasites can keep their body structure well inside the capsule. That is why fishes can be rated acceptable as the intermediate hosts for the *Eustrongylides* nematode larvae, as formation of the tight capsule as well as surrounding inflammatory processes have no impact on the vital activity of the parasites (Guagliardo *et al.*, 2019).

The parasites form half-transparent capsules in the fish's body on the inner side of the abdominal wall. The capsules are formed of the host's tissues and the *Eustrongylides* nematode larvae localize in them forming a tight spiral or a wide ring. As the cysts with the parasites were cut, a small amount of yellowish liquid was noticed flowing out. This liquid is an element of the inflammatory exudate and the product of the nematode larvae's vital activity. During the migration in the host's body specific cysts are formed in hollow organs (stomach and intestine). The larvae located freely on the walls of the inner organs are able to continue migrating until they reach tissues and organs that allow them to use the host's material for the formation of specific capsules where they shed one more time (Honcharov, 2017b).

Overstreet *et al.* (2003) report that *E. excisus* larvae can be located freely or form a spiral in the thickness of muscles. Larvae enlarge the abdominal cavity, but the fish's death is registered relatively seldom. The death can be caused by spreading of the secondary infection in the organism of the infected fish.

Eustrongylides larvae can leave the capsule and migrate in the muscular tissue in case of high temperatures of the environment, which can cause hemorrhages in the muscular tissue (Cooper *et al.*, 1978).

Histology showed that even in case of chronic inflammation the microanatomy of the parasites is kept within the capsule. Thus fishes are acceptable as hosts for the *Eustrongylides* larvae, as the capsule formation has no impact on the parasite's vital activity (Guagliardo *et al.*, 2019).

In the case of infestation of *Galaxias maculatus* by *E. ignotus* larvae, which are quite large compared to the body of the fish, physical and metabolic overload is likely to take place. This fact decreases a chance of the fish being caught by the fish-eating birds to realize the parasitic strategy (Coyner *et al.*, 2001).

Physiology of the *Eustrongylides* spp.

Observing physical and biochemical characteristics of the *Eustrongylides* nematodes the experimental studies showed that the parasitic nutrition is happening via osmosis, the parasites can get oxygen from the host's tissues. *Eustrongylides* larvae are aerobic.

In the in vitro conditions they consume oxygen intensively, in case of temperature rising the consuming of oxygen and the glycogen loss tend to increase (Brandt & Simpson, 1944). Starving of the host was proven to have no impact on the tissue parasites. Observation showed no glycogen decrease in the *Eustrongylides* larvae localized in the body of a starving fish for 65 days (Brandt, 1944, 1952).

The *Eustrongylides* larvae were found to have hemoglobin. In terms of biochemical characteristics this hemoglobin differs significantly from that one of the host as it has a better ability to fix oxygen even if there is a small amount of oxygen in the environment (Brandt, 1937). The iron-containing breathing pigment is present in parasites colored in red (Brandt, 1937). If the pH level is unsatisfactory, the hydrogen ion activity of the *Eustrongylides* moves towards optimum. This adaptive characteristic is caused by the significant swings of the pH level in the area of natural dislocation of the parasites, especially in the gastrointestinal tract (Brandt, 1942, 1943).

Artificially cultivating *E. ignotus* in the Sabouraud Dextrose Broth in the temperature of 37 °C outside the host's organism, Brant *et al.* were able to get the mature samples. All the nematodes received in this experiment were male (Brandt, 1952). It was found that that *Fundulus heteroclitus* fish infested with *Eustrongylides* larvae accumulate 72 % less mercury (0.77 µg/g) than the non-infected fish (1.07 µg/g), and the parasite itself accumulates 66.23 % less mercury (0.51 µg/g) than the infected fish (Bergey *et al.*, 2002).

To sum up, the biological features of development and life cycle of the *Eustrongylides* nematodes directly depend on the organisms of intermediate, accidental and definitive hosts. Because of their ability to accommodate even to the most unfavorable conditions, caused by physiological, morphological and biochemical features, the *Eustrongylides* nematodes are able to invade a significant amount of living organisms.

Epizootic characteristics of Eustrongylidosis

Prevalence of *Eustrongylides* infection by season

Invading the second intermediate hosts – fish – with the *Eustrongylides* nematode larvae highly depends on the temperature of the environment, so it has a seasonal character. The optimal temperature for keeping the vital activity and eggs' maturation is 20 – 30 °C (Karmanova, 1968; Cole, 1999). The seasonal swing dynamics of eustrongylidosis depends on several main factors: temperature of the environment, feeding intensiveness of the fish, the parasite development period and the presence of the fish-eating birds to spread the parasite (Honcharov *et al.*, 2017).

In European countries (Ukraine, Moldova etc.), situated in the temperate continental climatic zone, the infection rate reaches the peak in spring. Thus, among the fish of the Kuchurgan reservoir in the Republic of Moldova, as the author of the research notes, the cases of the *Eustrongylides* infection were registered throughout

the year, but reached the highest point in spring (Moshu, 2014). Observing the seasonal dynamics of eustrongylidosis among the predatory fishes of the Dnipro-Buh estuary (Ukraine), two peaks were registered – in autumn and in spring. But the infection extensiveness and intensiveness rates reached the top in spring. The biggest percentage of infection was in perches – 95.4 %, 81.8 % of sanders and 80.4 % of pikes were infected. In summer the infection extensiveness counted 72.7 %, 41.6 and 55.5 % for perches, sanders and pikes respectively. In spring – 75.7 %, 57.6 % and 51.9 % for perches, sanders and pikes respectively (Honcharov *et al.*, 2017). In winter the *Eustrongylides* infection extensiveness rates reached the record low – 66.6 %, 35.7 % and 26.6 %, for perches, sanders and pikes respectively, which coincides with the results of the research by Yesipova (2013), which proves that the infection of the predatory fishes with the *Eustrongylides* in the Zaporizhzhya water reservoir (Ukraine) reaches the record high in spring.

In the subtropical climate of Turkey the peak of the eustrongylidosis infection was registered in autumn and winter. This, observing the infection of the hydrobionts in the Siğirci lake, the peak of the perch infection (almost 100 %) was reached in autumn and winter, dropping down in spring (87.5) and summer (90 %) (Soylu, 2013). Similar situation is for roach (*Rutilus rutilus*) in the Kocadere stream in Bursa: the highest rates were fixed in autumn (15 %) and winter (3.2 %). In summer and spring no infected fish was found (Selver *et al.*, 2009); *Blicca bjoerkna* of the natural waters of Turkey was noticed to have eustrongylidosis only in autumn (the infection extensiveness rates counted 27.8 % in September, 14.2 % in October and 15 % in November), as for other seasons, no infection was noticed (Selver *et al.*, 2010). In Bulgaria, in conditions of the temperate climate, the infection extensiveness of perch (*P. fluviatilis*) with the *E. excisus* nematode from Srebarna Biosphere Reserve reaches the highest score in autumn – 23.3 %, tending to decrease in spring (8.3 %) and summer (10 %) (Shukerova *et al.*, 2010).

In subtropical climatic conditions of the Iranian coast of the Caspian Sea, the infection extensiveness of the South-Caspian sturgeon *Acipenser persicus* with the *E. excisus* nematode larvae reached the maximum in winter (13.04 %), slightly decreasing in autumn (10.97 %) and getting to the record low in spring (3.85 %). The research was not conducted in summer (Noei *et al.*, 2015); But in Brazil, in equatorial and tropical climatic conditions of the Paraná River, observation of the seasonal dynamics of the eustrongylidosis infection of the local ichthyic fauna found that *Cichla piquiti*, *Plagioscion squamosissimus* have the highest infection rates in summer, while *Hoplias malabaricus* – in winter (Martins *et al.*, 2009).

According to Hahn *et al.* (1999), some fish-eating predatory animals, in part *Plagioscion squamosissimus*, hunt more intensively in summer and autumn, but in some aquatic areas of Brazil – in spring and autumn, and this is when the larvae are accumulating in the fish's organisms. Merona and Bittencourt (1993) believe that

the infection rates increase could be caused by the seasonal drying out in winter that limits the space of the water environment, which stimulates the predatory instinct of *H. malabaricus*.

Apparently, it can be explained with the biological characteristics of the *Eustrongylides* nematode. Fish infection takes place throughout a year because *Eustrongylides*'s development in oligochaetes from the egg getting into it with the invasive larva to the new larva formation for invading the next intermediate host can take 5-5.5 months. Territorial waters of Turkey and Caspian Sea are located much further to the South than the natural waters of Ukraine and Moldova, that is why the climatic conditions there are not the same as in the Dnipro-Buh estuary, the Dnipro delta, Kuchurgan water reservoir and Zaporizhzhya water reservoir.

Cole (1999) notes that the temperature rates directly impact on the eggs maturation and the level of infection spreading. It allows to suggest that the development process characteristics and time required for the *Eustrongylides* nematode depends on temperature rates, which in turn differ according to the geographic conditions. Seasonal dynamics of infection swings depending on seasonal dynamics of consuming food (in part the water oligochaetes) by fish. The larvae development period in the organisms of hydrobionts is another important aspect (Persson *et al.*, 1988).

Ukraine is situated in the temporal continental climatic zone with a wide range of temperature rates significantly changing depending on seasons, which influences seasonal dynamics of the fish infection rates. The infection takes place throughout a year but intensifies during the warm period. The main definitive hosts are fish-eating birds, who nest and form settled or migratory colonies from early spring till early autumn in floodplains and swamps along the Dnipro-Buh estuary shoreline (Goncharov *et al.*, 2018). At the beginning of spring the birds start to spread the eggs of the parasite in the waters of the Dnipro-Buh estuary with feces. But the settled fish-eating birds, especially seagulls, are spreading the eggs of the nematode throughout the year, but eggs and larvae mature differently because of the seasonal temperature gap (Goncharov *et al.*, 2018). Infection continued during the cold period (winter) as food (oligochaetes) consuming by predatory fishes does not always depend on temperature, but the intensiveness significantly decreased (Honcharov *et al.*, 2017).

Prevalence of *Eustrongylides* infection by age

The level of the *Eustrongylides* infection also depends on the age of the subjected organisms. The analysis of the eustrongylidosis infection of the predatory fishes in the Dnipro-Buh estuary showed that the infection rates are the highest in perches of the age category 7+-8+ (65.2 %) and the lowest – in 5+ – 6+ (33.3 %). The most infected age category in pikes is 9+ (85.7 %), and the least - 0+ – 2+ (52.9 %). 100 % of the sanders of the age category 9+ were infected, the lowest point (43.7 %) was in the group 3+-4+ (Honcharov, 2017a).

The younger age groups are more likely to be infected because

invertebrate organisms, such as oligochaetes – the intermediate hosts of *E. excisus* nematodes larvae, are the major part of their nutrition (Karmanova, 1968). Older fish are predatory, so they are usually infected spontaneously and accidentally. It should be suggested that perches of older age groups are infected gradually every year, so the age groups 7+ – 8+ and 9+ have the highest abundance index rates (Honcharov, 2017a).

As for the *E. excisus* infection of the Gobiidae fishes in the Iranian waters of the Caspian Sea it was found that infection extensiveness and intensiveness is higher for older fish (3+), than in younger (1+ – 2+) (Sattari *et al.*, 2005).

That is why there is a tendency of correlation between the age of predatory fishes and the rates of the infection intensiveness, extensiveness and abundance index. It was discovered that the eustrongylidosis infection rates are higher in the older age groups (Dogel, 1962; Haugen *et al.*, 2008).

Prevalence of *Eustrongylides* infection by sex

Cullinan R. (1945) found that among 465 *Fundulus heteroclitus* of the Chesapeake Bay near Baltimore infected with the *eustrongylides* nematodes 54.7 % were female and 45.3 % – male. The author also notes that the larvae size depends on the fish size. According to Martins *et al.* (2009), among the *Hoplias malabaricus* infected with the eustrongylidosis in the Paraná River in Brazil the extensiveness counted 79.8 % for females and 47.7 % for males. Among *Plagioscion squamosissimus* infected males dominate – the infection extensiveness is 35.4 % in comparison to 25.4 in females. Among *Cichla piquiti* there was no significant difference of the infection extensiveness rates of two sexes – they counted 38.9 % for males and 39.6 % for females. The study of perch in the Dnipro-Buh estuary showed no significant difference between the infection extensiveness rates of males and females (Honcharov *et al.*, 2017). Monteiro *et al.* (2011), studying the eustrongylidosis infection rates in cormorants, found no correlation of the infection extensiveness or intensiveness with sex, age or weight.

This allows to conclude that the representatives of the same aquatic species of different sexes can have different food consuming biology, preferences and activity.

To sum up, the *Eustrongylides* infection rates clearly depend on season and age of the fish; as for correlation between the infection rate and sex, there is not enough data to prove it. The *Eustrongylides* nematode invades numerous hydrobionts, birds, amphibians, reptiles and mammals, including humans, which tells about biological flexibility and polyhostality of the agent.

The influence of the *Eustrongylides* nematodes on the host's organism

The *Eustrongylides* nematodes are mostly parasites of the gastrointestinal tract, where its influence is the most noticeable (Karmanova, 1968). This part gives an observation of scientific sources

on pathological changes in different hosts infected naturally or experimentally

The pathological impact of the *Eustrongylides* nematodes in case of natural infection

Fish-eating birds

Pathological anatomic autopsy of the big cormorants of the Biwa lake in Japan infected with eustrongylidosis showed the nematodes locating in the glandular stomach wall (El-Dakhly *et al.*, 2012). The infection followed by hemorrhages, ulcers and microscopically detected granulomatous inflammatory reactions of various degrees. The degenerated parasites were found in the thickness of gastric channel surrounded by connective tissue. The invasive intensiveness rate is noticed to be higher for female birds (El-Dakhly *et al.*, 2012). Fish-eating birds with the high infection intensiveness rates were observed to have gastrointestinal tract wall perforations and peritonitis that could be deadly. Intestinal obstruction may occur with this type of parasite (Franson *et al.*, 1994). Cole R. (1999) indicates inflammation of the mucous membrane of the gastrointestinal tract of the fish-eating birds infected with the *Eustrongylides* nematode (Cole, 1999). Channels in the thickness of the mucous membrane were a place of location for living and dead parasites or their fragments; perforations in the gastrointestinal tract deformed the hollow organs which led to peritonitis (Cole, 1999). The author of the research indicated the presence of thick-walled fibrinous granulomas with a necrotic center and nematodes inside.

Fishes

As a result of the pathological anatomic autopsy of the fish infected with the *Eustrongylides* nematode larvae, Goncharov *et al.* (2018) reported noticeable signs of inflammation around the encapsulated larvae: redness, compaction of surrounding tissues and edema. Inflammatory processes were especially noticeable in mesentery and muscles. No inflammatory processes surrounded the capsules with the nematode larvae. The reactivity of internal tissues and muscles to mechanical injury by parasite larvae during migration is likely to be different. In our opinion, such phenomena could be partly explained by the timing infection and migration in the organism of the intermediate host (Goncharov *et al.*, 2017).

Histology of the muscular tissue of *Perca fluviatilis* showed that the nematode larvae were surrounded by a capsule. The necrosis areas were noticed at the parasitic infection spots. Muscular tissue was in a degenerative condition. Significant aggregation of macrophages was found at the ends of the spindle-shaped capsules and multifocal fibroepithelial granulomas formed in the capsule thickness (Dezfuli *et al.*, 2015). Histological analysis of *Galaxias maculatus* infected with the *Eustrongylides* nematode larvae discovered symptoms of the compressive tissue atrophy, substitution of muscles with the elements of connective tissue, chronic inflammatory process with the fibrous capsule formation and intensive melanization of the surrounding tissues (Guagliardo *et al.*, 2019).

According to Coyner *et al.*, (2001) the intensively melanized granulomas on the fish's body make it more noticeable for fish-eating birds, which increases the chances for invading the definitive hosts and further spreading. Histological analysis of the liver (hepatopancreas) of the fishes of the *Gymnotus*, genus caught in the Pantanala fish farms in Brazil showed that *Eustrongylides* sp. and other parasitic nematodes caused destructive changes of hepatocytes which are typical for chronic diseases, areas of extra iron accumulation alternate with the areas of unchanged tissue, apoptosis and necrosis areas were registered as well (Ventura *et al.*, 2016). *Eustrongylides* sp. parasitic activity in *Glossogobius giurus* caused ovary damage characterized by destruction of the embryonic epithelium, damage to oocytes. Signs of gonade necrosis, egg lysis and decreased yolk formation were noted. A decrease in the gonadosomatic index and fertility is noticeable in infected fish in comparison to uninfected ones (Kaur *et al.*, 2013). The blood of predatory fish infected with eustrongylidosis had a decrease of hemoglobin, erythrocytes and lymphocytes and an increase of leukocytes, rod and segmental neutrophils, monocytes (Honcharov, 2019c). The amount of young neutrophils differed in the researched fishes: they were absent in perches, increased in pikes and decreased in sanders. Biochemical analysis of the blood serum showed hypoproteinemia, hypoalbuminemia, hypoglobulinemia and dysproteinemia. The ratio of protein fractions changed, namely there was a statistically significant decrease in the content of α - and β -globulins, urea, glucose and an increase in the content of γ -globulins and transaminase activity compared to the control (Honcharov, 2019d). Morphological analysis of the blood of pikes (*Esox lucius*), infected with numerous parasites including *E. excisus*, showed the increased amount of neutrophils, monocytes and eosinophils; the number of lymphocytes decreased (Fallah *et al.*, 2015). Eustrongylidosis of garden snakes (*Thamnophis sirtalis parietalis*, Say 1823) showed formation of subcutaneous neoplasms, significant curvature of the body, from the nostrils observed the release of bloody exudate. At autopsies, helminthes infected under the skin, in the lungs and body, along the spine. 7 of the 25 infected snakes did not survive. In snakes in which parasites were transported surgically, clinical recovery was noticed (Lichtenfels & Lavies, 1976).

Pathological impact of the *Eustrongylides* nematodes in case of experimental infection

Chickens

The experimental infection with the *E. tubifex* nematode larvae was successful (Brugni & Viozzi, 1999). During the experiment, the authors observed immature parasites in the gastrointestinal tract of chickens 22 hours after the infection. The autopsy conducted 18 days later discovered mature forms of helminths. The infected chickens died on the 6th day of the experiment (Brugni & Viozzi, 1999). Among the blue herons (*Ardea herodias*) infected with the *E. ignotus* nematode larvae, ataxia, exhausting, weakness ane-

mia and hematological profile changes were noticed. Pathological anatomic autopsy revealed peritonitis that had damaged intestine, stomach, spleen, pancreas and liver (Ziegler *et al.*, 2000).

Rabbits

D. Shirazian *et al.* (1984) and L. A. Barros *et al.* (2004) conducted experimental researches of invading rabbits with the *Eustrongylides* sp. nematode larvae, in part *E. ignotus*. They noticed inflammatory processes in the abdominal cavity organs, peritonitis and granuloma formation on the liver surface. The authors also report about hyperemia on the stomach surface with necrotic areas in the middle, abscesses in the abdominal cavity and parasites in the thorax.

Rats

Experimental infection of laboratory rats with *E. excisus* nematode larvae taken from *P. fluviatilis* led to changes in their clinical condition: appetite and mobility decrease, negative dynamics of general condition, tachypnea, abdominal wall pain (Honcharov, 2019a). Pathological anatomic autopsy showed serous-fibrinous and purulent-fibrinous peritonitis, perforations of the wall of the gastrointestinal tract, inflammatory processes on the stomach and intestine walls. Microabscesses under the liver capsule, secondary pathologies of kidneys and organs of the thoracic cavity were noticed as well. There were larvae in the lumen of the intestines and in the abdominal cavity, some of them were alive, other showed no vital signs (Honcharov, 2020a). The influence of the *E. excisus* larvae taken from *Rutilus rutilus* was less significant than of those taken from predatory fishes.

Abortive course of the disease was noted: spontaneous recovery with improvement of the clinical condition was registered. Pathologic anatomical analysis showed mostly serous fibrinous peritonitis and several cases of purulent fibrinous peritonitis. Splenomegaly was noted in some animals. Dead nematode larvae and their fragments were found in the abdominal cavity and lumen of the stomach and intestines. In general, nematode larvae that developed in the body of a roach as a non-specific host caused much less pathological changes in laboratory rats' organisms than those taken from predatory fishes (Honcharov, 2020b, 2020c).

Honcharov (2020a) compared the living potential of the *E. excisus* larvae taken from perches and roaches in the organisms of laboratory rats. As a result of two researches the author noted that the living potential of the larvae depends on an intermediate host. *E. excisus* nematode larvae taken from perches and roaches differed in color and morphometric characteristics, which allows to conclude that the parasite developing in the organism of unspecific host (roach) is unable to develop enough to reach the same size and color as in the organism of specific host (predatory fish) (Honcharov, 2020a).

Mice

The rise of the level of specific antibodies IgE and IgG found dur-

ing the intraperitoneal and subcutaneous injection of the laboratory mice with a crude extract of the *Eustrongylides* spp. (L4) larvae, which means that the larval production stages are able to cause an immunological sensitization of the experimental mice (Kuraimi *et al.*, 2021).

Summary of evidence of the pathological changes in the host organisms infected with *Eustrongylides* spp.

So, according to the literature sources, the pathological impact of the *Eustrongylides* nematodes is caused by damaging the host's body tissues during the larvae migration, gastrointestinal tract organs' damage, spontaneous and systematic inflammatory processes, probably caused by secondary bacterial flora (Shirazian *et al.*, 1984; Barros *et al.*, 2004). The inoculating effect is shown as microorganisms located on the surface of the parasites' bodies get in the thickness of the host's tissues making local inflammatory processes more difficult. Under favorable conditions and with secondary microflora involved they can lead to more pathological processes and complications, even the death of the host (Overstreet, 2003). More detailed analysis of the pathological impact of the parasite on the host's organism can be viewed as an object for further research.

The danger of the Eustrongylidosis infection for humans

Eustrongylides spp. is a zoonotic parasite, which means it is dangerous for humans. Infection with the eustrongylidosis takes place if a human consumes fish or fish products that are not heat treated enough. These infections are characterized with gastrointestinal tract organs' perforations and gastritis (Deardorff *et al.*, 1991). Guerin (1982) was the first one to officially report about a human being naturally infected with the *E. excisus* nematode (Table 1).

Clinical case of eustrongylidosis was registered in 3 fishermen from Baltimore, MD, USA. The infection took place as they swallowed two living minnows infected with the eustrongylidosis. Clinical symptoms characterized by progressive spastic pains of the stomach area 24 hours after the parasites got into gastrointestinal tract (Guerin *et al.*, 1982; Gunby, 1982).

As a surgical aid was given to the 17-year-old young man from New Jersey with severe abdominal pains, eustrongylidosis was diagnosed. Surgical interaction found two mature nematodes outside the intestine; they were identified as *Eustrongylides* at the stage 4. The teen got infected as he swallowed a living fish infected with the nematode larvae. Later there was one more case of human infection with eustrongylidosis registered in New Jersey, this person consumed raw fish (Eberhard *et al.*, 1989; Narr *et al.*, 1996).

A case of a 24-year-old student of the New York City College, who was infected with eustrongylidosis after consuming the infected fish in sushi and sashimi the day before reaching the medical help, was described as acute. Alleged case of the eustrongylidosis infection was reported in the state of California, USA, as the under the skin granulomas in the chest contained the *Eustrongylides* nematodes (Beaver *et al.*, 1979).

Only isolated cases of the eustrongylidosis infection of humans were reported outside the USA. In South Sudan two women were registered to have an atypical course of eustrongylidosis. The parasites localized under the skin in granulomas in the distal segment of the lower limbs. Granulomas had a hole which allowed nematodes to contact with the outside environment (Eberhard *et al.*, 2014).

In case of infection of the gastrointestinal tract of humans the appendix was perforated so the helminths could get outside the intestine. Point hemorrhages were seen on the mucous membrane of the colon and exudate was found in the middle of the hollow

Table 1. Human cases of eustrongylidosis infection.

Country, area, year	Researched species	Human cases	Site of infection
USA, California, 1979 (Beaver & Thei, 1979)	<i>Eustrongylides</i> spp.	suspected <i>Eustrongylides</i>	Thorax
USA, Maryland, 1982 (Guerin <i>et al.</i> , 1982)	<i>Eustrongylides</i> spp.	2 cases	Abdominal cavity, intestine
USA, New Jersey, 1989 (Eberhard <i>et al.</i> , 1989)	<i>Eustrongylides</i> spp.	1 case	Abdominal cavity, intestine
USA, New York, 1989 (Wittner <i>et al.</i> , 1989)	<i>Eustrongylides</i> spp.	1 case	Abdominal cavity
USA, New Jersey, Big Timber Creek of Belmawr, 1996 (Narr <i>et al.</i> , 1996)	<i>E. ignotus</i>	1 case (17-year-old boy)	Abdominal cavity, intestine
South Sudan The Payam District of Jie, Kapoeta East County, Eastern Equatoria State, 2014 (Eberhard & Ruiz-Tiben, 2014)	<i>Eustrongylides</i> spp.	2 cases	Distal segment of lower limbs

organ (Guerin *et al.*, 1982). Cases of nematode localization under the skin in granulomas were described. These granulomas located in different body parts, including chest and limbs and caused a significant inflammatory reaction (Beaver *et al.*, 1979; Eberhard *et al.*, 2014).

So, commercial fishes can be potentially dangerous for humans and animals and threatening for the general epidemiological well-being. That is why the issue of spreading zoonotic helminths, especially those that were not previously registered on a certain territory, requires a special attention.

Diagnosics of Eustrongylidosis

The main intermediate hosts of *Eustrongylides* are hydrobionts, so the parasites are most likely to be found in them, if to believe the literary sources.

Main methods of diagnosing eustrongylidosis

Microscopy is the most important method of laboratory diagnostics of eustrongylidosis. Larvae and mature parasites are discovered in the bodies of intermediate and definitive hosts as a result of autopsy. Analysis of the structure of the parasite's body allows to identify the species of the parasite. The analysis of the first intermediate hosts, water oligochaetes of Tubificidae, Lumbriculidae and Limnodrilus spp. families, is conducted via compression and further microscopy using stereoscopic optical tools (Karmanova, 1968). The discovered larval forms are mechanically removed from the host's body for their morphological structure to be observed (Karmanova, 1968).

The detailed description of microscopic method of diagnosing eustrongylidosis in fishes was given by Goncharov *et al.* (2018). Pathological anatomic analysis discovered the general exhaust of the fish and significant amount of mucus on their scale. Nematodes are found, localizing in the thickness of the intercostal and abdominal muscles. Less commonly, parasites are found in the muscle tissue of the back. The larvae are placed in a dense spiral or wide ring on the inner side of the abdominal wall in the transparent capsules. Nematode larvae are also found in the tissues of the hepatopancreas and gonads. The parasites can also freely locate on the surface of the internal organs. They can also locate on the stomach wall forming a capsule from the host's tissues. In isolated cases there were signs of inflammation around the capsule: hyperemia, compaction of surrounding tissues and edema (Honcharov, 2017b).

The autopsy of fish-eating birds as definitive hosts showed parasites in granulomas and walls of hollow organs (goiter, glandular stomach, intestines), in thoracic and abdominal cavities, in thickness of organs and tissues. To identify the species, the parasites were washed in the normal saline and subjected to detailed microscopy (Karmanova, 1968).

Molecular-genetic methods are proven to be effective for identi-

fying the taxonomy of several nematode species, including *Eustrongylides*, with high accuracy (Menconi *et al.*, 2020). Mazzoni *et al.*, (2019) described genetic similarity of stage 3 and 4 larvae as well as adult nematodes of *E. excisus* found in Lake Trasimeno, Italy. Genetic methods proved to be effective for larvae stage identification as their morphological characteristic do not allow precise species identification according to the authors. The molecular markers are shown to be able to identify the species and specificity regarding different hosts (Alama-Bermejo *et al.*, 2011; Westram *et al.*, 2011). Spreading and identity of *Eustrongylides* spp. was investigated using mitochondrial cytochrome oxidase c subunit 1 (COI) and internal transcribed spacer (ITS) rDNA regions as molecular markers (Xiong *et al.*, 2012).

Additional methods of diagnosing eustrongylidosis

Even though eustrongylidosis has no pathognomonic clinical symptoms, the symptoms of this disease in fish can ease diagnosing, such as aberrant behavior, convulsions and surfacing. The above-mentioned symptoms were registered in 67 % of fish infected. Researchers believe that this behavior of the fish stimulates predatory behavior of the fish-eating birds, so the mentioned parasites can easily invade the definitive hosts. The abdominal cavity increased due to parasitic accumulation. Migrating inside small fishes the larvae can damage the muscular tissue of the tail area and deform the spine in this area as well, so the fish can lose their swimming ability (Coyner *et al.*, 2001). Clinical analysis of *Galaxias maculatus* in the waters of Patagonia (Argentina) showed specific intensively melanized cysts formed on the fish's body, containing the *Eustrongylides* sp. larvae; the cysts visualized easily (Guagliardo *et al.*, 2019).

Some scientists offer palpation as a method of diagnosing eustrongylidosis in fish-eating water birds of different species (Ciconiiformes). The research author reports that goiter and esophagus palpation can help to discover granulomas and thickening. Using this method helped to diagnose eustrongylidosis in 226 dead birds of 238 researched (Spalding, 1990).

To increase the surviving potential of the eustrongylidosis in the organisms of unspecific hosts, such as laboratory rats, Honcharov offered injecting 1 % hydrochloric acid solution in an amount of 1 ml intragastrically for three days straight, which helped to increase the surviving potential of the parasites to 52 % in comparison to 18 % in the control group (Honcharov, 2019a).

The available literary sources do not contain any data about antibodies formation as a specific immune protection in case of eustrongylidosis, so it is not known whether serological diagnostic methods can be used.

Summary of evidence of diagnosis of Eustrongylidosis

Diagnosing of eustrongylidosis on the basis of clinical symptoms is difficult as this disease has no pathognomonic clinical symptoms

(Coyner *et al.*, 2001). For the accurate diagnosis the laboratory methods are used; they are based on identifying the morphological characteristics of the parasites and on the microscopic analysis (Karmanova, 1968; Goncharov *et al.*, 2018). The typical morphological characteristics of the Eustrongylide nematodes allow to identify their taxonomy. For more detailed observation of the taxonomic characteristics the molecular-genetic analysis is required. But in regular diagnostic practice light microscopy is usually used to observe mature larvae taken from the host's tissues during the autopsy (Goncharov *et al.*, 2018).

The role of ecological aspects in formation of the Eustrongylidosis infection centers in nature

Anthropogenic factor leads to severe changes in the parasitological system (MacLeod & Poulin, 2012; Perkins, 2010). The impact of the anthropogenic factor is felt not only by the hosts, but by the parasites whose development cycle became evolutionary more complicated (biohelminths). There is a direct correlation between the impact of parasites on the hosts and the density of both populations. Thus, under the influence of different ecological and environmental factors, biological, physical or chemical, the parasitological system is restructured from the point of view of species variety, the biomass of parasites and hosts, etc. Anthropogenic factors provide keeping and further development (progress or regress) of the parasitological systems defining their changeability and variability levels (Davydov *et al.*, 2011).

For example, for the Dioctophymatidae nematodes, in part *Eustrongylides*, water oligochaetes stand as hosts for the first and second larval periods (Lichtenfels & Stroup; 1985). Increased amount of the organic substances and their accumulation in the water form a nutritional base for the intermediate hosts for this parasite: mollusks, oligochaetes and other representatives of benthos. Water pollution with the organic fragments and oversaturation of the waters with biogenic elements are the main causes of parasitic diseases being spread among the ichthyic fauna in the natural waters (Coyner *et al.*, 2002). Oversaturation with pollutants leads to eutrophication of waters that leads to death of both parasites and hydrobionts (Spalding & Forrester, 1993; Ogden, 1994).

Special and mostly defining role in spreading the parasites among the ichthyic fauna is played by fish-eating birds, which migrate and spread the helminths far beyond the areas where they were previously registered and form new centers of infection. The main reason of changing the migration ways and the settlement periods in migrating birds is most likely climatic conditions caused by the global warming in the world (Švažas *et al.*, 2011; Menconi *et al.*, 2020).

Climate changes of the recent years led to shortening of the period of time when the waters of the temperate climatic zone are covered by the ice in cold seasons, which means that the parasites whose definitive hosts are fish-eating birds have much more time to finish their development cycle than they used to before. Climatic

changes also change the migration time for birds and the percentage of birds that migrate (Root *et al.*, 2003; Tottrup *et al.*, 2008; Polley & Thompson, 2009).

During the spring migration the southern birds are now able to cross the northern border as the early spring temperature is high enough, and to nest in the northern areas where they are not normally registered. And vice versa – as the spring migration time gets shorter, the birds who usually nest in northern areas can settle much closer to the south if cold temperatures in spring last long (Kumari, 2012).

Within the nearest 100 years the parasites whose development cycle includes fish-eating birds will dominate over those whose entire development cycle takes place in the water. So the energy and materials flow from the water to the land will increase (Gopko *et al.*, 2017).

Unsatisfactory hydro-chemical regime of the waters causes pathological processes, in part death of the fish, depopulation and variety decrease of the ichthyic fauna, which in turn lead to temporary nutrition spots for the fish-eating birds that are the main definitive hosts for the eustrongylidosis. This is how both biotic and abiotic natural factors can influence the population of ichthyic fauna in certain aquatic areas. Accumulation of the fish-eating birds in the areas with mass fish mortality increases the parasitic infection rates among fishes in general and the eustrongylidosis infection rates among fishes in part (Honcharov, 2019b).

The example of eustrongylidosis infection reaching potentially epizootic scales is the case of an unprecedented decline in the number of wetland birds over the past 40 years in North America, Florida, due to the high mortality of fish-eating birds infected with *E. ignotus*. Mortality of chicks in some colonies of wetland birds was up to 80 % (Spalding & Forrester, 1993; Ogden, 1994).

So, prevention and liquidation of this parasitic disease in natural waters is difficult. But it is known that the environmental conditions, in part oversaturation of the water with the organic fragments and temperature rates create the appropriate conditions for increasing the population of the first intermediate host of the *Eustrongylides* – oligochaetes. So the water quality is one of the defining factors for spreading the infection among the fishes that could be potentially affected (Cole, 1999). That is why decreasing of the anthropogenic overload of the waters, in part pollution by fertilizers and sewage, is one of the decisive and environmentally friendly measures that would not only reduce the population of oligochaetes and therefore prevalence of eustrongylidosis among the ichthyic fauna, but also improve hydro-chemical characteristics of the waters. The impact of migrating birds on formation of the stationary infection centers among commercial fishes in the natural waters should be noted. In part the centers of eustrongylidosis deserve special attention as this disease can be potentially dangerous for humans.

Conclusion

In the given review the authors highlighted the most relevant is-

sues related to eustrongylidosis: development biology, seasonal and age dynamics, diagnosing etc.

The nematodes *Eustrongylides* spp., Jägerskiöld, 1909 were first described and substantiated as the species of the *Eustrongylides* genus by Jägerskiöld in 1909, as they were taken from the waterfowl bird from East Africa during the autopsy. This nematode genus has a number of specific morphological characteristics which makes it possible to identify its taxonomy. In particular, such features of the body structure are the presence at the head end of two rows of papillae – six in each row.

Eustrongylides nematodes are typical biohelminths with a complicated development cycle. The main definitive hosts are fish-eating birds that spread the parasite with feces and invade the waters. The first intermediate hosts are water oligochaetes that are infected as they swallow the nematode eggs. The parasite reaches the stages I and II of its development in the body of the invertebrates. The maturing speed for eggs in the water environment directly depends on temperature. The second intermediate hosts are mostly hydrobionts – predatory fishes that get infected with the eustrongylidosis as they swallow oligochaetes; in their organisms the parasites reach stages III and IV of their development cycle. Fish-eating birds are infected with the *Eustrongylides* nematodes as they consume the infected fish and the parasite gets mature in their bodies. Accidental and unspecific hosts for these nematodes can be snakes, frogs, turtles, alligators and sea mammals. Humans can be infected too, if they consume fish that is not heated enough. The possibility of infection of rats and rabbits was proven experimentally. The distribution of larvae in the body of fish during infection is uneven: the vast majority of parasites are localized in the ventral part of the body, fewer larvae are found in the dorsal part of the body of the fish. Regarding the biological characteristics, the larvae can form a capsule in the fish's body where it is located rolled in a spiral or they can locate freely in the body cavities. From the point of view of the biochemical characteristics of the nematodes of the genus *Eustrongylides* this parasite is aerobic.

Eustrongylidosis spreading in the natural environment has a seasonal character, which is defined by temperature and biological characteristics of the nematode development cycle. In countries with the temperate continental climate (Ukraine, Moldova) the infection rates reach the peak in spring, while in countries with the subtropical climate (Turkey, Iran) – in autumn, and in countries with equatorial climate (Brazil, Argentina, Mexico) – in summer and autumn. The infection rates of the fish is directly connected with age, the older the intermediate host is, the higher are the infection rates (intensiveness and extensiveness). Scientific literature has no data to confirm the connection between the infection rates and sex, but females have eustrongylidosis oftener than males.

The course of the disease was mostly acute, followed by hemorrhages and gastrointestinal tract perforations. Autopsy of fish-eating birds found fibrous granulomas in which living and degenerated *Eustrongylides* nematodes were located; peritonitis and intestinal wall perforations were registered as well. Hemorrhages in the

thickness of muscle tissue, hyperemia and compaction are noted in fish at pathological-anatomical autopsy. Histological analysis shows significant leukocyte infiltration of the surrounding tissues, signs of necrosis and a connective tissue capsule formation.

Morphological analysis of the blood of predatory fishes with eustrongylidosis showed a decrease in hemoglobin, in the amount of erythrocytes and lymphocytes and an increase in the amount of leukocytes, rod- and segmental neutrophils, monocytes; biochemical analysis of blood serum, in turn, showed hypoproteinemia, hypoalbuminemia, hypoglobulinemia and dysproteinemia, decrease in α - and β -globulins, urea, glucose and increase in γ -globulines and transaminase activity.

Experimental infection of laboratory rats with the *E. exisus* nematode larvae taken from perches showed tachypnea, abdominal wall pain and worsened general condition. Autopsy showed serous-fibrous and purulent peritonitis, microabscesses under the liver capsule etc. The infection of rats with the *E. exisus* larvae taken from roaches led to an easier course of the disease with an abortive recovery. Autopsy showed mostly serous-fibrous, less often - purulent-fibrous peritonitis. The larvae removed during the autopsy after the two experiments differed in color and size, those taken from perches also tended to have a bigger living potential. This fact makes it clear that the parasite loses its pathogenic ability in the body of an unspecific host, such as a roach.

Eustrongylides nematodes can be dangerous for human health. The infection is possible in case of consuming infected fish or fish products. The biggest amount of cases of humans being infected with the eustrongylidosis was registered in the United States. The main clinical symptom of eustrongylidosis for humans is pain in the abdominal cavity area. The parasite can perforate the wall of the tubular organ of the gastrointestinal tract and be localized in the extraintestinal space. Parasites in humans can be localized in newly formed granulomas, under the skin.

The most commonly used method for diagnosing eustrongylidosis is microscopy of larvae and mature *Eustrongylides* nematodes and defining their taxonomy according to morphological characteristics. Eustrongylidosis has no specific clinical symptoms such as increasing of the abdominal cavity, thickening of the body tissues etc., which makes it difficult to diagnose the disease while the host is alive. Autopsy of intermediate and definitive hosts found larvae and mature parasites localized in the body tissues (mostly in the muscular tissue) or freely located in the abdominal cavity. Molecular-genetic methods are used to identify the species of the parasite. Palpation of the gastrointestinal tract organs of fish-eating birds to find granulomas and thickenings was offered as an additional diagnostic method for eustrongylidosis.

Oversaturation and pollution of natural and artificial water reservoirs with organic fragments and biogenic elements forms conditions for intensive development of populations of oligochaetes - the first intermediate hosts for the *Eustrongylides* nematodes – which in turn creates a satisfactory nutritional base for fish, second intermediate hosts who consume oligochaetes and get infected

with the eustrongylidosis. The increase in the amount of pollutants in the waters worsens the biochemical characteristics, which can lead to fish mortality. Mortality processes taking place locally, in the rivers and estuaries, attract fish-eating birds – definitive hosts-which leads to natural centers of the eustrongylide infection being formed.

To sum up, observing special characteristics of the eustrongylide infection is a topic of great interest for the researchers from the point of view of the parasite-host relationships, epizootology of the disease, impact of helminths on the host's organism and providing the stable epidemiological well-being.

Conflict of interest

The authors declare that they have no known competing financial interests or personal relationships that could have appeared to influence the work reported in this paper.

Reference

- ALAMA-BERMEGIO, G., RAGA, J.A., HOLZER, A.S. (2011): Host-parasite relationship of *Ceratomyxa puntazzi* n. sp. (Myxozoa: Myxosporea) and sharpnose seabream *Diplodus puntazzo* (Walbaum, 1792) from the Mediterranean with first data on ceratomyxid host specificity in sparids. *Vet Parasitol*, 182: 181 – 192. DOI: 10.1016/j.vetpar.2011.05.012
- BARROS, L.A., MATEUS, L.A.F., BRAUN, D.T., BONALDO, J. (2010): Ecological aspects of endoparasites in red piranha (*Pygocentrus nattereri* Kner, 1860) from Cuiabá river, Mato Grosso, Brazil. *Arq Bras Med Vet Zootec*, 62, 228 – 231. DOI: 10.1590/S0102-09352010000100033
- BARROS, L.A., TORTELLY, R., PINTO, R. M., GOMES, D. C. (2004): Effects of experimental infections with larvae of *Eustrongylides ignotus* Jägerskiöld, 1909 and *Contraecaecum multipapillatum* (Drasche, 1882) Baylis, 1920 in rabbits. *Arq Bras Med Vet Zootec*, 56: 325 – 332. DOI: 10.1590/S0102-09352004000300007
- BEAVER, P.C., THEIS, J.H. (1979): Diectophymid larval nematode in a subcutaneous nodule from man in California. *Am J Trop Med Hyg*, 28: 206 – 212. DOI: 10.4269/ajtmh.1979.28.206
- BERGEY, L., WEIS, J. S., WEIS, P. (2002): Mercury uptake by the estuarine species *Palaemonetes pugio* and *Fundulus heteroclitus* compared with their parasites, *Probopyrus pandalicola* and *Eustrongylides* sp. *Mar Pollut Bull*, 44: 1046 – 1050. DOI: 10.1016/S0025-326X(02)00154-6
- BJELIĆ-CABRILLO, O., NOVAKOV, N., IRCOVI, M., KOSTI, D., POPOVI, E., ALEKSI, N., LUJI, J. (2013): The first determination of *Eustrongylides excisus* Jägerskiöld, 1909: Larvae (Nematoda: Diectophymatidae) in the pike-perch *Sander lucioperca* in Vojvodina (Serbia). *Helminthologia*, 50: 291 – 294. DOI: 10.2478/s11687-013-0143-1
- BRAND, TH. V., SIMSON, W. F. (1944): Studies upon survival and metabolism in sterile surroundings. *J Parasitol*, 30 (2): 121 – 129
- BRAND, TH. V. (1942): Factors influencing the oxygen consumption of larval *Eustrongylides*. *J. Parasitol.*, 28 (6), (suppl).
- BRAND, TH. V. (1937): Haemoglobin in larval nematode. *J Parasitol*, 23: 225
- BRAND, TH. V. (1943): Influence of temperature, pH and inorganic ions upon the oxygen consumption. *Biol Bull*, 84: 148
- BRAND, TH. V. (1944): Physiological observation on a larval *Eustrongylides* VI. Transmission to various coldblooded intermediate host. *Proc Helminthol Soc Wash*, 11 (1): 23 – 27
- BRAND, TH. V. (1947): Physiological observation upon a larval *Eustrongylides*. XI. Influence of oxygen tension on the aerobic and postanaerobic oxygen consumption. *Biol. Bull.*, 92 (2): 162 – 166
- BRAND, TH. V. (1952): *Chemical physiology of endoparasitic animals*. Acad. Press. N. Y, 339
- BRUGNI, N., VIOZZI, G. (1999): Presence of *Eustrongylides* sp. (Jägerskiöld, 1909) (Nematoda: Diectophymatoidea) in *Galaxias maculatus* (Jenyns, 1842) (Pisces: Galaxiidae) from Patagonia, Argentina. *J. Helminthol. Soc. Wash.*, 66: 92 – 94
- CIUREA, J. (1924): Die *Eustrongylides*-Larven bei Donaufischen [The *Eustrongylides* larvae in Danube fish]. *Z. Fleisch und Milchhygiene*, 34(13): 134 – 137 (In German)
- COLE, R.A. (1999): Eustrongylidosis. In: FRIEND, M., FRANSON, J.C. (Eds) *Field Manual of Wildlife Diseases: General Field Procedures and Diseases of Birds*. U.S. Department of the Interior Fish and Wildlife Service: Washington, DC, USA, 223 – 228
- COOPER, C., CRITES, J., SPINKLE, FASTKIE, D. (1978): Population biology and behavior of larval *Eustrongylides tubifex* (Nematoda: Diectophymatida) in Poikilothermous hosts. *J Parasitol*, 64: 102 – 107
- COYNER, D., SCHAACK, S., SPALDING, M., FORRESTER, D. (2001): Altered predation susceptibility of mosquitofish infected with *Eustrongylides ignotus*. *J Wildl Dis*, 37: 556 – 560. DOI: 10.7589/0090-3558-37.3.556
- COYNER, D., SPALDING, M., FORRESTER, D. (2002): Epizootiology of *Eustrongylides ignotus* in Florida: Transmission and Development of Larvae in Intermediate Hosts. *J Parasitol*, 89: 290 – 298. DOI: 10.1645/0022-3395(2003)089[0290:EOEIF]2.0.CO;2
- CRAM, E.B. (1927): Bird parasites of the Nematode suborder *Strongylata*, *Ascaridata* and *Spirurata*. *Bull. U.S. Mus. Wash.*, 140: 465. DOI: 10.5479/si.03629236.140.1
- CULLIAN, R.P. (1945): The larvae of *Eustrongylides ignotus* in *Fundulus heteroclitus*. *J Parasitol*, 31 (2): 109 – 112. DOI: 10.2307/3272933
- DAVYDOV, O.N., KUROVSKAYA, L.YA, TEMNIKHOV, YU.D., NEBORACHEK, S.I. (2011): Formation of links between parasites and their hosts in anthropogenically altered hydrobiocenoses. *Hydroparasitology. Hydrobiol. J.*, 47, 80 – 90 (In Russian)
- DEARDOFF, T.L., OVERSTREET, R.M. (1991): Sea food transmitted zoonoses in the United States: the fishes, the dishes, and the worms. In: WARD, D.R., HACKNEY, C.R. (Eds) *Microbiology of marine food products*. Van Nostrand Reinhold, New York, 211 – 265
- DEZFULI, B.S., MANERA, M., LORENZONI, M., PIRONI, F., SHINN, A.P., GIARI, L. (2015): Histopathology and the inflammatory response of European perch, *Perca fluviatilis* muscle infected with *Eustron-*

- gylides* sp. (Nematoda). *Parasit Vectors*, 8: 227. DOI: 10.1186/s13071-015-0838-x
- DIESING, K.M. (1861): Revision der Nematoden [Revision of the nematodes]. *Sitzungsber. Kaiserl. Akad. Wiss., Math.-Naturwiss. Cl.*, 42, 28: 595 – 736 (In German)
- DOGELV, A. (1962): *General parasitology*. Publisher: Leningrad University, 463 (In Russian)
- EBENHARD, M.L., HURWITZ, H., SUN, A.M., COLETTA, D. (1989): Intestinal perforation caused by larval *Eustrongylides* (Nematoda: Dioctophymatoidea) in New Jersey. *Am J Trop Med Hyg*, 40: 648 – 650. DOI: 10.4269/ajtmh.1989.40.648
- EBENHARD, M.L., RUIZ-TIBEN, E. (2014): Cutaneous emergence of *Eustrongylides* in two persons from South Sudan. *Am J Trop Med Hyg*, 90: 315 – 317. DOI: 10.4269/ajtmh.13-0638
- EL-DAKHLI, K.M., EL-NAHASS, E., UNI, S., TUJI, H., SAKAI, H., YANAI, T. (2012): Levels of infection of gastric nematodes in a flock of great cormorants (*Phalacrocorax carbo*) from Lake Biwa, Japan. *J Helminthol*, 86: 54 – 63. DOI: 10.1017/S0022149X11000046
- FALLAH, F.J., KHARA, H., ROHI, J.D., SAYADBORANI, M. (2015): Hematological parameters associated with parasitism in pike, *Esox lucius* caught from Anzali wetland. *J Parasit Dis*, 39: 245 – 248. DOI: 10.1007/s12639-013-0329-y
- FEIST, S.W., LONGSHAW, M. (2008): Histopathology of fish parasite infections – importance. *J Fish Biol*, 73: 2143 – 2160. DOI: 10.1111/j.1095-8649.2008.02060.x
- FRANCESCHINI, R., GUARDONE, L., ARMANI, A., RANUCCI, D., ROILA, R., VALIANI, A., SUSISNI, F., BRANCIARI, R. (2022): Five-years management of an emerging parasite risk (*Eustrongylides* sp., Nematoda) in a fishery supply chain located on Trasimeno Lake (Italy). *Food Control*, 136, 108858. DOI:10.1016/j.foodcont.2022.108858
- FRANSON, J.C., CLUSTER, T.W. (1994): Prevalence *Eustrongylidosis* in Wading Birds from colonies in California, Texas and Rhode Island, USA. *Col Waterbirds*, 17 (2): 168 – 172. DOI:10.2307/1521295
- GONCHAROV, S.L., SOROKA, N.M., PASHKEVICH, I.Y., DUBOVYI, A.I., BONDAR, A.O. (2018): Infection of Predatory Fish with Larvae of *Eustrongylides excisus* (Nematoda, Dioctophymatidae) in the Delta of the Dnipro River and the Dnipro-Buh Estuary in Southern Ukraine. *Vestn Zool*, 52 (2): 137 – 144. DOI: 10.2478/vzoo-2018-0015
- GOPKO, M.V., MIKHEEV, V.N., TASKINEN, J. (2017): The deterioration of basic components of the antipredator behaviour in fish harbouring eye fluke larvae. *Behav Ecol Sociobiol*, 71: 68. DOI: 10.1007/s00265-017-2300-x
- GUAGLIARDO, S., VIOZZI, G., BRUGNI, N. (2019): Pathology associated with larval *Eustrongylides* sp. (Nematoda: Dioctophymatoidea) infection in *Galaxias maculatus* (Actinopterygii: Galaxiidae) from Patagonia, Argentina. *Int J Parasitol Parasites Wildl*, 10: 113-116. DOI: 10.1016/j.ijppaw.2019.08.004
- GUERIN, P. F., MARAPENDI, S., GRAIL, S.L. (1982): Intestinal perforation caused by larval *Eustrongylides* – Maryland. *MMWR Morb Mortal Wkly Rep.*, 31: 383 – 384
- GUNBY, P. (1982): One worm in the minnow equals too many in the gut. *JAMA*, 248: 163. DOI: 10.1001/jama.1982.03330020011004
- HAHN, N.S., AGOSTINCHO, A.A., GOITEIN, R. (1997): Feeding ecology of curvina *Plagioscion squamosissimus* (Heckel, 1840) (Osteichthyes, Perciformes) in the Itaipu reservoir and Porto Rico floodplain. *Acta Limnol. Bras*, 9: 11 – 22
- HAUGEN, P., HEMMINGSEN, W., MACKENZIE, K. (2008): The distribution of *Eustrongylides* sp. (Nematoda: Dioctophymatoidea) in brown trout *Salmo trutta* L. in the River Otra in southern Norway. *Bull Eur Assoc Fish Pathol*, 28: 138 – 143
- HONCHAROV S. L., SOROKA N.M., DUBOVYI A.I. (2017): Seasonal dynamics of infection of predatory fish species by nematodes *Eustrongylides excisus* (Nematoda: Dioctophymatidae) in the Dnieper-Bug Estuary and the Dnieper Delta. *Anim Biol*, 19(4): 16 – 23. DOI: 10.15407/animbiol19.04.016 (In Ukrainian)
- HONCHAROV, S.L. (2017a): Age dynamics of infection of predatory fish species by larvae of nematodes *Eustrongylides excisus* in the Dnieper-Bug estuary and the Dnieper delta. *BPSAA*, 3: 110 – 115. DOI: 10.31210/visnyk2017.03.25 (In Ukrainian)
- HONCHAROV, S.L. (2017b): Distribution of nematode larvae *Eustrongylides excisus* Jägerskiöld, 1909 (Nematoda: Dioctophymatidae) in the body of predatory fish. *Scientific and technical bulletin of the Research Center for Biosafety and Environmental Control of Agricultural Resources*, 5(3): 5 – 9 Retrieved from <https://bulletin-biosafety.com/index.php/journal/article/view/150/162>. (In Ukrainian)
- HONCHAROV, S.L. (2019 a): Experimental infection of laboratory rats with larvae of the nematode *Eustrongylides excisus* (Nematoda: Dioctophymatidae). *Ukr. J. Vet. Sci.*, (3): 13 – 24. DOI: 10.31548/ujvs2019.03.011 (In Ukrainian)
- HONCHAROV, S.L. (2019b): Influence of some biotic and abiotic factors on the state of parasitofauna of aquatic organisms of natural reservoirs of the South of Ukraine. *Sci. Bull. Vet. Med.*, 2: 60 – 70. DOI: 10.33245/2310-4902-2019-152-2-60-70 (In Ukrainian)
- HONCHAROV, S.L. (2019c): Morphological changes in the blood of predatory fish species in eustrongylidosis. *Scientific Bulletin of LNUVMB named after S. Z. Gzhytsky. Series: Veterinary Sciences*, 21(93): 15 – 20. DOI: 10.32718/nvlvet9303 (In Ukrainian)
- HONCHAROV, S.L. (2020a): Pathological anatomic changes among laboratory rats in case of experimental infection with the larvae of the nematode *Eustrongylides excisus* (Nematoda: Dioctophymatidae). *Anim Biol*, 22(1): 30 – 37. DOI: 10.15407/animbiol22.01.003
- HONCHAROV, S.L. (2020b): Prevalence of the nematodes *Eustrongylides excisus* Jägerskiöld, 1909, – larvae (Nematoda: Dioctophymatidae) infection in the *Rutilus rutilus*, Linnaeus, 1758 and the seasonal dynamics of the infection in the waters of the Dnipro-Buh Estuari in Southern Ukraine. *Scientific Messenger of Lviv National University of Veterinary Medicine and Biotechnologies. Series: Veterinary sciences*: 22(97): 31 – 38. DOI: 10.32718/nvlvet9706 (In Ukrainian)
- HONCHAROV, S.L. (2020c): Results of experimental infestation of laboratory rats with larvae of the nematode *Eustrongylides excisus* (Nematoda: Dioctophymatidae), selected from the rouch (*Rutilus rutilus*, Linnaeus 1758). *Ukr. J. Vet. Sci.*, 11(1): 12 – 19. DOI: 10.31548/ujvs2020.01.011 (In Ukrainian)

- HONCHAROV, S.L. (2019d): Some biochemical parameters of the serum of predatory fish in eustrongylidosis. *BPSAA*, 2: 140 – 147. DOI: 10.31210/visnyk2019.02.18 (In Ukrainian)
- JÄGERSKIÖLD, L.A. (1909): Zur Kenntnis der Nematoden-Gattungen *Eustrongylides* und *Hystrichis* [About the nematode genera *Eustrongylides* and *Hystrichis*]. *Nova acta R. Soc. Sci. Upsaliensis*, ser. 4 v. 2: 48p. (In German)
- KARMANOVA E. M. (1968): *Diectophymidea of animals and man and the diseases caused by them*. Nauka Publishing: Moscow, 383 (In Russian)
- KAUR P., SHRIVASTAV R. T. A. (2013): Qureshi Pathological effects of *Eustrongylides* sp. Larvae (Diectophymatidae) infection in freshwater fish, *Glossogobius giuris* (Ham.) with special reference to ovaries. *J Parasit Dis*, 37: 245 – 250. DOI: 10.1007/s12639-012-0173-5
- KUMARI, E.V. (2012): Bird migration as a zoogeographic problem. *Russ. Ornithol. J.*, 21: 1131 – 1140 (In Russian)
- KURAIEM, B.P., VERICIMO, M.A., KNOFF, M., MATTOS, D.P.B.G., SAO CLETMENTE, S.C. (2021): Sensitization with *Eustrongylides* sp. (Nematoda: Diectophymatidae) antigens induce production of specific IgG and IgE in murine model. *Rev Bras Parasitol Vet*, 26-30(1): 023920. DOI: 10.1590/S1984-29612021018
- LEUCKART, R. (1868): Die menschlichen Parasiten [The human parasites]. Bd. 2, Leipzig, 2; 38 – 387 (In German)
- LICHTENFEL, J.R., LAVIES, B. (1976): Mortality in red-sided garter snakes, *Thamnophis sirtalis parietalis*, due to larval nematode, *Eustrongylides* sp. *Lab Anim Sci*, 26: 465-467
- LICHTENFEL, J.R., STROUP, C.F. (1985): *Eustrongylides* sp. (Nematoda: Diectophymatoidea): First Report of an Invertebrate Host (Oligochaeta: Tubificidae) in North America. *Proc Helminthol Soc Wash*, 52(2): 320 – 323
- LINSTOW, O. (1899): Zur Kenntnis der Genera *Hystrichis* und *Tropidocerca* [About the Genera *Hystrichis* and *Tropidocerca*]. *Arch. Naturgesch*, 65: 155 – 164 (In German)
- LJUBOJEVICA, D., NOVAKOV, N., DJORDJEVIC, V., RADOSAVLJEVIC, V., PELICA, M. (2015): Potential parasitic hazards for humans in fish meat. *Procedia Food Sci*, 5: 172 – 175. DOI: 10.1016/j.profoo.2015.09.049
- MACLEOD, C.D., POULIN, R. (2012): Host-parasite interactions: a litmus test for ocean acidification? *Trends Parasitol*, 28: 365 – 369. DOI: 10.1016/j.pt.2012.06.007
- MARTINS, M., SANTOS, S., MARENGONI, N., TAKAHASHI, K., ONAKA, E. (2009): Seasonality of *Eustrongylides* sp. (Nematoda: Diectophymatidae) larvae in fishes from Paraná river, South-western Brazil. *Bol Inst Pesca*, 35: 29 – 37
- MAZZONE, A., CAFFARA, M., GUSTINELLI, A., AGNETTI, F., SGARILLA, E., VALHO, L.G., QUAGLIO, F., FIORAVANTI, M.L. (2019): Morphological and molecular characterization of larval and adult stages of *Eustrongylides excisus* (Nematoda: Diectophymatoidea) with histopathological observations. *J Parasitol*, 105(6): 882-889
- MELO, F.T., MELO, C.S., NASCIMENTO, L.C., GIESE, E.G., FURTADO, A.P., SANTOS, J.N. (2016): Morphological characterization of *Eustrongylides* ssp. Larvae (Nematoda, Diectophymatoidea) parasite of *Rhinella marina* (Amphibia: Bufonidae) from Eastern Amazonia. *Rev Bras Parasitol Vet*, 25(2): 235-239. DOI: 10.1590/S1984-29612016024
- MENCONI, V., RIINA, M.V., PASTORINO, P., MUGETTI, D., CANOLA, S., PIZZUL, E., BONA, M.C., DONDO, A., ACUTIS, P.L., PREARO, M. (2020): First occurrence of *Eustrongylides* spp. (nematoda: Diectophymatidae) in a subalpine lake in Northwest Italy: New data on distribution and host range. *Int J Environ Res Public Health*, 17: 4171. DOI: 10.3390/ijerph17114171
- MERONA, B., BITTENCOURT, M.M. (1993): Fish communities of the lago do Rei, a floodplain lake in the Central Amazon. A general description. *Amazoniana*, 12(3–4): 415 – 422 (In French)
- MIERZEJEWSKA, K., KVACH, Y, WOZNIAK, M., KOSOWSKA, A., DZIEKONSKA-RYNKO, J. (2012): Parasites of an Asian fish, the Chinese sleeper *Perccottus glenii*, in the Włocławek Reservoir on the Lower Vistula River, Poland: in search of the key species in the host expansion process. *Comp Parasitol*, 79: 23 – 29. DOI:10.1654/4519.1
- MIKAILOV, T.K., BUNYATOVA, K.I., NASIROVA, A.M. (1992): About the finding of eggs of the nematode *Eustrongylides excisus* in sturgeon of the Caspian Sea. *Parasitology*, 5: 440 – 442 (In Russian)
- MITCHELL, A., OVERSTREET, R., GOODVIN, A. (2009): *Eustrongylides ignotus* infecting commercial bass, *Morone chrysops* female X *Morone saxatilis* male, and other fish in the southeastern USA. *J Fish Dis*, 32(9): 795 – 799. DOI: 10.1111/j.1365-2761.2009.01051.x
- MONTEIRO, C.M., AMATO, J.F.R., AMATO, S.B. (2011): Helminth parasitism in the Neotropical cormorant, *Phalacrocorax brasilianus*, in Southern Brazil: Effect of host size, weight, sex, and maturity state. *Parasitol Res*, 109: 849 – 855. DOI: 10.1007/s00436-011-2311-x
- MOSHU, A. (2014): *Helminths of fish from reservoirs of the Dniester-Prut interfluvium, potentially hazardous to human health*. Chisinau: Eco-TIRAS, 88 (In Russian)
- NARR, L.L., O'DONELL, J.G., LIBSTER, B., ALESSI, P., ABRAHAM, D. (1996): Eustrongylidiasis a parasitic infection acquired by eating live minnow. *J Am Osteopath Assoc*, 96: 400 – 402
- NOEI, M.R., IBRAHIMOV, S., SATTARI, M. (2015): Parasitic worms of the Persian sturgeon, *Acipenser persicus* Borodin, 1897 from the southwestern shores of the Caspian Sea. *Iran. J. Ichthyol.*, 2: 287 – 295. DOI: 10.22034/iji.v2i4.107
- NOVAKOV, N., BUJELIC-CABRILLO, O., CIRVIC, M., JUBOJEVIK, D. LUJIC, J. (2013): Eustrongylidosis of European Catfish (*Silurus glanis*). *Bulg. J. Agric. Sci.*, 1: 72 – 76
- OGDEN, J.C. (1994): A comparison of wading bird nesting dynamics, 1931 – 1946 and 1974 – 1989, as an indication of change in ecosystem conditions in the southern Everglades, Florida. In DAVIS, S., OGDEN, J.C. (Eds) *Everglades: The ecosystem and its restoration*. Saint Lucie Press, Delray Beach, Florida, 533 – 570
- OVERSTREET R.M. (2003): Presidential address: flavor buds and other delights. *J Parasitol*, 89(6): 1093 – 1107. DOI:10.1645/GE-236
- PAPERNA, I. (1974): Hosts distribution and pathology of infections with larvae of *Eustrongylides* (Diectophymidae, Nematoda) in fish

- from East African lakes. *J Fish Biol*, 6: 67–76. DOI: 10.1111/j.1095-8649.1974.tb04523.x
- PARKER, G.A., BALL, M.A., CHUBB, J.C. (2009): To grow or not to grow? Intermediate and paratenic hosts as helminth life cycle strategies. *J Theor Biol*, 25: 135 – 147. DOI: 10.1016/j.jtbi.2009.01.016
- PEKMEZCI, G.Z., BOLUKBAS, C.S. (2021): Morphological and molecular characterization of *Eustrongylides excisus* larvae (Nematoda: Dioctophymatidae) in *Sander lucioperca* (L.) from Northern Turkey. *Parasitol Res*, 120(6): 2269 – 2274. DOI: 10.1007/s00436-021-07187-8
- PERKINS, S.E. (2010): Invasion biology and parasitic infections. In: OSTFELD, R.S., KEESING, F., EVINER, V.T. (Eds) Infectious disease ecology: effects of ecosystems on disease and of disease on ecosystems. *Princeton Univ. Press*, 179 – 204.
- POLLEY, L., THOMPSON, R.C.A. (2009): Parasite zoonoses and climate change: Molecular tools for tracking shifting boundaries. *Trends Parasitol*, 25: 285 – 291. DOI: 10.1016/j.pt.2009.03.007
- RUDOLPHI, C.A. (1802): Beschreibung von *Strongylus gigas* [Description of *Strongylus gigas*]. *Beitr. Anat. Physiol. Tiere*, 1, 115 – 116 (In German)
- SATTARI, M., KHARA, H., NEZAMI, S., DAGHIGH, R., SHAFII, S. (2005): Occurrence and intensity of some nematodes in the bonyfish species of the Caspian Sea and its basin. *Bull. Eur. Assoc. Fish Pathol.*, 25: 166 – 178
- SELVER, M., AYDOĞDU, A., CİRAK, V. (2009): Helminth communities of the roach (*Rutilus rutilus*) from Kocadere stream in Bursa, Turkey: Occurrence, intensity, seasonality and their infestations linked to host fish size. *Bull. Eur. Assoc. Fish Pathol.*, 29: 131 – 138
- SELVER, M., AYDOĞDU, A., CİRAK, V. (2010): Helminth parasites of white bream (*Blicca bjoerkna* L. 1758) from Kocadere stream, Bursa. *Turkiye Parazit Derg.* 34: 118 – 121
- SHIRAZIAN, D., SCHLLER, E.L., GLASER, C.A., VONDEERFECHT, S.L. (1984): Pathology of larval *Eustrongylides* in the rabbit. *J Parasitol*, 70 (5): 803 – 806
- SHUKEROVA, S., KIRIN, D., HANZELOVA, V. (2010): Endohelminth communities of the perch, *Perca fluviatilis* (Perciformes, Percidae) from Srebarna Biosphere Reserve, Bulgaria. *Helminthologia*, 47: 99 – 104. DOI: 10.2478/s11687-010-0016-9
- SLOBODA, M., MIHALCA, A., FALKA, I., PETRZELKOVA, K., CARLSSON, M., GHIRA, I., MODRY, D. (2010): Are gobiid fish more susceptible to predation if parasitized by *Eustrongylides excisus*? An answer from robbed snakes. *Ecol Res*, 25: 469 – 473. DOI: 10.1007/s11284-009-0676-4
- SOYLU, E. (2013): Metazoan Parasites of Perch *Perca fluviatilis* L. From Lake Sığirci, Ipsala, Turkey. *Pakistan J Zool*, 45 (1): 47 – 52
- SPALDING M.G., FORRESTER D.J. (1993): Pathogenesis of *Eustrongylides ignotus* (Nematoda: Dictiophymatoidea) in Ciconiiformes. *J Wildl Dis*, 29: 250-260. DOI: 10.7589/0090-3558-29.2.250
- SPALDING, M.G. (1990): Antemortem diagnosis of Eustrongylidosis in wading birds (Ciconiiformes). *Col. Waterbirds*, 13 (1): 75 – 77. DOI: 10.2307/1521425
- SEBEKTI, S., KURNIWAN, M.R., SUDJARWO, S.A. (2020): Identification and prevalence infection of helminth in the gastrointestinal tract swamp eel (*Synbranchus bengalensis*) which marketed in Surabaya, East Java. *IIOF Conf. Ser.: Earth Environ. Sci.*, 441, 012146.
- ŠVAZAS, S., CHUKALOVA, N., GRISHANOV, G., PUTYS, Ž., SRUOGA, A., BUTKAUSKAS, D., RAUDINIKIS, L., PRAKAS, P. (2011): The role of great cormorant (*Phalacrocorax carbo sinensis*) for fish stock and dispersal of helminthes parasites in the Curonian lagoon area. *Vet Med Zoot*, 55: 79 – 85
- VENTURA, A.S., ISHIKAWA, M.M., GABRIEL, A.M.A., SILBINGER, H.L.N., CAVICHIOLLO, F., TAKEMOTO, R.M. (2016): Histopathology from liver of tuvira (*Gymnotus* spp.) parasitized by larvae of nematodes. *Cienc Rural*, 47: 1233 – 1239. DOI: 10.1590/0103-8478cr20150881
- WESTRAM, A.M., BAUMGARTNER, C., KELLER, I., JOKELA, J. (2011): Are cryptic host species also cryptic to parasites? Host specificity and geographical distribution of acanthocephalan parasites infecting freshwater Gammarus. *Infect Genet Evol*, 11: 1083 – 1090. DOI: 10.1016/j.meegid.2011.03.024
- WITTNER, M., TURNER, J.W., JACQUETTE, G., ASH, L.R., SALGO, M.P., TANOVITZ, H.B. (1989): Eustrongylidiasis: A parasitic infection acquired by eating sushi. *N Engl J Med*, 320: 1124-1126. DOI: 10.1056/NEJM198904273201706
- XIONG, F., LI, W., WU, S., ZOU, H., WANG, G. (2012): Molecular Phylogeny and Host Specificity of the Larval *Eustrongylides* (Nematoda: Dioctophmidae) From Freshwater Fish in China. *J Parasitol*, 99: 137 – 144. DOI: 10.1645/GE-3163.1
- YAMAGUTI, S. (1961): *Systema Helminthum. Pt. II, v. III. The nematodes of vertebrates*. N.Y., London, 1126.
- ZIEGLER, A.F., WELTE, S.C., MILLER, E.A., NOLAN, T.J. (2000): Eustrongylidiasis in eastern great blue herons (*Ardea herodias*). *Avian Dis*, 44(2): 443 – 448