



CASE REPORT

Case report: Heterotopic intrarenally located adrenocortical oncocytoma [v1; ref status: approved with reservations 2, <http://f1000r.es/34h>]

Konstantin Godin¹, Nicole Bang², Yuri Tolkach³

¹Südharz Klinikum Nordhausen gGmbH, Urology Clinic, Nordhausen, 99734, Germany

²Südharz Klinikum Nordhausen gGmbH, Pathology Clinic, Nordhausen, 99734, Germany

³Medizinische Hochschule Hannover, Urology and Urologic Oncology Clinic, Hannover, 30625, Germany

v1 First published: 17 Mar 2014, 3:73 (doi: [10.12688/f1000research.3780.1](https://doi.org/10.12688/f1000research.3780.1))
 Latest published: 12 May 2014, 3:73 (doi: [10.12688/f1000research.3780.2](https://doi.org/10.12688/f1000research.3780.2))

Abstract

The clinical case of a 65-year-old woman with an incidentally detected left-sided mass in the upper renal pole is presented. A functional adrenal tumor was excluded. The mass was removed retroperitoneoscopically. The perioperative period was uneventful. The histopathological examination revealed a heterotopic intrarenal adrenocortical oncocytoma. Adrenal oncocytic neoplasms are very rare, with, to the authors' knowledge, only 159 described cases so far. Most cases are non-functioning adenomas that can reach a considerable size. Only 10 heterotopic adrenal oncocytomas have been described (three retroperitoneal and seven intraspinal cases). Although the intrarenal adrenal rest is the most frequently appearing variant of adrenal heterotopia, to the best of our knowledge, this report is the first description of an intrarenally growing adrenocortical oncocytic adenoma. In addition to retroperitoneally located oncocytomas, this case could be interesting for urological practice because there are no diagnostic features which could provide a secure preoperative diagnosis of an adrenal oncocytic neoplasm and its malignant variant. Generally accepted indications for surgery of adrenal masses have to be respected. The definitive pathologic diagnosis is in most cases surprising because of its rarity. Benign adrenal oncocytic neoplasms do not require any adjuvant treatment. The oncocytic variant of adrenocortical carcinoma generally has a poor prognosis.

Open Peer Review

Invited Referee Responses

	1	2
version 1 published 17 Mar 2014	 report	 report
	1	1
version 2 published 12 May 2014 REVISED	 report	 report

- 1 **M Hammad Ather**, Aga Khan University
Pakistan
- 2 **Levent Turkeri**, Marmara University
School of Medicine Turkey

Latest Comments

No Comments Yet

Corresponding author: Konstantin Godin (konstantin.m.godin@gmx.de)

How to cite this article: Godin K, Bang N and Tolkach Y. **Case report: Heterotopic intrarenally located adrenocortical oncocytoma [v1; ref status: approved with reservations 2, <http://f1000r.es/34h>]** *F1000Research* 2014, 3:73 (doi: [10.12688/f1000research.3780.1](https://doi.org/10.12688/f1000research.3780.1))

Copyright: © 2014 Godin K *et al.* This is an open access article distributed under the terms of the [Creative Commons Attribution Licence](#), which permits unrestricted use, distribution, and reproduction in any medium, provided the original work is properly cited. Data associated with the article are available under the terms of the [Creative Commons Zero "No rights reserved" data waiver](#) (CC0 1.0 Public domain dedication).

Grant information: The author(s) declared that no grants were involved in supporting this work.

Competing interests: No competing interests were disclosed.

First published: 17 Mar 2014, 3:73 (doi: [10.12688/f1000research.3780.1](https://doi.org/10.12688/f1000research.3780.1))

Case report

A 65-year-old Caucasian woman with a history of arterial hypertension underwent an ultrasound examination of the kidneys performed by her general practitioner in 2012. A left-sided suprarenal mass measuring about 5 cm was detected. The physical examination showed no palpable masses in the abdomen, and the peripheral lymph nodes were not enlarged. A 3-T magnetic resonance imaging (MRI) of the adrenal glands presented a heterogeneously enhancing mass measuring 48×48×33 mm in the left apical renal pole in contact with the adrenal gland (Figure 1). The findings seemed to suggest the presence of a renal cell carcinoma. A differential diagnosis of pheochromocytoma had also been considered. Enlarged intra- or retroperitoneal lymph nodes were not detectable in the MRI. Catecholamines and metanephrines, aldosterone-renin ratio and serum cortisol before and after inhibition were within normal range in a 24 hour-urine sample analysis. Thus, a functional adrenal tumor could be excluded.

The patient underwent a retroperitoneoscopic exploration. A round shaped 4.5 cm exophytic mass of the upper renal pole was excised retroperitoneoscopically in the fashion of a renal mass enucleation applying the zero-ischemia technique. Intraoperatively, the mass had a very thin, poorly defined pseudo-capsule which was adhering to the renal parenchyma caudally and to the macroscopically inconspicuous adrenal gland medially. The adrenal gland was removed *en bloc* with the mass (Figure 2). No judgement could be made regarding the origin of the tumor. The postoperative recovery period was uneventful. Histopathological examination (haematoxyline-eosin) of the specimen revealed an oncocytic adrenocortical adenoma that arose from the heterotopic intrarenal adrenal tissue (Figure 3).

The follow-up of this patient (approximately 2 years by the date of article submission) was uneventful. No additional treatment was necessary.

Discussion

Oncocytic neoplasms of the adrenal glands are extremely rare. A PUBMED search up to December 2013 uncovered only 159 cases

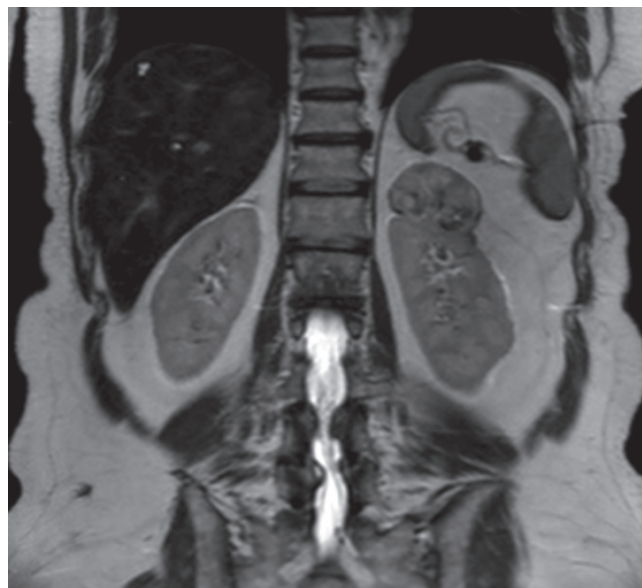


Figure 1. Mass in the left upper renal pole (T2-weighted MR image) with a size of 48×48×33 mm having a diffusely heterogeneous structure.

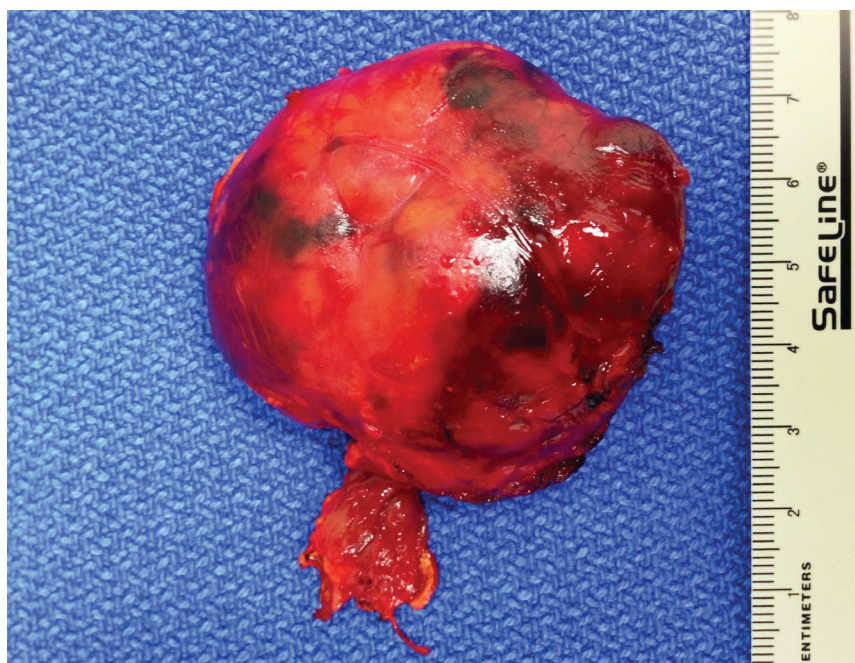

Figure 2. Specimen with adjacent part of left adrenal gland after retroperitoneoscopically performed tumor enucleation.



Figure 3. Histopathology section showing diffuse proliferation of oncocytes (Haematoxyline-eosin staining, magnification 200x).

of adrenocortical oncocytomas since the first description of this tumor in adrenal in 1986¹⁷. Most of the papers describe only single patient case reports.

Oncocytic neoplasms or oncocytomas are mostly benign tumors which commonly occur in the kidneys, thyroid, parathyroid, pituitary and salivary glands^{1,2} and rarely in the respiratory tract^{3,4}, choroid plexus⁵ and adrenal glands. Oncocytic neoplasms of the adrenal glands, with, to the authors' knowledge, only 159 previously described cases, are an extremely rare phenomenon. Most of these tumors were discovered as incidental findings on CT or MRI as non-functional adrenal masses. Various malignant potential can be determined in 20% of adrenocortical oncocytic neoplasms⁶. Oncocytomas arising from the heterotopic adrenocortical tissue have been described in only 10 case reports, seven cases were located intraspinally⁷⁻¹³ and three cases in the retroperitoneum¹⁴⁻¹⁶. An oncocytic adenoma arising from heterotopic intrarenal adrenocortical tissue was not suspected in the preoperative assessment of this case because this entity has not been described previously. However, in addition to retroperitoneally located oncocytomas, this should be considered in the future as a differential diagnosis in cases presenting with an intrarenal or retroperitoneal mass.

This paper contains the first report on an oncocytic adenoma arising from the heterotopic intrarenal located adrenal tissue. Heterotopic adrenal tissue or adrenal rest presented mostly by cortical structures is more frequently located in the kidney. Other sites such as the celiac trunk, epididymis, spermatic cord, ovary, broad ligament, liver capsule, gallbladder, pancreas and spleen are rare¹⁸.

Oncocytic neoplasms are mostly encapsulated masses with a brown or yellow surface on cut-section. The radial scar can be absent.

Oncocytic neoplasms microscopically consist of so called oncocytes, large cells with rich eosinophilic granulations due to the high concentration of mitochondria. The Weiss criteria¹⁹, which are commonly used in the histological diagnosis of adrenocortical malignancies, are not applicable to adrenocortical oncocytic neoplasms because all tumors have eosinophilic tumor cytoplasm, diffuse architecture and nuclear atypia. The modified Lin-Weiss-Bisceglia system differentiates between major, minor and definitional criteria for malignancy⁶. None of these criteria is present in benign adrenal oncocytic neoplasms. Masses with uncertain malignant potential demonstrate the presence of one to four minor criteria (>10 cm or >200g, necrosis, capsular invasion or sinusoidal invasion) in absence of major criteria (mitotic rate >5 mitoses per 50 high-power fields, any atypical mitoses or venous invasion). In adrenal oncocytic carcinomas any of the major criteria could be present.

There are no specific criteria on both computed tomography and MRI and MRI with chemical shift subtraction for adrenal oncocytic neoplasm and its malignant variant²⁰. The bulk size cannot be used as a reliable criterion to estimate the risk of malignancy.

Eighty-three percent of adrenal oncocytic neoplasms are non-functioning masses²¹. In rare cases, an adrenal oncocytic neoplasm can produce catecholamines, cortisol or testosterone²¹.

The therapeutic standard is a minimally invasive adrenalectomy. In cases of a large mass, infiltration of surrounding structures, and lymph node bulks, an open surgery approach should be chosen.

Today, there are no recommendations for the follow-up of benign adrenal oncocytic neoplasms. Only one local recurrence of a neoplasm that was originally diagnosed as benign has been described and fulfilled the criteria of uncertain malignant potential²¹. The oncocytic variant of adrenocortical carcinoma has a poor prognosis, with a postoperative recurrence rate of 75%, and a tumour-related mortality of 40% in a small group of 24 patients with a median follow-up of 21 months (range: 1 – 180 months)²¹. An adjuvant or palliative chemotherapy with mitotane can be administered in patients with adrenocortical carcinomas with beneficial effects²², but there is no evidence of efficacy when applied to oncocytic variant.

Conclusion

To the authors' knowledge, this case report presents the first description of a heterotopic intrarenally located adrenocortical oncocytoma. Although being a rare location, this case is worth mentioning, given the challenging situation with regard to the diagnostics and differentiation from the potentially aggressive malignant lesions. Taking in account the absence of radiological criteria of a benign character, this tumor should be considered and treated as a malignant lesion, although a minimally invasive approach should be chosen when possible. The definitive pathologic diagnosis is in most cases surprising because of the rarity of this type of neoplasm and radiological appearance mimicking renal cell carcinoma or adrenal carcinoma. Benign adrenal oncocytic neoplasms do not require any adjuvant treatment.

Informed consent

Written informed consent for the publication of clinical details and clinical images was obtained from the patient.

Author contributions

KG was an operating surgeon, conceived the article, drafted the manuscript and reviewed it for critical intellectual content. NB performed the histological examination, acquired the data and critically reviewed the manuscript for important intellectual content. YT

contributed to data acquisition, drafted the manuscript and reviewed it for critical intellectual content. All authors were involved in the revision of the draft manuscript and have agreed to the final content.

Competing interests

No competing interests were disclosed.

Grant information

The author(s) declared that no grants were involved in supporting this work.

References

- Chang A, Harawi SJ: **Oncocytes, oncocytosis and oncocytic tumors.** *Pathol Annu.* 1992; **27**(Pt 1): 263–304.
[PubMed Abstract](#)
- Tallini G: **Oncocytic tumours.** *Virchows Arch.* 1998; **433**(1): 5–12.
[PubMed Abstract](#)
- Tsuta K, Kalhor N, Raso MG, *et al.*: **Oncocytic neuroendocrine tumors of the lung: histopathologic spectrum and immunohistochemical analysis of 15 cases.** *Hum Pathol.* 2011; **42**(4): 578–585.
[PubMed Abstract](#) | [Publisher Full Text](#)
- Kozakiewicz J, Teodorowicz E, Haczyńska-Partyka A, *et al.*: **[Adenoma oxyphilicum, an extremely rare case of tumour of the larynx end cancer lungs which are going together].** *Otolaryngol Pol.* 2007; **61**(3): 311–4.
[PubMed Abstract](#) | [Publisher Full Text](#)
- Sav A, Scheithauer BW, Mazzola CA, *et al.*: **Oncocytic choroids plexus carcinoma: case report.** *Clin Neuropathol.* 2010; **29**(1): 14–20.
[PubMed Abstract](#) | [Publisher Full Text](#)
- Bisceglia M, Ludovico O, Di Mattia A, *et al.*: **Adrenocortical oncocytic tumors: report of 10 cases and review of the literature.** *Int J Surg Pathol.* 2004; **12**(3): 231–243.
[PubMed Abstract](#) | [Publisher Full Text](#)
- Schittenhelm J, Ebner FH, Harter P, *et al.*: **Symptomatic intraspinal oncocytic adrenocortical adenoma.** *Endocr Pathol.* 2009; **20**(1): 73–77.
[PubMed Abstract](#) | [Publisher Full Text](#)
- Kepes JJ, O'Boynick P, Jones S, *et al.*: **Adrenal cortical adenoma in the spinal canal of an 8-year-old girl.** *Am J Surg Pathol.* 1990; **14**(5): 481–484.
[PubMed Abstract](#)
- Cassarino DS, Santi M, Arruda A, *et al.*: **Spinal adrenal cortical adenoma with oncocytic features: report of the first intramedullary case and review of the literature.** *Int J Surg Pathol.* 2004; **12**(3): 259–264.
[PubMed Abstract](#) | [Publisher Full Text](#)
- Karikari IO, Uschold TD, Selznick LA, *et al.*: **Primary spinal intramedullary adrenal cortical adenoma associated with spinal dysraphism: case report.** *Neurosurgery.* 2006; **59**(5): E1144.
[PubMed Abstract](#) | [Publisher Full Text](#)
- Kim SH, Paik S, Yoon DH, *et al.*: **Oncocytoma of the spinal cord. Case report.** *J Neurosurg.* 2001; **94**(2 Suppl): 310–312.
[PubMed Abstract](#) | [Publisher Full Text](#)
- Park DH, Park YK, Oh JI, *et al.*: **Oncocytic paraganglioma of the cauda equina in child. Case report and review of the literature.** *Pediatr Neurosurg.* 2002; **36**(5): 260–265.
[PubMed Abstract](#) | [Publisher Full Text](#)
- Park HS, Jang KY, Kang MJ, *et al.*: **Oncocytoma of the spinal cord causing paraplegia - a case report.** *Spinal Cord.* 2007; **45**(2): 183–186.
[PubMed Abstract](#) | [Publisher Full Text](#)
- Corsi A, Riminucci M, Petrozza V, *et al.*: **Incidentally detected giant oncocytoma arising in retroperitoneal heterotopic adrenal tissue.** *Arch Pathol Lab Med.* 2002; **126**(9): 1118–1122.
[PubMed Abstract](#) | [Publisher Full Text](#)
- Nguyen GK, Vriend R, Ronaghan D, *et al.*: **Heterotopic adrenocortical oncocytoma. A case report with light and electron microscopic studies.** *Cancer.* 1992; **70**(11): 2681–2684.
[PubMed Abstract](#) | [Publisher Full Text](#)
- Surrey LF, Thaker AA, Zhang PJ, *et al.*: **Ectopic functioning adrenocortical oncocytic adenoma (oncocytoma) with myelolipoma causing virilization.** *Case Rep Pathol.* 2012; **2012**: 326418.
[PubMed Abstract](#) | [Publisher Full Text](#) | [Free Full Text](#)
- Smirnova EA, Mikhailov IG: **[Electron microscopic characteristics of oncocytoma of the lung, small intestine and adrenal gland].** *Arkh Pathol.* 1986; **48**(6): 79–81.
[PubMed Abstract](#)
- Lloyd R: **Endocrine Pathology.** New York, Springer-Verlag, 1990.
[Publisher Full Text](#)
- Medeiros LJ, Weiss LM: **New developments in the pathologic diagnosis of adrenal cortical neoplasms. A review.** *Am J Clin Pathol.* 1992; **97**(1): 73–83.
[PubMed Abstract](#)
- Monk IP, Lahiri R, Sivaprakasam R, *et al.*: **Adrenocortical oncocytoma: Review of imaging and histopathological implications.** *Int J Surg Case Rep.* 2010; **1**(3): 30–32.
[PubMed Abstract](#) | [Publisher Full Text](#) | [Free Full Text](#)
- Wong DD, Spagnolo DV, Bisceglia M, *et al.*: **Oncocytic adrenocortical neoplasms—a clinicopathologic study of 13 new cases emphasizing the importance of their recognition.** *Hum Pathol.* 2011; **42**(4): 489–499.
[PubMed Abstract](#) | [Publisher Full Text](#)
- Kerkhofs TM, Baudin E, Terzolo M, *et al.*: **Comparison of two mitotane starting dose regimens in patients with advanced adrenocortical carcinoma.** *J Clin Endocrinol Metab.* 2013; **98**(12): 4759–4767.
[PubMed Abstract](#) | [Publisher Full Text](#)

Open Peer Review

Current Referee Status:



Referee Responses for Version 1



Levent Turkeri

Department of Urology, Marmara University School of Medicine, Istanbul, Turkey

Approved with reservations: 09 April 2014

Referee Report: 09 April 2014

doi: [10.5256/f1000research.4049.r4152](https://doi.org/10.5256/f1000research.4049.r4152)

This is a report of a very interesting case of a heterotopic intrarenal adrenocortical oncocytoma.

As the authors stated this may be the first reported case in the literature.

The major concern is the appearance of the mass in relation to the kidney at figure 1, exactly at the location of left adrenal gland. The authors stated that they performed a retroperitoneoscopic enucleation and, intraoperatively, the mass had a very thin, poorly defined pseudo-capsule which was adhering to the renal parenchyma as well as to the macroscopically inconspicuous adrenal gland.

These observations raise the possibility that this mass was in fact arising from the adrenal gland itself and not from a heterotopic location within the kidney. A tumor of 4.5 cm located intrarenally would be difficult to enucleate without interfering with any renal parenchyma and therefore vascular structures - causing bleeding.

The provided histopathological figure displays only diffuse sheets of oncocytic cells without any evidence any surrounding renal tissue.

I would recommend a repeat discussion with the pathologist to see if this not really an adrenal oncocytoma, which would be still a rare entity, albeit with more than 50 cases reported in the literature.

I have read this submission. I believe that I have an appropriate level of expertise to confirm that it is of an acceptable scientific standard, however I have significant reservations, as outlined above.

Competing Interests: No competing interests were disclosed.

1 Comment

Author Response

Yuri Tolkach, Urology Clinic, Military Medical Academy, Russian Federation

Posted: 07 May 2014

Dear Professor Turkeri,

Thank you for your evaluation.

Indeed, this tumor arose from the renal parenchyma and in fact left adrenal was intact and had no continuous contact to the tumor.

We have discussed your concerns with the pathologist and in the revised version of the article we will provide a pathology slice, where the nearby renal parenchyma and normal adrenal cells could be seen direct by the tumor, making the final diagnosis undoubtful.

With best wishes,

Konstantin Goding, Nicole Bang and Yuri Tolkach

Competing Interests: None



M Hammad Ather

Department of Surgery, Aga Khan University, Karachi, 74800, Pakistan

Approved with reservations: 07 April 2014

Referee Report: 07 April 2014

doi: [10.5256/f1000research.4049.r4146](https://doi.org/10.5256/f1000research.4049.r4146)

The authors report a heterotopic adrenal oncocytoma in a 65 year-old lady with essential hypertension. A routine ultrasound detected a 5 cm adrenal mass, however, MRI showed a 4.8 x 4.8 x 3.3 cm mixed intensity upper polar renal mass. Features were not suggestive of a malignant tumour. Urinary and blood work up excluded a functioning adrenal adenoma. The oncocytoma was removed retroperitoneoscopically with the zero-ischemia technique.

It is a well written report, however, I have the following observations on the current submission:

1. The sequence of the work up is not clear: was the MRI done first; or were urinary catecholamines and metanephrines, aldosterone-renin ratio and serum cortisol determined first? In the latter case, why was a pheochromocytoma suspected when neither the clinical manifestations nor imaging (MR) suggested a pheochromocytoma?
2. The authors have rightly noted that the imaging characteristics of benign and malignant oncocytoma are not clearly described in the current literature - they were entertaining a diagnosis of an RCC pre-operative. Did the authors consider doing a biopsy prior to surgical intervention? It would be pertinent to mention indications for biopsy in such a situation, and discuss its merits and demerits.

I have read this submission. I believe that I have an appropriate level of expertise to confirm that it is of an acceptable scientific standard, however I have significant reservations, as outlined above.

Competing Interests: No competing interests were disclosed.

1 Comment

Author Response

Yuri Tolkach, Urology Clinic, Military Medical Academy, Russian Federation

Posted: 07 May 2014

Dear Dr. Ather,

Thank you for your valuable comments.

With regard to the first point: hormonal evaluation was done after MRI investigation to exclude the probability of hormone-producing tumor, while the tumor was located very close to the adrenal, though the probability was indeed very small. It was done according to the local guidelines.

Concerning the second point, based on contemporary evidence it is hard to discuss the necessity of biopsy both in adrenal and renal tumors. We did not consider this diagnostic modality. In our opinion, in this case there was no place for the biopsy.

With kind regards,

Konstantin Godin, Nicole Bang and Yuri Tolkach

Competing Interests: None