



CASE REPORT

REVISED Case Report: Heparin-induced thrombocytopenia during COVID-19 outbreak: the importance of scoring system in differentiating with sepsis-induced coagulopathy [version 2; peer review: 2 approved]

Louisa Fadjri Kusuma Wardhani ^{1,2}, Ivana Purnama Dewi ¹⁻³,
Denny Suwanto ^{1,2}, Ade Meidian Ambari⁴, Meity Ardiana^{1,2,5}

¹Faculty of Medicine, Airlangga University, Surabaya, Indonesia

²Department of Cardiology and Vascular Medicine, Dr. Soetomo Hospital, Surabaya, Indonesia

³Faculty of Medicine, Duta Wacana Christian University, Yogyakarta, Indonesia

⁴University of Indonesia, Jakarta, Indonesia

⁵Department of Cardiology and Vascular Medicine, Bhayangkara H.S Samsueroi Mertojoso Hospital, Surabaya, Indonesia

V2 First published: 14 Jun 2021, 10:469
<https://doi.org/10.12688/f1000research.52425.1>

Latest published: 26 Aug 2021, 10:469
<https://doi.org/10.12688/f1000research.52425.2>

Abstract

Background: COVID-19 disease is accompanied by derangement of coagulation with a risk of fatal thromboembolic formation. COVID-19 patients are among those indicative for heparin treatment. Increased heparin administration among COVID-19 patients increased heparin induced-thrombocytopenia's risk with/without thrombocytopenia.

Case presentation: We present a 71-year-old male patient who came to the emergency room (ER) with a COVID-19 clinical manifestation followed by positive PCR nasopharyngeal swab result. He was assessed to have acute respiratory distress syndrome (ARDS), as shown by rapid progression of hypoxemic respiratory failure and bilateral pulmonary infiltrate. He was then treated with moxifloxacin, remdesivir, dexamethasone, unfractionated heparin (UFH) pump, and multivitamins. During admission, his respiratory symptoms got worse, so he transferred to the ICU for NIV support. On the ninth day of admission, he had gross hematuria followed by a rapid fall of platelet count. We used two different scoring systems (4Ts and HEP scoring system) to confirm the diagnosis of heparin-induced thrombocytopenia (HIT). Following the discontinuation of UFH injection, the thrombocyte continued to rise, and hematuria disappeared.

Conclusion: Heparin-induced thrombocytopenia is associated with an increased risk of severe disease and mortality among COVID-19 patients. The differential diagnosis of HIT could be difficult as thrombocytopenia can also be caused by the progression of infection.

Open Peer Review

Reviewer Status

Invited Reviewers

1 2

version 2

(revision)
26 Aug 2021

version 1

14 Jun 2021



report



report

1. **Alan Fong**, Sarawak Heart Centre, Kota Samarahan, Malaysia

2. **Anggoro Budi Hartopo**, Universitas Gadjah Mada, Jogjakarta, Indonesia

Any reports and responses or comments on the article can be found at the end of the article.

We use two scoring systems (4Ts and HEP scoring) in order to help us managing the patient. These could improve the outcomes, thus avoiding morbidity and mortality.

Keywords

Heparin Induced Thrombocytopenia, HIT, COVID-19, mortality

Corresponding author: Meity Ardiana (meityardiana@fk.unair.ac.id)

Author roles: **Wardhani LFK:** Conceptualization, Data Curation, Formal Analysis, Visualization, Writing – Original Draft Preparation, Writing – Review & Editing; **Dewi IP:** Conceptualization, Formal Analysis, Writing – Review & Editing; **Suwanto D:** Formal Analysis, Writing – Review & Editing; **Ambari AM:** Formal Analysis, Writing – Review & Editing; **Ardiana M:** Conceptualization, Funding Acquisition, Supervision, Validation, Writing – Review & Editing

Competing interests: No competing interests were disclosed.

Grant information: The author(s) declared that no grants were involved in supporting this work.

Copyright: © 2021 Wardhani LFK *et al.* This is an open access article distributed under the terms of the [Creative Commons Attribution License](#), which permits unrestricted use, distribution, and reproduction in any medium, provided the original work is properly cited.

How to cite this article: Wardhani LFK, Dewi IP, Suwanto D *et al.* **Case Report: Heparin-induced thrombocytopenia during COVID-19 outbreak: the importance of scoring system in differentiating with sepsis-induced coagulopathy [version 2; peer review: 2 approved]** F1000Research 2021, 10:469 <https://doi.org/10.12688/f1000research.52425.2>

First published: 14 Jun 2021, 10:469 <https://doi.org/10.12688/f1000research.52425.1>

REVISED Amendments from Version 1

There are some revisions from the initial manuscript regarding the case presentation. We add minor information supporting the use of both scoring systems in our cases and how it helps us determine the involvement of HIT. The drug of choice for those suspected for HIT is argatroban and danaparoid with several recommendations regarding secondary prevention of HIT using rivaroxaban and fondaparinux. Since the availability of some drugs are limited and this patient experiences ongoing hematuria, We prefer rivaroxaban as an exchange. Moreover, the use of rivaroxaban twice daily has non-inferior efficacy than those with fondaparinux. Ade Meidian Ambari has been added to the author list for his contribution to the formal analysis and writing and reviewing of this version 2.

Any further responses from the reviewers can be found at the end of the article

Background

The outbreak of the novel-coronavirus SARS-CoV-2 was first identified in Wuhan, China, in January 2020. This was later classified as a pandemic because it affected more than 114 countries with more than two million cases. The infection manifest as fever, dry cough, myalgia, diarrhea, and anosmia. Acute respiratory distress syndrome (ARDS) can be a manifestation of severe cases, which is shown by rapid progression of hypoxemic respiratory failure and bilateral pulmonary infiltrate. Hypercoagulability often complicates COVID-19 infection as part of its pathophysiology and some may progress into venous and arterial thrombosis.¹ The laboratory results of COVID-19 patients show an elevated D-dimer concentration, increased fibrin degradation products (FDP), and lower antithrombin levels. These are the reasons for anticoagulation administration among COVID-19 patients. Heparin is the agent of choice for anticoagulation, especially in those with severe COVID-19 manifestation.²⁻⁵

Although heparin is commonly used in COVID-19 patients, its side effects cannot be forgotten. The most avoided side effect, which is potentially fatal with 20% mortality rates, is heparin induced thrombocytopenia (HIT) with/without thrombocytosis. This is caused by the formation of antibodies (IgG) against the complex of platelet factor 4 (PF4) and heparin. The PF4/IgG antibodies complex can activate platelets, which can cause catastrophic thrombosis. It can occur within 5–10 days of heparin therapy in 0.5–3% of patients. It can also develop rapidly within 24 hours after re-exposure of heparin in some patients with a recent heparin administration history.^{2,6,7} An increasing incidence of HIT occurs among COVID-19 patients, explained by exacerbated immune reactions and probably by an increased release of PF4, linked to platelet activation. However, the underlying pathophysiology of increased HIT risk and thrombosis risk in COVID-19 patients is not yet well understood.⁸ We present a HIT case with severe thrombocytopenia followed by gross hematuria manifestation in a COVID-19 patient.

Case presentation

A 71-year-old male patient presented to the emergency room (ER) with a chief complaint of dry cough for one week followed by dyspnea and febrile that had increased three days before admission. He had a fever one week prior admission that relieved with acetaminophen, and no other complaints were reported. He had no contact history with confirmed COVID-19 patients. He has history of diabetes mellitus, hypertension, and myocardial infarction. He previously consumed aspirin, bisoprolol, lisinopril, diltiazem, atorvastatin and subcutaneous insulin.

His blood pressure (BP) was 132/75 mmHg, heart rate (HR) 79 beats per minutes (bpm) regular, and respiratory rate (RR) of 28 breaths per minute, with oxygen saturation of 85% (free air) that improved to 95% with a non-rebreathing oxygen mask (NRM) 15 Liters per minute. His physical examination showed no increased jugular venous pressure, bilateral lung crackles, pleural friction rub, and leg edema.

Comprehensive evaluations were performed, including ECG, COVID-19 antigen swab, laboratory examination, and chest radiography. His initial ECG showed normal sinus rhythm of 79 bpm, left axis deviation, with inferior OMI. Laboratory data showed increased CRP (195.3 mg/L), hypokalemia (3.2 mEq/L), respiratory failure, and respiratory acidosis. Chest radiography showed cardiomegaly and bilateral pneumonia. COVID-19 antigen swab was positive. Thus patient and family were consent for isolation and tracing procedure. As his blood gas showed respiratory failure with severe ARDS (P_{aO_2}/F_{iO_2} 82 mmHg), we planned on invasive ventilation, however the procedure was postponed due to unavailability of ventilator machine and intensive care unit overload.

He was then started on antibiotic treatment with moxifloxacin, antiviral therapy with remdesivir, dexamethasone, continuous infusion of unfractionated heparin (UFH) multivitamins and his daily medication (insulin, aspirin, lisinopril, beta-blockers, nitrates, and atorvastatin). Tocilizumab 400 mg was also given on the second day of admission and continued for 5 days. His vital signs and laboratory examinations were routinely monitored.

During the sixth day of admission, his oxygen saturation deteriorated. He was then put on non-invasive ventilation (NIV) with slightly better oxygen saturation (92-94%). His symptoms showed gradual improvement in several days. His laboratory examination on the tenth day showed leukocytosis, thrombocytopenia, increased neutrophil-lymphocyte ratio (NLR), increased D-Dimer. No prolonged hemostatic values were found. Plasma prothrombin time (PPT) was 20 sec, and activated partial thromboplastin time (APTT) was 38.6 sec.

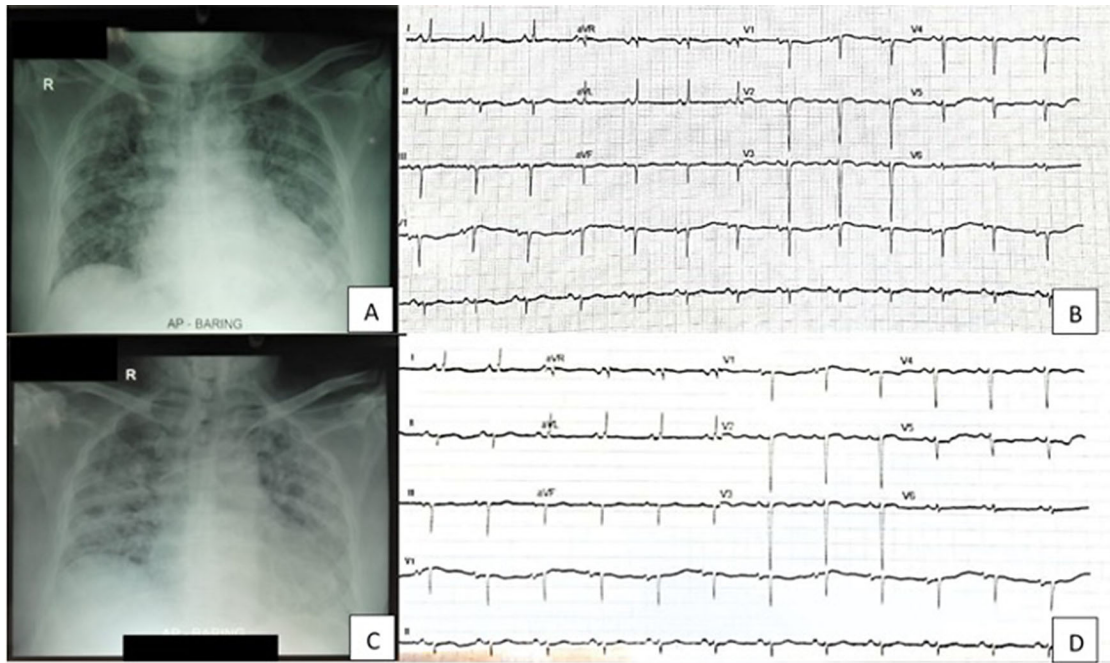


Figure 1. Radiology and electrocardiography (ECG) comparison of patient on first day admission (A, B) and ninth day admission (C, D).

(A)

Category	2 points	1 point	0 point
Thrombocytopenia	Platelet count fall > 50% and platelet nadir $\geq 20 \times 10^9 /L$ ✓	Platelet count fall 30%–50% or platelet nadir $10\text{--}19 \times 10^9 /L$	Platelet count fall < 30% or platelet nadir $< 10 \times 10^9 /L$
Timing of platelet count fall	Clear onset between days 5 and 10 or platelet fall ≤ 1 day (prior heparin exposure within 30 days) ✓	Consistent with days 5–10 fall, but not clear (e.g. missing platelet counts) or onset after day 10 or fall ≤ 1 day (prior heparin exposure 30–100 days ago)	Platelet count fall < 4 days without recent heparin exposure
Thrombosis or other sequelae	New thrombosis (confirmed) or skin necrosis at heparin injection sites or acute systemic reaction after intravenous heparin bolus	Progressive or recurrent thrombosis or non-necrotizing (erythematous) skin lesions or suspected thrombosis (not proven)	None ✓
Other causes for thrombocytopenia	None apparent	Possible	Definite ✓

Figure 2. Checklist of scoring system used in measuring HIT probability using (A) 4Ts scoring system showing 6 point and (B) HEP scoring system showing 5 point. Both measurements show high probability of HIT in this patient.

(B)

Clinical Feature	-2	-1	1	2	3
Magnitude of fall in platelet count*		<30%	30-50%		>50%
Timing of fall in platelet count					
For patients in whom typical onset HIT is suspected	Fall begins <4 days after heparin exposure	Fall begins >14 days after heparin exposure		Fall begins 4 days or 11-14 days after heparin exposure	Fall begins 5-10 days after heparin exposure
For patients with previous heparin exposure in last 100 days in whom rapid onset HIT is suspected		Fall begins >48 hours after heparin re-exposure		Fall begins <48 hours after heparin re-exposure	
Nadir platelet count	≤ 20 x 10 ⁹ /L			>20 x 10 ⁹ /L	
Thrombosis (select no more than one)					
For patients in whom typical onset HIT is suspected				Progression of pre-existing VTE or ATE while receiving heparin	New VTE or ATE ≥ 4 days after heparin exposure
For patients in whom rapid onset HIT is suspected				Progression of pre-existing VTE or ATE while receiving heparin	New VTE or ATE after heparin exposure
Skin necrosis at subcutaneous heparin injection sites					Existed
Acute systemic reaction after intravenous heparin bolus				Presented	
Presence of bleeding, petechiae, or extensive bruising		Presence			
Other cause of thrombocytopenia (Select all that apply)	Newly initiated non-heparin medication known to cause thrombocytopenia	Presence of a chronic thrombocytopenic disorder			No other apparent cause
	Indwelling intra-arterial device (e.g IABP, VAD, ECMO)	Cardiopulmonary bypass within previous 96 hours			
	Severe DIC**				
	Severe infection				
<p>*measured from peak platelet count to nadir platelet count since heparin exposure</p> <p>**defined as fibrinogen < 100 mg/dL and D-dimer > 5.0 ug/mL</p> <p>VTE, venous thromboembolism; ATE, arterial thromboembolism; DIC, disseminated intravascular coagulation; IABP, intra-aortic balloon pump; VAD, ventricular assist device; ECMO, extracorporeal membrane oxygenation</p>					

Figure 2. (continued)

On the ninth day of admission, the patient reported gross hematuria, at that time he was still on unfractionated heparin therapy within targeted APTT. Laboratory data showed significantly reduced thrombocytes (40,000 mg/L). Urine examination showed gross hematuria with leukocyturia (10–15 cells/field), nitrituria, and proteinuria (2+). The patient underwent ECG and chest radiography evaluation, which showed no significant changes (Figure 1).

Heparin was thought to be the underlying cause of thrombocytopenia in this patient. Since heparin antibody was not routinely checked in the developing country, we choose HIT's scoring system as an alternative. The scoring system shows 4Ts of 6 and HEP Scoring system of 5 (Figure 2A-B). Both 4Ts and HEP scoring indicate a high-risk probability for HIT, hence the anticoagulant was switched to rivaroxaban 20 mg twice daily. The symptoms were then improved with the absence of hematuria after 2 days. The thrombocyte evaluation showed normalization to 177,000 on the eleventh day. The patient was transferred back to the low care and discharged after 13 days.

Discussion

We report a patient presented to the ED with clinical manifestation of COVID-19 with severe ARDS (PaO_2/FiO_2 of 82 mmHg). COVID-19 patient is among those indicative for heparin treatment. Low-molecular-weight heparin is used as prophylaxis for the thromboembolic complication of COVID-19, while unfractionated heparin is commonly used in severe manifestations.

A routine evaluation of both physical and laboratory examination is needed to evaluate treatment and side effects of infection and therapy of COVID-19. A fatal side effect that can occur during heparin treatment is HIT. HIT is characterized by a fall of platelet count with/without a sign of bleeding, arterial, or venous thrombosis during heparin administration and disappears equally quickly once the heparin is withdrawn. The widely known diagnostic criteria for HIT includes (1) HIT antibodies to PF4-heparinoid complexes, (2) HIT antibodies-mediated platelet activation, (3) progressive platelet fall 40-50% from baseline, (4) thrombocytopenia occurs within 5–10 days after initiation or 24–48 hours after re-exposure of heparin, and (5) thrombosis occurs in patients treated with heparin. It should also be suspected of an unexplained fall in platelet count by 50%, skin lesion at the heparin injection site, and systemic reaction to heparin injection. Thrombocytopenia in HIT is usually moderate to severe, with the fall of platelet rarely <100,000 platelets/ μ L. It has been reported that 30–60% of patients can suffer venous events while 15–20% can suffer arterial events while bleeding manifestation is rare.^{2,5,9,10}

The differential diagnosis of HIT could be difficult among COVID-19 patients as thrombocytopenia can also be caused by infection progression. Disseminated intravascular coagulopathy (DIC) can complicate the septic status of COVID-19, called sepsis-induced coagulopathy. Thrombocytopenia is associated with an increased risk of severe disease and mortality among COVID-19 patients. On the other hand, heparin exposure is correlated with severe thrombocytopenia, suggesting that HIT may be responsible for severe thrombocytopenia in COVID-19. PF4/H antibodies or a scoring system makes the presumptive diagnosis of HIT. The measurement of PF4/H is not commonly checked in our center, so we use the scoring system to measure the possibility of HIT.^{2,5,7,9,11}

Our patient experienced a rapid fall of thrombocytes on a ninth day following gross hematuria manifestation. The clinical suspicion laid on HIT as it is known to be a fatal side effect of heparin administration. We use two scoring systems, which

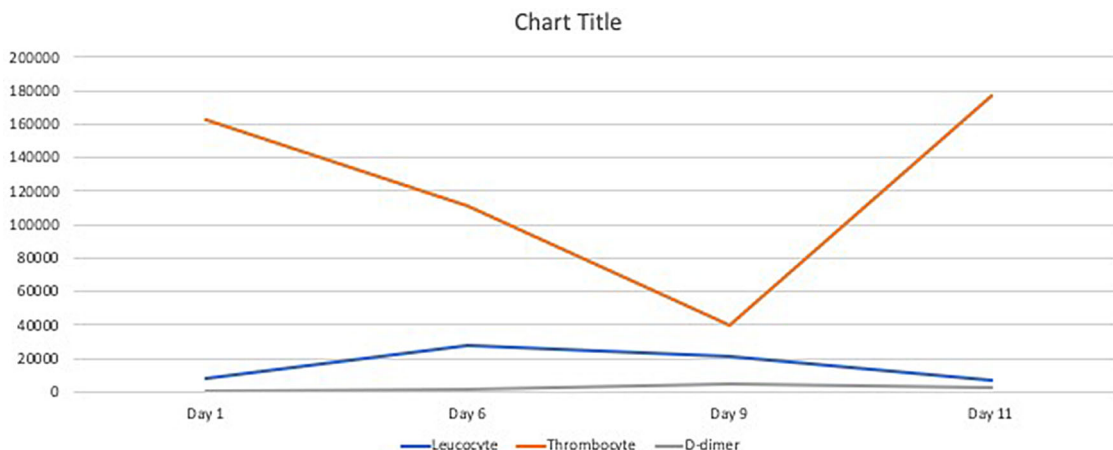


Figure 3. Summary of laboratory results.

showed a high probability of HIT in our patient using the 4Ts (5 points) and HEP scoring (5 points) system (Figure 2). The use of two different methods reduces the possibility of overdiagnosis since improper anticoagulation in COVID-19 patients can lead to worse prognosis. The 4Ts scoring system valued thrombocytopenia, timing of platelet fall, thrombosis (or other sequelae of HIT), and the absence of other thrombocytopenia cause (medication, DIC) in which the fourth indicator is subjective to the discretion of the observer. On the other hand, the HEP scoring system listed infection as a marker of thrombocytopenia which is found in COVID-19 patients. The clinician can confidently reduce the use of alternative anticoagulation due to false diagnosis in clinically oriented HIT assessment using the HEP scoring system.

When isolated HIT is suspected clinically, the discontinuation of heparin-based therapy is recommended. Clinicians shall consider the initiation of other anticoagulant agents using direct thrombin or factor Xa inhibitors to prevent thrombus formation.^{7,9} Rivaroxaban was chosen as substitute agent as it was structurally different from heparin and no cross reactivity was found to heparin-PF4 antibodies. Following the discontinuation of heparin injection and switching to rivaroxaban, the thrombocyte continued to rise, and the hematuria resolved (Figure 3).

Conclusion

There has been an escalation of heparin usage during the outbreak of SARS-CoV-2 infection as it is a known risk of fatal thromboembolic formation. HIT is a rare but fatal complication following heparin administration. As the progression of COVID-19 also shows thrombocytopenia, it is somehow ambiguous to perform discontinuation of heparin. Moreover, the measurement of PF4/H antibodies is not available in most of the centers. It makes the clinical assessment of HIT critical to risk-stratify the need to stop heparin as it also led to poor prognosis. The use of 4Ts scoring system is subjective to the observer's discretion to determine the involvement of other thrombocytopenia. However, the HEP scoring system has multiple values that help physicians determine the HIT risk probability. We used two different scoring systems (4Ts and HEP scoring systems) that show a high HIT probability. As important as diagnosing HIT, heparin product must be discontinued and substitute anticoagulant with no heparin profile is recommended based on indication.

Declaration

This case report does not require ethical approval as it is not human or animal research.

Consent

Written informed consent for publication of their clinical details and/or clinical images was obtained from the patient.

Acknowledgments

Not applicable.

Data availability

Underlying data

All data underlying the results are presented within the manuscript, and no additional source data are required.

References

- Helms J, Jin H, Wang M: **High risk of thrombosis in patients with severe SARS-CoV-2 infection: a multicenter prospective cohort study.** *Intensive Care Med.* 2020; **46**: 1089–96. [PubMed Abstract](#) | [Publisher Full Text](#) | [Publisher Full Text](#)
- Fabiana T, Angela S, Jacopo M, et al.: **COVID-19 and Thrombocytopenia: Heparin or Sepsis-Induced?** *J Geriatr Med Gerontol.* 2020; **6**: 6–8. [Publisher Full Text](#)
- Liltjos J-F, Leclerc M, Chochols C, et al.: **High incidence of venous thromboembolic event in anticoagulated severe COVID-19 patients.** *J Thromb Haemost.* 2020. [PubMed Abstract](#) | [Publisher Full Text](#) | [Publisher Full Text](#)
- Riker RR, May TL, Fraser GL, et al.: **Heparin-induced thrombocytopenia with thrombosis in COVID-19 adult respiratory distress syndrome.** *Res Pract Thromb Haemost.* 2020; **4**: 936–41. [PubMed Abstract](#) | [Publisher Full Text](#) | [Publisher Full Text](#)
- Liu X, Zhang X, Xiao Y, et al.: **Heparin-induced thrombocytopenia is associated with a high risk of mortality in critical COVID-19 patients receiving heparin-involved treatment.** *medRxiv.* 2020. [Publisher Full Text](#)
- Aly R, Gupta S, Gupta S, et al.: **Case Report: Heparin-induced thrombocytopenia in a patient with COVID-19.** *F1000Res.* 2020; **9**: 704. [Publisher Full Text](#)
- Cuker A, Arepally G, Crowther MA, et al.: **The HIT Expert Probability (HEP) Score: A novel pre-test probability model for heparin-induced Thrombocytopenia based on broad expert opinion.** *J Thromb Haemost.* 2010; **8**: 2642–50. [PubMed Abstract](#) | [Publisher Full Text](#)
- Daviet F, Guervilly C, Baldesi O, et al.: **Heparin-induced thrombocytopenia in severe COVID-19.** *Circulation.* 2020; **142**: 1875–7. [PubMed Abstract](#) | [Publisher Full Text](#) | [Publisher Full Text](#)
- Chan M, Malynn E, Shaz B, et al.: **Utility of consecutive repeat HIT ELISA testing for heparin-induced Thrombocytopenia.** *Am J Hematol.* 2008; **83**: 212–7. [PubMed Abstract](#) | [Publisher Full Text](#)
- Franchini M: **Heparin-induced thrombocytopenia: An update.** *Thromb J.* 2005; **3**: 1–5. [PubMed Abstract](#) | [Publisher Full Text](#)
- Lingamaneni P, Gonakoti S, Moturi K, et al.: **Heparin-Induced Thrombocytopenia in COVID-19.** *J Investig Med High Impact Case Reports.* 2020; **8**: 4–7. [PubMed Abstract](#) | [Publisher Full Text](#) | [Publisher Full Text](#)

Open Peer Review

Current Peer Review Status:  

Version 1

Reviewer Report 09 August 2021

<https://doi.org/10.5256/f1000research.55699.r90612>

© 2021 Hartopo A. This is an open access peer review report distributed under the terms of the [Creative Commons Attribution License](#), which permits unrestricted use, distribution, and reproduction in any medium, provided the original work is properly cited.



Anggoro Budi Hartopo

Department of Cardiology and Vascular Medicine, Faculty of Medicine, Public Health and Nursing, Dr. Sardjito Hospital, Universitas Gadjah Mada, Jogjakarta, Indonesia

The authors report a case of COVID-19 pneumonia with HIT complication and finally can survive the disease. The emphasis of recognition of HIT, by two scoring system assessment, and proper discontinuation of heparin (UFH?) benefit the patient survival.

However several concerns were addressed regarding the case presentation, as follows:

1. "Tocilizumab 400 mg was also given on the second day before admission", is it true that **before hospital admission** the tocilizumab already be given?
2. What kind heparin is used in this case? Continuous infusion of unfractionated heparin or subcutaneous LMWH? Please describe clearly the heparin type.
3. "Since heparin antibody was not routinely checked in the developed country," what developed country this refers to?
4. The use of 4Ts and HEP scoring must be reported in the Case presentation which recite the patient situation and management given, not in the Discussion session. In the Case presentation, there is no statement/narration about the use of these scores during patient management.
5. Author switch to rivaroxaban as alternative anticoagulant in HIT replacing heparin, please give comment and reference/guideline which support this management.

Is the background of the case's history and progression described in sufficient detail?

Partly

Are enough details provided of any physical examination and diagnostic tests, treatment given and outcomes?

Yes

Is sufficient discussion included of the importance of the findings and their relevance to future understanding of disease processes, diagnosis or treatment?

Yes

Is the case presented with sufficient detail to be useful for other practitioners?

Partly

Competing Interests: No competing interests were disclosed.

Reviewer Expertise: Cardiovascular medicine

I confirm that I have read this submission and believe that I have an appropriate level of expertise to confirm that it is of an acceptable scientific standard.

Author Response 10 Aug 2021

Louisa Fadjri Kusuma Wardhani, Airlangga University, Surabaya, Indonesia

The authors report a case of COVID-19 pneumonia with HIT complication and finally can survive the disease. The emphasis of recognition of HIT, by two scoring system assessment, and proper discontinuation of heparin (UFH?) benefit the patient survival.

However several concerns were addressed regarding the case presentation, as follows:

- "Tocilizumab 400 mg was also given on the second day before admission", is it true that **before hospital admission** the tocilizumab already be given?
 - Thank you for your correction. Tocilizumab was given in the second day admission. The following correction has been submitted in the case presentation section.
- What kind heparin is used in this case? Continuous infusion of unfractionated heparin or subcutaneous LMWH? Please describe clearly the heparin type.
 - Thank you for your correction. We used unfractionated heparin (UFH) pump at first. We have been decribed it in the revision format.
- "Since heparin antibody was not routinely checked in the developed country," what developed country this refers to?
 - The correct statement is "Since heparin antibody was not routinely checked in the developing country" since its not applicable in our country (Indonesia).
- The use of 4Ts and HEP scoring must be reported in the Case presentation which recite the patient situation and management given, not in the Discussion session. In the Case presentation, there is no statement/narration about the use of these scores during patient management.
 - Thank you for your kind suggestion. We have added the use of both scoring system in our case presentation section.
- Author switch to rivaroxaban as alternative anticoagulant in HIT replacing heparin, please give comment and reference/guideline which support this management.
 - The drug of choices for whom suspected for HIT is argatroban and danaparoid. There is several recommendations regarding secondary prevention of HIT

using rivaroxaban and fondaparinux (A Cuker, 2010; Lori Ann Linkins, BMJ 2015). Since the availability of some drug is limited and patient with ongoing hematuria, We prefer rivaroxaban as an exchange. Moreover, the use of rivaroxaban twice daily has non-inferior efficacy than those with fondaparinux (ESC Guidelines for Pulmonary Embolism).

Competing Interests: none disclose

Reviewer Report 30 June 2021

<https://doi.org/10.5256/f1000research.55699.r87581>

© 2021 Fong A. This is an open access peer review report distributed under the terms of the [Creative Commons Attribution License](#), which permits unrestricted use, distribution, and reproduction in any medium, provided the original work is properly cited.



Alan Fong

Department of Cardiology, Sarawak Heart Centre, Kota Samarahan, Malaysia

This case report illustrates a clinical scenario that has to be identified early. Early risk stratification of the unwell patient and institution of an aggressive management plan will improved outcomes. This has been discussed in this draft, which is commendable. Therefore, this case report is relevant during this COVID pandemic.

However, language editing is recommended, for better presentation of this manuscript in your journal.

Therefore, minor revision, and then suitable for indexing.

Is the background of the case's history and progression described in sufficient detail?

Yes

Are enough details provided of any physical examination and diagnostic tests, treatment given and outcomes?

Yes

Is sufficient discussion included of the importance of the findings and their relevance to future understanding of disease processes, diagnosis or treatment?

Yes

Is the case presented with sufficient detail to be useful for other practitioners?

Yes

Competing Interests: No competing interests were disclosed.

Reviewer Expertise: Cardiovascular diagnostics

I confirm that I have read this submission and believe that I have an appropriate level of expertise to confirm that it is of an acceptable scientific standard.

Author Response 10 Aug 2021

Louisa Fadjri Kusuma Wardhani, Airlangga University, Surabaya, Indonesia

This case report illustrates a clinical scenario that has to be identified early. Early risk stratification of the unwell patient and institution of an aggressive management plan will improved outcomes. This has been discussed in this draft, which is commendable. Therefore, this case report is relevant during this COVID pandemic. However, language editing is recommended, for better presentation of this manuscript in your journal. Therefore, minor revision, and then suitable for indexing.

Thank you for your kind suggestion and comment. We have reviewed our manuscript and restructured with a better language editing

Competing Interests: None disclose

The benefits of publishing with F1000Research:

- Your article is published within days, with no editorial bias
- You can publish traditional articles, null/negative results, case reports, data notes and more
- The peer review process is transparent and collaborative
- Your article is indexed in PubMed after passing peer review
- Dedicated customer support at every stage

For pre-submission enquiries, contact research@f1000.com

F1000Research