

Protective Effect of Minocycline on *Bax* and *Bcl-2* Gene Expression, Histological Damages and Oxidative Stress Induced by Ovarian Torsion in Adult Rats

Mohammad Khaje Roshanaee, M.D.¹, Seyed-Hosein Abtahi-Eivary, Ph.D.², Majid Shokoohi, Ph.D.³, Masoumeh Fani, M.Sc.⁴, Azamsadat Mahmoudian, M.D.⁵, Maryam Moghimian, Ph.D.^{6*}

1. Student Research Committee, Gonabad University of Medical Sciences, Gonabad, Iran

2. Department of Biochemistry, School of Medicine, Gonabad University of Medical Sciences, Gonabad, Iran

3. Clinical Research Development, Unit of Tabriz Valiasr Hospital, Tabriz University of Medical Sciences, Tabriz, Iran

4. Department of Anatomy, School of Medicine, Gonabad University of Medical Sciences, Gonabad, Iran

5. Department of Obstetrics and Gynecology, School of Medicine, Allameh Bohlool Gonabadi Hospital, Gonabad University of Medical Sciences, Gonabad, Iran

6. Department of Physiology, School of Medicine, Gonabad University of Medical Sciences, Gonabad, Iran

Abstract

Background: Minocycline is a widely used bacteriostatic antibiotic with various functions. The aim of this study was to investigate impact of apoptotic genes in ovary of the torsion/detorsion treated rat model by minocycline.

Materials and Methods: This experimental study was performed in 32 female Wistar rats classified in four groups, including: i. sham, ii. TD: torsion/detorsion group received normal saline, iii. TDM: torsion/detorsion group treated with 40 mg/kg Minocycline, and iv. MC: healthy group received 40 mg/kg Minocycline. After treatment period (7 days), histological parameters, oxidative stress markers and hormone profile of serum as well as the expression of *Bax* and *Bcl-2* genes were measured in the ovary of rats.

Results: Levels of superoxide dismutase (SOD), glutathione peroxidase (GPX) and estrogen were decreased in the TD group and significantly increased in the treated groups ($P=0.001$). Levels of malondialdehyde (MDA) and testosterone were increased in the TD group and decreased in the treated groups ($P=0.001$). Expression level of *Bax* was elevated in the TD group, while it was attenuated in the treated groups ($P=0.001$). Expression level of *Bcl-2* was significantly increased in treated groups ($P=0.001$).

Conclusion: Minocycline can repair oxidative damage in ovarian tissue and regulate apoptotic-related gene expressions.

Keywords: Ganirelix Acetate, Gonadotrophin-Releasing Hormone Antagonist, *In Vitro* Fertilization, Letrozole, Ovarian Hyperstimulation Syndrome

Citation: Khaje Roshanaee M, Abtahi-Eivary SH, Shokoohi M, Fani M, Mahmoudian A, Moghimian M. Protective effect of minocycline on *Bax* and *Bcl-2* gene expression, histological damages and oxidative stress induced by ovarian torsion in adult rats. *Int J Fertil Steril.* 2021; 16(1): 30-35. doi: 10.22074/IJFS.2021.522550.1069. This open-access article has been published under the terms of the Creative Commons Attribution Non-Commercial 3.0 (CC BY-NC 3.0).

Introduction

Torsion or twisting of ovary around its ligament include 3% of gynecological emergency. Ischemia, caused by torsion, is occurred via blockage of blood flow. After this, tissue oxygen is reduced (1, 2). This condition also results in some ovarian tissue damages, such as necrosis and gangrene and follicles degenerations as well as destruction in improving of follicles (3, 4). All of this disorders may result in female infertility. After the first recognition of torsion, reinstatement of blood flow (detorsion) was done to prevent tissue necrosis (5, 6).

It was reported that detorsion led to overproduction of reactive oxygen species (ROS) and free radicals in ovarian tissue (7, 8). The imbalance condition between ROS

production and antioxidant defense system is named oxidative stress. Massive production of ROS through oxidative stress could individually damage mitochondrial membrane and lead to release of cytochrome c. *Bcl-2* family proteins are classified in two groups: anti-apoptotic (including *Bcl-2* and *Bcl-x*) and pro-apoptotic (consisting of *bax* and *bad*). They regulate releasing of cytochrome c from inner membrane of mitochondria. In details, anti-apoptotic proteins prevent releasing of cytochrome c, in the following incidence of apoptosis. In contrast with anti-apoptotic proteins, pro-apoptotic proteins act as inducer of apoptosis via stimulation of pro-caspase 9. After this, pro-caspase 9 turns into the activated caspase 9, subsequently activating caspase 3. This ultimately leads to DNA damage and apoptosis. The weakness of antioxidant defense

Received: 5/January/2021, Accepted: 24/August/2021

*Corresponding Address: P.O.Box: 397, Department of Physiology, School of Medicine, Gonabad University of Medical Sciences, Gonabad, Iran
Email: moghimian2@yahoo.com



Royan Institute
International Journal of Fertility and Sterility
Vol 16, No 1, January-March 2022, Pages: 30-35

system could be improved by antioxidant components and prevent the potential subsequent damages (8-10).

Nowadays, exogenous antioxidant compounds are more than ever utilized to treat different diseases associated with oxidative stress-induced tissue damages. Minocycline, as a tetracycline derivative, is a widely used bacteriostatic antibiotic with various functions, including suppression of pro-inflammatory cytokines, inhibition of apoptosis pathways and antioxidant activity (11). In this regard, Naderi et al. (12) indicated that minocycline has protective effect against brain ischemia, due to its antioxidant properties. In addition, other investigations demonstrated that antioxidant properties of minocycline can protect diabetic rats from nephropathy (11, 13).

Since oxidative stress and apoptosis are considered as responsible of Torsion/Detorsion pathogenesis, the current experimental study was designed to assess the impact(s) of administration of minocycline (as potentially an anti-apoptotic and antioxidant agent) on Torsion/Detorsion-induced damages in ovary and oxidative stress in adult female rats.

Materials and Methods

Present research work was accepted by "Ethical Committee of Gonabad University of Medical Sciences, Gonabad, Iran" (IR.GMU.REC.1398.117). Thirty two adult female Wistar rat with average weight of 200-250 g and average old of eight weeks were utilized in the experimental study (14). The sample size was decided based on our pervious study. All animals were randomly selected from the animal house of "Gonabad University of Medical Sciences" and they kept in the standard condition of animal house. During this experiment, food and water were free for all animals.

All of the rats were randomly classified into four groups.

Group 1: Sham group or control group; in the lower median part of the abdomen, a 2.5 cm longitudinal cutting was created, then sutured with 6/0 nylon (n=8).

Group 2: firstly ovarian torsion was performed and after 3 hours, detorsion was carried out. Thirty minutes before detorsion, subjects were treated with normal saline (TD; n=8).

Group 3: ovarian torsion was initially performed and after 3 hours, detorsion was carried out. All rats were treated with 40 mg/kg minocycline by intraperitoneal injection 30 minutes before detorsion (TDO30; n=8) (15).

Group 4: or minocycline group with no TD operation, only received 40 mg/kg minocycline by intraperitoneal injection (n=8).

Surgical method of ovarian torsion induction

According to the previous studies, induction of ovarian torsion was performed (5, 7). Initially, anesthesia for all rats was done with ketamine/xylazine (10 mg/kg xylazine and 50 mg/kg ketamine intraperitoneally) (7).

Next, hairs of the abdominal region were shaved, in the midline of abdomen a 2/5 cm cutting was created. Afterward, uterine tube and ovary were exposed and ovary with adnexa was rotated 720 degree around its ligament. Then, to stabilize this situation, the rotated ovary was fixed to abdominal wall with 6/0 nylon suture. This condition was maintained for 3 hours. Half an hour before detorsion, the first dose of minocycline was injected. Then detorsion was accomplished and reperfusion was performed for 7 days. During this period, treated groups were induced to different doses of minocycline. After receiving the last dose of drug, all treated groups were anesthetized and ovarian tissues were extracted for histopathological assessment as well as evaluation of oxidative stress and gene expression (7).

Histopathological examination of ovarian tissue

After removing the ovarian tissue, samples were placed in 10% formalin for 72 hours, followed by dehydration. Paraffin-embedded tissues were sectioned by a microtome at a thickness of 5 μ m. At the end of this process, samples were stained with Hematoxylin and Eosin method and examined for histopathological assessment.

For this aim, tissue slides were prepared and samples were appraised with a light microscope spirally from the cortex to the medulla. In the whole field of slides, number of "pre-antral," "antral Graafian follicles," and "atretic bodies" were counted and compared among the experimental groups. In addition, tendency of hemorrhage, tissue bleeding and disruption were assessed (5).

Evaluation of biochemical parameters

For measurement of malondialdehyde (MDA) level, 0.2 ml plasma was added to a tube containing mixture of 3 ml glacial acetic acid, 3 ml thiobarbituric acid and 2% NaOH. The resulting mixture was placed in a shaker and kept in boiling water for 15 minutes to create the pink-colored solution. After cooling down the samples, absorbance was read at a wavelength of 532 nm (16).

Activity of superoxide dismutase and glutathione peroxidase

Plasma levels of superoxide dismutase (SOD) and glutathione peroxidase (GPX) were determined by the commercial kits according to the manufacturers' instructions (Randox and Ransod, UK) using ELISA method.

Method of SOD assay based on Ransod kit: This method employs xanthine and xanthine oxidase (XOD) to generate superoxide radicals, reacting with 2-(4-iodophenyl)-3-(4-nitrophenol)-5-phenyltetrazolium chloride (I.N.T.) to form a red formazan dye. SOD activity is then measured by the degree of inhibition of this reaction.

Method of GPX assay based on Randox kit: GPX catalyzes oxidation of glutathione (GSH) by Cumene of hy-

dro peroxide. In the presence of glutathione reductase and NADPH, the oxidized glutathione (GSSG) is immediately converted to the reduced form with a concomitant oxidation of NADPH to NADP.

cDNA synthesis and quantitative reverse transcription polymerase chain reaction

The left ovaries were utilized for assessment of *Bax* and *Bcl-2* gene expressions. Total RNA was isolated using TRIzol Reagent (Invitrogen, UK) and concentration was measured by spectrophotometer. Afterwards, they were carefully set to a concentration of 0.5 µg/ml. Finally, cDNA was reverse-transcribed in a final volume of 20 µl from 5 µg total extracted RNA using the commercial kit (Thermo Scientific, USA). Sequences of the utilized primer to analyze gene expressions are as following:

Bcl-2-

F: 5'-CTTTGCAGAGATGTCCAGTCAG-3'
R: 5'-GAACTCAAAGAAGGCCACAATC-3'

Bax-

F: 5'-GGCGAATTGGAGATGAACTG-3'
R: 5'-TTCTTCCAGATGGTGAGCGA-3'

Gapdh-

F: 5'-GCAGCTCCTTCGTTGCCGGT-3'
R: 5'-CCCGCCATGGTGTCCGTTTC-3'

Gapdh gene was used as the internal control. The quantitative reverse transcription polymerase chain reaction (qRT-PCR) reactions were conducted in a 48-well plate with a volumes of 20 µl containing 1 µl cDNA, 2 µl of the mixed forward and reverse primers, 7 µl deionized water and 10 µl SYBR Green PCR master mix. Two-step qRT-PCR was conducted in the Applied Biosystems 7500 Fast Real-Time PCR System (Applied Biosystems Germany GmbH). PCR cycling condition are described as following: one cycle at 95°C for 10 minutes, followed by 40 cycles at 95°C for 15 seconds, 58°C for 30 seconds and 72°C for 30 seconds, and one cycle of final extension step (melt curve step) at 95°C for 15 seconds, 60°C for 60 seconds and 95°C for 15 seconds. Finally, quantitative analysis was calculated by the Pfaffl method, shown as ratios ($2^{-\Delta CT}$ target: $2^{-\Delta CT}$ reference) (7, 9).

Evaluation of apoptosis in ovarian tissue by TUNEL method

Apoptosis rate in ovary tissue follicles was measured by terminal deoxynucleotidyl transferase-mediated nick end labeling (TUNEL) assay using the In Situ Cell Death Detection Kit (Boehringer Mannheim, Germany). All process was implemented in accordance with the protocols provided by the commercial kit as follows: i. Sections of the ovary were deparaffinized and then hydrated in descending gradient of ethanol. ii. Section samples were incubated in humid room temperature with 20 mg/ml proteinase K for 20 minutes. iii. Endogenous peroxidase activity was blocked by in-

ubation with 3% hydrogen peroxide in methanol for 10 minutes. iv. Sections of the ovary were incubated with the TUNEL solution including deoxy-nucleotide mixture and terminal deoxynucleotidyl transferase enzyme at 4°C overnight. v. The tissue slid specimens were incubated with the anti-fluorescein antibody peroxidase solution at 25°C for 30 minutes. vi. The tissue sections were ultimately treated with diaminobenzidine for 15 minutes.

All of the indicated steps were conducted separately by rinsing the samples in phosphate buffered saline (PBS) after each stage. Next, tissue slides were stained with hematoxylin for 1 minute. Afterwards, tissue specimens were dehydrated, cleared and mounted with Entellan (Merck, Germany). Apoptotic cells appeared in dark brown and were homogeneous (7). For calculation of apoptosis index in the ovary tissue section, number of TUNEL-positive cells were counted, dividing into the total number of granulosa cells and expressed as the percentage. Next, the mean apoptotic index of each group was calculated and analyzed by the ImageJ software (version 1.44, NIH, Bethesda, MD, USA).

Plasma levels of testosterone and estrogen

Plasma levels of testosterone and estrogen were analyzed by the enzyme-linked immunosorbent assay (ELISA) kit (Demeditec Diagnostics, Germany). Optical density of the samples was determined at a wavelength of 405 nm.

Statistical analysis

For the statistical analysis, the SPSS software version 20 was used (IBM, USA). Data were examined by the Kolmogorov-Smirnov test for checking the normality distribution of the samples. All results were presented as means ± standard errors. To compare the histopathological parameters and oxidative stress values, one-way ANOVA was used, followed by Tukey's post hoc test. The statistical significance was set at $P < 0.05$.

Results

Histopathological changes

Number of pre-antral, antral and graafian follicles showed a marked reduction in the TD groups compared to the sham group. Number of the atretic bodies was notably higher in the TD group than the sham group ($P=0.001$). In the experimental groups treated with minocycline, the number of pre-antral, antral and graafian follicles was significantly higher than the TD group ($P=0.001$). Frequency of atretic bodies in therapeutic groups was remarkably lowered, in comparison with the TD group ($P=0.001$, Table 1, Fig.1). Hemorrhage, tissue bleeding, and disruption of ovarian tissue was observed in TD group Compared to the sham group. On the other hand, treatment with minocycline replaced this damages.

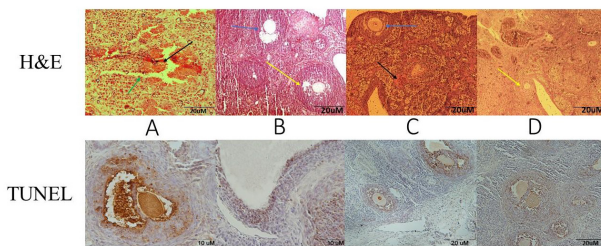


Fig.1: Histological findings and apoptosis in the study groups. **A.** TD ovarian torsion for 3 hours (T3h), **B.** Sham (cutting the abdominal wall without applying torsion), **C.** TD+Myno ovarian torsion for 3 hours (T3h), receiving minocycline, and **D.** MYNO Healthy group receiving minocycline. Black arrows show hemorrhage, Blue arrows show antral follicles, green arrow shows tissue disruption, yellow arrows show preantral follicles. In the histopathological examination of ovarian tissue in TD group, degeneration, hemorrhage and tissue disruption were observed. In the sham and healthy treated groups, normal follicular development, normal histological assessment and normal morphology of follicles were visualized. In tissue sections of the sham group, no hemorrhage and tissue degeneration was observed. In the treated group, all of the tissue damage and degeneration were replaced with administration of minocycline.

Table 1: Histopathological findings

Groups	Primary follicles ± SD	Pre-antral follicles ± SD	Antral follicles ± SD	Yellow body ± SD
Sham	18.4 ± 1.14	27.8 ± 1.92	16.2 ± 1.30	9.4 ± 1.83
TD	7.4 ± 1.14*	7.2 ± 1.30*	3.8 ± 1.14*	1.8 ± 0.89*
TD+MYNO	13.8 ± 1.30†	18 ± 1.58†	12 ± 1.58†	6.8 ± 0.83†
MYNO	18.2 ± 2.38†	25.8 ± 2.48†	14.6 ± 2.07†	7.5 ± 1.89†

*, Significant difference compared to the sham group, †; Significant difference compared to the TD group, TD; Ovarian torsion/detorsion, and MYNO; Minocycline.

Apoptotic markers

Effectiveness of minocycline on programmed cell death (apoptosis) in different groups under treatment, sham and TD group expressed as follow. As shown in Figure 1, count of TUNEL positive cells in the TD group compared to the sham group were significantly higher. Apoptosis index in pre-antral, antral and graafian follicles were enhanced, in comparison with the sham group. Evaluation of apoptosis index in ovarian tissue cells and follicles of the treated groups with various dosages of minocycline were not ably distinguished in comparison with the TD group (Figs.1, 2).

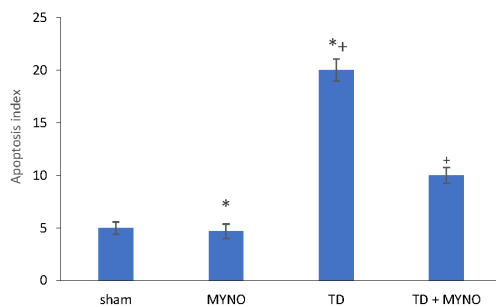


Fig.2: Apoptosis index in study groups. Data are presented as mean ± SD. *, Significant difference compared to the sham group, †; Significant difference compared to the TD group, TD; Ovarian torsion/detorsion, and MYNO; Minocycline.

Bax gene expression was increased in the TD group than the sham group as well as the expression of this gene was notably distinguished in treated groups with Minocycline (i.e TD+MYNO and MYNO, P<0.05). On the other hand, findings showed that *Bcl-2* gene

expression was remarkably reduced in the TD group than sham (P<0.05). In the treated groups, expression of *Bcl-2* was significantly enhanced in comparison with the TD group (P<0.05, Table 2).

Table 2: The oxidative stress markers in the study groups

Group	SOD (U/ml) ± SD	GPX (ng/ml) ± SD	MDA (nm/ml) ± SD
Sham	1.77 ± 0.04	22.04 ± 0.77	0.57 ± 0.03
TD	0.82 ± 0.12*	9.11 ± 0.63*	1.58 ± 0.07*
TD+MYNO	0.95 ± 0.24	16.42 ± 0.89	0.97 ± 0.05
MYNO	1.63 ± 0.24+	21.81 ± 0.31†	0.65 ± 0.01†

*, Significant difference compared to the sham group, †; Significant difference compared to the TD group, TD; Ovarian torsion/detorsion, MYNO; Minocycline, SOD; Superoxide dismutase, GPX; Glutathione peroxidase, MDA; Malondialdehyde, and SD; Standard deviation.

Serum antioxidant enzymes

A significant decrease was found in the serum level of SOD and GPx in the TD group as compared with the sham group (P=0.001). Additionally, comparison of therapeutic groups with TD group indicated higher levels of serum GPx in minocycline-treated groups (P<0.05) but the level of SOD was not significantly higher than TD group (P>0.05). Serum level of MDA was elevated in the TD group, compared to the sham group. In addition, treatment with minocycline reversed the increased concentration of MDA to the baseline values (P<0.05, Table 3).

Table 3: Comparison of *Bax* and *Bcl-2* gene expressions in the study groups

Group	<i>Bax</i> ± SD	<i>Bcl-2</i> ± SD
Sham	0.32 ± 0.022	1.38± 0.034†
TD	1.48± 0.032*	0.41± 0.038*
TD+MYNO	0.89± 0.04†	0.94± 0.014†
MYNO	0.35 ± 0.014†	1.43± 0.028†

*, Significant difference compared to the sham group, †; Significant difference compared to the TD group, TD; Ovarian torsion/detorsion, MYNO; Minocycline, and SD; Standard deviation.

Hormonal profile

In the TD groups, estrogen level was significantly lower than the sham group (P=0.001). Additionally, in the minocycline-treated groups, estrogen level was significantly enhanced compared to the TD group (P=0.001, Table 4).

Table 4: Estrogen and testosterone levels in serum

Groups	Testosterone (ng/ml)	Estrogen (pg/ml)
Sham	0.48 ± 0.050	52.25 ± 1.75
TD	2.94 ± 0.078*	33.50 ± 1.19*
TD+MYNO	1.59 ± 0.064+	44.75 ± 1.31+
MYNO	0.49 ± 0.030+	56.25 ± 0.85+

Data are presented as mean ± SD. *, Significant difference compared to the sham group, †; Significant difference compared to the TD group, TD; Ovarian torsion/detorsion, and MYNO; Minocycline.

The serum level of testosterone was significantly increased in the TD group in comparison with the sham group (P=0.001). A significant reduction was detected in the other experimental groups treated with minocycline when compared to the TD group (P=0.001, Table 4).

Discussion

Induction of torsion/detorsion causes histological damage in TD group. These damages are observed as disruption and hemorrhage in ovary tissue sections. Additionally, this was observed in follicles evaluation and follicles morphology, as a degenerative damage. In this context many studies have presented similar results (17, 18). Tissue degeneration maybe due to ovarian torsion followed by tissue hypoxia and ischemia caused by disturbance in circulation temporary cut off blood flow. This disorder carries out tissue to hypoxia, necrosis and gangrene. In turn, reperfusion, which is done for prevention of ischemia, leads to microvascular endothelial damage, rupture and hemorrhage. When the massive volume of blood suddenly entire ovary cause tissue disruption and hemorrhage in ovarian tissue (19). In line with our results, studies demonstrated that torsion/detorsion of ovary led to tissue damages consisting of follicles degeneration, tissue hemorrhage and tissue disruption. In addition, studies done by Shokoohi et al. (7) indicated that 3 hours ischemia of ovary tissue followed by 10 days reperfusion cause tissue damage in TD group.

Assessment of oxidative stress markers in the current study represented that activity of antioxidant enzymes (SOD and GPx) were declined in the TD group. In this group, Level of lipid peroxidation was markedly increased. This enhancement was observed in tissue MDA level as end product of lipid peroxidation. Lipid peroxidation due to torsion/detorsion of ovary occurred as free radicals such as hydroxyl, and peroxy activity. Increased free radical activity causes reduction in endogenous antioxidant enzymes activity, such as SOD and GPx. Thereby torsion/detorsion of ovary occasion imbalance between SOD and GPx activity, in addition to production of free radicals and ROS lead to increasing MDA production (3, 9). This increase shows the weakness in antioxidant defense system of body. In the result of this happen ovarian tissue cells and follicles become to DNA damage and followed by apoptosis (7, 19). In this context, Ashok Agarwal et al. showed that antioxidants can protect the ovarian tissue damage against oxidative stress by prevention of free radicals and ROS activation (20).

In addition, apoptosis in ovarian tissue cells can be controlled through intracellular apoptosis pathway, affected by pathways activation. Accumulation of intracellular ROS can release cytochrome c from internal membrane of mitochondria. This leads to forming a protein complex called apoptosome, which activates pro-caspase 9. It can also active caspase-3 and caspase-7 (effector caspase). This process causes apoptosis induction. Internal apoptotic pathway is directly controlled by two groups of protein, consisting of pro-apoptotic proteins, such as Bax, Bid, Bad and nitric oxide molecules (9, 21). These molecules and genes activate the cytochrome c releasing pathway from internal membrane of mitochondria. Another controlling protein of intracellular apoptotic pathway includes Bcl-2 and Bcl-XL which is known as anti-apoptotic group and preventive of cytochrome c releasing (9, 22). In this research, expression of *Bax* and *Bcl-2* was detected. Findings showed elevation of ROS level and weakness of antioxidant defense. In addition, expression levels of *Bax*

and *Caspase-3* were increased, while *Bcl-2* gene expression level was declined in the TD group. These complications represent induction of apoptosis in ovarian tissue.

In the present study, evaluation with TUNEL method displayed increase in the count of TUNEL positive cells, due to apoptosis in the TD group. This results could be the reason of confirming high expression of *Bax* gene in the TD group that shows activation of apoptosis pathway (7). Increase in the number of TUNEL positive cells in the TD group confirmed enhancement of apoptosis. This process can be the result of accumulation of ROS, activation of free radical and weakness of antioxidant defense system (23). In this context several studies showed that torsion/detorsion led to ovarian tissue damage and cell apoptosis. Many researches also presented that torsion/detorsion of ovary increased apoptotic related genes, such as *Bax* and *Caspase-3* in the TD group. Studies also showed decrease in *Bcl-2* gene expression in the TD group (7, 24).

On the other hand, ovarian torsion/detorsion impairs imbalance of serum hormonal levels. As a case, in the present research increased level of testosterone and reduced level of estrogen were observed in serum of rats. This may stem from degeneration of normal follicles and granulosa cells, leading to inability of testosterone (DHEA) to convert into estrogen. This would result in increased level of testosterone and decreased level of estrogen (25, 26).

Result of the current study indicated use of minocycline, as an antioxidant substance, preserving ovarian tissue against injuries of ROS accumulation and activity of free radicals. So that, few tissue damages and follicles degenerations were observed in the treated group with minocycline but it was not significant. Evaluation of oxidative stress marker levels also showed the important reduction in the level of lipid peroxidation in groups that treated with Minocycline (27). Activity of antioxidant enzymes were clearly elevated in this group, resulting in deactivation of ROS and reduction in injuries, due to oxidative stress by this antioxidant property. In this regard, several studies exhibited minocycline, as an antioxidant agent which can prevent lipid peroxidation, increase SOD and GPx levels (28, 29).

Administration of minocycline in the treated group of current study caused reduction of apoptotic index, gene and protein expressions related to apoptosis in ovarian tissue of rat. This led to reduction of testosterone and increase of estrogen levels in serum. In this regard, Barghi et al. (26) showed that ovarian torsion led to reduction of estrogen and increase of testosterone levels in serum. Additionally, treatment with antioxidant can increase level of estrogen and reduce testosterone levels in serum. Antioxidant properties of minocycline can diminish injuries, due to increasing ROS and consequently elevation of antioxidant defense system of body (30). Minocycline, by preventing accumulation of extracellular ROS, can hamper activation of caspase-8 and extracellular apoptotic pathway. This antioxidant combine also prevents releasing cytochrome c by inhibiting free radicals and intracellular ROS activation, thereby excluded activation of intracellular apoptotic pathway. Also with an

enhancement of the antioxidant defense system increase the expression of the anti-apoptotic proteins and genes such as Bcl-2. The elevation of these genes lead to the prevention of releasing of cytochrome c and activation of the apoptotic pathway. Evaluation of ovarian tissue by TUNEL assay showed reducing amount of TUNEL positive cells and apoptosis index in the treated group. In this context, many researches demonstrated that minocycline, as an antioxidant agent, decreased apoptotic related gene and proteins, while it elevated expression level of *Bcl-2*.

Conclusion

It seems that minocycline attenuates torsion/detorsion-induced ovarian damage, while it is considered as one of the causes of infertility in females. Our study exhibited that minocycline, as an antioxidant component, enhanced antioxidant enzyme activity while diminished expression of *Bax*, as well as the rate of programmed cell death in ovarian tissue of rats with ovarian torsion.

Acknowledgements

Authors want to thank Gonabad University of Medical Sciences (Gonabad, Iran) for financial support of this study. The authors declare no conflict of interest.

Authors' Contributions

M.Kh.R., S.-H.A.-E., M.M.; Planned and designed the experiments. M.Sh.; Performed the experiments. M.F., A.M.; Analyzed the data. M.Sh., M.M.; Wrote the manuscript. M.Kh.R., S.-H.A.-E., M.Sh., M.F., A.M., M.M.; Reviewed and discussed the data. All authors read and approved the final manuscript.

References

- Laganà AS, Sofo V, Salmeri FM, Palmara VI, Triolo O, Terzić MM, et al. Oxidative stress during ovarian torsion in pediatric and adolescent patients: changing the perspective of the disease. *Int J Fertil Steril*. 2016; 9(4): 416-423.
- Stambough KC, Childress KJ. Ovarian torsion in adolescents. In: Nezhath CH, editor. *Endometriosis in adolescents*. Springer; 2020; 499-509.
- Ersoy GS, Eken M, Tal R, Oztekin D, Devranoglu B, Kaygusuz EI, et al. N-acetylcysteine leads to greater ovarian protection than enoxaparin sodium in a rat ovarian torsion model. *Reprod Biomed Online*. 2016; 33(1): 93-101.
- Otjen JP, Stanescu AL, Alessio AM, Parisi MT. Ovarian torsion: developing a machine-learned algorithm for diagnosis. *Pediatr Radiol*. 2020; 50(5): 706-714.
- Soltani M, Moghimian M, Abtahi H, Shokoohi M. The protective effect of *Matricaria chamomilla* extract on histological damage and oxidative stress induced by Torsion/Detorsion in adult rat ovary. *Int J Women's Health Reprod Sci*. 2017; 5(3): 187-192.
- Ugurel V, Cicek AC, Cemek M, Demirtas S, Kocaman AT, Karaca T. Antioxidant and antiapoptotic effects of erdosteine in a rat model of ovarian ischemia-reperfusion injury. *Iran J Basic Med Sci*. 2017; 20(1): 53-58.
- Shokoohi M, Soltani M, Abtahi-Eivary SH, Niazi V, Rafeei Poor MJ, Ravaei H, et al. Effect of hydro-alcoholic extract of *olea europaea* on apoptosis-related genes and oxidative stress in a rat model of torsion/detorsion-induced ovarian damage. *Asian Pac J Reprod*. 2019; 8(4): 148-156.
- Agarwal A, Aponte-Mellado A, Premkumar BJ, Shaman A, Gupta S. The effects of oxidative stress on female reproduction: a review. *Reprod Biol Endocrinol*. 2012; 10: 49.
- Shokoohi M, Khaki A, Shoorei H, Khaki AA, Moghimian M, Abtahi-Eivary SH. Hesperidin attenuated apoptotic-related genes in testicle of a male rat model of varicocele. *Andrology*. 2020; 8(1): 249-258.
- Spencer SJ, Cataldo NA, Jaffe RB. Apoptosis in the human female reproductive tract. *Obstet Gynecol Surv*. 1996; 51(5): 314-323.
- Naderi Y, Panahi Y, Barreto GE, Sahebkar A. Neuroprotective effects of minocycline on focal cerebral ischemia injury: a systematic review. *Neural Regen Res*. 2020; 15(5): 773-782.
- Naderi Y, Sabetkasaei M, Parvardeh S, Zanjani TM. Neuroprotective effect of minocycline on cognitive impairments induced by transient cerebral ischemia/reperfusion through its anti-inflammatory and antioxidant properties in male rat. *Brain Res Bull*. 2017; 131: 207-213.
- Shahzad K, Bock F, Al-Dabet MM, Gadi I, Nazir S, Wang H, et al. Stabilization of endogenous Nrf2 by minocycline protects against Nlrp3-inflammasome induced diabetic nephropathy. *Sci Rep*. 2016; 6: 34228.
- Sengupta P. The laboratory rat: relating its age with human's. *Int J Prev Med*. 2013; 4(6): 624-630.
- Naderi Y, Sabetkasaei M, Parvardeh S, Moini Zanjani T. Neuroprotective effects of pretreatment with minocycline on memory impairment following cerebral ischemia in rats. *Behav Pharmacol*. 2017; 28(2 and 3-Spec Issue): 214-222.
- Abtahi-Evari SH, Shokoohi M, Abbasi A, Rajabzade A, Shoorei H, Kalarestaghi H. Protective Effect of *galega officinalis* extract on streptozotocin-induced kidney damage and biochemical factor in diabetic rats. *Crescent J Medical Biol Sci*. 2017; 4(3): 108-114.
- Santos XM, Cass DL, Dietrich JE. Outcome following detorsion of torsed adnexa in children. *J Pediatr Adolesc Gynecol*. 2015; 28(3): 136-138.
- Bertozzi M, Esposito C, Vella C, Briganti V, Zampieri N, Codrich D, et al. Pediatric ovarian torsion and its recurrence: a multicenter study. *J Pediatr Adolesc Gynecol*. 2017; 30(3): 413-417.
- Calis P, Bozdogan G, Sokmensuer LK, Kender N. Does ischemia-reperfusion injury affect ovarian reserve and follicle viability in a rat model with adnexal torsion? *Eur J Obstet Gynecol Reprod Biol*. 2015; 185: 126-130.
- Agarwal A, Sengupta P, Durairajanayagam D. Role of L-carnitine in female infertility. *Reprod Biol Endocrinol*. 2018; 16(1): 5.
- Durairajanayagam D, Agarwal A, Ong C. Causes, effects and molecular mechanisms of testicular heat stress. *Reprod Biomed Online*. 2015; 30(1): 14-27.
- Agarwal A, Kasinathan A, Ganesan R, Balasubramanian A, Bhaskaran J, Suresh S, et al. Curcumin induces apoptosis and cell cycle arrest via the activation of reactive oxygen species-independent mitochondrial apoptotic pathway in Smad4 and p53 mutated colon adenocarcinoma HT29 cells. *Nutr Res*. 2018; 51: 67-81.
- Refaie MMM, El-Husseyen M. Protective effect of pioglitazone on ovarian ischemia reperfusion injury of female rats via modulation of peroxisome proliferator activated receptor gamma and heme-oxygenase 1. *Int Immunopharmacol*. 2018; 62: 7-14.
- Gokalp N, Basaklar AC, Sonmez K, Turkyilmaz Z, Karabulut R, Poyraz A, et al. Protective effect of hydrogen rich saline solution on experimental ovarian ischemia reperfusion model in rats. *J Pediatr Surg*. 2017; 52(3): 492-497.
- Ahmad B, Shrivastava VK, Saleh R, Henkel R, Agarwal A. Protective effects of saffron against zearalenone-induced alterations in reproductive hormones in female mice (*Mus musculus*). *Clin Exp Reprod Med*. 2018; 45(4): 163-169.
- Barghi B, Shokoohi M, Khaki AA, Khaki A, Moghimian M, Soltani M. Eugenol improves tissue damage and oxidative stress in adult female rats after ovarian torsion/detorsion. *J Obstet Gynaecol*. 2021: 1-6.
- Garabadu D, Shah A, Singh S, Krishnamurthy S. Protective effect of eugenol against restraint stress-induced gastrointestinal dysfunction: potential use in irritable bowel syndrome. *Pharm Biol*. 2014; 53(7): 968-974.
- Ahuja N, Singh HP, Batish DR, Kohli RK. Eugenol-inhibited root growth in *Avena fatua* involves ROS-mediated oxidative damage. *Pestic Biochem Phys*. 2015; 118: 64-70.
- Bezerra DP, Militão GCG, de Moraes MC, de Sousa DP. The dual antioxidant/prooxidant effect of eugenol and its action in cancer development and treatment. *Nutrients*. 2017; 9(12): 1367.
- Huang X, Liu Y, Lu Y, Ma C. Anti-inflammatory effects of eugenol on lipopolysaccharide-induced inflammatory reaction in acute lung injury via regulating inflammation and redox status. *Int Immunopharmacol*. 2015; 26(1): 265-271.