

Pentalogy of Cantrell: Is Echocardiography Sufficient in the Neonatal Period?

Elke Zani-Ruttenstock¹ Augusto Zani¹ Osami Honjo² Priscilla Chiu¹

¹Division of General and Thoracic Surgery, The Hospital for Sick Children, Toronto, Ontario, Canada

²Division of Cardiovascular Surgery, Labatt Family Heart Centre, The Hospital for Sick Children, Toronto, Ontario, Canada

Address for correspondence Priscilla Chiu, MD, PhD, FRCSC, FACS, FAAP, Division of General and Thoracic Surgery, The Hospital for Sick Children, 555 University Avenue, Toronto, ON M5G 1X8, Canada (e-mail: priscilla.chiu@sickkids.ca).

Eur J Pediatr Surg Rep 2017;5:e9–e11.

Abstract

Pentalogy of Cantrell is a rare syndrome that is characterized by varying degrees of midline wall defects and congenital cardiac anomalies. A left ventricular diverticulum (LVD) is defined as partial ectopia cordis, can be part of the pentalogy of Cantrell, and can put the patient at risk of severe complications. Early diagnosis and ligation/resection of the LVD is important to prevent complications. We report on a case of pentalogy of Cantrell, in which a LVD was diagnosed only at 2 months of age despite preceding pre- and postnatal echocardiography. We conclude that in the suspicion of pentalogy of Cantrell, either complete or incomplete, cardiac magnetic resonance imaging should be performed, when possible, to avoid the potential complication of a herniating ventricular diverticulum.

Keywords

- ▶ omphalocele
- ▶ pentalogy of Cantrell
- ▶ ectopia cordis
- ▶ cardiac MRI

New Insights and the Importance for the Pediatric Surgeon

Neonates with omphalocele presenting with sternal defect and/or associated cardiac anomalies should be suspected to have a pentalogy of Cantrell, until proven otherwise. In these patients, cardiac magnetic resonance imaging should be performed, when possible, to avoid impending complications due to misdiagnosis or underestimation of congenital heart defects.

Introduction

With an estimated incidence of less than 1 in 100,000 live births, pentalogy of Cantrell is an extremely rare syndrome associating varying degrees of midline wall defects and congenital cardiac anomalies.^{1,2} First described by Cantrell in 1958, the pentalogy is characterized by a combination of midline supraumbilical abdominal wall defect, lower sternum anomaly, a deficiency of the anterior diaphragm, congenital intracardiac anomalies, and a defect in the pericardium.¹

We report on a case of pentalogy of Cantrell with a small omphalocele and a late diagnosis of an intra-abdominally extending left ventricular diverticulum (LVD) despite preceding cardiac imaging.

Case


We report on a female term infant born with an antenatal diagnosis of intrauterine growth retardation, omphalocele with liver and bowel contents, and congenital heart defect. Fetal echocardiogram at 34 weeks of gestation demonstrated a large ventricular septal defect (VSD) and total anomalous pulmonary venous drainage with connection to the left atrium. The patient was born through spontaneous vaginal delivery at a gestational age of 38 + 5 weeks with a birth weight of 2,600 g. Postnatal echocardiogram on day 1 of life revealed dextrocardia and three pulmonary veins draining into a retrocardiac confluence with connection to the left atrium. Additionally, a moderate secundum atrial septal defect (ASD), as well as multiple VSDs, a small persistent

received
November 7, 2016
accepted after revision
January 24, 2017

DOI <http://dx.doi.org/10.1055/s-0037-1599794>.
ISSN 2194-7619.

© 2017 Georg Thieme Verlag KG
Stuttgart • New York

License terms



ductus arteriosus (PDA), and an anomalous origin of the right subclavian artery were seen. No LVD was identified at this point. Electrocardiography (ECG) was unremarkable.

On day 2 of life, the patient underwent omphalocele primary closure (3.5-cm defect, with a hernia containing small bowel and no liver). In contrary to prenatal ultrasounds, only bowel content was found within an intact sack intraoperatively. The postoperative course was uncomplicated with steady progression to full feeds.

At clinic follow-up at 2 months of age, the child presented with growth retardation and poor feeding, and an obvious pulsatile mass above the patient's omphalocele repair site was noticed. Abdominal ultrasound and cardiac magnetic resonance imaging (MRI) showed a diverticulum of the left ventricle (LVD) herniating into the into the epigastric area between liver and anterior abdominal wall causing abdominal muscle deficiency (→Fig. 1). A repeat echocardiogram showed mesocardia, a large perimembranous VSD, a small midmuscular VSD, a big secundum ASD, a small PDA, and a significant, aberrant right ventricular muscle bundle with flow acceleration in the right ventricular outflow tract.

At 4 months of age, the patient underwent elective cardiac surgery on cardiopulmonary bypass. Intraoperatively, an enlarged heart and an abnormal short sternum were found. At surgery, the pulmonary veins were connected to the left atrium but had a nonobstructing membrane at the insertion point. The LVD had herniated inferiorly, with gradually decreasing size all the way down to the umbilicus (→Fig. 2).

The patient underwent resection of the ridge between the pulmonary vein and the left atrium, patch closure of ASD and perimembranous and midmuscular VSD, ligation of PDA, and resection of the hypertrophic right ventricular muscle bundle. The LVD was disconnected from an intra-abdominal ligament. The small (5-mm) anterior diaphragmatic defect was repaired without the need for a patch. Intraoperative transesophageal echocardiography showed good biventricular function and the LVD without cavity or flow. The LVD

was not visualized at a repeated echocardiogram done on postoperative day 11. At 1-year follow-up, the patient has been asymptomatic, thriving, and meeting her developmental milestones.

Written informed consent was obtained from the patient's legal guardian for publication of this case report and its accompanying images.

Discussion

The case herein presented shows that the diagnosis of pentalogy of Cantrell can be difficult, especially when anomalies are missed during routine imaging studies. Our patient had a congenital ventricular diverticulum missed at echocardiography during the perinatal age and diagnosed only later in life. This is a rare cardiac malformation characterized by a fingerlike appendix of the ventricular wall, beyond the myocardial margin, often localized in the left ventricle.³ Of all pentalogy of Cantrell malformations, ectopia cordis, defined as extrathoracic location of the heart, is the most severe. However, it can also present only partially, in form of LVD.⁴ Patients with LVD are prone to complications in 20 to 35% of cases.⁴ While a conservative approach could be justified in patients with isolated LVD,³ in patients with pentalogy of Cantrell, surgical resection or ligation of LVD is usually advocated due to the higher risk of spontaneous or traumatic rupture and sudden death due to tachyarrhythmia.^{4,5} Major complications of LVD include thrombosis, embolism, rupture, congestive heart failure, ventricular arrhythmias, and valvular abnormalities.⁵ A systematic review showed that fetuses with prenatally diagnosed LVD or left ventricular aneurysms have a high rate of prenatal complications and death.⁵ Moreover, patients with pentalogy of Cantrell and undiagnosed LVD are at risk of accidental damage to the diverticulum during surgical repair of associated anomalies such as diaphragmatic hernia or omphalocele. Therefore, early detection of LVD is particularly important in patients with pentalogy of Cantrell.

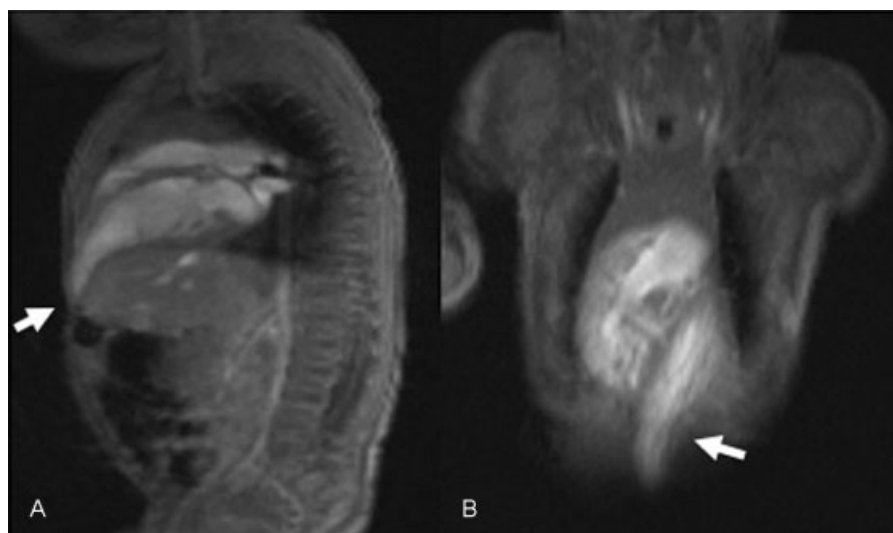


Fig. 1 Magnetic resonance imaging at 2 months of life: left ventricular diverticulum (arrows) extending from the chest into the abdomen (two views: sagittal, A; coronary, B).

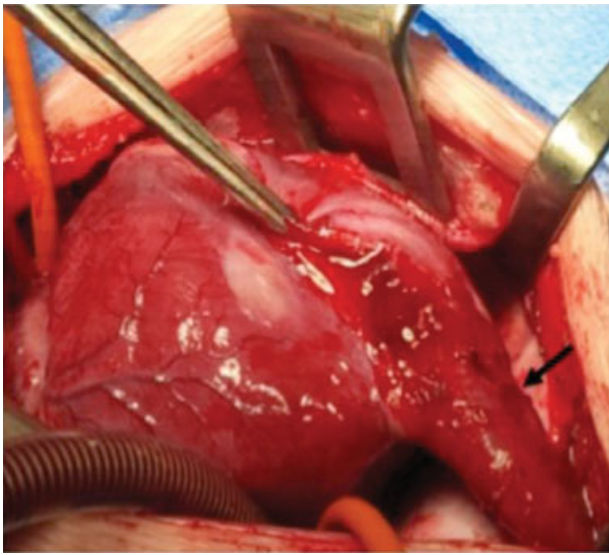


Fig. 2 Intraoperative picture: left ventricular diverticulum arising from the left ventricular apex (arrow) and extending into the epigastrium.

In our case, LVD was not diagnosed prenatally or preoperatively but was identified only later. Possibly, this was due to the fact that this LVD was a slim elongation of intact three-layer myocardium and had no large cavity or aneurysm. Similarly, the rationale of LVD ligation was to avoid potential complications of bleeding and leaving an unnecessary suture line.

Patients with pentalogy of Cantrell may present with visible or palpable mass on physical examination and/or those who have an associated LVD may have an ejection-type murmur on auscultation. Conversely, our patient had none of these findings present at birth, and the LVD was unrecognized until later. However, this is not exceptional given the several reports in the literature of incidentally detected LVD.³ ECG alterations should be the first clinical sign of LVD,³ but in our case, the ECG on day 1 of life was normal. Nevertheless, this is in keeping with the study from Ohlow et al, which reported an abnormal ECG in only 56% of patients with isolated LVD.³ Use of cross-sectional echocardiography and color Doppler imaging has been reported for the diagnosis of congenital LVD in fetuses, neonates, and infants.^{5,6} However, in our case, the LVD was identified on neither pre- nor postnatal echocardiography. LVD complete visualization was impossible due to the peculiar shape of the left ventricular apex, and the LVD became visible only at 2 months of age. MRI has also been used for diagnosis of LVD. On MRI, LVD appears as a structure with a thinned but contractile wall, associated with no signal alterations of the left ventricular wall and no signs of necrosis or fibrous tissue on delayed

enhancement images.^{3,7} In adults, cardiac MRI helps in differentiating LVD from left ventricle true aneurysms or pseudoaneurysms.³ Some authors have also reported the value of computed tomography (CT) angiography for the identification of LVD in patients with pentalogy of Cantrell.^{3,8} However, given the amount of radiation associated with CT scans, we would not consider this imaging modality in infants or children.

Missing the diagnosis of pentalogy of Cantrell could put the patient at serious risk, as in the case herein presented. However, it is difficult to establish when to suspect the pentalogy of Cantrell. Pediatric surgeons would be involved due to the presence of an omphalocele. Therefore, we believe that neonates with an omphalocele, especially when above the umbilicus, presenting with sternal defect and/or associated cardiac anomalies should be suspected to have a pentalogy of Cantrell. In this scenario, we advocate the use of cardiac MRI, if available. This approach would detect all potential cardiac malformations and avoid impending complications due to misdiagnosis or underestimation of congenital heart defects.

Conflict of Interest

None.

References

- 1 Cantrell JR, Haller JA, Ravitch MM. A syndrome of congenital defects involving the abdominal wall, sternum, diaphragm, pericardium, and heart. *Surg Gynecol Obstet* 1958;107(05):602–614
- 2 O’Gorman CS, Tortoriello TA, McMahon CJ. Outcome of children with Pentalogy of Cantrell following cardiac surgery. *Pediatr Cardiol* 2009;30(04):426–430
- 3 Romagnoli A, Ricci A, Morosetti D, Fusco A, Citraro D, Simonetti G. Congenital left ventricular diverticulum: Multimodality imaging evaluation and literature review. *J Saudi Heart Assoc* 2015; 27(01):61–67
- 4 Kaouthar H, Jihen A, Faten J, et al. Cardiac anomalies in Cantrell’s pentalogy: From ventricular diverticulum to complete thoracic ectopia cordis. *Cardiol Tunis* 2013;9(01):94–97
- 5 Ohlow MA, Brunelli M, Lauer B. Characteristics and outcome of primary congenital left ventricular aneurysm and diverticulum: analysis of cases from the literature. *Prenat Diagn* 2014;34(09): 893–899
- 6 Yang H, Zhu Q, Chen J, Guo N. Congenital left ventricular diverticulum diagnosed by echocardiography. *Pediatr Cardiol* 2012; 33(04):646–648
- 7 Tissot C, Pache JC, da Cruz E. Clinical vignette. A giant congenital left ventricular diverticulum simulating an aneurysm. *Eur Heart J* 2007;28(01):25
- 8 Singh N, Bera ML, Sachdev MS, Aggarwal N, Joshi R, Kohli V. Pentalogy of Cantrell with left ventricular diverticulum: a case report and review of literature. *Congenit Heart Dis* 2010;5(05): 454–457