

Primary paratesticular carcinoid in a 70-year-old male

Rumana Makhdoomi, Humaira Bashir, Malik Muanfat, Khalil Muhammad Baba

Department of Pathology SKIMS, Soura Srinagar Kashmir, India

KEY WORDS

paratesticular tumor ▶ carcinoid primary

ABSTRACT

Carcinoid tumors are neuroendocrine tumors and most frequently occur within tissues derived from the embryonic gut. These tumors can occur in any organ but are very rare in the paratesticular region. We hereby report a case of paratesticular carcinoid in a 70-year-old male who, to the best of our knowledge, is the oldest patient reported so far in the world literature.

INTRODUCTION

Carcinoid tumors represent an interesting family of tumors that are derived from neuroendocrine cells. These tumors were first described by Langhans but were not described in detail until Lubarsh described them in 1888 [1, 2]. Carcinoid tumors occur commonly in gastrointestinal tract and may be present in the extraintestinal sites i.e. lung, liver, respiratory tract, uterus, ovary, and breast or kidney [3]. Testis is an uncommon site of carcinoid tumors and a few cases of testicular carcinoid have been reported in peripubertal or postpubertal males [4, 5]. Paratesticular region is a complex anatomical area that includes the contents of the spermatic cord, testicular tunics, epididymis and vestigial remnants i.e. the appendices epididymis, and testis [6]. Neoplasms arising from this region therefore form a heterogeneous group of tumors with different behavioral patterns [6]. Carcinoid tumor of paratesticular region is an uncommon entity

and may be secondary to the carcinoid tumor of small intestine [7]. Primary carcinoid of the paratesticular region is very rare, we hereby report primary carcinoid of paratesticular region in a 70-year-old male who is the oldest patient reported so far with this entity.

CASE REPORT

A 70-year-old male reported to the Urology outpatient department with a long-standing history of a right inguinoscrotal mass (>10 years). The past history of the patient was not significant. His general physical examination was normal. On examination of the right testis, an inguinoscrotal mass was seen in relation to the right cord. The mass measured 4 cm x 3 cm and it was in relation to the upper pole of right testis. Left testis was normal. On ultrasonography of the right testis, a hypoechoic solid mass measuring 3.6 x 2.6 cm was seen in the right spermatic cord, in relation to the upper pole of testis. His routine hematological and biochemical parameters were normal. His β -HCG was 4.69 mIU/ml (against a normal value of 0-5), his AFP (α -feto-protein) was <3 ng/ml against a normal of 0-10, and his LDH (lactate dehydrogenase) was 568 (normal: 240-480).

Right high inguinal orchiectomy was done, intraoperatively, the tumor was solid arising from the cord. There was moderate hydrocele, however testes were normal. Gross examination showed testis with attached cord. Near the superior pole of the testis, there was a grey white globular tumor in the paratesticular area measuring 3 x 2.5 cm. This globular tumor was well encapsulated and there was no hemorrhage or necrosis within it.

On routine hematoxylin and eosin staining, sections from the globular swelling showed a tumor comprising of small round cells depicting mild to moderate pleomorphism. The tumor cells showed

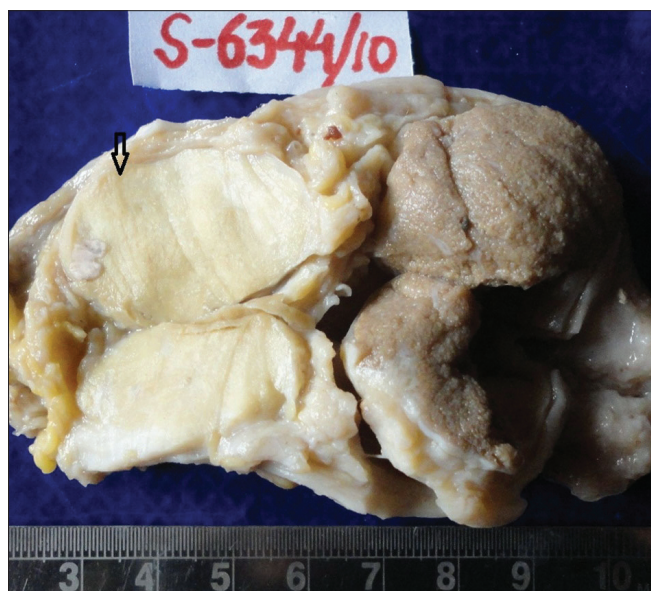

Fig. 1. Gross picture showing grey white smooth tumor in paratesticular region (arrow).

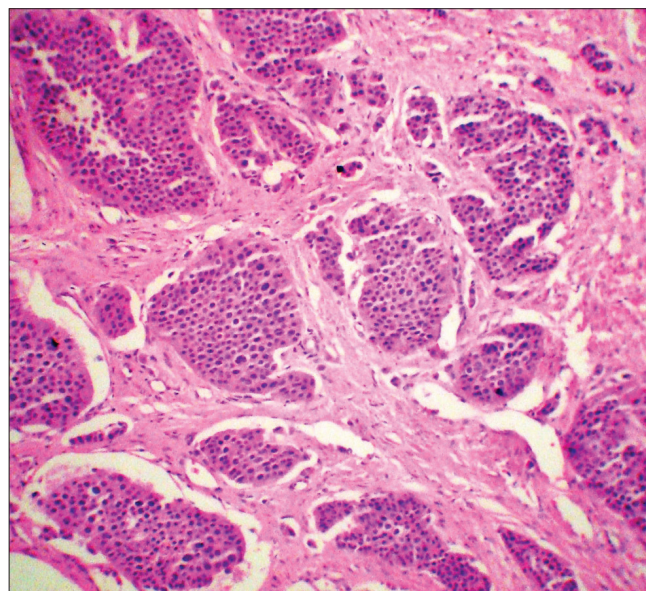


Fig. 2. Photomicrograph showing small round cells arranged in a classical nesting pattern (Hematoxylin & Eosin x20).

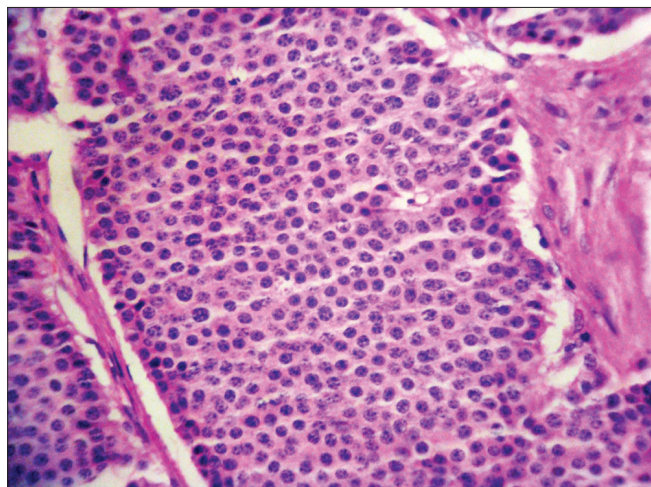


Fig. 3. Photomicrograph showing the typical salt & pepper chromatin of a carcinoid (Hematoxylin & Eosin x40).

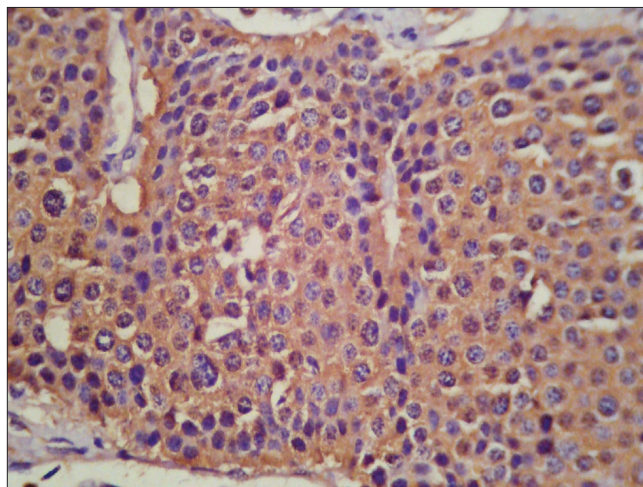


Fig. 4. Photomicrograph showing carcinoid cells with intense chromogranin positivity (Immunostain x40).

a nesting pattern and these nests were separated from each other by connective tissue septae. The capsule of the tumor was partially breached. Individual cells showed a salt and pepper type nuclear pattern. In view of these characteristics, the possibility of a neuroendocrine tumor was thought on the conventional histomorphology with the diagnostic possibility of a carcinoid or paraganglioma. The testis was histologically unremarkable.

Immunohistochemistry was done for chromogranin, synaptophysin, S-100, cytokeratin, Ki-67, desmin, myo D₁ and myogenin. Immunostain was strongly positive for chromogranin and synaptophysin. The stain for S-100 which stains sustentacular cells in a paraganglioma was negative. Cytokeratin positivity was focal and Ki-67 showed a labeling index of <5%. With these immunohistochemical characteristics, the diagnosis of a carcinoid tumor of paratesticular region was given.

In order to rule out the possibility of a secondary carcinoid, a CT of abdomen and chest was done with pan-endoscopy, which ruled out a synchronous tumor or a primary elsewhere in the gastrointestinal or respiratory tract.

DISCUSSION

Paratesticular tumors are infrequent and it has been seen that 70% of paratesticular tumors are benign and 30% are malignant. Although it is often difficult to determine with certainty the exact site of origin of paratesticular tumors, it is thought that the spermatic cord is the most common; amounting for 90% [8]. The commonest benign tumors arising from paratesticular region are lipomas, adenomatoid tumors and leiomyomas [9]. Other soft tissue tumors i.e. neurofibroma, hemangioma, cystadenoma, angiomyxoma, granular cell tumor, or dermoid cyst of the spermatic cord may also involve the paratesticular region [6]. Malignant tumors of the paratesticular region are uncommon. Malignant soft tissue tumors i.e. rhabdomyosarcoma, leiomyosarcoma, fibrosarcoma, malignant fibrohistiocytoma, malignant mesothelioma, ovarian type epithelial tumors, lymphoma, or metastatic carcinomas may be seen in the paratesticular region.

Although testicular carcinoid has been reported infrequently and is believed to be a component of a mature teratoma, paratesticular carcinoid has been seldom reported. There is hardly any available data regarding the paratesticular carcinoid with which our case can be compared [10].

Our patient presented with the history of a long-standing inguinoscrotal mass, which is the common presentation of all the be-

nign tumors of the paratestis [10]. The size of the tumor was small, it was separated and well demarcated from the surrounding testis without any evidence of necrosis/hemorrhage and had a uniform greywhite firm cut surface.

On histology, the tumor had a classical neuroendocrine morphology and its nesting pattern differentiated it from a lymphoma. Immunostaining for S-100, which stains sustentacular cells, was also negative ruling out the possibility of a paraganglioma. The MIB-1 labeling index was low, although the capsule of the tumor was breached. The longstanding nature of the mass also points out that the lesion was less likely to be malignant. The morphology of the tumor may resemble a rhabdomyosarcoma, especially an alveolar, rhabdomyosarcoma, however these tumors are commonly seen in children and adolescent and their cell morphology in our case was monotonous with no pleomorphism and necrosis [10].

Desmoplastic round cell tumors are highly aggressive sarcomas which are rare in the paratesticular region and occur in the young adult with an age distribution of 17-43 years and it characteristically shows a dot-like pattern of desmin staining, which was negative in this case. Up to 90% of the cases stain for this antigen [9].

In view of the classical morphology and characteristic immunohistochemistry characteristics, the diagnosis of a particular carcinoid was made, which is a rare entity. Its occurrence in a 70-year-old male makes it even more rare. This patient is doing well on follow-up of six months. He has not been subjected to chemotherapy since his Ki-67 index is low. For carcinoids that have a low Ki-67 index without metastasis excision with follow-up is sufficient.

REFERENCES

- Langhans T: *Ueber einen drusenpolyp in ileum*. Virchows Arch 1867; 38: 559-560.
- Lubarsch O: *Ueber den Primären Krebs des ileum, nebst Bemerkungen über des geichzeitige vorkommen von Krebs und Toberkose*. Virchows Arch 188; 111: 280-317.
- Shurtleff BT, Shvarts O, Rajfer J: *Carcinoid: Tumor of the kidney: Case report and review of the literature*. Rev Urol 2005; 7 (4): 229-233.
- Leake J, Levitt G, Ramani P: *Primary carcinoid of the testis in a 10-year old boy*. Histopathology 1991; 19: 373-375.
- Abrahamsson J, Mellander L, Nilsson O, Rubensson A: *Multiple lymph node metastasis in a body with primary testicular carcinoid, despite negative preoperative imaging procedures*. J Pediat Surg 2005; 40: 19-21.

6. Khoubehi B, Mishra V, Ali M, et al: *Adult paratesticular tumors*. BJU Int 90; 7: 707-715.
7. Lodato RF, Zentnei GJ, Gomez CA, Nochomovitz LE: *Scrotal carcinoid. Presenting manifestation of multiple lesions in the small intestine*. Am J Clin Pathol 1991; 90 (5): 664-668.
8. Richie JP: *Neoplasms of testis*. In Walsh PC, Retik AB, Vaughan ED, Nein AJ, etc. Campbells' Urology. 7th Edn. Vol. III, chapt. 78. Philadelphia: WB Saunders, 1998, pp: 2411-2452.
9. Lioe TF, Biggart JD: *Tumors of the spermatic cord and paratesticular tissue. A clinicopathological study*. Br J Urol 1993; 7: 600-606.
10. Dharkar D, Kraft JR: *Paraganglioma of the spermatic cord*. J Urol Pathol 1994; 2: 89-93.
11. Hamilton CR, Pinkerton R, Horwich A: *The management of para-testicular rhabdomyosarcoma*. Clin Radiol 1989; 40: 314-317.

Correspondence

Rumana Makhdoomi
Department of Pathology
SKIMS, Kashmir, India
190011, Post Box 29
phone: +91 941 908 1223
rumanahamid@rediffmail.com