

Management of ocular surface squamous neoplasia: Bowman Club Lecture 2021

 Osmel Peter Alvarez,¹ Mike Zein,¹ Anat Galor ,^{1,2} Carol L Karp ¹

To cite: Alvarez OP, Zein M, Galor A, *et al.* Management of ocular surface squamous neoplasia: Bowman Club Lecture 2021. *BMJ Open Ophthalmology* 2021;**6**:e000842. doi:10.1136/bmjophth-2021-000842

Received 1 July 2021
 Accepted 4 July 2021

ABSTRACT

The gold-standard treatment for ocular surface squamous neoplasia (OSSN) has traditionally been surgical excision with wide margins and a no-touch technique. However, surgery may be associated with several unfavourable sequelae, as well as significant recurrence rates if margins are positive. In recent years, topical chemotherapy with 5-fluorouracil, interferon α -2b and mitomycin C have emerged as valuable agents capable of effectively treating OSSN with varying adverse effects. These medical treatment options usually present additional costs to the patient but can allow patients to avoid surgery with fewer long-term effects. Anterior segment high-resolution optical coherence tomography is an excellent tool for diagnosing and monitoring OSSN and can be a useful aid for both surgical and medical treatments of OSSN.

INTRODUCTION

Ocular surface squamous neoplasia (OSSN) is the most common non-pigmented malignancy of the cornea and conjunctiva and represents a group of disease including dysplasia, corneal and conjunctival intraepithelial neoplasia and squamous cell carcinoma.^{1 2} The primary treatment for OSSN has generally been surgical excision with a no-touch technique, but surgical treatment has been associated with sequelae including conjunctival scarring, symblepharon, conjunctival hyperaemia and limbal stem cell deficiency.²⁻⁵ In recent years, medical treatments consisting of topical chemotherapies have emerged as valuable alternatives to surgical intervention. These topical treatments have the advantage of treating the entire ocular surface, reaching subclinical disease that could otherwise cause up to 56% recurrence rates following surgical excision with resultant positive margins.⁶ Another recent development is the advancement of anterior segment high-resolution optical coherence tomography (HR-OCT) technology. HR-OCT is an excellent tool for diagnosing and monitoring OSSN as it provides fast, noninvasive, and high-resolution imagery of the ocular surface.

SURGICAL MANAGEMENT OF OSSN

Surgical excision has long been the gold-standard treatment for OSSN. Surgical

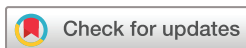management has the advantages of potentially faster resolution than medical treatment. However, surgery can be associated with up to 56% recurrence rates with resultant positive margins, requiring further treatments.⁶ Additionally, surgical excision has been associated with unfavourable sequelae such as conjunctival scarring, symblepharon, conjunctival hyperaemia and limbal stem cell deficiency.²⁻⁵ As such, patients and physicians should consider both medical and surgical approaches to treatment and balance their respective advantages and disadvantages.

Technique

The primary method of surgical excision for OSSN is the Shields 'no-touch' technique with wide margins (figure 1).⁷ Intraoperative cryotherapy is helpful, as studies have shown that this significantly reduces recurrences after surgical excision.⁸

Wide margins of 3–4 mm are marked around the visible edges of the tumour. For tumours with limbal and corneal components, corneal epitheliectomy is performed by applying absolute alcohol for 1 min. The lesion is then excised in one piece. Special attention is paid to manipulate only at the marked margins and to keep the surgical field dry to prevent potential seeding of tumour cells. For adherent tumours, a 20% sclerectomy is recommended. Cryotherapy is performed in a double freeze-slow thaw method on conjunctival margins of the excised area, as well as the limbus and cornea if the margins extend thus far. Closure of the wound with amniotic membrane tissue and fibrin glue is preferred but may also be completed with primary close if the wound is small. In this case, it would be a two-layer closure with Tenon's fascia first, then conjunctiva.

Surgical excision of OSSN is effective, but excisions with positive margins may cause up to 56% recurrence rates.⁶ However, more recent studies have found lower recurrence rates of 0%–21% following surgical excision.⁸⁻¹⁰ One study of 27 lesions used intraoperative cryotherapy on only some cases and post-operative topical mitomycin C



© Author(s) (or their employer(s)) 2021. Re-use permitted under CC BY-NC. No commercial re-use. See rights and permissions. Published by BMJ.

¹Bascom Palmer Eye Institute, Department of Ophthalmology, University of Miami Miller School of Medicine, Miami, FL, USA

²Department of Ophthalmology, Miami Veterans Administration, Miami, FL, USA

Correspondence to

Dr Carol L Karp; ckarp@med.miami.edu

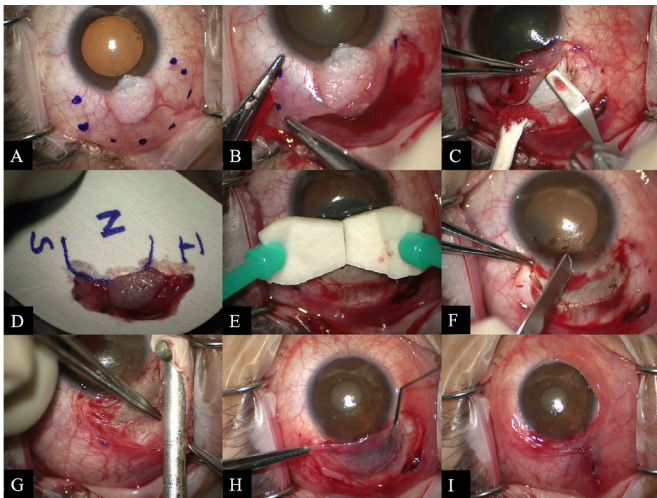


Figure 1 (A) Leukoplakic OSSN on cornea and conjunctiva with marked 4 mm margins. (B) Incision at marked margins with special care to manipulate only at or outside the margins. (C) Due to adherence of the lesion to the sclera, an approximately 20% sclerectomy under area of lesion was performed. (D) Orientation of excised lesion on sterile paper to be sent for pathological analysis. (E) Application of absolute alcohol on corneal area of excised lesion, followed by (F) corneal epitheliectomy. (G) Double freeze-slow thaw cryotherapy on conjunctival and corneal margins of the excised lesion. (H) Application of two layers of amniotic membrane tissue (AMT) bonded with fibrin glue over area of sclerectomy and excision. (I) In this case, the conjunctiva was mobile and a double closure with conjunctiva over AMT was performed. OSSN, ocular surface squamous neoplasia.

(MMC) in all cases and saw a 0% recurrence rate.¹⁰ A larger study of 389 excised lesions found a 1-year recurrence rate of 10% and a 5-year recurrence rate of 21% after surgical excision; it also found that intraoperative cryotherapy significantly reduced the risk of recurrence, as did postoperative topical interferon (IFN) α -2b for patients with resultant positive margins.⁸

Expert opinion

While the advent of effective topical chemotherapies may reduce the need for surgical management of OSSN, surgery continues to be a good choice for many cases. Surgery is an effective treatment for OSSN, often with a shorter overall treatment period than medical treatment. Additionally, insured patients may have significantly less out-of-pocket expenses with surgical treatment than with medical, as most available topical chemotherapies are generally not covered by insurance. Regardless, many patients may favour medical treatment to avoid the stress and discomfort many associate with surgery; as such, patients should be given the choice between medical and surgical treatment when appropriate.

MEDICAL MANAGEMENT OF OSSN

Since the 1990s, several topical chemotherapies have emerged as efficient medical treatment options for OSSN. These offer the benefit of treating the entire

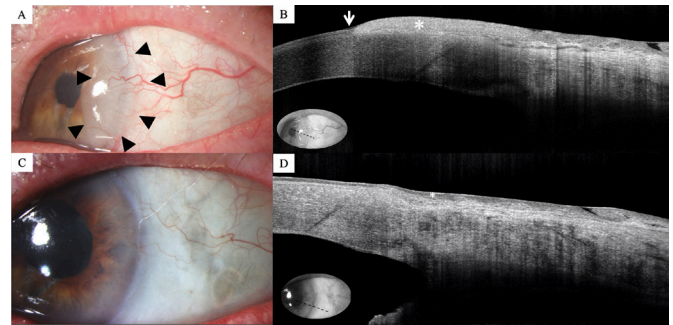


Figure 2 (A) Slit lamp photo of the left eye demonstrating an ocular surface squamous neoplasia with gelatinous features on the temporal aspect of the conjunctiva and limbus (arrow heads). (B) High-resolution anterior segment optical coherence tomography image of the inferior temporal conjunctiva and limbus demonstrating a thickened and hyper-reflective epithelium (asterisk) and an abrupt transition between normal and abnormal epithelium (arrowhead). Inset denotes anatomical location of scan. (C) Slit lamp photo of the left eye after 2 months (two cycles) of topical 5-fluorouracil treatment with clinical tumour resolution. (D) High-resolution anterior segment optical coherence tomography image of the inferior temporal conjunctiva and limbus demonstrating tumour resolution with thin, normalised epithelium (asterisk) after 2 months (two cycles) of topical 5-FU treatment. Empiric treatment was continued for the full four cycles. Inset denotes anatomical location of image. 5-FU, 5-fluorouracil.

ocular surface, theoretically addressing subclinical disease that could be left untreated by surgery. The three most common options—5-fluorouracil (5FU), IFN-2b and MMC—are all effective with have different side effect profiles and costs that should be carefully considered.

5-fluorouracil

5FU is an anticancer drug that interrupts DNA replication and cell growth.^{2 11} It was first used to treat OSSN by de Keizer *et al* and has reemerged as an effective treatment for these lesions.¹²

5FU is generally used as topical eye-drops in 1% concentration and is administered in ‘cycles’ of four times a day for 1 week, followed by 3 weeks of no medication, with cycles repeated until resolution^{2 13–15} (figure 2). Studies have shown 5FU to be very effective in treating OSSN, with high-resolution rates of 82%–100% and low recurrence rates of 10%–14%.^{13–16} 5FU has also been used as subconjunctival and perilesional injections to treat OSSN; however, the evidence is limited and this requires further study.¹⁷

Side effects of 5FU are generally mild and well tolerated. These may include pain, tearing, redness, eyelid oedema and keratopathy.¹⁴ One study of 44 patients reported that 61% experienced at least one side effect, but only one patient could not tolerate 5FU and discontinued it.¹⁵ Topical 5FU eye-drops have minimal side effects compared with other chemotherapies such as MMC.^{13 14}

Topical eye-drops of 1% 5FU must be compounded and may be safe to store at room temperature; however,

we recommend refrigeration.^{15 18 19} It is relatively inexpensive when compared with other topical treatments for OSSN, costing about US\$50 per cycle at our institution and often less in other countries. Because it is a compounded medication, most insurers generally do not cover it and patients must pay out of pocket.

Expert opinion

Topical 5FU is an excellent treatment option for OSSN. It is highly effective, easy to administer, minimally toxic and relatively inexpensive. Although it is associated with some unfavourable adverse effects, these can be minimised with proper precautions. Patients should be advised to lubricate liberally with preservative-free artificial tears throughout the course of treatment to prevent toxicity to the ocular surface. They may also be prescribed topical corticosteroids to use as needed for short-term relief of irritation. Additionally, they may be instructed to occlude the punctum briefly after applying the medication to minimise the risk of punctal stenosis. Applying petroleum jelly to the lower eyelid skin may also prevent skin irritation and toxicity. In the USA, 5FU is significantly less costly than both IFN and MMC. This should be taken into consideration as it is generally not covered by insurance because it is a compounded medication and is thus an additional expense for patients.

IFN α -2b

IFNs are naturally occurring proteins produced by immune cells and have antiviral, antimicrobial and anti-neoplastic properties.^{3 20 21} They have been used to treat a variety of diseases, including cutaneous cell carcinoma, hepatitis, cervical intraepithelial neoplasia, Kaposi's sarcoma, melanoma, hairy cell leukaemia, renal cell carcinoma and follicular lymphoma.^{21–26} IFN α -2b was first used to treat OSSN in 1994 and has since become one of the most commonly used topical chemotherapies for OSSN (figure 3).²⁷

IFN can be used as topical eye-drops, subconjunctival perilesional injections, or both.^{28 29} Both forms have shown great success in treating OSSN, with topical eye-drops having 81%–100% resolution rates and injections having 87%–100% resolution rates.^{14 28–33} IFN eye-drops also have remarkably low recurrence rates ranging from 0% to 4%.^{16 31 33 34}

As topical eye-drops, IFN is usually compounded in a 1 million international units (MIU)/mL solution and used four times per day until resolution and then at least 1–3 months after resolution.² One study compared a 1 MIU/ml dosage to a 3 MIU/ml dosage and found no significant difference in outcomes between the two.³⁵ IFN injections can be given as 3 MIU in a .5 mL solution, administered once a week²⁹ or 10 MIU in 0.5 mL given monthly.³⁴

Topical IFN eye-drops are very well tolerated by patients and generally have no side effects.^{30 31} Injections of IFN are also well tolerated, but patients typically experience

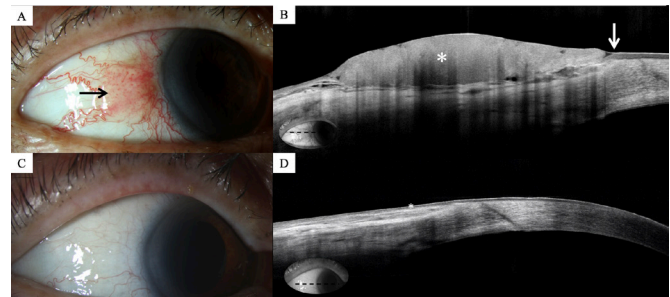


Figure 3 (A) Slit lamp photo of the right eye demonstrating an ocular surface squamous neoplasia with papilliform features on the temporal aspect of the conjunctiva and limbus (arrow). (B) High-resolution anterior segment optical coherence tomography image of the temporal conjunctiva and limbus demonstrating a thickened and hyper-reflective epithelium (asterisk) and an abrupt transition between normal and abnormal epithelium (arrowhead). Inset denotes anatomical location of scan. (C) Slit lamp photo of the right eye 4 months after topical interferon α -2b 1 MIU/mL four times daily with clinical tumour resolution. (D) High-resolution anterior segment optical coherence tomography image of the temporal conjunctiva and limbus demonstrating tumour resolution with thin, normalised epithelium (asterisk) after 4 months of topical interferon α -2b treatment. Inset denotes anatomical location of scan. MIU, million international unit.

mild flu-like symptoms for about 24 hours following the injection.²⁸

Like 5FU, topical IFN eye-drops must be compounded and are not typically covered by insurance, thus presenting an additional cost to the patient. IFN has become significantly more expensive in the USA, at around US\$800 per month, although it may be less costly in other countries. We recommend refrigeration of IFN eye-drops as well. Injections of IFN are typically covered by insurance.

Expert opinion

IFN is highly effective and has essentially no side effects, making it an ideal choice for topical chemotherapy for OSSN. Its major drawback is the cost, as it can be much more expensive than 5FU and MMC in the USA. Additionally, it is becoming increasingly difficult to obtain. However, it may be much less costly and easier to obtain in other countries. Furthermore, it must be used four times a day consistently until tumour resolution, so patient compliance is vital for tumour response. For patients who may have issues with maintaining the treatment regimen for topical IFN eye-drops, clinic-administered subconjunctival injections may be a good alternative. However, patients must commit to weekly or biweekly clinic visits. This option reduces patient responsibility, has tolerable side effects, has been proven to be effective, and is generally covered by insurance in the USA. We recommend patients take 1 g of acetaminophen at the time of injection and every 4 hours for the next day to help with the flu-like symptoms associated with IFN injections.

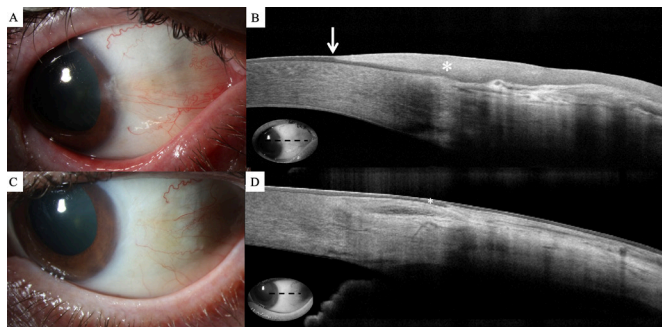


Figure 4 (A) Slit lamp photo of the left eye demonstrating an ocular surface squamous neoplasia with leukoplakic and opalescent features on the temporal aspect of the conjunctiva and limbus. (B) High-resolution anterior segment optical coherence tomography image of the temporal conjunctiva and limbus demonstrating a thickened and hyper-reflective epithelium (asterisk) and an abrupt transition between normal and abnormal epithelium (arrowhead). Inset denotes location of scan. (C) Slit lamp photo of the left eye after three cycles of topical mitomycin C treatment with clinical tumour resolution. (D) High-resolution anterior segment optical coherence tomography image of the temporal conjunctiva and limbus demonstrating tumour resolution with thin, normalised epithelium (asterisk) after 3 weekly cycles of topical mitomycin C 0.04% treatment. Inset denotes anatomical location of scan.

Mitomycin C

MMC is an antimetabolite originally isolated from *Streptomyces caespitosus*.³ Its antineoplastic and antibiotic properties make it useful in glaucoma and pterygium surgery; it is also used as an adjuvant therapy in OSSN excision surgery and for medical treatment of OSSN.^{2 36–38} MMC was first used to treat OSSN by Frucht-Pery and Rozenman and is one of the three major topical chemotherapies for OSSN.³⁹

MMC is generally used in the form of topical eye drops in strengths of 0.02–0.04%³ (figure 4). One study compared 0.02% and .04% strengths and found no difference in time to resolution or recurrence rates among the two.³⁷ MMC is also very effective, with high resolution rates ranging from 76% to 100% and low recurrence rates ranging from 0% to 20%.^{16 37 40–44}

Many different administration regimens of MMC have been studied; we recommend MMC in 4 week cycles of 0.04% four times a day for 1 week, followed by 3 weeks of no treatment, with cycles repeated until resolution. Others may use MMC with shorter breaks or longer consecutive days of treatment.^{16 19 40–46}

The main drawback of MMC is the intensity of its side effects. MMC has more adverse effects than IFN and 5FU; these include redness, itching, tearing, pain, corneal erosion, hyperaemia, punctate staining of cornea, punctal stenosis and limbal stem cell deficiency.^{16 37 40–44 46 47} In order to alleviate these effects and prevent severe toxicity, patients are commonly instructed to use steroids and artificial tears throughout the course of treatment.^{16 46} MMC should be paused with any epitheliopathy, as this can

lead to more toxic effects and intolerance. Additionally, punctal plugs are used to prevent punctal stenosis.^{42 44}

As with IFN and 5FU, MMC is a compounded medication and is generally not covered by insurance. It is typically less costly than IFN but more expensive than 5FU, costing around US\$100–US\$190 in the USA, but may be less expensive elsewhere. We recommend refrigeration of MMC.

Expert opinion

While it is very effective for OSSN, its propensity for causing ocular surface toxicity and other serious adverse effects is much greater than 5FU or IFN. Patients using MMC should be carefully monitored for signs of toxicity. They should be advised to lubricate liberally with preservative-free artificial tears throughout treatment, as epitheliopathy can lead to intolerance and limbal stem cell deficiency. We wait until the eye is white and quiet before starting the next cycle, as treatment when epitheliopathy is present can lead to unwanted toxicity. Punctal occlusion is also recommended, and silicone punctal plugs may be a good option to achieve this. Applying petroleum jelly to the lower eyelid skin is recommended to reduce skin irritation and toxicity. Additionally, patients may be given topical steroids to minimise ocular surface irritation.

ANTERIOR SEGMENT HR-OCT

OCT is an excellent technology for imaging various parts of the eye. OCT produces two-dimensional imagery of optical scattering by using low-coherence interferometry.⁴⁸ Although its first in vivo use was for the retina in 1993,⁴⁹ it was soon after used to capture in vivo images of the anterior segment in 1994.⁵⁰ Over time, OCT has advanced from time-domain, to spectral-domain, to current swept-source technology capable of producing ultrahigh resolution imagery of the anterior segment.⁵¹ Today, available OCT technology is capable of producing imagery with high resolutions of 3.5–5 µm or less.^{52 53}

HR-OCT is highly useful for detecting and monitoring several pathologies of the cornea and conjunctiva, such as OSSN (figures 2–4),⁵⁴ pterygia and pingueculae,⁵⁵ dry eye disease,⁵⁶ Fuchs' dystrophy⁵⁷ and more. It provides fast, noninvasive and high-resolution imaging of the ocular surface that can be easily interpreted by novice clinicians.⁵⁸

HR-OCT is particularly valuable for diagnosing and managing OSSN. On HR-OCT, OSSN can be identified as thickened, hyper-reflective epithelium with an abrupt transition from normal to abnormal tissue.⁵⁴ Additionally, one study showed that HR-OCT can detect subclinical OSSN in 17% of cases that were determined to be resolved clinically.⁵⁹ Thus, HR-OCT is especially useful for monitoring progression of OSSN treatment with topical chemotherapy.

HR-OCT can also potentially be useful for surgical treatment of OSSN. One recent pilot study used HR-OCT during surgical excision of OSSN as an 'optical Mohs' to

predict the margins of the tumour to be excised.⁵¹ Such use of HR-OCT may further reduce the risk of recurrence after surgical excision of OSSN and may become more common in the future.

Expert opinion

HR-OCT is a valuable tool for the diagnosis and management of OSSN. HR-OCT allows the physician to identify OSSN, track the progression of treatment and check for recurrences during follow-up. It can also help find tumour margins during surgical excision. In subtle cases, OSSN can be difficult to detect when present with other ocular surface pathologies such as pannus, pterygia, pinguecula and scarring. As such, HR-OCT serves as an 'optical biopsy'. It is fast, non-invasive and presents virtually no discomfort to the patient. Recent models offering ultrahigh resolution offer impressive visualisations of OSSN and other lesions. It should be noted that OSSN occurring on the cornea may appear less thickened than conjunctival OSSN, but usually also show the other classic features of hyper-reflective epithelium and abrupt transition from normal to abnormal tissue.

CONCLUSION

While surgical excision has traditionally been the gold-standard treatment for OSSN, topical chemotherapies are now available as valuable and effective alternatives. These medical treatments offer the advantage of treating the entire ocular surface and can avoid some of the unfavourable sequelae associated with surgery. However, their various side effect profiles, need for compliance and financial implications should be taken into account by the patient and physician. Additionally, advanced HR-OCT technology can complement both medical and surgical treatments. HR-OCT can aid the physician in diagnosing OSSN, monitoring it throughout medical treatment and detecting subclinical disease. Future integration with operating microscopes will potentially allow the surgeon more accurately mark the margins of the tumour to be removed, hopefully further reducing the risk of recurrence.

Funding NIH Center Core Grant P30EY014801, RPB Unrestricted Award, Dr Ronald and Alicia Lepke Grant, The Lee and Claire Hager Grant, The Robert Farr Family Grant, The Grant and Diana Stanton-Thornbrough, The Robert Baer Family Grant, The Roberto and Antonia Menendez Grant, The Emilyn Page and Mark Feldberg Grant, The Calvin and Flavia Oak Support Fund, The Robert Farr Family Grant, The Jose Ferreira de Melo Grant, The Richard and Kathy Lesser Grant, The Michele and Ted Kaplan Grant and the Richard Azar Family Grant (institutional grants).

Competing interests None declared.

Patient consent for publication Not required.

Provenance and peer review Commissioned; internally peer reviewed.

Data availability statement No data are available. Not applicable.

Open access This is an open access article distributed in accordance with the Creative Commons Attribution Non Commercial (CC BY-NC 4.0) license, which permits others to distribute, remix, adapt, build upon this work non-commercially, and license their derivative works on different terms, provided the original work is properly cited, appropriate credit is given, any changes made indicated, and the use is non-commercial. See: <http://creativecommons.org/licenses/by-nc/4.0/>.

ORCID iDs

Anat Galor <http://orcid.org/0000-0002-3026-6155>

Carol L Karp <http://orcid.org/0000-0002-6452-7181>

REFERENCES

- Shields CL, Demirci H, Karatza E, *et al*. Clinical survey of 1643 melanocytic and nonmelanocytic conjunctival tumors. *Ophthalmology* 2004;111:1747–54.
- Al Bayyat G, Arreaza-Kaufman D, Venkateswaran N, *et al*. Update on pharmacotherapy for ocular surface squamous neoplasia. *Eye Vis* 2019;6:24.
- Nanji AA, Sayyad FE, Karp CL. Topical chemotherapy for ocular surface squamous neoplasia. *Curr Opin Ophthalmol* 2013;24:336–42.
- Nanji AA, Moon CS, Galor A, *et al*. Surgical versus medical treatment of ocular surface squamous neoplasia: a comparison of recurrences and complications. *Ophthalmology* 2014;121:994–1000.
- Sayed-Ahmed IO, Palioura S, Galor A, *et al*. Diagnosis and medical management of ocular surface squamous neoplasia. *Expert Rev Ophthalmol* 2017;12:11–19.
- Tabin G, Levin S, Snibson G, *et al*. Late recurrences and the necessity for long-term follow-up in corneal and conjunctival intraepithelial neoplasia. *Ophthalmology* 1997;104:485–92.
- Shields JA, Shields CL, De Potter P. Surgical management of conjunctival tumors. The 1994 Lynn B. McMahan lecture. *Arch Ophthalmol* 1997;115:808–15.
- Galor A, Karp CL, Oellers P, *et al*. Predictors of ocular surface squamous neoplasia recurrence after excisional surgery. *Ophthalmology* 2012;119:1974–81.
- Bowen RC, Soto H, Raval V, *et al*. Ocular surface squamous neoplasia: outcomes following primary excision with 2 mm margin and cryotherapy. *Eye* 2021. doi:10.1038/s41433-020-01353-5. [Epub ahead of print: 19 Jan 2021].
- Chen C, Louis D, Dodd T, *et al*. Mitomycin C as an adjunct in the treatment of localised ocular surface squamous neoplasia. *Br J Ophthalmol* 2004;88:17–18.
- Abraham LM, Selva D, Casson R, *et al*. The clinical applications of fluorouracil in ophthalmic practice. *Drugs* 2007;67:237–55.
- de Keizer RJ, de Wolff-Rouendaal D, van Delft JL. Topical application of 5-fluorouracil in premalignant lesions of cornea, conjunctiva and eyelid. *Doc Ophthalmol* 1986;64:31–42.
- Parozzani R, Frizziero L, Trainiti S, *et al*. Topical 1% 5-fluorouracil as a sole treatment of corneconjunctival ocular surface squamous neoplasia: long-term study. *Br J Ophthalmol* 2017;101:1094–9.
- Venkateswaran N, Mercado C, Galor A, *et al*. Comparison of topical 5-fluorouracil and interferon alfa-2b as primary treatment modalities for ocular surface squamous neoplasia. *Am J Ophthalmol* 2019;199:216–22.
- Joag MG, Sise A, Murillo JC, *et al*. Topical 5-Fluorouracil 1% as Primary Treatment for Ocular Surface Squamous Neoplasia. *Ophthalmology* 2016;123:1442–8.
- Kusumesh R, Ambastha A, Kumar S, *et al*. Retrospective comparative study of topical interferon α 2b versus mitomycin C for primary ocular surface squamous neoplasia. *Cornea* 2017;36:327–31.
- Sun Y, Hua R. Long-Term efficacy and safety of Subconjunctival/Perilesional 5-fluorouracil injections for ocular surface squamous neoplasia. *Drug Des Devel Ther* 2020;14:5659–65.
- Kim JW, Abramson DH. Topical treatment options for conjunctival neoplasms. *Clin Ophthalmol* 2008;2:503–15.
- Cohen VML, O'Day RF. Management issues in conjunctival tumours: ocular surface squamous neoplasia. *Ophthalmol Ther* 2020;9:181–90.
- Baron S, Tyring SK, Fleischmann WR, *et al*. The interferons. mechanisms of action and clinical applications. *JAMA* 1991;266:1375–83.
- Parker BS, Rautela J, Hertzog PJ. Antitumour actions of interferons: implications for cancer therapy. *Nat Rev Cancer* 2016;16:131–44.
- Edwards L, Berman B, Rapini RP, *et al*. Treatment of cutaneous squamous cell carcinomas by intralesional interferon alfa-2b therapy. *Arch Dermatol* 1992;128:1486–9.
- Chevaliez S, Pawlotsky J-M. Interferon-based therapy of hepatitis C. *Adv Drug Deliv Rev* 2007;59:1222–41.
- Chakalova G, Ganchev G. Local administration of interferon-alpha in cases of cervical intraepithelial neoplasia associated with human papillomavirus infection. *J Buon* 2004;9:399–402.
- Decatris M, Santhanam S, O'Byrne K. Potential of interferon-alpha in solid tumours: part 1. *BioDrugs* 2002;16:261–81.



- 26 Santhanam S, Decatris M, O'Byrne K. Potential of interferon-alpha in solid tumours: part 2. *BioDrugs* 2002;16:349–72.
- 27 Maskin SL. Regression of limbal epithelial dysplasia with topical interferon. *Arch Ophthalmol* 1994;112:1145–6.
- 28 Karp CL, Galor A, Chhabra S, *et al*. Subconjunctival/perilesional recombinant interferon α 2b for ocular surface squamous neoplasia: a 10-year review. *Ophthalmology* 2010;117:2241–6.
- 29 Vann RR, Karp CL. Perilesional and topical interferon alfa-2b for conjunctival and corneal neoplasia. *Ophthalmology* 1999;106:91–7.
- 30 Karp CL, Moore JK, Rosa RH. Treatment of conjunctival and corneal intraepithelial neoplasia with topical interferon alpha-2b. *Ophthalmology* 2001;108:1093–8.
- 31 Kusumesh R, Ambastha A, Sinha B, *et al*. Topical interferon α -2b as a single therapy for primary ocular surface squamous neoplasia. *Asia Pac J Ophthalmol* 2015;4:279–82.
- 32 Shah SU, Kaliki S, Kim HJ, *et al*. Topical interferon alfa-2b for management of ocular surface squamous neoplasia in 23 cases: outcomes based on American joint Committee on cancer classification. *Arch Ophthalmol* 2012;130:159–64.
- 33 Shields CL, Constantinescu AB, Paulose SA, *et al*. Primary treatment of ocular surface squamous neoplasia with topical interferon alpha-2b: comparative analysis of outcomes based on original tumor configuration. *Indian J Ophthalmol* 2021;69:563–7.
- 34 Shields CL, Kaliki S, Kim HJ, *et al*. Interferon for ocular surface squamous neoplasia in 81 cases: outcomes based on the American joint Committee on cancer classification. *Cornea* 2013;32:248–56.
- 35 Galor A, Karp CL, Chhabra S, *et al*. Topical interferon alpha 2b eye-drops for treatment of ocular surface squamous neoplasia: a dose comparison study. *Br J Ophthalmol* 2010;94:551–4.
- 36 Blasi MA, Maceroni M, Sammarco MG, *et al*. Mitomycin C or interferon as adjuvant therapy to surgery for ocular surface squamous neoplasia: comparative study. *Eur J Ophthalmol* 2018;28:204–9.
- 37 Daniell M, Maini R, Tole D. Use of mitomycin C in the treatment of corneal conjunctival intraepithelial neoplasia. *Clin Exp Ophthalmol* 2002;30:94–8.
- 38 Giaconi JA, Karp CL. Current treatment options for conjunctival and corneal intraepithelial neoplasia. *Ocul Surf* 2003;1:66–73.
- 39 Frucht-Pery J, Rozenman Y. Mitomycin C therapy for corneal intraepithelial neoplasia. *Am J Ophthalmol* 1994;117:164–8.
- 40 Ballalai PL, Erwenne CM, Martins MC, *et al*. Long-term results of topical mitomycin C 0.02% for primary and recurrent conjunctival-corneal intraepithelial neoplasia. *Ophthalmic Plast Reconstr Surg* 2009;25:296–9.
- 41 Frucht-Pery J, Sugar J, Baum J, *et al*. Mitomycin C treatment for conjunctival-corneal intraepithelial neoplasia: a multicenter experience. *Ophthalmology* 1997;104:2085–93.
- 42 Hirst LW. Randomized controlled trial of topical mitomycin C for ocular surface squamous neoplasia: early resolution. *Ophthalmology* 2007;114:976–82.
- 43 Prabhasawat P, Tarinvorakup P, Tesavibul N, *et al*. Topical 0.002% mitomycin C for the treatment of conjunctival-corneal intraepithelial neoplasia and squamous cell carcinoma. *Cornea* 2005;24:443–8.
- 44 Wilson MW, Hungerford JL, George SM, *et al*. Topical mitomycin C for the treatment of conjunctival and corneal epithelial dysplasia and neoplasia. *Am J Ophthalmol* 1997;124:303–11.
- 45 Khong JJ, Muecke J. Complications of mitomycin C therapy in 100 eyes with ocular surface neoplasia. *Br J Ophthalmol* 2006;90:819–22.
- 46 Russell HC, Chadha V, Lockington D, *et al*. Topical mitomycin C chemotherapy in the management of ocular surface neoplasia: a 10-year review of treatment outcomes and complications. *Br J Ophthalmol* 2010;94:1316–21.
- 47 Dudney BW, Malecha MA. Limbal stem cell deficiency following topical mitomycin C treatment of conjunctival-corneal intraepithelial neoplasia. *Am J Ophthalmol* 2004;137:950–1.
- 48 Huang D, Swanson EA, Lin CP, *et al*. Optical coherence tomography. *Science* 1991;254:1178–81.
- 49 Swanson EA, Izatt JA, Hee MR, *et al*. In vivo retinal imaging by optical coherence tomography. *Opt Lett* 1993;18:1864–6.
- 50 Izatt JA, Hee MR, Swanson EA, *et al*. Micrometer-scale resolution imaging of the anterior eye in vivo with optical coherence tomography. *Arch Ophthalmol* 1994;112:1584–9.
- 51 Karp CL, Mercado C, Venkateswaran N, *et al*. Use of High-Resolution Optical Coherence Tomography in the Surgical Management of Ocular Surface Squamous Neoplasia: A Pilot Study. *Am J Ophthalmol* 2019;206:17–31.
- 52 Ang M, Baskaran M, Werkmeister RM, *et al*. Anterior segment optical coherence tomography. *Prog Retin Eye Res* 2018;66:132–56.
- 53 Puzyeyeva O, Lam WC, Flanagan JG, *et al*. High-resolution optical coherence tomography retinal imaging: a case series illustrating potential and limitations. *J Ophthalmol* 2011;2011:764183.
- 54 Shousha MA, Karp CL, Perez VL, *et al*. Diagnosis and management of conjunctival and corneal intraepithelial neoplasia using ultra high-resolution optical coherence tomography. *Ophthalmology* 2011;118:1531–7.
- 55 Soliman W, Mohamed TA. Spectral domain anterior segment optical coherence tomography assessment of pterygium and pinguecula. *Acta Ophthalmol* 2012;90:461–5.
- 56 Ibrahim OMA, Dogru M, Takano Y, *et al*. Application of visante optical coherence tomography tear meniscus height measurement in the diagnosis of dry eye disease. *Ophthalmology* 2010;117:1923–9.
- 57 Shousha MA, Perez VL, Wang J, *et al*. Use of ultra-high-resolution optical coherence tomography to detect in vivo characteristics of Descemet's membrane in Fuchs' dystrophy. *Ophthalmology* 2010;117:1220–7.
- 58 Yim M, Galor A, Nanji A, *et al*. Ability of novice clinicians to interpret high-resolution optical coherence tomography for ocular surface lesions. *Can J Ophthalmol* 2018;53:150–4.
- 59 Tran AQ, Venkateswaran N, Galor A, *et al*. Utility of high-resolution anterior segment optical coherence tomography in the diagnosis and management of sub-clinical ocular surface squamous neoplasia. *Eye Vis* 2019;6:27.