



CLINICAL PRACTICE ARTICLE

REVISED **The impact of using primaquine without prior G6PD testing: a case series describing the obstacles to the medical management of haemolysis [version 2; peer review: 2 approved]**

Cindy S. Chu ^{1,2}, Germana Bancone ^{1,2}, Nay Lin Soe¹, Verena I. Carrara ^{1,3}, Gornpan Gornsawun¹, François Nosten ^{1,2}

¹Shoklo Malaria Research Unit, Mahidol-Oxford Tropical Medicine Research Unit, Faculty of Tropical Medicine, Mahidol University, Mae Sot, Thailand

²Centre for Tropical Medicine and Global Health, Nuffield Department of Medicine, University of Oxford, Oxford, UK

³Department of Medicine, Swiss Tropical and Public Health Institute, Basel, Switzerland

v2 **First published:** 06 Feb 2019, 4:25 (<https://doi.org/10.12688/wellcomeopenres.15100.1>)

Latest published: 09 Apr 2019, 4:25 (<https://doi.org/10.12688/wellcomeopenres.15100.2>)

Abstract

Radical cure of *Plasmodium vivax* malaria in glucose-6-phosphate dehydrogenase (G6PD) deficient individuals employs weekly primaquine dosing. This is the only recommended regimen for this patient sub-group. If national malaria programs mandate daily primaquine dosing (the recommended regimen for G6PD normal individuals), then G6PD testing before prescription is necessary to avoid iatrogenic haemolysis in G6PD deficient individuals. In this case series, two *P. vivax* infected patients with unknown G6PD status from two different countries were prescribed primaquine as per national malaria program guidelines. During treatment both patients presented to the clinic with symptoms of anaemia after taking primaquine incorrectly. The clinical management of the iatrogenic severe haemolysis that occurred in these patients demonstrates the various adverse effects primaquine can cause, that other common medical treatments also have haemolytic potential, and how the diagnosis of G6PD deficiency can be elusive during acute haemolysis. Health care providers should provide careful instructions about primaquine dosing, be watchful for haemolysis, and have a high index of suspicion for G6PD deficiency in the presence of haemolysis if the G6PD status is previously unknown.

Keywords

Plasmodium vivax, Primaquine, Haemolysis, G6PD deficiency

Open Peer Review

Referee Status:

	Invited Referees	
	1	2
REVISED		
version 2	report	report
published 09 Apr 2019		
version 1	? report	? report
published 06 Feb 2019		

1 **Larry A. Walker** , University of Mississippi, USA

2 **Wuelton M. Monteiro**, Universidade do Estado do Amazonas, Brazil

Any reports and responses or comments on the article can be found at the end of the article.

Corresponding author: Cindy S. Chu (cindy@tropmedres.ac)

Author roles: **Chu CS:** Conceptualization, Data Curation, Formal Analysis, Supervision, Visualization, Writing – Original Draft Preparation, Writing – Review & Editing; **Bancone G:** Validation, Visualization, Writing – Review & Editing; **Soe NL:** Data Curation, Writing – Review & Editing; **Carrara VI:** Data Curation, Supervision, Writing – Review & Editing; **Gornsawun G:** Validation, Writing – Review & Editing; **Nosten F:** Conceptualization, Supervision, Writing – Review & Editing

Competing interests: No competing interests were disclosed.

Grant information: CSC, GB, and FN are part of the Wellcome Trust Mahidol University Oxford Tropical Medicine Research Programme funded by the Wellcome Trust.

The funders had no role in study design, data collection and analysis, decision to publish, or preparation of the manuscript.

Copyright: © 2019 Chu CS *et al.* This is an open access article distributed under the terms of the [Creative Commons Attribution Licence](https://creativecommons.org/licenses/by/4.0/), which permits unrestricted use, distribution, and reproduction in any medium, provided the original work is properly cited.

How to cite this article: Chu CS, Bancone G, Soe NL *et al.* **The impact of using primaquine without prior G6PD testing: a case series describing the obstacles to the medical management of haemolysis [version 2; peer review: 2 approved]** Wellcome Open Research 2019, 4:25 (<https://doi.org/10.12688/wellcomeopenres.15100.2>)

First published: 06 Feb 2019, 4:25 (<https://doi.org/10.12688/wellcomeopenres.15100.1>)

REVISED Amendments from Version 1

The revised version of this manuscript mainly respond to the reviewer comments. It includes more clinical details during the hospital course and outcome. Revisions are also made in the discussion to emphasise the risk of severe haemolysis, further describe G6PD activity in reticulocytes in context of haemoglobin recovery, and clarify that the recommendations made are applicable to all G6PD genotypes.

An additional affiliation has been listed for Verena I. Carrara: Department of Medicine, Swiss Tropical and Public Health Institute, Basel, Switzerland.

For more information and interesting discussion, please see the reviewer comments and our responses.

See referee reports

Introduction

Primaquine is the only treatment available for the radical cure of *Plasmodium vivax* malaria. It is not widely used because G6PD deficient persons develop a dose dependent haemolysis when exposed to the daily doses in the 14-day regimen. They should receive the weekly dose of 0.75 mg/kg in the 8-week regimen which delivers nearly the same total dose. The evidence supporting the safety of the 8-week regimen was derived from a study performed in the 1960's where a weekly primaquine dose (45 mg) caused less haemolysis than a daily dose (30 mg) in G6PD deficient adult patients of African descent¹. The efficacy of this weekly dose was 90% and this resulted in the recommendation that 45 mg or 0.75mg/kg/week for 8 weeks be used in G6PD deficient persons within the general population "providing some supervision of drug administration be maintained"¹. Contemporary studies show that the efficacy of this dose remains over 90%² and more safety assessments are needed³.

In some areas, the practice is to prescribe primaquine to patients in the entirety of the dose without G6PD testing and without further follow up or medical supervision. Adherence to this prolonged weekly treatment regimen is an issue especially if common adverse effects such as abdominal pain occur. In Myanmar, the national policy up to 2018 is to give the 8-week 0.75mg base/kg regimen to all *P. vivax* infected patients. In Thailand, the 14-day 0.25 mg base/kg/day regimen is given. Testing for G6PD deficiency prior to treatment is not a requirement in the national policy for malaria treatment in either country. This means that undiagnosed G6PD deficient patients have the potential to develop primaquine induced haemolysis, especially with daily regimens⁴. The haemolysis can be more severe if doses are taken incorrectly with either primaquine regimen⁵.

The prevalence of G6PD deficiency varies by geographic region and between ethnic groups⁶. In Thailand, it reaches 20% in some populations^{7,8}. In neighbouring Myanmar the prevalence ranges from 4% to 12% in the general population⁹ and nearly 13% in males living in eastern Myanmar along the Thailand border^{10,11}. A substantial proportion of populations are thus at risk for primaquine induced haemolysis if G6PD deficiency is not diagnosed before treatment¹² or if primaquine is taken incorrectly.

Here, we describe primaquine induced haemolysis in two G6PD Mahidol hemizygous males. The first case received the initial

P. vivax diagnosis and treatment in Myanmar and the second case in Thailand.

Case 1

A 16-year-old male presented to the clinic. He was weak and nearly prostrate. He had a >10 day history of fever, dizziness, cough, dyspnoea and abdominal pain. Earlier in the morning, he had passed red urine. He was diagnosed with *P. vivax* malaria at a government clinic in Myanmar 10 days previous. In addition to chloroquine, he was prescribed a course (number of tablets unknown) of primaquine tablets (7.5 mg) with verbal instructions from the health worker. This was presumed to be the 8-week primaquine regimen as per the Myanmar national malaria policy. At home, the patient took 30mg daily for 4 days (1mg/kg/day). He stopped because he felt unwell.

On arrival, the Glasgow Coma Score (GCS) score was 15/15. He appeared severely unwell and was unable to speak due to dyspnoea. Weight was 30 kg, temperature 37.5°C, heart rate (HR) 113 beats per minute, respiratory rate (RR) 36 breaths per minute, blood pressure (BP) 90/50 mmHg, and oxygen saturation (SaO₂) 82–87% on 5L O₂ by face mask. On physical examination the following were noted: icteric sclerae, conjunctival pallor, tachycardia with normal heart sounds and no audible murmur, clear lung sounds bilaterally, a soft abdomen with no hepatosplenomegaly, and pallor of the hands.

Initial blood work was performed (Table 1); malaria smear was negative, haematocrit was 15%, and G6PD fluorescent spot test (FST) was normal (not deficient). He was resuscitated with normal saline and treated empirically with ceftriaxone 1gm intravenously. Within 4 hours of arrival, the patient was given one unit of blood to which he responded well. The donor was a female whose G6PD status was normal by FST and genotyping. Vital signs after blood transfusion were: HR 90 beats per minute, RR 24 breaths per minute, BP 100/50 mmHg, and SaO₂ 90% on 2L O₂ by nasal cannula. Urine output was normal throughout the resuscitation period.

The patient's clinical condition improved daily for the remainder of the hospital course. The DNA analysis showed that the patient was hemizygote for G6PD Mahidol variant. On the 8th day of hospitalisation, the patient was discharged home. His haematocrit had increased to 30%. The patient was counselled not to take daily doses of primaquine, but that the 8-week course under supervision would be possible. He was given a 'G6PD deficiency card' describing the disease and drugs to avoid, which was to be presented at all future health care visits. It was emphasised that other members of the family might also have G6PD deficiency and should be tested. Weekly primaquine dosing for the radical cure of *P. vivax* malaria could not be prescribed because close medical supervision during treatment was not possible. Health care workers with specific knowledge of haemolysis and access to hospital care were not available in their remote village.

Case 2

This case is a 13-year-old male who presented to the clinic with a history of fever for the previous 4 days. He reported fatigue, cough, vomiting and passing some red urine. He was taken to a

Table 1. Laboratory test results for Cases 1 and 2.

Laboratory test (reference range)	Case 1 (fever history >10 days)			Case 2 (fever history 4 days)				
	Day 1*	Day 2	Day 8	Day 1	Day 2	Day 3*	Day 4	Day 8
Field Haematocrit (36–56%) ^a	15	20	30	34	30	27	24	24
Methaemoglobin (<3%)	-	-	-	17.1	18.3	15.5	2.7	0.6
RBC count (3.80–5.30 x10 ⁶ /uL)	1.43	-	-	5.01	-	3.57	-	-
Haemoglobin (11.0–17.0 g/dL)	4.1	-	-	9.8	-	6.8	-	-
MCV (80–100 fL)	93.7	-	-	63.1	-	65.0	-	-
WBC (4.0–9.0 x10 ³ /uL)	40.4	-	-	5.5	-	11.3	-	-
Neutrophil (1.7–7.7 x10 ³ /uL)	30.8	-	-	4.3	-	7.3	-	-
Lymphocyte (0.4–4.4 x10 ³ /uL)	5.4	-	-	0.9	-	2.3	-	-
Platelets (120–380 x10 ³ /uL)	596	-	-	224	-	352	-	-
Nucleated RBC (<1%)	9	-	-	-	-	-	-	-
Reticulocyte count (<2.5%)	ND	-	-	0.5	-	1.2	-	-
G6PD FST (normal)	normal	-	-	deficient	-	-	-	-
G6PD spectrophotometry (>5.6 IU/gHb)	-	-	-	0.39	-	-	-	-
G6PD genotype ^b	-	-	Mahidol	-	-	-	-	Mahidol
Urine colour (clear or yellow)	red	-	clear	yellow/red	-	black	-	clear
Urine stick for haemoglobin ^c	-	4+	-	4+	4+	-	-	-
CRP (<8 mg/L)	89.6	-	-	<8	-	6.4	-	-
BUN (6–20 mg/dL)	35	-	-	-	12	11	17	-
Creatinine (0.67–1.17 mg/dL)	1.22	-	-	-	0.58	0.64	0.97	-
LDH (135–225 IU/L)	5,381	-	-	-	-	-	-	-
Dengue rapid diagnostic test ^c	negative	-	-	-	-	negative	-	-
Scrub rapid diagnostic test ^c	-	-	-	-	-	negative	-	-

* A blood transfusion was given on this day and the blood work results are prior.

^a Capillary sample is obtained, centrifuged, and read manually

^b G6PD genotyping was performed only for Mahidol variant

^c For these tests the normal result is 'negative'

government clinic in Thailand on the first day of fever. He was diagnosed with *P. vivax* malaria and given chloroquine plus primaquine 30mg daily for 14 days (15 mg tablets) as per the Thailand national guidelines. At home, the patient took primaquine 30mg daily for 2 days, then 30mg twice daily for 1 day (0.84mg/kg on the first 2 days, then 1.7 mg/kg for the 3rd day). The patient then felt unwell and came to the SMRU clinic.

On physical examination, he was stable but weak with slight central cyanosis. His GCS was 15/15. Weight was 35 kg, temperature 38.8°C, HR 97 beats per minute, RR 23 respirations per minute, blood pressure 110/70 mmHg and SaO₂ 88% on 2L O₂ by nasal cannula. On physical examination his conjunctiva and sclera were normal, heart sounds were normal, lungs clear to auscultation bilaterally, abdomen soft and without hepatosplenomegaly, and his palms were not pale or cyanotic.

At admission the malaria smear was negative, field haematocrit was 34%, and G6PD FST was deficient. Because of the cyanosis, a transcutaneous methaemoglobin measurement (Masimo®) was performed and found to be 17.1% (normal range 0–2%). He was started on Vitamin C 200mg three times daily for symptomatic methaemoglobinaemia. The primaquine was stopped and no other treatments were given.

On the following day (hospital day 2), results from the blood work were available (Table 1). The CBC showed a high RBC count and low MCV. The reticulocyte count was 0.5%, which was unexpectedly low for the 4th day of a haemolytic episode. The G6PD spectrophotometric assay confirmed the deficiency with an enzymatic activity of 0.39IU/gHb (normal value for males 8IU/gHb) and DNA analysis showed that the patient was hemizygote for G6PD Mahidol variant. Antibiotics were not prescribed as the CBC and CRP results were not suggestive of a bacterial

infection. The haematocrit decreased further to 27% on hospital day 3 and was accompanied by red urine (Figure 1). The urine sediment was negative for RBCs (consistent with intravascular haemolysis). The next day, a blood transfusion was given. Vitamin C was stopped as it is a potential exacerbator of haemolysis^{13,14}.

Post-transfusion, his field haematocrit increased to 30% and the transcutaneous methaemoglobin values had decreased to 2.1% which were within the normal range. There were no clinical signs of acute kidney injury although his creatinine increased from 0.58 to 0.97mg/dL. The patient did not recover as quickly as expected. On hospital days 5–7, his oxygen requirement decreased to room air. He continued to have a low-grade fever (37.5°C) and this may have been due to the haemolysis. His haematocrit declined to 21%. By hospital day 8, the fever resolved spontaneously and haematocrit increased to 24%. The patient's clinical condition was stable, so he was discharged that day by request of the family. They were counselled with the same information as for Case 1 and the G6PD deficiency card was given. For the same reasons as Case 1, the 8-week primaquine regimen was not prescribed.

Discussion

Presented here are two G6PD deficient patients who received primaquine without G6PD testing as per the national policy of the country where the initial consultation occurred. The patient from Myanmar (Case 1) received the 8-week primaquine regimen, which should have been safe, but the doses were taken incorrectly, and severe haemolysis occurred. The patient from Thailand (Case 2) received the 14-day primaquine regimen which would have caused haemolysis even if the dose was taken correctly. In both cases haemolysis was exacerbated, by concomitant illness and a haemolytic medication^{3,15} and both cases had the potential to be fatal¹⁶.

During treatment with primaquine (a rapidly eliminated oxidative drug) in G6PD deficient patients whose enzymatic activity is not compromised yet in reticulocytes, the haematocrit is expected to stabilize or rise the following day after the drug has been stopped given an adequate reticulocyte response¹⁷. However, in both of these cases the haematocrit did not rise even after stopping primaquine. In the first case, a concomitant bacterial infection may have caused persistent haemolysis, though primaquine induced haemolysis may also be accompanied by fever and increased WBC¹⁸. The second case, presented with an elevated methaemoglobin¹⁹, a nearly normal haematocrit

and normal reticulocyte count indicating that the bulk of haemolysis occurred after primaquine had been stopped. Administration of Vitamin C, which has been shown to cause haemolysis in G6PD deficient subjects^{13,14,20} might have contributed to continued haemolysis. This patient also demonstrated reduced reticulocyte production, which may have been caused by iron deficiency or a concomitant haemoglobinopathy²¹. Haemoglobin typing and assessment of iron deficiency could not be carried out.

The G6PD FST can give a normal result in a G6PD deficient patient who has already undergone some degree of haemolysis. Thus, a normal qualitative test result does not rule out G6PD deficiency during or shortly after a haemolytic crisis because older red blood cells with low G6PD enzymatic activity have haemolysed and younger cells with higher G6PD enzymatic activity have reached blood circulation²². In this specific situation, genotyping is used to make a diagnosis of G6PD deficiency; in populations with well described variants, a well-equipped laboratory could support this approach. If genotyping is not available, the G6PD phenotypic test can be repeated later, after recovery. Transiently elevated G6PD activity can lead to an incorrect diagnosis of G6PD normality and potentially incorrect medical management.

During haemolysis, acute kidney injury from severe haemolysis and massive haematuria is a concern. Thus, using G6PD normal donor blood for transfusion can avoid further haemolysis and kidney injury. If only qualitative G6PD tests are available, ideally, the donor would be a healthy G6PD normal male. For healthy female blood donors, a quantitative G6PD test is necessary to confirm if there is enough G6PD activity (>80% normal activity) so that further haemolysis is avoided.

Accurate phenotypic diagnosis of G6PD deficiency and increased knowledge of what illnesses and drugs contribute to haemolysis are needed to improve the management of haemolysis. Primaquine will be used increasingly for *P. vivax* elimination, and more G6PD deficient patients will be exposed. If G6PD testing is not performed before prescribing primaquine we may see similar cases as presented here. Health care providers should consider the diagnosis of G6PD deficiency in any patient with a haemoglobin or haematocrit reduction following primaquine or any other haemolytic drug⁴. Potential actions will depend on the health care level (Figure 2).

To promote safe primaquine prescription for *P. vivax*, we recommend the following:

- If G6PD testing is not performed before the primaquine regimen, it is safest to supervise treatment in all treated individuals.
- If G6PD *qualitative* testing is available, counselling should be given to G6PD deficient individuals and all females about the signs and symptoms of haemolysis and anaemia, so they know when to seek care for complications. Females with intermediate G6PD activity are also at risk for haemolysis. It can be useful to supervise treatment to prevent accidental overdose and monitor for haemolysis.
- When G6PD *quantitative* testing is available, focused counselling can be given to G6PD deficient individuals

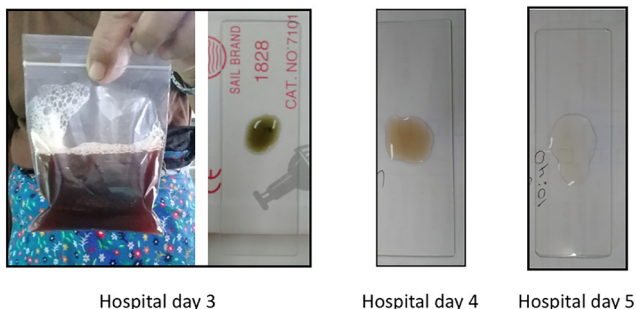


Figure 1. The resolution of haemoglobinuria in case 2.

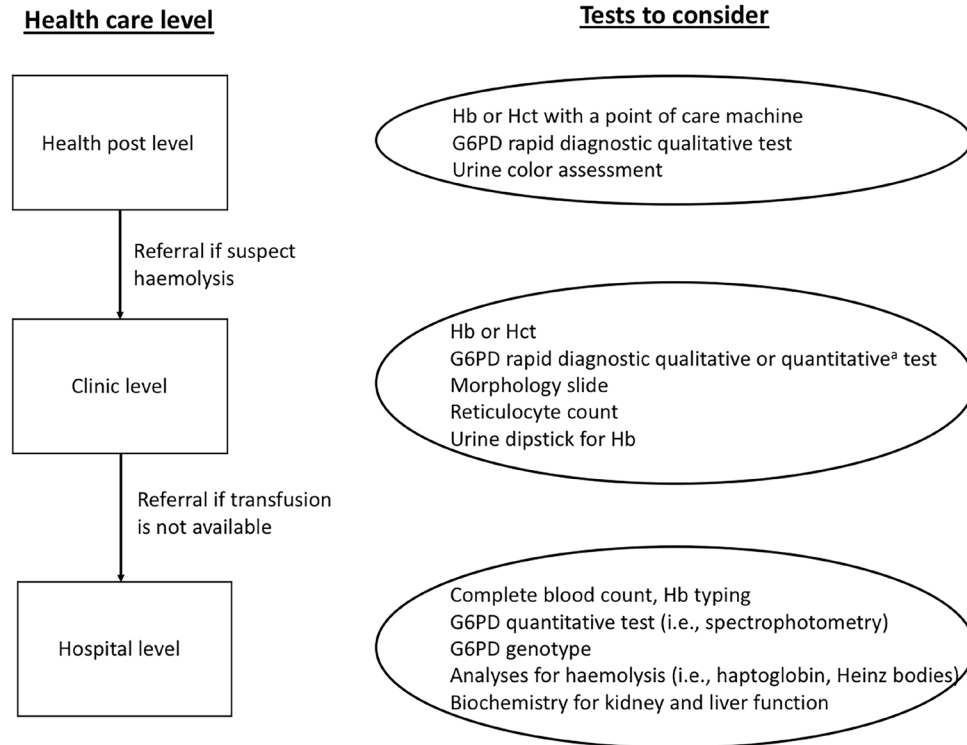


Figure 2. Suggested procedures when haemolysis in a G6PD deficient patient is suspected. ^a Currently, the STANDARD™ G6PD Test by SD Biosensor^{23,24} and the Carestart™ G6PD Biosensor by AccessBio^{25,26} are commercially available. The suggested procedures above apply to all G6PD genotypes. Haemoglobin (Hb), Haematocrit (Hct)

and only females with intermediate G6PD activity. As above, supervised treatment further improves safety.

- In some areas, such as rural Myanmar, referral from remote health posts is not possible. In this situation, acceptable solutions are to prescribe the weekly primaquine regimen or perform point of care quantitative G6PD testing before prescribing a daily primaquine regimen and to supervise treatment in G6PD deficient or intermediate patients²⁷.

If a haemolytic complication is suspected, primaquine should be stopped. Patients should be referred as soon as possible to a facility where blood transfusion services are available. At higher levels of care, additional investigation can be done at the discretion of the health care provider (Figure 2). When discharged, it is important to counsel the G6PD deficient patient on their disease, risks for haemolysis, and drugs to avoid and to provide a 'G6PD deficiency card' translated to local languages that the patient can bring to future health care visits.

Conclusion

With increased use of unsupervised primaquine for the elimination of *P. vivax* malaria, G6PD deficient patients (a substantial proportion in many malaria endemic populations) may be exposed to haemolysis and potentially life-threatening anaemia. Ideally, health care providers at all health care levels should

counsel and/or supervise patients carefully on correct primaquine dosing to avoid accidental overdose and be watchful when administering primaquine. During haemolysis, a high suspicion of G6PD deficiency is needed. It is also important to look for other causes of haemolysis, such as infection and concomitant use of commonly prescribed potentially haemolytic drugs.

Data availability

All data underlying the results are available as part of the article and no additional source data are required.

Consent

Written informed consent for publication of the patients' details and images was obtained from the guardians of the patients.

Grant information

CSC, GB, and FN are part of the Wellcome Trust Mahidol University Oxford Tropical Medicine Research Programme funded by the Wellcome Trust.

The funders had no role in study design, data collection and analysis, decision to publish, or preparation of the manuscript.

Acknowledgements

We would like to thank the patients, their families and the clinical staff who cared for them. Thank you also to Professor Sir Nicholas J White for helpful comments on the manuscript.

References

1. Alving AS, Johnson CF, Tarlov AR, *et al.*: Mitigation of the haemolytic effect of primaquine and enhancement of its action against exoerythrocytic forms of the Chesson strain of *Plasmodium vivax* by intermittent regimens of drug administration: a preliminary report. *Bull World Health Organ.* 1960; **22**: 621–31. [PubMed Abstract](#) | [Free Full Text](#)
2. Leslie T, Mayan I, Mohammed N, *et al.*: A randomised trial of an eight-week, once weekly primaquine regimen to prevent relapse of *Plasmodium vivax* in Northwest Frontier Province, Pakistan. *PLoS One.* 2008; **3**(8): e2861. [PubMed Abstract](#) | [Publisher Full Text](#) | [Free Full Text](#)
3. Kheng S, Muth S, Taylor WR, *et al.*: Tolerability and safety of weekly primaquine against relapse of *Plasmodium vivax* in Cambodians with glucose-6-phosphate dehydrogenase deficiency. *BMC Med.* 2015; **13**: 203. [PubMed Abstract](#) | [Publisher Full Text](#) | [Free Full Text](#)
4. Monteiro WM, Franca GP, Melo GC, *et al.*: Clinical complications of G6PD deficiency in Latin American and Caribbean populations: systematic review and implications for malaria elimination programmes. *Malar J.* 2014; **13**: 70. [PubMed Abstract](#) | [Publisher Full Text](#) | [Free Full Text](#)
5. Burgoine KL, Bancone G, Nosten F: The reality of using primaquine. *Malar J.* 2010; **9**: 376. [PubMed Abstract](#) | [Publisher Full Text](#) | [Free Full Text](#)
6. Howes RE, Piel FB, Patil AP, *et al.*: G6PD deficiency prevalence and estimates of affected populations in malaria endemic countries: a geostatistical model-based map. *PLoS Med.* 2012; **9**(11): e1001339. [PubMed Abstract](#) | [Publisher Full Text](#) | [Free Full Text](#)
7. Nuchprayoon I, Sanpavat S, Nuchprayoon S: Glucose-6-phosphate dehydrogenase (G6PD) mutations in Thailand: G6PD Viangchan (871G>A) is the most common deficiency variant in the Thai population. *Hum Mutat.* 2002; **19**(2): 185. [PubMed Abstract](#) | [Publisher Full Text](#)
8. Laosombat V, Sattayasevana B, Janejindamai W, *et al.*: Molecular heterogeneity of glucose-6-phosphate dehydrogenase (G6PD) variants in the south of Thailand and identification of a novel variant (G6PD Songklanagarind). *Blood Cells Mol Dis.* 2005; **34**(2): 191–6. [PubMed Abstract](#) | [Publisher Full Text](#)
9. Matsuoka H, Wang J, Hirai M, *et al.*: Glucose-6-phosphate dehydrogenase (G6PD) mutations in Myanmar: G6PD Mahidol (487G>A) is the most common variant in the Myanmar population. *J Hum Genet.* 2004; **49**(10): 544–7. [PubMed Abstract](#) | [Publisher Full Text](#)
10. Bancone G, Chu CS, Somsakchaicharoen R, *et al.*: Characterization of G6PD genotypes and phenotypes on the northwestern Thailand-Myanmar border. *PLoS One.* 2014; **9**(12): e116063. [PubMed Abstract](#) | [Publisher Full Text](#) | [Free Full Text](#)
11. Bancone G, Chowwiwat N, Somsakchaicharoen R, *et al.*: Single Low Dose Primaquine (0.25 mg/kg) Does Not Cause Clinically Significant Haemolysis in G6PD Deficient Subjects. *PLoS One.* 2016; **11**(3): e0151898. [PubMed Abstract](#) | [Publisher Full Text](#) | [Free Full Text](#)
12. Brito-sousa JD, Santos TC, Avalos S, *et al.*: Clinical Spectrum of Primaquine-induced Hemolysis in G6PD Deficiency: A Nine-Year Hospitalization-Based Study from the Brazilian Amazon. *Clin Infect Dis.* 2019; **ciz122**. [PubMed Abstract](#) | [Publisher Full Text](#)
13. Rees DC, Kelsey H, Richards JD: Acute haemolysis induced by high dose ascorbic acid in glucose-6-phosphate dehydrogenase deficiency. *BMJ.* 1993; **306**(6881): 841–2. [PubMed Abstract](#) | [Publisher Full Text](#) | [Free Full Text](#)
14. Mehta JB, Singhal SB, Mehta BC: Ascorbic-acid-induced haemolysis in G-6-PD deficiency. *Lancet.* 1990; **336**(8720): 944. [PubMed Abstract](#)
15. Tarlov AR, Brewer GJ, Carson PE, *et al.*: Primaquine sensitivity. Glucose-6-phosphate dehydrogenase deficiency: an inborn error of metabolism of medical and biological significance. *Arch Intern Med.* 1962; **109**: 209–34. [PubMed Abstract](#) | [Publisher Full Text](#)
16. Monteiro WM, Moura-Neto JP, Recht J, *et al.*: Fatal Primaquine-Induced Hemolysis in a Patient With *Plasmodium vivax* Malaria and G6PD A(-) Variant in the Brazilian Amazon. *Clin Infect Dis.* 2016; **62**(9): 1188. [PubMed Abstract](#) | [Publisher Full Text](#)
17. World Health Organization: Guidelines for the treatment of malaria. 3rd Edition. Geneva: World Health Organization; 2015. [Reference Source](#)
18. Ramos Júnior WM, Sardinha JF, Costa MR, *et al.*: Clinical aspects of hemolysis in patients with *P. vivax* malaria treated with primaquine, in the Brazilian Amazon. *Braz J Infect Dis.* 2010; **14**(4): 410–2. [PubMed Abstract](#) | [Publisher Full Text](#)
19. Brewer GJ, Tarlov AR, Kellermeier RW, *et al.*: The hemolytic effect of primaquine. XV. Role of methemoglobin. *J Lab Clin Med.* 1962; **59**: 905–17. [PubMed Abstract](#)
20. Wu S, Wu G, Wu H: Hemolytic jaundice induced by pharmacological dose ascorbic acid in glucose-6-phosphate dehydrogenase deficiency: A case report. *Medicine (Baltimore).* 2018; **97**(51): e13588. [PubMed Abstract](#) | [Publisher Full Text](#) | [Free Full Text](#)
21. Pootrakul P, Sirankapracha P, Hemsorach S, *et al.*: A correlation of erythrokinetics, ineffective erythropoiesis, and erythroid precursor apoptosis in Thai patients with thalassemia. *Blood.* 2000; **96**(7): 2606–12. [PubMed Abstract](#)
22. Dern RJ, Beutler E, Alving AS: The hemolytic effect of primaquine. II. The natural course of the hemolytic anemia and the mechanism of its self-limited character. *J Lab Clin Med.* 1954; **44**(2): 171–6. [PubMed Abstract](#)
23. Alam MS, Kibria MG, Jahan N, *et al.*: Field evaluation of quantitative point of care diagnostics to measure glucose-6-phosphate dehydrogenase activity. *PLoS One.* 2018; **13**(11): e0206331. [PubMed Abstract](#) | [Publisher Full Text](#) | [Free Full Text](#)
24. Pal S, Bansil P, Bancone G, *et al.*: Evaluation of a Novel Quantitative Test for Glucose-6-Phosphate Dehydrogenase Deficiency: Bringing Quantitative Testing for Glucose-6-Phosphate Dehydrogenase Deficiency Closer to the Patient. *Am J Trop Med Hyg.* 2019; **100**(1): 213–221. [PubMed Abstract](#) | [Publisher Full Text](#) | [Free Full Text](#)
25. Weppelmann TA, von Fricken ME, Wilfong TD, *et al.*: Field Trial of the CareStart Biosensor Analyzer for the Determination of Glucose-6-Phosphate Dehydrogenase Activity in Haiti. *Am J Trop Med Hyg.* 2017; **97**(4): 1262–70. [PubMed Abstract](#) | [Publisher Full Text](#) | [Free Full Text](#)
26. Bancone G, Gornsawun G, Chu CS, *et al.*: Validation of the quantitative point-of-care CareStart biosensor for assessment of G6PD activity in venous blood. *PLoS One.* 2018; **13**(5): e0196716. [PubMed Abstract](#) | [Publisher Full Text](#) | [Free Full Text](#)
27. Chu CS, Bancone G, Moore KA, *et al.*: Haemolysis in G6PD Heterozygous Females Treated with Primaquine for *Plasmodium vivax* Malaria: A Nested Cohort in a Trial of Radical Curative Regimens. *PLoS Med.* 2017; **14**(2): e1002224. [PubMed Abstract](#) | [Publisher Full Text](#) | [Free Full Text](#)

Open Peer Review

Current Referee Status:  

Version 2

Referee Report 17 April 2019

<https://doi.org/10.21956/wellcomeopenres.16616.r35270>



Wuelton M. Monteiro

Escola Superior de Ciências da Saúde, Universidade do Estado do Amazonas, Manaus, Brazil

I have read this version and believe that it can be accepted as it is.

Competing Interests: No competing interests were disclosed.

I have read this submission. I believe that I have an appropriate level of expertise to confirm that it is of an acceptable scientific standard.

Referee Report 16 April 2019

<https://doi.org/10.21956/wellcomeopenres.16616.r35271>



Larry A. Walker 

The National Center for Natural Products Research, School of Pharmacy, University of Mississippi, Mississippi, MS, USA

I appreciate the authors' responses, and I believe the revisions clarify and add to the paper's impact.

Competing Interests: No competing interests were disclosed.

Reviewer Expertise: pharmacology, antimalarial drug metabolism, primaquine toxicity

I have read this submission. I believe that I have an appropriate level of expertise to confirm that it is of an acceptable scientific standard.

Version 1

Referee Report 07 March 2019

<https://doi.org/10.21956/wellcomeopenres.16474.r34852>



Wuelton M. Monteiro

Escola Superior de Ciências da Saúde, Universidade do Estado do Amazonas, Manaus, Brazil

In this manuscript, the authors describe primaquine-induced haemolysis in two G6PD Mahidol hemizygous males. Some considerations:

1. The description of cases of primaquine-induced hemolysis is not properly an original subject. What is lacking in the literature today is the knowledge of estimates of clinically relevant hemolysis among primaquine users, obtained through pharmacovigilance studies. Thus, in the introduction and discussion of the manuscript, I miss references and comparison with other series of cases of primaquine-induced hemolysis, including estimates of the primaquine-induced hemolysis rate among drug users. See: Recht *et al.* (2014¹), Monteiro *et al.* (2014²) and Brito-Sousa *et al.* (2019³).
2. Genetic variants associated to PQ-induced hemolysis are a matter of debate. Thus, include a discussion of those variants, whose presence may result in dangerous or even potentially life-threatening hemolysis, including now Mahidol. See: Recht *et al.* (2014¹) and Monteiro *et al.* (2016⁴).
3. The 8-week course of PQ under supervision was indicated as the possible alternative radical cure treatment for these cases, but no further information on the outcome was presented. Was it employed? Was it safety checked?

References

1. Recht J, Ashley E, White N: Safety of 8-aminoquinoline antimalarial medicines. *World Health Organization*. 2014. [Reference Source](#)
2. Monteiro WM, Franca GP, Melo GC, Queiroz AL, Brito M, Peixoto HM, Oliveira MR, Romero GA, Bassat Q, Lacerda MV: Clinical complications of G6PD deficiency in Latin American and Caribbean populations: systematic review and implications for malaria elimination programmes. *Malar J*. 2014; **13**: 70 [PubMed Abstract](#) | [Publisher Full Text](#)
3. Brito-Sousa JD, Santos TC, Avalos S, Fontecha G, Melo GC, Val F, Siqueira AM, Alecrim GC, Bassat Q, Lacerda MVG, Monteiro WM: Clinical Spectrum of Primaquine-induced Hemolysis in G6PD Deficiency: A Nine-Year Hospitalization-Based Study from the Brazilian Amazon. *Clin Infect Dis*. 2019. [PubMed Abstract](#) | [Publisher Full Text](#)
4. Monteiro W, Moura-Neto J, Recht J, Bassat Q, Lacerda M: Fatal Primaquine-Induced Hemolysis in a Patient With *Plasmodium vivax* Malaria and G6PD A(-) Variant in the Brazilian Amazon. *Clinical Infectious Diseases*. 2016; **62** (9): 1188.1-1188 [Publisher Full Text](#)

Is the background of the cases' history and progression described in sufficient detail?

Partly

Is the background of the cases' history and progression described in sufficient detail?

Partly

Are enough details provided of any physical examination and diagnostic tests, treatment given and outcomes?

Partly

Are enough details provided of any physical examination and diagnostic tests, treatment given and outcomes?

Partly

Is sufficient discussion included of the importance of the findings and their relevance to future understanding of disease processes, diagnosis or treatment?

Yes

Is sufficient discussion included of the importance of the findings and their relevance to future understanding of disease processes, diagnosis or treatment?

Yes

Is the conclusion balanced and justified on the basis of the findings?

Yes

Is the conclusion balanced and justified on the basis of the findings?

Yes

Competing Interests: No competing interests were disclosed.

Reviewer Expertise: Epidemiology

I have read this submission. I believe that I have an appropriate level of expertise to confirm that it is of an acceptable scientific standard, however I have significant reservations, as outlined above.

Author Response 02 Apr 2019

Cindy Chu, Faculty of Tropical Medicine, Shoklo Malaria Research Unit, Mahidol University, Thailand

We would like to thank Reviewer 2 for suggesting further references and providing comments that initiate further contemplation on this manuscript in the public domain.

1. *The description of cases of primaquine-induced hemolysis is not properly an original subject. What is lacking in the literature today is the knowledge of estimates of clinically relevant hemolysis among primaquine users, obtained through pharmacovigilance studies. Thus, in the introduction and discussion of the manuscript, I miss references and comparison with other series of cases of primaquine-induced hemolysis, including estimates of the primaquine-induced hemolysis rate among drug users. See: Recht et al.(2014¹), Monteiro et al.(2014²) and Brito-Sousa et al.(2019³).*

RESPONSE: This case series focuses on the haemolysis caused by patients taking unsupervised primaquine incorrectly. But as Reviewer 2 points out, G6PD deficient patients taking daily primaquine (presumably as prescribed) are also at risk for hemolysis. To raise this issue in the manuscript two changes have been made. The last sentence of the second paragraph in the introduction has been amended to "This means that undiagnosed G6PD deficient patients have the potential to develop primaquine induced haemolysis, especially with *daily* regimens." A reference suggested by the reviewer has been added. The last sentence at the end of the first paragraph of the discussion has amended to highlight the risk of mortality in these patients. "In both cases haemolysis was exacerbated, by concomitant illnessand both cases also had the potential to

be fatal." A reference suggested by the reviewer has been added.

2. *Genetic variants associated to PQ-induced hemolysis are a matter of debate. Thus, include a discussion of those variants, whose presence may result in dangerous or even potentially life-threatening hemolysis, including now Mahidol. See: Recht et al. (2014¹) and Monteiro et al. (2016⁴).*

RESPONSE: This comment raises a few thoughts. Firstly, there is very little known about the associated PQ-induced haemolytic risk in the vast majority of G6PD variants. Primaquine challenge clinical trials in the past were mainly carried out in hemizygous A- subjects (Tarlov *et al.*, 1962) and rarely in subjects from Sardinia, presumably with Mediterranean variant (Pannacciulli, 1965). In the last few years, clinical trials have been carried out in subjects with Mahidol variant, but data come from treatment in heterozygous women with normal phenotype by FST. Secondly, some variants such as Mahidol and African A-, are described as 'mild' based on the WHO classification. The data informing the WHO classification are based on small numbers of analyzed subjects (sometimes just one per variant) often poorly characterized (genotyping in pre-PCR era, non-standardized biochemical and enzymatic analysis), and cannot be used to indicate the associated hemolytic risk. This means that the evidence available to date on G6PD variants, described as 'mild' by the WHO classification, in fact show that hemolysis does occur and is life threatening. As much as we would like to include a discussion on this important complicated topic in the manuscript, it is not the main point of the manuscript. The recommendations in the discussion apply to all genotypes and no differentiation is made. However, to improve clarity, we have added a footnote to Figure 2 that states "*The suggested procedures above apply to all G6PD genotypes*".

3. *The 8-week course of PQ under supervision was indicated as the possible alternative radical cure treatment for these cases, but no further information on the outcome was presented. Was it employed? Was it safety checked?*

RESPONSE: We have added the outcome to the case presentations. In both cases weekly primaquine was not given because the close medical supervision was not possible.

Is the background of the cases' history and progression described in sufficient detail?

Partly.

RESPONSE: We have added more detail to the cases to address the reviewer comment on case history and progression.

Are enough details provided of any physical examination and diagnostic tests, treatment given and outcomes? Partly.

RESPONSE: We have added to the manuscript an explanation of the patient outcomes.

Competing Interests: The authors declare no competing interests.

Referee Report 01 March 2019

<https://doi.org/10.21956/wellcomeopenres.16474.r34850>



Larry A. Walker

The National Center for Natural Products Research, School of Pharmacy, University of Mississippi, Mississippi, MS, USA

The authors present two cases which further illustrate the dangers of using PQ in populations where G6PD status is unknown, especially in unsupervised treatment settings. These two reports convey details that emphasize the complexity of the problems of hemolysis etiology, treatment and recovery, as encountered by practitioners in malaria endemic countries. In particular, both patients took PQ incorrectly due to poor understanding of instructions. But the laboratory findings and recovery course were complicated by other medications, concurrent illness, and timing of presentation to the clinic. The authors have done an excellent job of framing the history and clinical details, and then interpreting these in their relevance to current knowledge and implications for future utilization of PQ. They rightly point out the urgent need for better training of health workers in recognizing possible PQ-induced hemolysis, and in specific instruction of patients regarding the importance of strict adherence to the drug regimen; this should entail careful attention to literacy and language barriers, which seemed to be limiting in these cases.

I have the following comments regarding the article:

1. The authors have pointed out the constraints of relying on G6PD activity tests for diagnosing G6PD deficiency after a hemolytic episode has already ensued. But it seems worthwhile to clarify this in the recommendations (in the discussion on Figure 2), which might be construed as employing the qualitative tests “in any patient with a haemoglobin or haematocrit reduction following primaquine or any other haemolytic drug” in the prior sentence. This might be misunderstood by casual readers.
2. Regarding the time course of the recovery in hemoglobin, mentioned in paragraph two of the Discussion, some further development on this issue would be helpful. The authors state, “During treatment with primaquine (a rapidly eliminated oxidative drug) in G6PD abnormal patients, the haematocrit is expected to stabilize or rise the following day after the drug has been stopped.¹⁴” This reference is the WHO Guidelines, but I wonder if this quick recovery has a solid basis in clinical evidence. While evidence has suggested the “self-limiting” character of the hemoglobin drop, and even recovery with continued dosing (a “resistance phase”, article reference 19), I wonder if these would be expected so rapidly. In Rueangweerayut *et al.* (2017¹) the modest drop in hemoglobin with 14d PQ dosing in heterozygous Mahidol females was sustained for the 14 days dosing, though recovered by 21 days. The data from Kheng *et al.* (article reference 3), suggest that after a single 45 mg dose of PQ in Viangchan deficient, the decline in hemoglobin was seen on day 1 and sustained for a week – though it did recover during subsequent weekly doses. It seems like the recovery picture may be an interplay between the oxidative stress insult (due to continued drug dosing or to persistent metabolite(s) recycling?) and the erythropoietic recovery mechanism. I may be off base, but I think it would be of interest to have the authors’ perspectives on these.
3. Further to time course issues, the development of the hemolytic response in these two cases is perhaps worthy of note. Though the regimens prescribed were presumably different, the patients took 30 mg/day for 4 days (case 1) and 30mg/day for 2 days and 60 mg on the third day (case 2), when they developed serious symptoms. This, along with other studies, suggests that it takes 2-3 days for the hemolytic clinical picture to fully develop after dosing. In Rueangweerayut *et al.* (2017¹), with 15 mg/d it took 3-4 days to elicit a hemoglobin drop. But with the higher weekly dose of 45 mg in the Cambodian study, a drop in hemoglobin was observed on the first day (article reference 3). Since neither the drop in hemoglobin, nor the recovery, are related to the parent drug, it might again suggest some persistent insult from a red cell metabolite recycling. Or perhaps there is some lag time in the development of the hemolytic picture because of other dynamics to reach the clinically severe stages? The authors’ insights here, if any, might be useful.

4. The apparent intravascular hemolysis observed here is perhaps worthy of note. How often is this apparent in such cases? In some of the animal studies, and in a number of case reports, there appears to be erythrocyte damage and clearance without intravascular hemolysis. Is this perhaps related to severity of deficiency in G6PD activity?
5. In the first paragraph of the discussion, the last sentence appears to be incorrectly worded. I am perhaps unfamiliar with this use of “mediation”. Or perhaps it should be “and another haemolytic medication”? Also, do these references (article references 3 and 13) support the last sentence, or the one prior?

References

1. Rueangweerayut R, Bancone G, Harrell EJ, Beelen AP, Kongpatanakul S, Möhrle JJ, Rousell V, Mohamed K, Qureshi A, Narayan S, Yubon N, Miller A, Nosten FH, Luzzatto L, Duparc S, Kleim JP, Green JA: Hemolytic Potential of Tafenoquine in Female Volunteers Heterozygous for Glucose-6-Phosphate Dehydrogenase (G6PD) Deficiency (G6PD Mahidol Variant) versus G6PD-Normal Volunteers. *Am J Trop Med Hyg.* 2017; **97** (3): 702-711 [PubMed Abstract](#) | [Publisher Full Text](#)

Is the background of the cases' history and progression described in sufficient detail?

Yes

Is the background of the cases' history and progression described in sufficient detail?

Yes

Are enough details provided of any physical examination and diagnostic tests, treatment given and outcomes?

Yes

Are enough details provided of any physical examination and diagnostic tests, treatment given and outcomes?

Yes

Is sufficient discussion included of the importance of the findings and their relevance to future understanding of disease processes, diagnosis or treatment?

Yes

Is sufficient discussion included of the importance of the findings and their relevance to future understanding of disease processes, diagnosis or treatment?

Yes

Is the conclusion balanced and justified on the basis of the findings?

Yes

Is the conclusion balanced and justified on the basis of the findings?

Yes

Competing Interests: No competing interests were disclosed.

Reviewer Expertise: pharmacology, antimalarial drug metabolism, primaquine toxicity

I have read this submission. I believe that I have an appropriate level of expertise to confirm that it is of an acceptable scientific standard, however I have significant reservations, as outlined above.

Author Response 02 Apr 2019

Cindy Chu, Faculty of Tropical Medicine, Shoklo Malaria Research Unit, Mahidol University, Thailand

We would like to thank Reviewer 1 for comments and dialogue on this manuscript in the public domain.

1. *The authors have pointed out the constraints of relying on G6PD activity tests for diagnosing G6PD deficiency after a hemolytic episode has already ensued. But it seems worthwhile to clarify this in the recommendations (in the discussion on Figure 2), which might be construed as employing the qualitative tests “in any patient with a haemoglobin or haematocrit reduction following primaquine or any other haemolytic drug” in the prior sentence. This might be misunderstood by casual readers.*

RESPONSE: The transition of this paragraph was amended to separate the idea of constraints of relying on G6PD tests after a hemolytic episode and how to improve the safety of prescribing primaquine. A new paragraph was inserted and the opening sentence of the new paragraph was clarified to read “To promote safe primaquine prescription for *P. vivax*,”

2. *Regarding the time course of the recovery in hemoglobin, mentioned in paragraph two of the Discussion, some further development on this issue would be helpful. The authors state, “During treatment with primaquine (a rapidly eliminated oxidative drug) in G6PD abnormal patients, the haematocrit is expected to stabilize or rise the following day after the drug has been stopped.¹⁴” This reference is the WHO Guidelines, but I wonder if this quick recovery has a solid basis in clinical evidence. While evidence has suggested the “self-limiting” character of the hemoglobin drop, and even recovery with continued dosing (a “resistance phase”, article reference 19), I wonder if these would be expected so rapidly. In Rueangweerayut et al. (2017) the modest drop in hemoglobin with 14d PQ dosing in heterozygous Mahidol females was sustained for the 14 days dosing, though recovered by 21 days. The data from Kheng et al. (article reference 3), suggest that after a single 45 mg dose of PQ in Viangchan deficient, the decline in hemoglobin was seen on day 1 and sustained for a week – though it did recover during subsequent weekly doses. It seems like the recovery picture may be an interplay between the oxidative stress insult (due to continued drug dosing or to persistent metabolite(s) recycling?) and the erythropoietic recovery mechanism. I may be off base, but I think it would be of interest to have the authors’ perspectives on these.*

RESPONSE: This comment raises 2 important questions. The first is about the attenuation of the haemolysis in G6PD deficient individuals despite continuing primaquine and the second is about hematologic recovery. We can share our thoughts and clinical experiences:

Question 1: There is little literature on acute hemolysis during weekly primaquine treatment in G6PD deficient cohorts and even less in those who inadvertently were administered daily doses. Historical data in certain G6PD deficient individuals show that when primaquine doses are continued, the hemolysis becomes self-limited and haematocrit will rise, presumably due to increased reticulocyte production and a younger RBC population (G6PD activity is higher in reticulocytes). Additionally, in Rueangweerayut et al. (2017) and Chu et al. (2016), G6PD

heterozygous females who were diagnosed as G6PD normal on a qualitative test demonstrated that haemoglobin recovery begins around day 7 despite continued primaquine dosing. Though, it does take more time to reach full recovery.

Question 2: In our clinical experience with *P. vivax* patients, when hemolysis with severe anemia occurs and primaquine is stopped immediately (usually between days 3-6 after the first dose), we see the hematocrit rise in the following few days (along with a rise in reticulocytes). We do not have the experience of stopping primaquine at days 0-2 after the first dose when the reticulocyte response may not yet have increased sufficiently enough for a large effect on the RBC population. Our thoughts are that the recovery picture is related to the physiologic (erythropoietic) response of the individual and concomitant diseases that individual may have (i.e. concurrent illness, hemoglobinopathies). Moreover, the G6PD activity in reticulocytes has been shown to be normal in Mahidol reticulocytes (Bancone, 2017) and is presumably so in the A- variant, while it is expected to be already compromised in mutations such as Mediterranean (Piomelli, 1958). This would affect haematologic recovery even if the reticulocyte response is adequate. Further data on primaquine metabolism may add to these assumptions. To clarify this issue in the manuscript, we have amended a sentence in the second paragraph of the discussion to read "During treatment with primaquine (a rapidly eliminated oxidative drug) in G6PD abnormal patients whose enzymatic activity is not compromised yet in reticulocytes, the hematocrit is expected to stabilize or rise the following day after the drug has been stopped *given an adequate reticulocyte response.*" We do not have other references aside from our unpublished clinical experience and thus will continue using the WHO reference.

3. *Further to time course issues, the development of the hemolytic response in these two cases is perhaps worthy of note. Though the regimens prescribed were presumably different, the patients took 30 mg/day for 4 days (case 1) and 30mg/day for 2 days and 60 mg on the third day (case 2), when they developed serious symptoms. This, along with other studies, suggests that it takes 2-3 days for the hemolytic clinical picture to fully develop after dosing. In Rueangweerayut et al. (2017¹), with 15 mg/d it took 3-4 days to elicit a hemoglobin drop. But with the higher weekly dose of 45 mg in the Cambodian study, a drop in hemoglobin was observed on the first day (article reference 3). Since neither the drop in hemoglobin, nor the recovery, are related to the parent drug, it might again suggest some persistent insult from a red cell metabolite recycling. Or perhaps there is some lag time in the development of the hemolytic picture because of other dynamics to reach the clinically severe stages? The authors' insights here, if any, might be useful.*

RESPONSE: This question is in regard to the development of hemolysis while on an 8-aminoquinoline. In Rueangweerayut et al. (2017) single dose tafenoquine was used in some G6PD intermediate healthy subjects whereas in Kheng et al. (2015) primaquine weekly dose was used in G6PD deficient patients with *P. vivax* infection. Peak concentrations of primaquine are reached ~3 hours after dosing whereas peak concentrations of tafenoquine are reached at ~20 hours. The time to development of the full hemolytic picture in these studies may be affected by *P. vivax* infection, G6PD activity (greater proportion of older and deficient cells in deficient subjects so hemolysis occurs earlier), and drug concentrations. Of course, we do not have enough knowledge of primaquine or tafenoquine metabolism to know if there are active metabolites that are recycled and cause prolonged oxidative effects.

4. *The apparent intravascular hemolysis observed here is perhaps worthy of note. How often is this apparent in such cases? In some of the animal studies, and in a number of case reports, there appears to be erythrocyte damage and clearance without intravascular hemolysis. Is this perhaps related to severity of deficiency in G6PD activity?*

RESPONSE: It is very difficult to answer this question; cases of evident haemoglobinuria are

usually reported while increased levels of bilirubin or free hemoglobin in blood can be detected almost only by specific laboratory investigations. As suggested in Luzzatto & Seneca (2014), 8-aminoquinoline-induced hemolysis is both intravascular and extravascular, with the former happening in more severely affected RBCs and the latter in less damaged RBCs. We do not know whether this might be related to the severity of enzymatic deficiency.

5. *In the first paragraph of the discussion, the last sentence appears to be incorrectly worded. I am perhaps unfamiliar with this use of “mediation”. Or perhaps it should be “and another haemolytic medication”? Also, do these references (article references 3 and 13) support the last sentence, or the one prior?*

RESPONSE: The word ‘mediation’ has been corrected to ‘medication’. In reference 3, a G6PD deficient male who received 45 mg primaquine developed severe anaemia requiring a blood transfusion. He had also received Ciprofloxacin (a hemolytic agent), which would support the idea that haemolysis could be exacerbated by concomitant drugs in addition to an 8-aminoquinoline. There are case reports of large doses of Vitamin C causing haemolysis but not in a normal dose concomitantly with another haemolytic agent. We have added a reference (Monteiro *et al.*, 2016) that further supports these sentences.

Competing Interests: The authors have no competing interests to declare.
