

Brief report

Optical coherence tomography angiography in best vitelliform macular dystrophy

Ahmad Mirshahi^a, Alireza Lashay^a, Ahmad Masoumi^a, Mojtaba Abrishami^{b,*}

^a Eye Research Center, Farabi Eye Hospital, Tehran University of Medical Sciences, Tehran, Iran

^b Eye Research Center, Mashhad University of Medical Sciences, Mashhad, Iran

Received 18 January 2019; revised 7 June 2019; accepted 29 June 2019

Available online 16 July 2019

Abstract

Purpose: To report best vitelliform macular dystrophy (BVMD) with an intriguing pattern of vascular flow on optical coherence tomography angiography (OCTA).

Methods: Four eyes of two patients with BVMD were evaluated. Complete ophthalmic examination including best corrected visual acuity (BCVA), spectral domain optical coherence tomography (SD-OCT), and OCTA were performed. Diagnosis was confirmed by electroretinography (ERG) and electrooculography (EOG) testing.

Results: All eyes had the electrophysiologic confirmation of the BVMD. The first patient was 35 years old with BCVA of 20/20 and pseudohypopyon stage macular lesion in right eye (RE) and BCVA of 20/32 and vitelliruptive stage macular lesion in the left eye (LE). The second patient was 18 years old with BCVA of 20/25 and macular lesion in vitelliform stage in the RE and BCVA of 20/60 and choroidal neovascularization (CNV) in the LE. In all eyes, a distinct foveal avascular zone (FAZ) was not detectable in OCTA, with a bridging vessel in the FAZ. A dense subretinal capillary network compatible with CNV in the LE of second patient was observed.

Conclusion: In our cases, we found bridging vessel in the FAZ, and it may be due to the effects of bestrophin on the calcium content and vascular endothelial growth factor (VEGF) secretion of the retinal pigment epithelium (RPE) cells.

Copyright © 2019, Iranian Society of Ophthalmology. Production and hosting by Elsevier B.V. This is an open access article under the CC BY-NC-ND license (<http://creativecommons.org/licenses/by-nc-nd/4.0/>).

Keywords: Best vitelliform macular dystrophy; Optical coherence tomography angiography; Choroidal neovascularization; Bridging vessel; Foveal avascular zone

Introduction

Best vitelliform macular dystrophy (BVMD) is a slowly progressive macular dystrophy with an autosomal dominant inheritance pattern. The disease is characterized by accumulation of subretinal deposits in the macula.¹ In advanced stages

of the disease, the macula becomes atrophic, or choroidal neovascularization (CNV) may ensue, leading to visual loss.² Historically, electroretinography (ERG) and electrooculography (EOG) have been used to confirm the diagnosis of BVMD. EOG reveals a reduced light peak-dark trough (Arden) ratio in patients with BVMD.³

This study has been presented in the Fifth International OCT Angiography and “En Face” OCT Congress - Rome, December, 2017, as an oral presentation.

Financial disclosure: No author has a financial or proprietary interest in any material or method mentioned.

Conflicts of interest: The authors declare that they have no competing interests.

Funding: The authors received no funding. It is the authors' own work, not funded by government or academics institutes.

* Corresponding author. Khatam-al-Anbia Eye Hospital, Eye Research Center, Mashhad University of Medical Sciences, Qarani Blvd., Mashhad, 9195965919, Iran.

E-mail address: mojtaba_abrishami@yahoo.com (M. Abrishami).

Peer review under responsibility of the Iranian Society of Ophthalmology.

<https://doi.org/10.1016/j.joco.2019.06.005>

2452-2325/Copyright © 2019, Iranian Society of Ophthalmology. Production and hosting by Elsevier B.V. This is an open access article under the CC BY-NC-ND license (<http://creativecommons.org/licenses/by-nc-nd/4.0/>).

Optical coherence tomography angiography (OCTA) has shown great promise for noninvasive mapping of retinal vasculature at the microcirculation level by using the blood flow characteristics of the retina. This new technique has been superior in many instances like in detecting retinal neovascularization and evaluating the foveal avascular zone (FAZ) compared to older imaging modalities like fluorescein angiography (FA).⁴ However, this method is less used to evaluate macular dystrophies and mostly in evaluation of CNV treatment of BVMD.⁵

Here, we describe two cases of BVMD with OCTA findings of the macula. In our cases, we found striking vessels in the fovea.

Methods

This study is an observational case series of patients with BVMD conducted at a tertiary referral ophthalmology center, Farabi Eye Hospital, Tehran, Iran. All patients underwent routine eye examination including best corrected visual acuity (BCVA), slit-lamp examination, and fundus examination. Macular lesions were classified according to a scheme developed by Gass.⁶ BVMD was diagnosed by considering fundus appearance and EOG findings. A reduction in the light peak to dark trough ratio (Arden ratio) of less than 1.5 was considered diagnostic of BVMD.

Spectral domain optical coherence tomography (SD-OCT) (Spectralis; Heidelberg Engineering, Heidelberg, Germany), ERG and EOG (Vision Monitor, Métrovision, France) were performed.

OCTA was performed for all patients to evaluate blood flow characteristics. The instrument used for OCTA images, AngioVue, is based on the Optovue RTVue XR Avanti technology to obtain amplitude decorrelation angiography images.

The study and its data acquisitions all were approved by the Ethical Committee of Research Deputy of Farabi Eye Hospital, Tehran University of Medical Sciences, Tehran, Iran. Patients were enrolled after providing written informed consent, in compliance with the Declaration of Helsinki.

Results

Two cases were included. In both patients, clinical and optical coherence tomography (OCT) findings were confirmed by ERG and Arden ration of EOG.

Case 1

The first patient was 35 years old with a 7-month history of decreased vision in his left eye (LE). BCVA was 20/20 and pseudohypopyon stage macular lesion in the right eye (RE) and BCVA of 20/32 and vitelliruptive stage macular lesion in the LE. (Fig. 1). EOG showed that the Arden ratio was 1.24 in the RE and 1.16 in the LE.

Case 2

The second patient was 18 years old and reported a 1-week history of decreased vision in her LE. BCVA was 20/25 in the RE and 20/60 in the LE. A macular lesion at the vitelliform

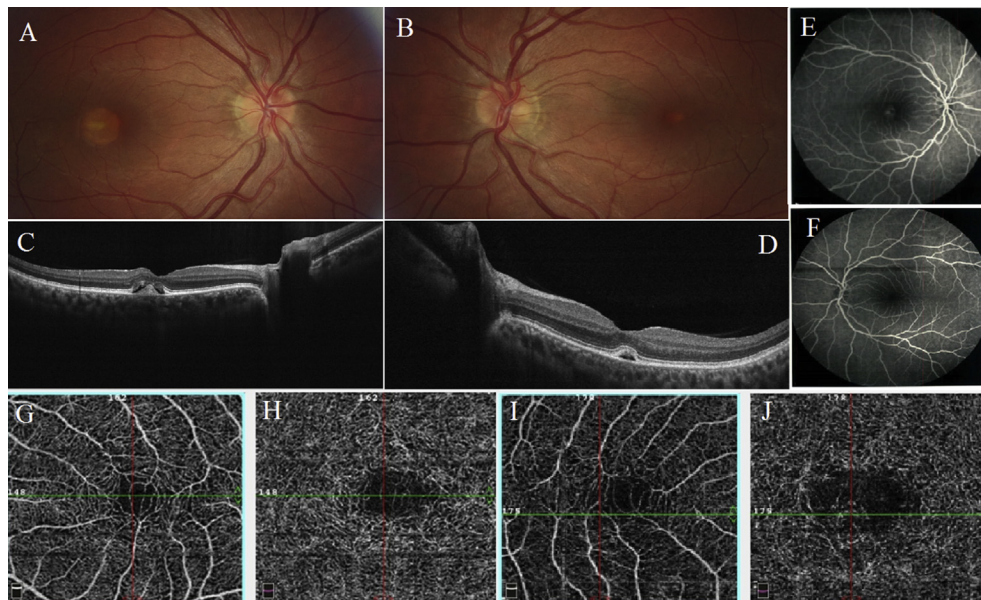


Fig. 1. Clinical findings and imaging studies of case #1. Fundus photo of the right eye (RE) (A), demonstrating a vitelliform lesion in the macula. Similar findings were observed in the left eye (LE) (B), images obtained by RT-VUE XR Avanti OCT show hyper-reflective material in the subretinal space in the RE (C), a hypo-reflective area is also observed in the LE (D), corresponding fluorescein angiography (FA) of the right (E), and LE (F), showing hyperfluorescence in the early phase frames of the RE which is consistent with staining of vitelliform lesion. Optical coherence tomography angiography (OCTA) of the RE shows bridging vessels in the superficial capillary plexus (SCP) (G), and deep capillary plexus (DCP) (H), the findings in the DCP could be projection artifact of the ones of the superficial layer. The bridging vessels are also observed in the OCTA of the LE (I, J).

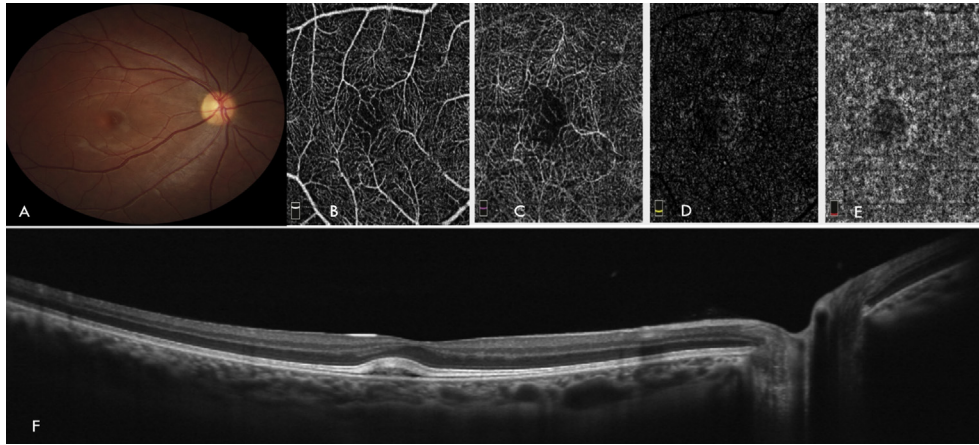


Fig. 2. Clinical findings and imaging studies of case #2 in the right eye (RE). A vitelliform lesion is observed in the macula (A), images obtained by RT-VUE XR Avanti OCT with AngioVue (3×3 mm) at the level of superficial capillary plexus (SCP) (B), deep capillary plexus (DCP) (C), outer retina (D) and choroid (E), based on the default segmentation of the system, shows bridging vessels at SCP and DCP. Optical coherence tomography (OCT) of the RE (F) shows a hyporeflective area in the subretinal space.

stage in the RE (Fig. 2) and subretinal fluid with a small amount of hemorrhage superior to the fovea, compatible of CNV, in the LE was seen. SD-OCT revealed intra and subretinal fluid with involvement of the subfoveal region (Fig. 3). EOG showed an Arden ratio of 1.08 in the RE and 1.17 in the LE. Intravitreal bevacizumab was injected two times, with an interval of 4 weeks. Exudate and intraretinal fluid were resolved 3 months after the first visit.

Optical coherence tomography angiography findings

Images captured with the RT-VUE OCTA system revealed a high-flow structure compatible with a capillary plexus passed through the FAZ in both the superficial and deep layers

of the retinal vasculature (Figs. 1 and 2). These vessels did not have any features of CNV, no branching, no straightening and not connected to straight vessels, and were in the superficial layers which exclude CNV. These vessels did not connect to any straight vessel.

Discussion

Before identification of the BEST1 gene, the pathogenesis of BVMD was a matter of debate.^{3,4} The BEST1 gene encodes the protein bestrophin, which plays important roles in ionic transport within retinal pigment epithelium (RPE) cells, regulation of phagocytosis and lysosomal function.^{7–9} Moreover, it has been proposed that RPE secretion of vascular

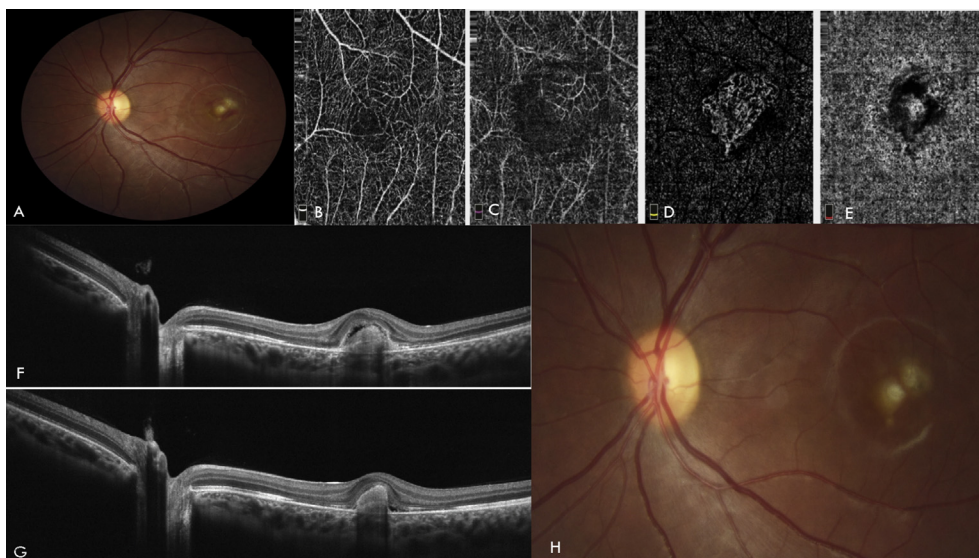


Fig. 3. Clinical findings and imaging studies of case #2 in the left eye (LE). Fundus photo demonstrates the presence of choroidal neovascularization (CNV) with subretinal edema and hemorrhage in the macula (A), images obtained by RT-VUE XR Avanti OCT with AngioVue (3×3 mm) at the level of superficial capillary plexus (SCP) (B), deep capillary plexus (DCP) (C), outer retina (D), and choroid (E), shows branching vessel in macula in SCP and also small caliber vessels consistent with the diagnosis of CNV in the outer retina of OCT (F, G), shows hyper-reflective material in the subretinal pigment epithelium (sub-RPE) space, elevating the neurosensory retina. Fundus photo of the LE after two-session intravitreal injection of bevacizumab, subretinal hemorrhage resolved (H).

endothelial growth factor (VEGF) may be controlled by bestrophin.^{6,10} In OCT of patients with BVMD, subretinal deposits and retinal layers changes can be observed, and in cases with CNV, subretinal and intraretinal fluid and hemorrhages will be observed.² However, until recently, no report was available about the findings of OCTA in BVMD. In this report, we present the intriguing bridging vessel in the macula.

In our patients, OCTA revealed an intriguing vascular flow pattern of bridging vessels across the FAZ, a capillary plexus in an area that is mostly considered avascular. This effect may be due to a defect of bestrophin and its effect on intracellular calcium content. These changes may explain why BVMD patients are prone to CNV. We believe that low doses of VEGF or other mediators in these cases induce vascular changes as a vessel in an avascular zone. As a growth factor, abnormal high doses of VEGF are pathologic while low doses are essential for angiogenesis and vascular remodeling.¹¹ Previously, bridging vessels have already been reported using FA, especially in the patients with a history of prematurity with related complications including retinopathy of prematurity.¹² Recently, using OCTA, macular-foveal capillaries have also been demonstrated by Cicinelli et al. in eyes with age-related macular degeneration and branch retinal artery occlusion.¹³ In all of the above-mentioned vascular disorders, VEGF has an essential role in the disease process. It seems that VEGF may have a crucial role in inducing vasculogenesis in avascular areas of FAZ in cases with pathologic RPE changes and retinal vascular diseases that involve area far from FAZ.

Previously, different diseases were found to have vascularized FAZ. Fovea plana and children with a history of preterm birth were reported to have vascularized FAZ, or the FAZ was absent.^{14,15} In a case series on 22 eyes of 14 patients with vascularized FAZ using OCTA, FAZ evaluation was performed in vascular layers of the retina, superficial and deep, and the degree of foveal pit hypoplasia was graded. They found absent FAZ in 21 out of 22 eyes at the superficial capillary plexus (SCP) and in eight out of 22 eyes at the deep capillary plexus (DCP). The severity of foveal pit hypoplasia was associated with the full vascularization of both the SCP and DCP. They also found that the absence of the FAZ did not affect visual acuity.¹⁶

More than bridging vessel founded in all cases, in the LE of case #2, OCT showed characteristic subretinal hemorrhage and fluid with corresponding late leakage on FA. OCTA showed subretinal small caliber vessels and capillaries consistent with the diagnosis of CNV. In our cases, we believe that RPE changes induce VEGF secretion, in which low doses may induce bridging vessels so that by increasing the dose, CNV is induced.

Based on the effects of bestrophin on the calcium content and VEGF secretion of RPE,⁹ the effects of VEGF in CNV formation of macular dystrophies, new FAZ vascular formations in other vascular diseases of the retina, and our observation of vessels in the FAZ of BVMD patients, we hypothesize that there may be an association between bridging vessels and BVMD, but this is not definitive as this is a non-consecutive case series.

It is obvious that the sample size of this case series is very small. Further studies should include larger samples sizes and longitudinal studies to assess the hypothesis postulating that bridging vessels occur due to increased VEGF.

Acknowledgements

The authors would like to thank Dr. David Sarraf for his comments. The authors would like to thank Pouran Fadakar MSc, Roghayeh Shafei BA, and Captain Ali Davoudzade for their help in the process of this report.

References

- Booij JC, Boon CJ, van Schooneveld MJ, et al. Course of visual decline in relation to the Best1 genotype in vitelliform macular dystrophy. *Ophthalmology*. 2010;117(7):1415–1422.
- Battaglia Parodi M, Iacono P, Romano F, Bandello F. Spectral domain optical coherence tomography features in different stages of best vitelliform macular dystrophy. *Retina*. 2018;38(5):1041–1046.
- Tsang SH, Sharma T. Best vitelliform macular dystrophy. *Adv Exp Med Biol*. 2018;1085:79–90.
- Kashani AH, Chen CL, Gahm JK, et al. Optical coherence tomography angiography: a comprehensive review of current methods and clinical applications. *Prog Retin Eye Res*. 2017;60:66–100.
- Murro V, Mucciolo DP, Giorgio D, et al. OCTA imaging of choroidal neovascularization treated using photodynamic therapy in a young patient with best macular dystrophy. *Ophthalmic Surg Laser Imag Retin*. 2018;49(12):969–973.
- Gass JDM. *Stereoscopic Atlas of Macular Diseases: Diagnosis and Treatment*. Mosby Inc; 1997.
- Marmorstein AD, Marmorstein LY, Rayborn M, Wang X, Hollyfield JG, Petrukhin K. Bestrophin, the product of the Best vitelliform macular dystrophy gene (VMD2), localizes to the basolateral plasma membrane of the retinal pigment epithelium. *Proc Natl Acad Sci Unit States Am*. 2000;97(23):12758–12763.
- Boon CJ, Klevering BJ, Leroy BP, Hoyng CB, Keunen JE, den Hollander AI. The spectrum of ocular phenotypes caused by mutations in the BEST1 gene. *Prog Retin Eye Res*. 2009;28(3):187–205.
- Rosenthal R, Heimann H, Agostini H, Martin G, Hansen LL, Strauss O. Ca²⁺ channels in retinal pigment epithelial cells regulate vascular endothelial growth factor secretion rates in health and disease. *Mol Vis*. 2007;13:443–456.
- Stanga PE, Lim JJ, Hamilton P. Indocyanine green angiography in chorioretinal diseases: indications and interpretation: an evidence-based update. *Ophthalmology*. 2003;110(1):15–21.
- Sankar MJ, Sankar J, Mehta M, Bhat V, Srinivasan R. Anti-vascular endothelial growth factor (VEGF) drugs for treatment of retinopathy of prematurity. *Cochrane Database Syst Rev*. 2016;2, CD009734. <https://doi.org/10.1002/14651858.CD009734>.
- Mintz-Hittner HA, Knight-Nanan DM, Satriano DR, Kretzer FL. A small foveal avascular zone may be an historic mark of prematurity. *Ophthalmology*. 1999;106(7):1409–1413.
- Cicinelli MV, Carnevali A, Rabiolo A, et al. Clinical spectrum of macular-foveal capillaries evaluated with optical coherence tomography angiography. *Retina*. 2017;37(3):436–443.
- Falavarjani KG, Iafe NA, Velez FG, et al. Optical coherence tomography angiography of the fovea in children born preterm. *Retina*. 2017;37(12):2289–2294.
- Dolz-Marco R, Phasukkijwatana N, Sarraf D, Freund KB. Optical coherence tomography angiography in fovea plana. *Ophthalmic Surg Laser Imag Retin*. 2016;47(7):670–673.
- Jiang S, Choudhry N. Swept-source OCT angiography of the anomalous foveal avascular zone. *Ophthalmic Surg Laser Imag Retin*. 2018;49(11):852–858.