


Transforaminal Endoscopic Lumbar Discectomy: Clinical Outcomes and Complications*

Discectomia endoscópica transforaminal lombar: Resultados clínicos e complicações

Leonardo Yukio Jorge Asano¹  João Paulo Machado Bergamaschi² Álvaro Dowling²
Luciano Miller Reis Rodrigues¹

¹Faculdade de Medicina do ABC, Santo André, SP, Brazil

²Clínica Kennedy, São Paulo, SP, Brazil

Address for correspondence Leonardo Yukio Jorge Asano, Faculdade de Medicina do ABC, Avenida Príncipe de Gales 821, Vila Príncipe de Gales, Santo André, SP, 09060-650, Brasil (e-mail: Yukioja@hotmail.com).

Rev Bras Ortop 2020;55(1):48–53.

Abstract

Objective To evaluate the clinical and functional results of transforaminal endoscopic lumbar discectomy.

Materials and Methods From August 2015 to January 2017, 101 patients with lumbar disc hernia refractory to clinical treatment underwent endoscopic discectomy. Through clinical evaluation by the Visual Analogue Scale and functional evaluation by the Oswestry Disability Index questionnaire, the patients were analyzed in the preoperative period, the immediate postoperative period, at 1 month, 3 months, 6 months and 1 year after surgery.

Results The mean age of the participants was 48.1 years. The most affected disc levels were L4-L5 and L5-S1. A total of 29 patients were treated at 2 disc levels. After 1 month of postoperative follow-up, the mean scores on the questionnaires (VAS and ODI) decreased significantly ($p < 0.001$).

Conclusion Transforaminal endoscopic Lumbar discectomy has been shown to be a safe, effective and minimally-invasive alternative for the treatment of lumbar disc herniation. The procedure has advantages, such as short hospital stay, surgery performed under local anesthesia and sedation, early return to daily activities, and low rate of complications.

Keywords

- ▶ intervertebral disc displacement
- ▶ percutaneous discectomy
- ▶ endoscopy
- ▶ minimally-invasive surgical procedures

Resumo

Objetivo Avaliar os resultados clínicos e funcionais da discectomia endoscópica transforaminal lombar.

Materiais e Métodos De agosto de 2015 a janeiro de 2017, 101 pacientes portadores de hérnia de disco lombar refratária ao tratamento clínico foram submetidos a discectomia endoscópica. Por meio de avaliação clínica pela Escala Visual Analógica e análise funcional pelo questionário Oswestry Disability Index, os pacientes foram

* Work developed At Faculdade de Medicina do ABC, Santo André, SP, Brazil.

Palavras-chave

- ▶ hérnia de disco
- ▶ discectomia percutânea
- ▶ endoscopia
- ▶ procedimentos cirúrgicos minimamente invasivos

analisados no período pré-operatório, no pós-operatório imediato, com 1 mês, 3 meses, 6 meses e 1 ano após a cirurgia.

Resultados A média de idade dos participantes foi de 48.1 anos. Os níveis disciais mais acometidos foram L4-L5, seguidos de L5-S1. Um total de 29 pacientes foram abordados em 2 níveis disciais. Após 1 mês de seguimento pós-operatório, a média das pontuações nos questionários (EVA e ODI) diminuiu significativamente ($p < 0.001$).

Conclusão A discectomia endoscópica transforaminal lombar mostrou ser uma alternativa segura, eficaz e minimamente invasiva para o tratamento de hérnia de disco lombar. O procedimento possui vantagens, como curto período de internação hospitalar, cirurgia realizada sob anestesia local e sedação, retorno precoce às atividades diárias, e baixa taxa de complicações.

Introduction

About 60% to 80% of adults may experience low back pain at some point during their lifetime.¹ At age 30, nearly half of adults have experienced a significant episode of lower back pain.² Lumbar disc herniation is a common cause of low back pain and sciatica, with an annual incidence of 5 cases per one thousand people.³ Currently, lumbar disc herniation is the condition that most leads to spine surgery, especially in men around 40 years of age.⁴

In 1934, Mixter and Barr⁵ were the first to describe the open conventional discectomy technique, which could relieve pain and improve nerve function. In 1989, Hijikata⁶ performed a nucleotomy through a cannula inserted into the intervertebral disc core using a posterolateral approach. He reported satisfactory postoperative results in 64% of his patients. Kambin and Schaffer,⁷ in 1989, used an arthroscope for disc visualization and excision. Foley e Smith,⁸ in 1997, and Jhala and Mistry,⁹ in 2010, introduced the endoscopic discectomy technique, and reported satisfactory clinical outcomes in 100 patients. Yeung¹⁰ has developed a rigid endoscopic working channel for percutaneous endoscopic lumbar discectomy.

Endoscopic lumbar discectomy has been developed as a minimally-invasive technique for disc herniations, and it has several advantages, including lower rates of tissue damage, with paravertebral musculature preservation, shorter hospitalization time, lower morbidity and early return to activities.¹¹

The present study evaluated the clinical and functional results of transforaminal endoscopic discectomy in patients with lumbar disc herniation.

Materials and Methods

A total of 101 patients underwent transforaminal endoscopic lumbar discectomy between August 2015 and January 2017 due to lumbar disc herniation refractory to clinical treatment. The present study was submitted and approved by the Ethics Committee of Faculdade de Medicina do ABC (CAAE 85551418.0.000.0082). All patients signed an informed consent form.

Patients with disc herniation confirmed by magnetic resonance imaging associated with a positive nerve root tension test on the physical examination and persistent sciatica for more than six weeks of adequate conservative treatment (physical therapy, pain relief, rest) were included.

Severe lumbar stenosis, instability (over 3 mm slip to adjacent vertebra during flexion and extension radiographs), tumor, trauma, and infection were the exclusion criteria.

The patients were evaluated regarding the pain clinical data using the Visual Analogue Scale (VAS), and as for the functional findings, by the Oswestry Disability Index (ODI). These data were obtained preoperatively, in the immediate postoperative period, and one month, three months, six months and one year after surgery. Magnetic resonance imaging was repeated at the postoperative follow-up in patients who developed persistent or new symptoms of root pain.

A significance level of 5% (0.050) was adopted for the statistical tests, that is, a statistically significant difference or relationship was observed when the calculated significance value (p) was lower than 5%; on the other hand, a statistically non-significant difference or relationship was identified when the p -value was higher than 5%. An Excel spreadsheet, part of the Office 2013 package (Microsoft Corp., Redmond, WA, US), was used for data organization, and the Statistical Package for Social Sciences (SPSS, IBM Corp., Armonk, NY, US) software, version 24.0, was used to obtain the results. The Mann-Whitney test verified possible differences between the first lines (operated cases) and the last 30 lines for variables of interest. The Wilcoxon signed-rank test identified which observation moments differed from the others.

For the surgical technique, the patient is placed in prone position on a radiolucent table, with the hip and knees flexed, under conscious sedation. After proper asepsis, skin marking is performed under fluoroscopy visualization. Then, local anesthesia with xylocaine 1% without vasoconstrictor is applied at the established puncture site. An 18-gauge needle is introduced in the lateral portion of the facet, and then in the posterior surface of the fibrous annulus for an additional injection of anesthetic solution. At this moment, through the image intensifier, the tip of the needle is observed at the medial pedicular line in an anteroposterior view, and at the vertebral posterior edge at a lateral projection (▶ **Figure 1**).

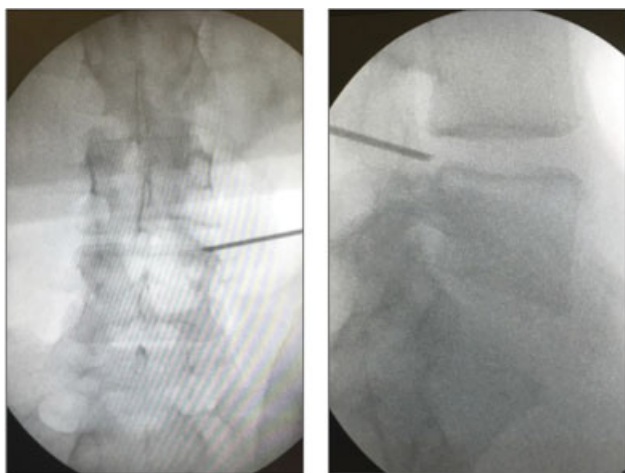


Fig. 1 Anteroposterior and lateral views of the inserted needle.

Discography is performed with a non-iodinated contrast solution and methylene blue. Next, the guidewire, dilator and working cannula are introduced, and a 30-degree endoscope with continuous flow irrigation is installed. In case of bleeding, hemostasis is achieved with a bipolar coagulator. The herniated disc fragment is identified with a blue color and carefully removed with special clamps (→ **Figures 2 and 3**). It is usually possible to observe nerve root release with the fluctuating irrigation pressure. The patients are allowed to ambulate as soon as they have fully recovered from sedation.

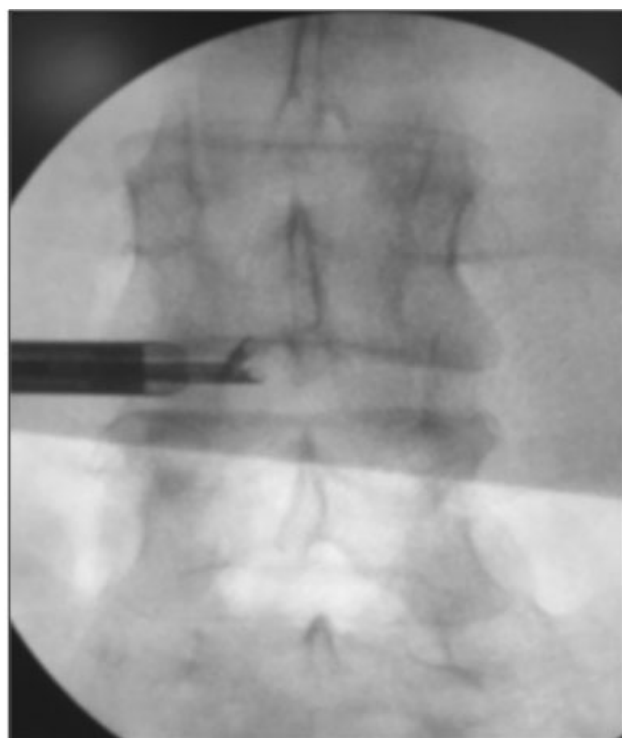


Fig. 2 Image of the disc clamp at the disc space.

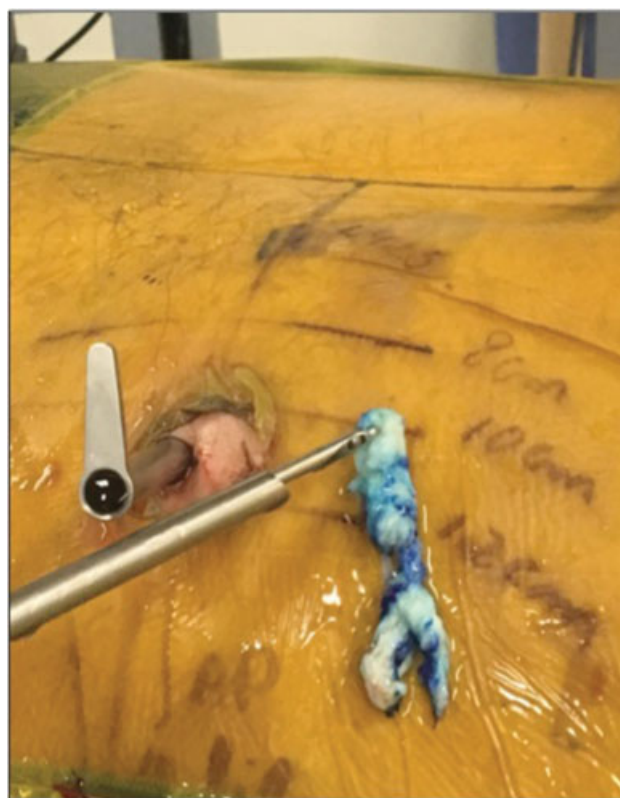


Fig. 3 Removal of the extruded disc fragment.

Results

Of 107 operated patients, a total of 101 (94.4%) individuals were included in the study, while 6 patients were lost at follow-up and, therefore, excluded. The average age of the participants was 48.1 years (ranging from 20 to 78 years). A total of 55 patients were male, and 46 were female. → **Table 1** shows patient demographics. The most affected disc levels were L4-L5, followed by L5-S1. In total, 29 patients were approached on 2 disc levels.

The procedure lasted from 36 to 126 minutes (average: 54 minutes). A total of 82 patients were discharged on the same day; however, 19 patients underwent surgery at night, being discharged the next morning. No patient was hospitalized for more than one day. In total, 91% of the procedures were performed under local anesthesia and sedation, and 5%

Table 1 Demographic and clinical characteristics

Variables	Values
Number of patients	101
Age (mean)	48.1
Male/Female	55/46
Body mass index (kg/m ²) (mean)	28.2
Surgical disc level	
L3-L4	2
L4-L5	19
L5-S1	11

Table 2 Visual Analogue Scale (VAS) and Oswestry Disability Index (ODI)

Period	Evaluation			
	VAS	p***	ODI	p***
Preoperative	16.37		15.51	
1 week	6.15	< 0.001	7.62	< 0.001
1 month	5.42	< 0.001	5.77	< 0.001
3 months	4.00	< 0.001	3.82	< 0.001
6 months	3.81	< 0.001	3.74	< 0.001
12 months	3.76	< 0.001	3.46	< 0.001

Note: ***p < 0.05 = statistically significant difference (in comparison with the preoperative period).

of the patients reported fear of maintaining conscience during the procedures, opting for general anesthesia. In these patients, surgery was not performed under neurophysiological monitoring; however, we chose to include them in the study because these cases involved disc hernias at levels with wide foraminal spaces (L3-L4 and L4-L5) and lower risk of emergent nerve root injury.

The preoperative and postoperative clinical and functional results are shown in ►Table 2. One month after surgery, the mean scores (VAS and ODI) decreased significantly (p < 0.001). This decrease was sustained twelve months after surgery compared to the initial score (p < 0.001), but with no statistical difference compared to the scores obtained one month after the procedure.

►Table 3 portrays the clinical and functional results twelve months after the procedure of the first thirty patients operated compared to the last thirty patients.

The clinical and functional results 12 months after the procedures involving disc levels L3-L4 and L4-L5 compared to the procedures involving disc level L5-S1 are described in ►Table 4.

Table 3 Comparison of clinical and functional findings 12 months after the procedure of the first 30 patients and the last 30 patients

Variable	Category	n	Mean value	p***
Visual Analogue Scale	First 30 patients	30	6.00	0.444
	Last 30 patients	30	2.90	
	Total	60		
Oswestry Disability Index	First 30 patients	30	5.4	0.830
	Last 30 patients	30	2.83	
	Total	60		

Note: ***p < 0.05 = statistically significant difference.

Table 4 Comparison between the clinical and functional findings 12 months after disc level procedures that included the L5-S1 level and those that did not

Variable	Category	n	Mean value	p***
Visual Analogue Scale	Not including L5-S1	40	3.93	0.997
	Including L5-S1	61	3.66	
	Total	101	3.76	
Oswestry Disability Index	Not including L5-S1	40	3.63	0.950
	Including L5-S1	61	3.34	
	Total	101	3.46	

Note: ***p < 0.05 = statistically significant difference.

Discussion

For many years, conventional open surgery has been considered the gold standard for the treatment of intervertebral disc herniation. Microdiscectomy significantly reduced open surgery morbidity, length of hospital stay and blood loss.¹² Even so, microdiscectomy has some disadvantages also observed in open surgery, such as paravertebral muscle retraction, postoperative pain and bone resection, in addition to the risk of long-term complications (recurrence, epidural fibrosis, spinal instability), which are challenges for an experienced surgeon.¹³ Lumbar microdiscectomy outcomes in recurrent disc prolapses are not good compared to those of the primary cases.¹⁴

Given these limitations, transforaminal percutaneous endoscopic discectomy is an alternative for lumbar disc herniation treatment. Advances in instruments have enabled direct endoscopic visualization for safe removal of disc material.¹⁵

Yeung and Tsou,¹⁶ in 2002, described disc excision outcomes in 307 patients, and observed 89.7% of satisfactory results after 1 year of follow-up. The complications were deep infection in two individuals, thrombophlebitis in two patients, dysesthesia in six subjects, and dural injury in one patient.

In 2008, Ruetten et al¹⁷ performed a prospective randomized controlled trial comparing microdiscectomy and endoscopy in 178 patients. The results were similar, with 96% of satisfactory outcomes. However, the endoscopic procedure had significant advantages over microdiscectomy in terms of surgical time, cost, rehabilitation, low back pain, healing, early revision and complications.

Chae et al¹⁸ reported 94.77% of satisfactory outcomes using percutaneous endoscopic discectomy in 153 patients with extruded lumbar disc herniation. These authors obtained 96% of good to excellent results and an extremely low complication rate, with no cases of surgical wound infection.

Jhala and Mistry,⁹ in 2010, reported endoscopic discectomy results in 100 patients, achieving good and excellent

outcomes in 91%. These authors observed seven dural injuries, one nerve injury and four patients with recurrence, four cases of discitis, and five facet removals. Four patients required a reoperation.

In 2012, Kaushal and Sen¹⁹ reported satisfactory results in 90% of the patients after endoscopic discectomy in 300 cases. The complications included five dura-mater injuries, five cases of discitis, and two nerve-root injuries. In 2014, Kulkarni et al¹⁵ observed endoscopic discectomy results in 188 patients, and found 5% of cases of dural injury, 2.1% of cases of residual disc herniation, 1.5% of recurrence, 0.5% of cases of wrong level and 0.5% of infection.

A meta-analysis²⁰ comparing endoscopic discectomy and open microdiscectomy observed a higher satisfaction rate in patients undergoing the former. In addition, the percutaneous approach was associated with lower blood loss and shorter hospitalization time, although there was no statistical difference regarding surgical time, recurrence or complication rates.²⁰

In a retrospective review of 10,228 single-center cases, Choi et al²¹ studied the cause of transforaminal endoscopic discectomy failure in lumbar disc herniation treatment. They observed a failure rate of 4.3%, mainly due to incomplete removal of disc material (2.8%), followed by disc herniation recurrence (0.8%) and pain persistence after complete fragment removal (0.4%).²¹

The main disadvantage of endoscopic discectomy is the long learning curve. In 2013, Wang et al²² recommended practicing transforaminal epidural infiltration prior to the performance of an endoscopic procedure.²² Wu et al,²³ in 2016, compared the first 60 cases of transforaminal endoscopic discectomy at level L4-L5 (group I) with the first 60 cases at level L5-S1 (group II). These authors found that the learning curve at the L5-S1 level was more difficult due to anatomical features, including the iliac crest height, broad facet joint, transverse L5 process, narrow disc space, and smaller foraminal space. In addition, they observed a statistical difference when comparing the surgical time of the first 20 cases with the last 20 cases in both groups. Hsu et al²⁴ demonstrated that the learning curve for the transforaminal approach was easier compared to the interlaminar access. Although spine surgeons are more familiar with the posterior anatomy, the transforaminal procedure requires less surgical time on average than the interlaminar procedure.

In the present study, no incidental dural injury, permanent neurological injury and disc or surgical site infection were observed. The low rate of infection can be explained by minimal damage to normal tissue, lower bleeding, short operative time, continuous saline irrigation, and surgical technique. There were three cases of disc hernia recurrence at the same level after a period of expressive symptom improvement. These cases included only one patient, who required a new endoscopic discectomy. Conversion to open microdiscectomy was not required in any case, nor in cases of herniated disc recurrence. Tolerable sciatica was observed in five patients with good improvement after an average period of four weeks of conservative treatment. This complication rate is similar to those reported in the literature. We observed

that complications occurred in the first 30 cases, but with no statistical difference when compared to the last 30 cases. In addition, we did not identify any statistical difference regarding the operated disc level.

Since the clinical and functional results were considered the most important after discectomy, postoperative disc herniation was not studied by magnetic resonance imaging; this modality was reserved for persistent cases or new onset of sciatica. Randomized controlled trials with larger numbers of patients and longer follow-up intervals are required to objectively assess the impact of endoscopic discectomy.

Conclusion

Transforaminal endoscopic lumbar discectomy has been shown to be a safe, effective and minimally-invasive alternative for the treatment of lumbar disc herniation. Although it requires a long learning curve, the technique has advantages, including minimal soft-tissue damage, short surgical and hospitalization times, low complication rate, and early return to work.

Conflict of Interests

The authors have no conflict of interests to declare.

References

- Andersson GB. Epidemiological features of chronic low-back pain. *Lancet* 1999;354(9178):581–585
- Papageorgiou AC, Croft PR, Ferry S, Jayson MI, Silman AJ. Estimating the prevalence of low back pain in the general population. Evidence from the South Manchester Back Pain Survey. *Spine* 1995;20(17):1889–1894
- Konstantinou K, Dunn KM. Sciatica: review of epidemiological studies and prevalence estimates. *Spine* 2008;33(22):2464–2472
- Spangfort EV. The lumbar disc herniation. A computer-aided analysis of 2,504 operations. *Acta Orthop Scand Suppl* 1972;142:1–95
- Mixter WJ, Barr J. Rupture of the intervertebral disc with involvement of the spinal canal. *N Engl J Med* 1934;211:208–215
- Hijikata S. Percutaneous nucleotomy. A new concept technique and 12 years' experience. *Clin Orthop Relat Res* 1989;(238):9–23
- Kambin P, Schaffer JL. Percutaneous lumbar discectomy. Review of 100 patients and current practice. *Clin Orthop Relat Res* 1989;(238):24–34
- Foley KT, Smith MM. Microendoscopic Discectomy. *Tech Neurosurg* 1997;3:301–307
- Jhala A, Mistry M. Endoscopic lumbar discectomy: Experience of first 100 cases. *Indian J Orthop* 2010;44(02):184–190
- Yeung AT. Minimally Invasive Disc Surgery with the Yeung Endoscopic Spine System (YESS). *Surg Technol Int* 1999;8:267–277
- Maroon JC. Current concepts in minimally invasive discectomy. *Neurosurgery* 2002;51(5, Suppl):S137–S145
- Caspar W. A new surgical procedure for lumbar disc herniation causing less tissue damage through microsurgical approach. In: Wullenweber R, Brock M, Hamer J, Klinger M, Spoerri O, editors. *Advances in Neurosurgery*. Berlin: Springer-Verlag; 1977:74–77
- Kraemer R, Wild A, Haak H, Herdmann J, Krauspe R, Kraemer J. Classification and management of early complications in open lumbar microdiscectomy. *Eur Spine J* 2003;12(03):239–246
- Acharya KN, Nathan TS, Kumar JR, Menon KV. Primary and revision lumbar discectomy: a three-year review from one center. *Indian J Orthop* 2008;42(02):178–181

- 15 Kulkarni AG, Bassi A, Dhruv A. Microendoscopic lumbar discectomy: Technique and results of 188 cases. *Indian J Orthop* 2014; 48(01):81–87
- 16 Yeung AT, Tsou PM. Posterolateral endoscopic excision for lumbar disc herniation: Surgical technique, outcome, and complications in 307 consecutive cases. *Spine* 2002;27(07):722–731
- 17 Ruetten S, Komp M, Merk H, Godolias G. Full-endoscopic interlaminar and transforaminal lumbar discectomy versus conventional microsurgical technique: a prospective, randomized, controlled study. *Spine* 2008;33(09):931–939
- 18 Chae KH, Ju CI, Lee SM, Kim BW, Kim SY, Kim HS. Strategies for Noncontained Lumbar Disc Herniation by an Endoscopic Approach : Transforaminal Suprapedicular Approach, Semi-Rigid Flexible Curved Probe, and 3-Dimensional Reconstruction CT with Discogram. *J Korean Neurosurg Soc* 2009;46(04):312–316
- 19 Kaushal M, Sen R. Posterior endoscopic discectomy: Results in 300 patients. *Indian J Orthop* 2012;46(01):81–85
- 20 Cong L, Zhu Y, Tu G. A meta-analysis of endoscopic discectomy versus open discectomy for symptomatic lumbar disk herniation. *Eur Spine J* 2016;25(01):134–143
- 21 Choi KC, Lee JH, Kim JS, et al. Unsuccessful percutaneous endoscopic lumbar discectomy: a single-center experience of 10,228 cases. *Neurosurgery* 2015;76(04):372–380, discussion 380–381, quiz 381
- 22 Wang H, Huang B, Li C, et al. Learning curve for percutaneous endoscopic lumbar discectomy depending on the surgeon's training level of minimally invasive spine surgery. *Clin Neurol Neurosurg* 2013;115(10):1987–1991
- 23 Wu XB, Fan GX, Gu X, et al. Learning curves of percutaneous endoscopic lumbar discectomy in transforaminal approach at the L4/5 and L5/S1 levels: a comparative study. *J Zhejiang Univ Sci B* 2016;17(07):553–560
- 24 Hsu HT, Chang SJ, Yang SS, Chai CL. Learning curve of full-endoscopic lumbar discectomy. *Eur Spine J* 2013;22(04):727–733