

Visual Object Perception in Premanifest and Early Manifest Huntington's Disease

Emma M. Coppen^{1,*}, Milou Jacobs¹, Kasper F. van der Zwaan¹, Huub A.M. Middelkoop^{2,3},
Raymund A.C. Roos¹

¹Department of Neurology, Leiden University Medical Center, 2333 ZA, Leiden, the Netherlands

²Department of Clinical Neuropsychology, Leiden University Medical Center, 2333 ZA, Leiden, the Netherlands

³Department of Psychology, Leiden University, 2300 RB, Leiden, the Netherlands

*Corresponding author at: Department of Neurology, Leiden University Medical Center, Albinusdreef 2, PO Box 9600 RC, Leiden, the Netherlands.
Tel.: +31-71-526-1634; fax: +31-71-526-4466. E-mail address: e.m.coppen@lumc.nl (E.M. Coppen)

Editorial Decision 10 January 2019; Accepted 11 January 2019

Abstract

Objective: In Huntington's disease (HD), a hereditary neurodegenerative disorder, cognitive impairment in early disease stages mainly involves executive dysfunction. However, visual cognitive deficits have additionally been reported and are of clinical relevance given their influence on daily life and overall cognitive performance. This study aimed to assess visual perceptual skills in HD gene carriers.

Methods: Subtasks of the Visual Object and Space Perception battery and Groningen Intelligence Test were administered in 62 participants (18 healthy controls, 22 participants with a genetic confirmation of HD without symptoms, i.e., premanifest HD, and 22 participants with a genetic confirmation of HD with symptoms, i.e., manifest HD). Group differences in task performance were measured using analysis of covariance with and without correction for age. Receiver Operating Characteristics (ROC) analysis was performed to examine which task best discriminated between groups and cut-off scores were provided.

Results: Manifest HD performed significantly worse compared to both controls and premanifest HD on all visual perceptual tasks. Premanifest HD did not differ in task performance from controls. Besides the Shape Detection, all tasks were robust in discriminating between groups. The Animal Silhouettes test was most accurate in discriminating manifest HD from premanifest HD (AUC = 0.90, SE = 0.048, $p < .001$).

Conclusion: Visual perceptual deficits are present in early manifest HD, especially an impaired recognition of animals and objects from sketched silhouettes, and not in premanifest HD. This suggests that decline in visual processing only occurs in clinical disease stages. The visual cognitive battery, especially the Silhouettes tasks used in this study is sensitive in discriminating manifest HD from premanifest HD and controls.

Keywords: Huntington's disease; Visual perception; Cognition

Introduction

Motor disturbances, cognitive impairment, and psychiatric symptoms are the main clinical characteristics of Huntington's disease (HD), an autosomal dominant inherited neurodegenerative disorder that is caused by an expanded cytosine-adenine-guanine (CAG) repeat length in the Huntington gene on chromosome 4 (The Huntington's Disease Collaborative Research Group, 1993). Cognitive decline in HD has been widely studied and mainly involves executive dysfunction, such as impaired attention and planning skills, and cognitive inflexibility (Dumas, van den Bogaard, Middelkoop, & Roos, 2013). In addition, impaired working memory, slower psychomotor speed, and deficits in emotion recognition have also been described (Dumas et al., 2013). Eventually, in more advanced disease stages, cognitive deterioration results in dementia. Findings from previous studies have shown that cognitive symptoms in HD patients contribute to a decline in daily functioning, such as the ability to work and drive a car, which causes a large burden on patients and their relatives (Paulsen, 2011; Ross, Pantelyat, Kogan, &

Brandt, 2014). Besides cognitive impairment, patients with HD also develop progressive motor disturbances and behavioral changes. Motor disturbances are characterized by chorea, dystonia, hypokinesia, and gait impairments (Roos, 2010). Depression, irritability and aggression, obsessive-compulsive behavior, and apathy are frequent reported neuropsychiatric symptoms in HD (van Duijn et al., 2014). The manifestation of motor disturbances typically defines the disease onset, in general between the ages of 30 and 50 years (Bates et al., 2015; Roos, 2010). Still, cognitive decline can already be present in early stages of the disease, even before the onset of motor symptoms (i.e., the premanifest stage) (Bates et al., 2015). In this stage, cognitive impairment primarily comprises of slower psychomotor speed and impaired emotion recognition (Bates et al., 2015; Dumas et al., 2013). Despite the growing evidence of early cognitive deficits in HD, there is no accepted cognitive battery available to measure the degree of these impairments, making it difficult to give predictions about poor cognitive functioning (Paulsen, 2011). Determining the affected cognitive domains in early disease stage is important as this might aid in better understanding the disease and finding new therapeutic targets for symptomatic treatment.

In addition to executive dysfunction, impaired working memory, and slower psychomotor speed, there is increasing evidence of impaired visual cognition in early stages of HD (Coppen, Van Der Grond, Hart, Lakke, & Roos, 2018; Dumas et al., 2013; Johnson et al., 2015; Lemiere, Decruyenaere, Evers-Kiebooms, Vandebussche, & Dom, 2004; O'Rourke et al., 2011; Say et al., 2011). Visual cognition or higher-level vision is defined as the processing of retinal input combined with prior knowledge to generate representations (Cavanagh, 2011). In the human brain, two distinct parallel anatomical pathways are involved in visual cognition, the ventral and dorsal streams (Ungerleider & Haxby, 1994). The dorsal stream projects from the occipitoparietal cortex to the frontal eye fields, and is also known as the “where” pathway that is responsible for three-dimensional vision and movement perception of objects in space (Braddick & Atkinson, 2011; Ungerleider & Haxby, 1994). The ventral stream, or the “what” pathway, in the occipitotemporal cortex is involved in visual object and face perception (Kravitz, Saleem, Baker, Ungerleider, & Mishkin, 2013; Ungerleider & Haxby, 1994).

In HD, atrophy of the striatum is the neuropathological hallmark of the disease, but atrophy of the posterior cerebral cortex also occurs early in the disease, and is specifically located in regions that are involved in higher-level vision, such as the lingual and fusiform gyri, and the lateral occipital cortex (Coppen et al., 2018; Johnson et al., 2015; Labuschagne et al., 2016; Rosas et al., 2008). Based on the ventral and dorsal visual pathways, visual cognition can be further divided in several subdomains, such as visuomotor and visuospatial function, visual working memory, visual construction, and visual object perception (Lezak, Howieson, & Loring, 2004). Previous studies in early HD disease stages revealed dysfunction in the visuomotor and visuospatial domains (Labuschagne et al., 2016; Lemiere et al., 2004; Mohr et al., 1991; Say et al., 2011), resulting in an impaired awareness of visual stimuli and deficits in processing spatial information. Worse performance on visuospatial tasks has also been reported in premanifest HD gene carriers (Johnson et al., 2015; O'Rourke et al., 2011), suggesting that early cognitive impairment in HD involves more than executive dysfunction.

Conceptual organization and the dissociation of figures from their background are necessary for the detection and recognition of shapes, facial emotions and objects in the environment, which is classified as visual perception (Fesi & Mendola, 2013). Patients with HD often suffer from difficulties in social communication and affected relationships due to impairments in the recognition of negative facial emotions, such as anger, disgust, and fear (Kordsachia, Labuschagne, & Stout, 2017). However, in contrast to reported deficits in visuospatial processing, visuomotor function, and emotion perception, the visual perception of objects has been studied less extensively in patients with HD (Coppen et al., 2018; Kordsachia et al., 2017). In addition, visual deficits such as visual hallucinations or ophthalmic disorders, are also rarely reported by patients with HD (Coppen et al., 2018; van Duijn et al., 2014). Instead of examining global visual cognition, investigating specific visual cognitive deficits such as an impaired visual object perception can give a better understanding of the affected pathways in a neurodegenerative disorder such as HD. Furthermore, examining deficits in visual object perception in HD is of clinical importance, as this can influence daily functioning, such as the impact on driving a car, difficulties with walking and a higher risk of falling. In addition, deficits in visual object perception can negatively impact complex cognitive task performance.

To date, only five studies have assessed visual object perception in HD and reported deficits in simultaneous perception of multiple objects (Finke et al., 2007), and an impaired object recognition in HD patients compared to controls (Gómez-Tortosa, del Barrio, Barroso, & García Ruiz, 1996; Lawrence, Watkins, Sahakian, Hodges, & Robbins, 2000; Lemiere et al., 2004; Wolf et al., 2014). In these studies, heterogeneous cognitive test batteries have been used and little is known about visual object perceptual skills in premanifest HD gene carriers. Therefore, the aim of this study is to contribute to the knowledge on deficits in visual object perception in HD using cognitive assessments that primarily focus on visual object perception in premanifest and manifest HD gene carriers compared to healthy controls.

Methods

Participants

A total number of 62 participants (18 healthy controls, 22 premanifest HD gene carriers, and 22 manifest HD gene carriers) were included in this study. Individuals were recruited from the outpatient clinic of our Neurology department. Partners and HD gene-negative relatives were recruited as healthy controls. The local Medical Ethical Committee approved this study and written informed consent was obtained from all participants.

Clinical characteristics are presented in Table 1. Premanifest HD gene carriers were significantly younger in age (mean 37.3 years, *SD* 8.8) compared to both controls (mean 46.2 years, *SD* 10.7) and manifest HD gene carriers (mean 52.5 years, *SD* 10.4, $F(2, 59) = 12.91$, $p = .020$ and $p < .001$ respectively). All participants had a normal or corrected to normal primary visual ability above 0.5 (20/40 vision) on the visual acuity test. In each group, one male participant was not able to perceive red-green color differences, measured using the Ishihara Color test. There were no individuals with ophthalmic disorders or other major co-morbidities. All HD gene carriers required a positive genetic test with a CAG repeat expansion of 36 or more on the Huntingtin gene. Trained investigators assessed the degree of motor disturbances using the Unified Huntington's disease Rating Scale – Total Motor Score (UHDRS-TMS), a scale that examines several motor domains, such as chorea and dystonia severity, gait and postural stability, and oculomotor function, with higher scores indicating increased motor impairment (Huntington Study Group, 1996). Participants were considered to be premanifest based on an UHDRS-TMS of 5 or less (Huntington Study Group, 1996). Manifest HD gene carriers were included with an UHDRS-TMS of more than 5. The UHDRS Total Functional Capacity (TFC) score was administered to assess global functioning. This involves five components of daily functioning including work, finances, domestic chores, activities of daily living (such as eating, bathing, and dressing), and care environment (home, or nursing home). Here, lower TFC scores indicate more impaired function. Manifest HD gene carriers had a higher UHDRS-TMS ($F(2, 59) = 53.17$, $p < .001$) and a lower TFC score ($H(2) = 42.45$, $p < .001$) compared to both controls and premanifest HD. The TFC score was additionally used to divide manifest HD gene carriers into disease stages, in which HD stage 1 and 2 represent early disease stages and HD stage 4 and 5 more advanced stages (Shoulson & Fahn, 1979). Twenty manifest HD gene carriers were in an early disease stage (18.2% in HD stage 1, 72.7% in HD stage 2), whereas 2 manifest HD gene carriers (9.1%) were in a mid to moderate stage of the disease.

There were no significant differences between groups for gender, education in years, and handedness. In addition, CAG repeat length did not significantly differ between premanifest and manifest HD.

Clinical Assessments

Visual object recognition and perceptual processing was measured using subtests of the Visual Object and Space Perception (VOSP) battery (Warrington & James, 1991) and a subtest of the Groningen Intelligence Test (GIT) (Luteijn & Barends, 2004). These assessments were chosen because of the minimal involvement of motor, attentional, and executive functions (Rapport et al., 1998; Warrington & James, 1991). For our study, we administered the visual screening test and three visual perceptual subtests of the VOSP. An example of each subtest used for this study is presented in Fig. 1. The

Table 1. Demographic and clinical characteristics

	Controls	Premanifest HD	Manifest HD
<i>N</i>	18	22	22
Age, years	46.2 ± 10.7 (24.1–61.3)	37.3 ± 8.8 (23.2–52.9)	52.5 ± 10.4 (28.5–64.8)
Gender (male/female)	7/11	11/11	12/10
Handedness–right (%)	15 (83.3%)	20 (90.9%)	17 (77.3%)
Education, years	16.9 (12–20)	16.8 (12–23)	16.0 (12–20)
CAG repeat length	N/A	42.0 ± 2.2 (38–45)	43.0 ± 2.4 (40–48)
UHDRS–TFC	13 (11–13)	13 (10–13)	9 (6–13)
UHDRS–TMS	1.8 ± 1.2 (0–5)	2.7 ± 1.0 (1–5)	29.3 ± 16.4 (8–58)

Data are mean ± *SD* (range) for age, CAG repeat length, education in years, and UHDRS-TMS. Numbers (%) are presented for handedness and gender, and median (range) is given for UHDRS-TFC.

N/A = Not applicable; CAG = Cytosine, Adenine, Guanine; UHDRS-TFC = Unified Huntington's Disease Rating Scale Total Functional Capacity; UHDRS-TMS = Unified Huntington's Disease Rating Scale Total Motor Score.




Fig. 1. Examples of visual object perception tasks: Modified examples of subtasks used in this study are displayed for both the Visual Object and Space Perception battery (Warrington and James, 1991) and the Groningen Intelligence Test (Luteijn and Barelds, 2004). (A) the Shape Detection test requires the identification of the letter X on separate sheets (left: yes, right: no). (B) The Silhouettes test entails the correct naming of an animal or object silhouette (left: camel and duck, right: cup, glasses). (C) The Object Decision test consists of four black shapes and requires pointing out the silhouette of a real object (left: real object is below right, right: real object is below right). (D) The Figure Recognition involves the correct naming of the figures (left: fish, right: violin player).

Shape Detection test is used as a screening test to assess if participants are able to complete the other assessments and requires the identification of the letter X on separate sheets, with a maximum score of 20 (Fig. 1). A score below 15 points indicates the inability to complete the rest of the battery. The *Silhouettes test* consists of black shapes of 15 animals and 15 objects on separate sheets. Participants need to correctly name each silhouette, with a maximum score of 15 on each test. The *Object Decision test* comprises of 20 separate sheets with four black shapes of which one represents the silhouette of a real object. The participant needed to point out the real object without requiring a verbal response. The total score is the total number of correct answers, with a maximum score of 20. The GIT is widely used to examine general intellectual ability and consists of nine subtests to evaluate several intelligence domains (Luteijn & Barelds, 2004). In our study, we used one subtest of the GIT, the *Figure Recognition test*, to assess the perceptual figure and object recognition. This subtest was thoroughly revised in 2004 to secure a more modern and accurate approach of testing visual perception by including objects such as a mobile phone, computer, and alarm clock, making it a more suitable assessment tool for visual object perception in younger individuals. In addition, the Figure Recognition test has, to our knowledge, not been investigated in HD patients previously. In this test, 20 partly sketched, fragmented, black- and white figures were presented in random order with increasing difficulty and comprise of animals and objects, and also includes figures of active individuals, such as a cleaning lady, jockey on a horse, and a cyclist. Participants needed to correctly name the figures. The total score measured is the total number of correctly named figures, with a maximum score of 20. For all assessments, the tests were terminated after five consecutive errors.

Statistics

Group differences were analyzed using a one-way Analysis of Variance (ANOVA) for age, years of education, and UHDRS-TMS. χ^2 -test was used for gender and handedness, whereas Kruskal–Wallis test was used for UHDRS-TFC scores. Independent samples *T*-test was performed to assess group differences between premanifest and manifest HD gene carriers for CAG repeat length. Analysis of Covariance (ANCOVA) was used to analyze group differences in visual perceptual task performance, with and without age as covariate, and post-hoc comparisons using Sidak correction, if the ANCOVA yielded

significant results. Because the cognitive battery consisted of five separate cognitive tasks, the significant *p*-value was defined as .05/5 = .01. We used a Receiver Operating Characteristics (ROC) analysis to examine which visual test best discriminated between groups that showed significant group differences and provided cut-off scores per subtest. In this analysis, the sensitivity is plotted against the specificity of the predictor. The area under the curve (AUC) was used as an indicator of which predictor had the most discriminatory accuracy to distinguish between premanifest HD, manifest HD, and controls. Statistical analyses were performed using the Statistical Package for Social Sciences (SPSS for Mac, version 23, SPSS Inc.).

Results

All participants scored above the threshold of 15 correct answers on the Shape Detection test. Therefore, all participants were able to complete the entire cognitive battery. Task performances per group are presented in Table 2. Besides the Shape Detection test, manifest HD performed significantly worse compared to controls on the Animal and Object Silhouettes tasks ($F(2,59) = 19.71, p < .001$, and $F(2,59) = 11.11, p < .001$ respectively), the Object Decision test ($F(2,59) = 7.61, p = .001$), and the Figure Recognition test ($F(2,59) = 8.60, p = .001$). Premanifest HD did not differ in task performance compared to controls. Although the premanifest HD group was significant younger compared to the other groups, performance on the Silhouettes tests and the Object Decision test remained significantly different after adjustment for age as presented in Fig. 2.

Using ROC analysis, all visual perceptual tasks were robust in discriminating between controls and manifest HD (Fig. 1A), and between premanifest HD and manifest HD (Fig. 1B), except for the Shape Detection test (Table 3). Both

Table 2. Group differences on visual cognitive assessments

	Controls (<i>N</i> = 18)	Pre-HD (<i>N</i> = 22)	Mani-HD (<i>N</i> = 22)	Covariate	Estimates of effect sizes	<i>p</i> -value Controls vs. Pre-HD	<i>p</i> -value Controls vs. Mani-HD	<i>p</i> -value Pre-HD vs. Mani-HD
Shape Detection	19.6 ± 0.6	19.9 ± 0.7	19.3 ± 1.0	—	0.100	.606	.485	.039
				Age	0.093	.522	.422	.053
Animal Silhouettes	11.9 ± 1.7	12.2 ± 1.6	9.2 ± 1.9	—	0.401	.943	<.001	<.001
				Age	0.336	.961	<.001	<.001
Object Silhouettes	10.6 ± 1.9	10.3 ± 2.5	7.2 ± 3.1	—	0.274	.967	<.001	.001
				Age	0.280	.998	<.001	.001
Object Decision	17.8 ± 1.6	17.4 ± 1.4	15.3 ± 3.2	—	0.205	.939	.003	.007
				Age	0.221	.999	.001	.005
Figure Recognition	13.8 ± 3.07	12.8 ± 2.9	9.5 ± 3.9	—	0.226	.747	.001	.008
				Age	0.170	.470	.003	.179

Note: Data are mean ± SD of total number correct. Estimates of effect sizes as partial eta squared (η^2) are presented in a separate column. Analysis of covariance (ANCOVA) was used to assess group differences, with and without age as covariate. Post-hoc tests were adjusted using Sidak correction. Significant *p*-values corrected for multiple comparisons ($p < .01$) are presented in bold. Pre-HD = premanifest HD gene carriers, before the onset of motor symptoms, Mani-HD = manifest HD gene carriers with motor symptoms.

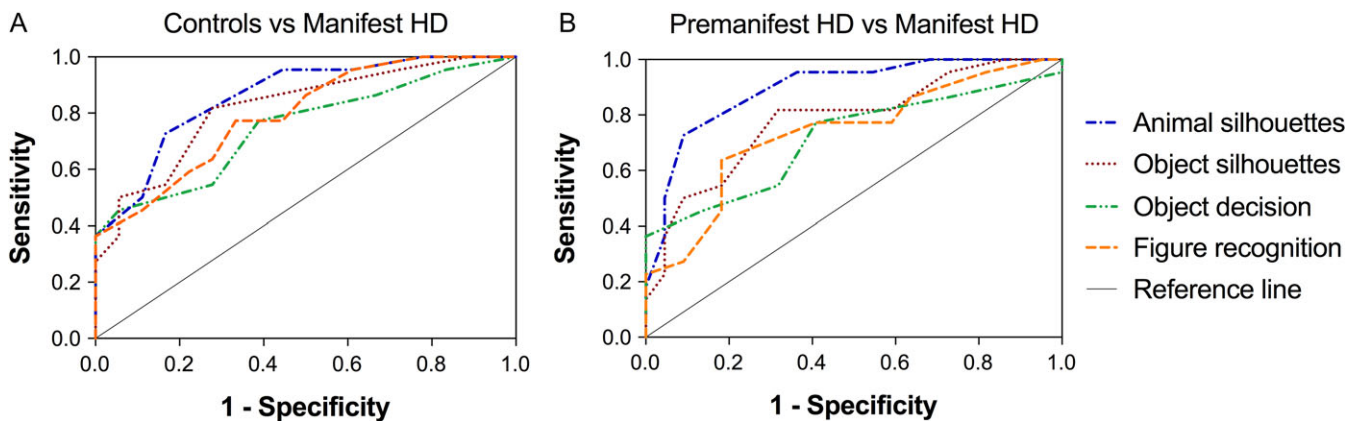


Fig. 2. Receiver Operating Characteristics (ROC) curves: Except for the Shape Detection test were all visual perceptual tasks were robust in discriminating between controls and manifest HD (1A), and between premanifest HD and manifest HD (1B).

Table 3. Receiver Operating Characteristics (ROC) curve analysis

	Controls vs. Mani-HD				Pre-HD vs. Mani HD			
	AUC [95% CI]	Cut-off scores	Sensitivity	Specificity	AUC [95% CI]	Cut-off scores	Sensitivity	Specificity
Animal Silhouettes	0.86 [0.75–0.97]*	11	83%	72%	0.90 [0.80–0.99]*	11	91%	73%
Object Silhouettes	0.82 [0.70–0.95]*	10	83%	81%	0.78 [0.65–0.92]*	9	82%	64%
Object Decision	0.75 [0.60–0.90]*	17	72%	55%	0.72 [0.56–0.87]*	17	68%	64%
Figure Recognition	0.79 [0.66–0.93]*	12	72%	64%	0.74 [0.60–0.89]*	11	82%	60%

* p -value < .05. AUC: area under the curve; CI = confidence interval.

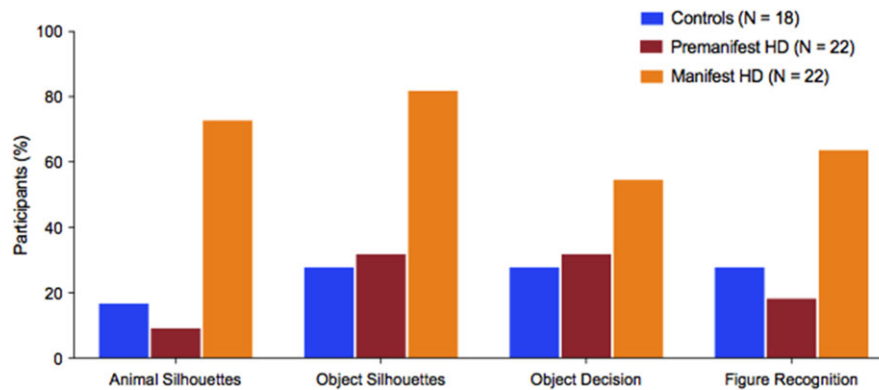


Fig. 3. Percentage of participants impaired on cognitive task: Participants were divided into impaired and normal based on the cut-off scores of the ROC analysis. Manifest HD gene carriers were impaired on all cognitive tasks with the highest percentage of impaired participants on the Animal and Object Silhouettes tasks.

Animal and Object Silhouettes tests were the most sensitive in distinguishing controls from manifest HD, with similar Areas Under the Curve (AUC), $AUC = 0.86$, $SE: 0.058$, $p < .001$ and $AUC = 0.82$, $SE: 0.066$, $p = .001$ respectively. The Animal Silhouettes test was also the most accurate assessment in identifying premanifest HD from manifest HD ($AUC = 0.90$, $SE: 0.048$, $p < .001$). Using the cut-off scores of the ROC analysis, 83% of the controls and 91% of the premanifest HD gene carriers scored 11 points or higher (maximum of 15 points) on the Animal Silhouettes test, while only 27% of the manifest HD reached this score (Fig. 3). This was also seen for the Object Silhouettes test, for which 18% of the manifest HD scored 10 points or higher (maximum of 15 points), compared to 72% of the controls and 68% of the premanifest HD gene carriers. Higher numbers of errors were found in all groups on the Figure Recognition test compared to the Silhouettes tests. Still, 72% of the controls scored 12 points or higher (maximum of 20) on the Figure Recognition task, compared to 82% of the premanifest HD and 36% of the manifest HD.

Discussion

Our study showed that deficits in visual object perception, specifically impairments in the recognition of animals and figures from sketched silhouettes, are present in early manifest HD gene carriers. We found normal visual perceptual skills in premanifest HD gene carriers, which suggest that decline in visual processing only occurs in clinical disease stages. Two other studies also examined visual perception in premanifest HD gene carriers (Gómez-Tortosa et al., 1996; Lemiere et al., 2004), and showed similar results. One study assessed cognitive performance using sum scores of visual perceptual tasks over a follow-up period of 2.5 years, but only found a decline in sum scores over time in manifest HD, not in premanifest HD (Lemiere et al., 2004). Our results complement the findings of this study, since we also used the Visual Object and Space Perception (VOSP) test battery to evaluate visual object perception. But in contrast to the study performed by Lemiere et al., we assessed cognitive performance per task separately without using sum scores. Our findings suggest that especially the identification of abstract objects, displayed in partly sketched silhouettes that were ranked with increasing difficulty, was most difficult for the symptomatic HD participants. Interestingly, 68% of our premanifest HD participants scored 10 points or higher on this task (maximum of 15 points), while only 18% of the manifest HD reached this score. Another study used a different cognitive battery, but also showed that only early and more advanced HD patients scored worse on a task where they needed to recognize and name a fragmented object on a card. Again, no differences in scores were observed between premanifest HD

and controls (Gómez-Tortosa et al., 1996). Two additional studies in manifest HD used a similar cognitive battery as was used in our study, but findings are inconsistent. One study concluded that perceptual dysfunction is not present in HD, as manifest HD only showed an impaired performance on one subtask, the Object Decision task (Lawrence et al., 2000). Here, 7 out of 18 (39%) manifest HD gene carriers scored below the fifth percentile of the control norm (e.g., a score below 15 points) (Lawrence et al., 2000). This is similar to our results, since 8 of the 22 manifest HD (36%) scored below 15 points on this task. However, we also observed worse performance on all other visual perceptual tasks, which is in line with another study that reported an overall impaired performance on visual perception tasks in early manifest HD compared to controls (Wolf et al., 2014).

Thus, our findings suggest that visual object perception in HD seems to remain unaffected in the premanifest disease stage but becomes pronounced in early manifest stages (Gómez-Tortosa et al., 1996; Lemiere et al., 2004; Wolf et al., 2014). An explanation for this could be that brain regions involved in visual perceptual processing remain relatively preserved early in the course of the disease. Neuroimaging studies have indeed confirmed that atrophy in premanifest HD stages is primarily located in striatal brain regions (such as the putamen, caudate nucleus, and nucleus accumbens) and can be detected even a decade before clinical disease onset, whereas atrophy of the cerebral cortex is less pronounced at this stage (Aylward et al., 2004; Tabrizi et al., 2009). In the human brain, visual processing involves a complex and hierarchical distributed system including all cortical lobes and many subcortical brain regions. Visual processing in humans is not restricted to the secondary associative visual areas, but continues within multiple regions in the parietal, temporal and frontal lobes (Kolb & Whishaw, 2015). Although specific functions have not yet been assigned to all of these additional visual brain regions, there is increasing evidence of different regions having certain functions (Kolb & Whishaw, 2015).

The processing of visual stimuli can generally be divided into two distinct anatomical streams. The ventral pathway, projecting to occipitotemporal brain regions, is associated with object perception, whereas the dorsal pathway, projecting to occipitoparietal brain regions, is concerned with spatial processing (Kravitz et al., 2013; Ungerleider & Haxby, 1994).

Studies in manifest HD gene carriers showed distinct volume loss and cortical thinning in occipital and temporal cortical regions, such as the lingual and fusiform gyri (Johnson et al., 2015; Labuschagne et al., 2016; Nana, Kim, Thu, Oorschot, & Tippett, 2014; Rosas et al., 2008). Therefore, our results of impaired visual object perception in manifest HD gene carriers might be caused by early neurodegenerative changes in the ventral pathway. Previous studies have already shown that visuospatial dysfunction in HD gene carriers was associated with parieto-occipital and temporal cortical volume loss (Johnson et al., 2015; Labuschagne et al., 2016). However, additional neuroimaging and neuropathological are needed to confirm this hypothesis for visual object perception.

Deficits in visual object perception and visuospatial function have also frequently been reported in other neurodegenerative disorders. For example, impaired visual object perception is common in patients with Alzheimer's disease (AD), dementia with Lewy bodies (DLB) and moderate stage patients with Parkinson's disease (PD) (Cagnin et al., 2013; Quental, Brucki, & Bueno, 2013), while patients with corticobasal degeneration showed more pronounced visuospatial deficits (Bak, Caine, Hearn, & Hodges, 2006). Both PD and DLB patients performed worse on visual object perception tasks compared to patients with AD (Mosimann et al., 2004). In corticobasal degeneration, it has been reported that impaired performance on visuospatial tasks is associated with cortical atrophy in the parietal lobe (Halpern et al., 2004). Studies in patients with PD found correlations between poor performance on visuo-perceptual tests and atrophy in the fusiform, parahippocampal, and occipital gyri (e.g., the occipitotemporal cortex or ventral pathway) (Pereira et al., 2009). Similar to patients with PD, HD gene carriers show impairments in visuospatial and visuo-perceptual functions, which might reflect specific anatomical changes in temporal and parietal brain regions. As the degree and patterns of impairment varies across diseases, this suggests a different neural basis in each condition (Bak et al., 2006; Mosimann et al., 2004).

Previous studies in HD patients have used heterogeneous test batteries to examine visual object perception or included tasks that integrated several visual cognitive domains, such as visuomotor function or visuoconstructive abilities (Gómez-Ansón et al., 2009; Gómez-Tortosa et al., 1996; O'Rourke et al., 2011). We believe that the use of a standardized battery that examines all visual cognitive domains separately can give a more complete evaluation of visual cognitive function in HD patients. The cognitive tasks selected in our study are designed to assess specific, dissociable aspects of object perception, relatively independent of other cognitive and motor processes with limited requirement of verbal responses (Rapport et al., 1998; Warrington & James, 1991). Because HD is a progressive disorder, patients in more advanced disease stages will naturally be older, as was also seen in our study. Interestingly, despite the fact that our premanifest HD group was younger compared to the other groups, performance on the visual object perception tasks was independent for age.

This way, we were able to accurately measure visual perception without the influence of age and other HD signs, such as motor disturbances, slowness in execution (i.e., bradykinesia) or slowness in information processing speed (i.e., bradyphrenia). Also, since all participants had a normal primary visual ability and the entire cohort scored above the threshold for the Shape Detection test, which was used as a screening test for the complete cognitive battery, this implies that our findings

seem to accurately measure higher-level processing deficits. However, since we did not measure visuospatial function in our study, it should be noted that the HD patients that showed impaired visual object perception could also have deficits in visuospatial function. This is not unlikely, as impaired visuospatial function has been detected in previous studies, even in premanifest HD gene carriers (Johnson et al., 2015; Lemiere et al., 2004; O'Rourke et al., 2011). Furthermore, the subtests of the VOSP that were used in our study might not encompass a complete assessment of visual perception, since we have not examined visual (emotion) recognition or contrast and color perception. The small sample size and markedly younger premanifest HD group in our cohort might have limited our ability to observe differences in the premanifest HD group compared to the manifest HD and control groups. Future studies are, therefore, needed to examine changes in visual perceptual and spatial abilities in premanifest HD gene carriers when the disease progresses and they convert into manifest HD. Still, retest effects on the VOSP object perception tasks were observed in premanifest HD and controls over time (Lemiere et al., 2004), so caution is warranted when selecting tests for visual cognition. Finally, it would be interesting to assess the influence of visual cognitive deficits on decline in daily functioning in a larger and longitudinal cohort study.

In conclusion, impaired object recognition is present in early manifest HD. In addition, the visual perceptual tasks of the VOSP battery and the Figure Recognition task of the GIT are sensitive to distinguish manifest HD gene carriers from controls. As these tasks require minimal interference of other cognitive functions or motor skills, these tasks should be included in a standardized battery and used as a marker of visual cognitive function.

Funding

None.

Conflict of Interest

E.M. Coppen, M. Jacobs, K.F. van der Zwaan and H.A.M. Middelkoop report no conflict of interests. R.A.C. Roos receives research grants from TEVA pharmaceuticals and is advisor for UniQure.

Acknowledgements

The authors would like to thank all patients and relatives that have participated in this study. We would also like to thank all investigators that have assisted in data collection.

References

- Aylward, E., Sparks, B., Field, K., Yallapragada, V., Shpritz, B., Rosenblatt, A., et al. (2004). Onset and rate of striatal atrophy in preclinical Huntington disease. *Neurology*, *63*, 66–72.
- Bak, T. H., Caine, D., Hearn, V. C., & Hodges, J. R. (2006). Visuospatial functions in atypical parkinsonian syndromes. *Journal of Neurology, Neurosurgery, and Psychiatry*, *77*, 454–456. <https://doi.org/10.1136/jnnp.2005.068239>.
- Bates, G. P., Dorsey, R., Gusella, J. F., Hayden, M. R., Kay, C., Leavitt, B. R., et al. (2015). Huntington disease. *Nature Reviews Disease Primers*, *1*, 15005.
- Braddick, O., & Atkinson, J. (2011). Development of human visual function. *Vision Research*, *51*, 1588–1609.
- Cagnin, A., Gnoato, F., Jelcic, N., Favaretto, S., Zarantonello, G., Ermani, M., et al. (2013). Clinical and cognitive correlates of visual hallucinations in dementia with Lewy bodies. *Journal of Neurology, Neurosurgery, and Psychiatry*, *84*, 505–510. <https://doi.org/10.1136/jnnp-2012-304095>.
- Cavanagh, P. (2011). Visual cognition. *Visual Cognition*, *51*, 1538–1551.
- Coppen, E. M., Van Der Grond, J., Hart, E. P., Lakke, E. A. J. F., & Roos, R. A. C. (2018). The visual cortex and visual cognition in Huntington's disease: An overview of current literature. *Behavioural Brain Research*, *351*, 63–74.
- Dumas, E., van den Bogaard, S., Middelkoop, H., & Roos, R. (2013). A review of cognition in Huntington's disease. *Frontiers in Bioscience*, *5*, 1–18. <https://doi.org/http://dx.doi.org/10.2741/S355>.
- Fesi, J. D., & Mendola, J. D. (2013). Linking brain to behavior for the visual perception of figures and objects. *Visual Neuroscience*, *30*, 299–313. <https://doi.org/10.1017/S0952523813000266>.
- Finke, K., Schneider, W. X., Redel, P., Dose, M., Kerkhoff, G., Hermann, J. M., et al. (2007). The capacity of attention and simultaneous perception of objects: A group study of Huntington's disease patients. *Neuropsychologia*, *45*, 3272–3284.
- Gómez-Ansón, B., Alegret, M., Muñoz, E., Monté, G. C., Alayrach, E., Sánchez, A., et al. (2009). Prefrontal cortex volume reduction on MRI in preclinical Huntington's disease relates to visuomotor performance and CAG number. *Parkinsonism and Related Disorders*, *15*, 213–219. <https://doi.org/10.1016/j.parkreldis.2008.05.010>.
- Gómez-Tortosa, E., del Barrio, A., Barroso, T., & García Ruiz, P. J. (1996). Visual processing disorders in patients with Huntington's disease and asymptomatic carriers. *Journal of Neurology*, *243*, 286–292. <https://doi.org/10.1111/j.1399-0004.2006.00668.x>.
- Halpern, C. H., Glosser, G., Clark, R., Gee, J., Moore, P., Dennis, K., et al. (2004). Dissociation of numbers and objects in corticobasal degeneration and semantic dementia. *Neurology*, *62*, 1163–1169. <https://doi.org/10.1212/01.WNL.0000118209.95423.96>.

- Huntington Study Group. (1996). Unified Huntington's disease rating scale: Reliability and consistency. *Movement Disorders*, *11*, 136–142. <https://doi.org/10.1002/mds.870110204>.
- Johnson, E. B., Rees, E. M., Labuschagne, I., Durr, A., Leavitt, B. R., Roos, R. A. C., et al. (2015). The impact of occipital lobe cortical thickness on cognitive task performance: An investigation in Huntington's Disease. *Neuropsychologia*, *79*, 138–146.
- Kolb, B., & Whishaw, I. Q. (2015). *Fundamentals of human neuropsychology* (7th ed.). New York: Worth.
- Kordsachia, C. C., Labuschagne, I., & Stout, J. C. (2017). Beyond emotion recognition deficits: A theory guided analysis of emotion processing in Huntington's disease. *Neuroscience and Biobehavioral Reviews*. <https://doi.org/10.1016/j.neubiorev.2016.11.020> Elsevier Ltd.
- Kravitz, D. J., Saleem, K. S., Baker, C. I., Ungerleider, L. G., & Mishkin, M. (2013). The ventral visual pathway: An expanded neural framework for the processing of object quality. *Trends in Cognitive Sciences*, *17*, 26–49. <https://doi.org/10.1016/j.tics.2012.10.011>.
- Labuschagne, I., Cassidy, A. M., Scahill, R. I., Johnson, E. B., Rees, E., Regan, A. O., et al Investigators, T. (2016). Visuospatial processing deficits linked to posterior brain regions in premanifest and early stage Huntington's disease. *Journal of the International Neuropsychological Society*, *22*, 595–608.
- Lawrence, A. D., Watkins, L. H., Sahakian, B. J., Hodges, J. R., & Robbins, T. W. (2000). Visual object and visuospatial cognition in Huntington's disease: Implications for information processing in corticostriatal circuits. *Brain*, *123*, 1349–1364.
- Lemiere, J., Decruyenaere, M., Evers-Kiebooms, G., Vandenbussche, E., & Dom, R. (2004). Cognitive changes in patients with Huntington's disease (HD) and asymptomatic carriers of the HD mutation. *Journal of Neurology*, *251*, 935–942. <https://doi.org/10.1007/s00415-004-0461-9>.
- Lezak, M., Howieson, D., & Loring, D. (2004). *Neuropsychological assessment* (4th ed.). Oxford, UK: Oxford University Press.
- Luteijn, F., & Barelds, D. P. (2004). *Handleiding Groninger Intelligentietest 2 (GIT)*. [Manual Groningen Intelligence Test]. Lisse, the Netherlands: Swets & Zeitlinger.
- Mohr, E., Brouwers, P., Claus, J. J., Mann, U. M., Fedio, P., & Chase, T. N. (1991). Visuospatial cognition in Huntington's disease. *Movement Disorders*, *6*, 127–132. <https://doi.org/10.1002/mds.870060207>.
- Mosimann, U. P., Mather, G., Wesnes, K. A., Brien, J. T. O., Burn, D. J., & Mckeith, I. G. (2004). Visual perception in Parkinson disease dementia and dementia with Lewy bodies. *Neurology*, *63*, 2091–2096. <https://doi.org/10.1212/01.WNL.0000145764.70698.4E>.
- Nana, A. L., Kim, E. H., Thu, D. C. V., Oorschot, D. E., & Tippett, L. J. (2014). Widespread heterogeneous neuronal loss across the cerebral cortex in Huntington's Disease. *Journal of Huntington's Disease*, *3*, 45–64.
- O'Rourke, J. J. F., Beglinger, L. J., Smith, M. M., Mills, J., David, J., Rowe, K. C., et al. (2011). The Trail Making Test in prodromal Huntington disease: Contributions of disease progression to test performance. *Journal of Clinical and Experimental Neuropsychology*, *33*, 567–579. <https://doi.org/10.1080/13803395.2010.541228>.
- Paulsen, J. S. (2011). Cognitive impairment in Huntington disease: Diagnosis and treatment. *Current Neurology and Neuroscience Reports*, *11*, 474–483.
- Pereira, J. B., Junqué, C., Martí, M. J., Ramirez-Ruiz, B., Bargalló, N., & Tolosa, E. (2009). Neuroanatomical substrate of visuospatial and visuoperceptual impairment in Parkinson's disease. *Movement Disorders*, *24*, 1193–1199. <https://doi.org/10.1002/mds.22560>.
- Qentel, N., Brucki, S., & Bueno, O. (2013). Visuospatial function in early Alzheimer's disease – The use of the Visual Object and Space Perception (VOSP) Battery. *PLoS One*, *8*, e68398. <https://doi.org/10.1371/journal.pone.0068398>.
- Rappport, L. J., Millis, S. R., Bonello, P. J., Rappport, L. J., Millis, S. R., & Bonello, P. J. (1998). Validation of the Warrington Theory of Visual Processing and the Visual Object and Space Perception Battery. *Journal of Clinical and Experimental Neuropsychology*, *20*, 211–220. <https://doi.org/10.1076/jcen.20.2.211.1169>.
- Roos, R. A. C. (2010). Huntington's disease: A clinical review. *Orphanet Journal of Rare Diseases*, *5*, 40. <https://doi.org/10.1186/1750-1172-5-40>.
- Rosas, H. D., Salat, D. H., Lee, S. Y., Zaleta, A. K., Pappu, V., Fischl, B., et al. (2008). Cerebral cortex and the clinical expression of Huntington's disease: Complexity and heterogeneity. *Brain*, *131*, 1057–1068.
- Ross, C. A., Pantelyat, A., Kogan, J., & Brandt, J. (2014). Determinants of functional disability in Huntington's disease: Role of cognitive and motor dysfunction. *Movement Disorders*, *29*, 1351–1358.
- Say, M. J., Jones, R., Scahill, R. I., Dumas, E. M., Coleman, A., Santos, R. C. D., et al. (2011). Visuomotor integration deficits precede clinical onset in Huntington's disease. *Neuropsychologia*, *49*, 264–270. <https://doi.org/10.1016/j.neuropsychologia.2010.11.016>.
- Shoulson, I., & Fahn, S. (1979). Huntington disease: Clinical care and evaluation. *Neurology*, *29*, 1–3.
- Tabrizi, S. J., Langbehn, D. R., Leavitt, B. R., Roos, R. A. C., Durr, A., Craufurd, D., et al. (2009). Biological and clinical manifestations of Huntington's disease in the longitudinal TRACK-HD study: Cross-sectional analysis of baseline data. *The Lancet Neurology*, *8*, 791–801.
- The Huntington's Disease Collaborative Research Group. (1993). A novel gene containing a trinucleotide repeat that is expanded and unstable on Huntington's disease chromosomes. *Cell*, *72*, 971–983.
- Ungerleider, L. G., & Haxby, J. V. (1994). "What" and "where" in the human brain. *Current Opinion in Neurobiology*, *4*, 157–165.
- van Duijn, E., Craufurd, D., Hubers, A. A. M., Giltay, E. J., Bonelli, R., Rickards, H., et al. (2014). Neuropsychiatric symptoms in a European Huntington's disease cohort (REGISTRY). *Journal of Neurology, Neurosurgery, and Psychiatry*, *85*, 1411–1418.
- Warrington, E., & James, M. (1991). *Visual Object and Space Perception Battery*. Bury St. Edmunds: Thames Valley Test Company.
- Wolf, R. C., Sambataro, F., Vasic, N., Baldas, E.-M., Ratheiser, I., Bernhard Landwehrmeyer, G., et al. (2014). Visual system integrity and cognition in early Huntington's disease. *European Journal of Neuroscience*, *40*, 2417–2426. <https://doi.org/doi:10.1111/ejn.12575>.