

SURGERY

OPEN

Modified Mini-open Transforaminal Lumbar Interbody Fusion

Description of Surgical Technique and Assessment of Free-hand Pedicle Screw Insertion

Peyman Pakzaban, MD

Study Design. Retrospective case series.**Objective.** To describe a modified technique for mini-open transforaminal lumbar interbody fusion (TLIF) that improves visualization for decompression, fusion, and freehand pedicle screw insertion. Accuracy of freehand pedicle screw placement with this technique was assessed.**Summary of Background Data.** Mini-open TLIF is a minimally invasive technique that allows limited visualization of the bone and neural anatomy via an expandable tubular retractor inserted through the Wiltse plane. No significant modification that of this technique has been described in detail.**Methods.** In this study, 92 consecutive patients underwent one-level modified mini-open TLIF (MOTLIF). MOTLIF modifications consisted of (i) transmuscular dissection through the multifidus muscle rather than intermuscular dissection in the Wiltse plane; (ii) microsurgical detachment of multifidus from the facet rather than muscle dilation; (iii) *en bloc* total facetectomy (unilateral or bilateral, as needed for decompression); (iv) facet autograft used for interbody fusion; and (v) solid pedicle screws placed bilaterally by a freehand technique under direct vision.**Results.** The mean age was 53 years. Mean follow-up was 35 months (minimum 2 yrs). By 6 months, mean Visual Analog Scale for back and leg pain had improved from 51 to 19 and from 58 to 17, respectively, and mean ODI improved from 53 to 16. These improvements persisted at 2 years. Solid fusion, defined

by computed tomography at 1 year, was achieved in 88.1%, whereas satisfactory fusion was achieved in 95.2% of patients. Pedicle screws were accurately placed in 335 of 336 imaged pedicles (pedicle breach grades: 91.1% grade 1; 8.6% grade 2; and 0.3% grade 3). Mean fluoroscopy time was 29.3 seconds.

Conclusion. MOTLIF is a safe and effective minimally invasive technique with a high fusion rate. It allows accurate pedicle screw placement by a freehand technique. By eliminating biplanar fluoroscopy, it helps reduce radiation exposure. This is the largest published report of mini-open TLIF to date.**Key words:** facetectomy, fusion, local autograft, lumbar spine, minimally invasive, mini-open fusion, pedicle screws, radiation exposure, screw placement accuracy, spondylolisthesis, transforaminal lumbar interbody fusion.**Level of Evidence:** 4**Spine 2016;41:E1124–E1130**

From the Houston Microneurosurgery, Houston, TX.

Acknowledgment date: September 24, 2014. First revision date: November 8, 2015. Second revision date: December 8, 2015. Acceptance date: February 10, 2016.

The device (s)/drug (s) is/are FDA-approved or approved by corresponding national agency for this indication.

No funds were received in support of this work.

Relevant financial activities outside the submitted work: consultancy, patents.

This is an open-access article distributed under the terms of the Creative Commons Attribution-Non Commercial-No Derivatives License 4.0, where it is permissible to download and share the work provided it is properly cited. The work cannot be changed in any way or used commercially.

Address correspondence and reprint requests to Peyman Pakzaban, MD, Houston Microneurosurgery, 5388 Lynbrook Drive, Houston, TX 77056; E-mail: Pakzaban@live.com

DOI: 10.1097/BRS.0000000000001510

E1124 www.spinejournal.com

Mini-open transforaminal lumbar interbody fusion (oTLIF), as described by Mummanemi,¹ is a minimally invasive fusion technique that utilizes expandable tubular retractors to permit insertion of pedicle screws and TLIF implants under direct vision. Unlike percutaneous TLIF (pTLIF),^{2–9} there is no need for placement of K-wires, cannulated pedicle screws, or biplanar fluoroscopy, thus making the technique more accessible to surgeons who are accustomed to open instrumented fusion.

Although good clinical and radiographic results have been reported with oTLIF,^{1,10–15} the accuracy of freehand pedicle screw placement through such limited exposures has not been assessed.

Here we describe a modification of oTLIF, named modified mini-open transforaminal lumbar interbody fusion (MOTLIF), in which we have assessed the accuracy of freehand pedicle screw placement guided by direct visualization of anatomical landmarks, lateral fluoroscopy, and electrophysiological monitoring. MOTLIF differs from oTLIF with regard to the location of the skin incision, the trajectory of the surgical corridor, exposure of bone anatomy by direct dissection rather than muscle dilatation, *en bloc* resection of facet processes, and reliance only on

local autograft and bone extenders. The MOTLIF surgical technique is presented in detail.

PATIENTS AND METHODS

Patients

Ninety-two consecutive patients who had undergone one-level MOTLIF procedures by a single surgeon between 2008 and 2012 were studied retrospectively. Indications for fusion included degenerative or isthmic spondylolisthesis (Meyerding grade I or II) with radiculopathy, symptomatic foraminal stenosis associated with disc degeneration and retrolisthesis, or multiple recurrent disc herniations. All patients had lumbar radiculopathy and back pain refractory to conservative treatment and were required to quit smoking if they were smokers.

Assessment

Patient evaluation included completion of pain and disability questionnaires preoperatively and at 6 and 24 months postoperatively. Dynamic radiographs were performed preoperatively, at 3 and 6 months postoperatively, and at 6-month intervals thereafter, until fusion was achieved. Computed tomography (CT) of the lumbar spine was scheduled at 12 months postoperatively to assess fusion. Statistical analysis was performed by a one-way ANOVA.

Accuracy of pedicle screw placement was assessed retrospectively from the available CT data with respect to presence and extent of breach of pedicle wall, according to a modification of previously published criteria,^{16–18} as outlined in Table 1 and Figure 1 (A–D). Screws breaching the lateral pedicle wall more than 2 mm and providing poor bone purchase (grade 3) or screws breaching the medial wall greater than 2 mm or causing neurological symptoms (grade 4) would be considered poorly-placed.

Grading of interbody and posterolateral fusion on CT was performed according to a modification of previously published criteria,^{19,20} as outlined in Table 2. Successful radiographic fusion was defined as CT grade 1 (Figure 2A–C). Acceptable fusion was defined as CT grade 2 with less than 5 degrees of angulation and no translation on dynamic radiographs. Failure of fusion was defined as CT grade 3 and/or

greater than 5 degrees of angulation or greater than 2 mm of translation on dynamic radiographs.

Surgical Technique

The MOTLIF surgical technique is demonstrated in detail in Video, Supplemental Digital Content 1, <http://links.lww.com/BRS/B121>.

Exposure

A small skin incision was made in the parasagittal plane between the centers of adjacent pedicles and extended through the lumbar fascia. Rather than using tubular dilators, the attachments of the multifidus muscle to the underlying bone were directly visualized under magnification (with loupes or microscope), bipolar coagulated and cut to expose the facet joint and the pars. This step prevented subsequent muscle creep into the field of view. An expandable miniopen retractor (Spyder retractor by Aesculap Implant Systems, USA) was then inserted. At the end of the procedure, the lumbar fascia and the underlying investing fascia of the multifidus were closed but no attempt was made to suture the muscle fibers together.

Decompression

An *en bloc* facetectomy was carried out to expose the exiting and traversing nerve roots and to provide large amounts of bone graft material. To perform this, the lateral aspect of the *pars interarticularis* was first identified by the characteristic concavity along its lateral margin. A drill equipped with a diamond burr or an ultrasonic bone scalpel was used to make a transverse cut across the *pars*, joined by a vertical cut along the lateral aspect of the lamina (Figure 3). The inferior articular process was mobilized and removed. Next, the superior articular process of the caudal vertebra was amputated flush with its pedicle and removed to obtain a pedicle-to-pedicle exposure. The lateral extension of *ligamentum flavum* was resected to expose the traversing and exiting nerve roots and the lateral dural margin. A wide annulotomy and a thorough discectomy were performed.

TLIF

The bone yielded by the *en bloc* facetectomy was decorticated with a cutting burr and decimated for interbody

TABLE 1. Grading of Pedicle Screw Placement Accuracy

Pedicle Breach Grade	Pedicle Breach Description	Number of Screws	% of Screws
1	0–2 mm breach of pedicle wall	306	91.1
2	>2 mm lateral breach but acceptable bone purchase	29	8.6
3	>2 mm lateral breach with insufficient bone purchase	1	0.3
4	>2 mm medial breach of pedicle wall or screw-associated neurological symptoms	0	0

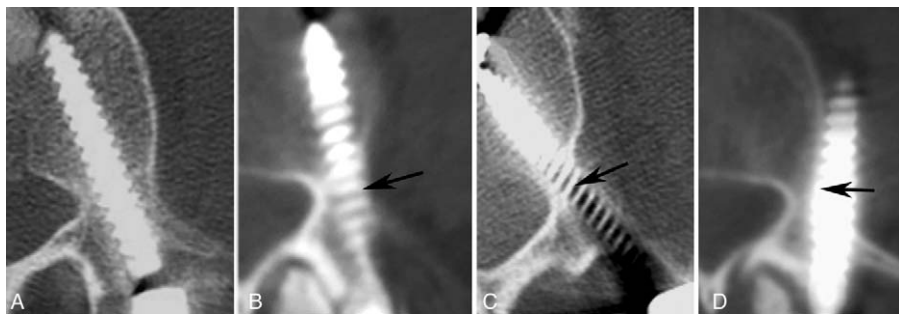


Figure 1. Representative CT images of various grades of pedicle screw placement accuracy. (A) Grade 1a, no breach. (B) Grade 1b, less than 2 mm lateral breach. (C) Grade 2, greater than 2 mm of lateral breach but adequate bone purchase. (D) Grade 3, greater than 2 mm of lateral breach and poor bone purchase. Arrows delineate lateral pedicle margin.

fusion. Any overhang of the posterior margin of the endplates over the disc space was resected. If the disc space was too narrow to accept an implant, contralateral pedicle screws were inserted and used for disc distraction whereas an osteotome inside the disc space wedged apart the endplates. A banana-shaped PEEK implant was packed with facet bone, and positioned in the disc space under lateral fluoroscopy. The remaining volume of the disc space lateral and posterior to the implant was packed with facet bone pieces. A small piece of beta tricalcium phosphate bone substitute (ChronOS by Synthes, USA) was wedged under the annulus to keep the bone pieces in place. After pedicle screw insertion, the transverse processes lateral to the screw heads were decorticated and covered with strips of the abovementioned bone substitute, impregnated with bone marrow aspirate obtained through a pedicle. If any local autograft remained from the resected facet, it was added to the posterolateral fusion mass.

Pedicle Screw Insertion and Spondylolisthesis Reduction

Bilateral pedicle screw insertion was performed in all cases by a freehand technique using noncannulated screws with extension tabs (S4 screws by Aesculap Implant Systems, USA) exactly as in an open fusion (Figure 4). The exposed margins of the pedicles and the adjacent nerves roots were directly visualized and/or palpated throughout the insertion process that involved drilling a pilot hole, pedicle probing, tapping, and screw insertion. Electrophysiological

monitoring and lateral fluoroscopy were used, but AP fluoroscopy was not used.

In many instances, grade I spondylolisthesis was found to have spontaneously reduced after facetectomy and TLIF. To reduce residual spondylolisthesis, the persuasion capabilities of the threaded extension tabs of the screws were used. A straight rod was first affixed to the caudal screw head such that its cranial end sat proud of the cranial screw head. The cranial screw was then persuaded back toward the fixed rod as the set screw was tightened in screw head's extension tab. In cases of grade II spondylolisthesis or narrow disc spaces, spondylolisthesis reduction was performed on the contralateral side before ipsilateral TLIF implant insertion. The contralateral side was handled either by a MOTLIF exposure with facetectomy (when contralateral decompression was needed) or MOTLIF exposure with facet decortication and fusion. Bilateral posterolateral fusion was performed in all cases.

RESULTS

The characteristics of the patient population, the indications for fusion, and clinical outcomes are summarized in Table 3. Of the 92 patients in this series, 40 (43.5%) were males and 52 (56.5%) were females. The mean age was 53 years (range 32–75 yrs). The indications for surgery are summarized in Table 3 and consisted mostly of spondylolisthesis (70.7%).

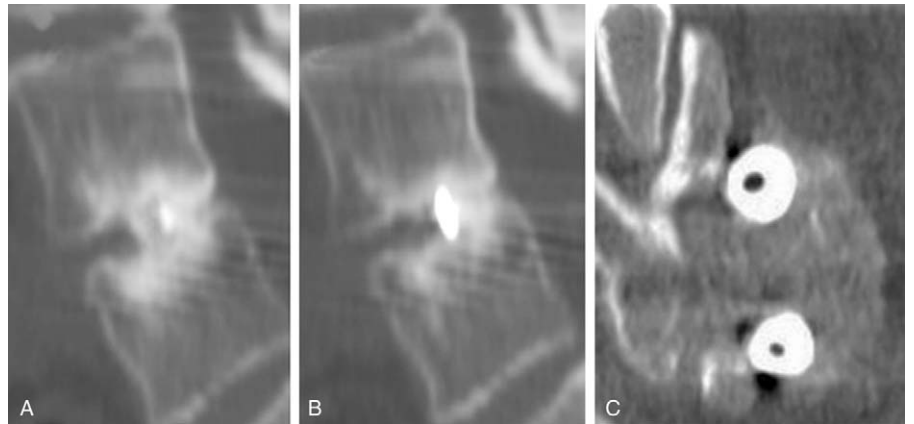Mean operating time was 148 minutes (range 111–182 min). Mean fluoroscopy time was 29.3 seconds (21.5–40.2 s). Mean hospital stay was 1.2 days (range 1–3 ds). Mean estimated blood loss was 65.2 mL (range 30–100 mL).

Mean follow-up was 35 months with a minimum follow-up of 2 years. At 6 months postoperatively, mean Visual Analog Scale (VAS) for back pain improved from 51 (range 20–100) to 19 (range 5–40), mean VAS for leg pain had improved from 58 (range 25–100) to 17 (range 0–35), and the mean ODI had improved from 53 (range 37–83) to 16 (range 5–29). Three patients were lost to follow-up after the 6-month time point. At 2 years postoperatively, the mean scores were: VAS-back (21; range 6–43), VAS-leg (16; range 0–36), and ODI (13; range 4–26). The differences between 6-month and 2-year scores were not statistically significant, but the differences between preoperative scores and both postoperative time points were significant ($P < 0.01$).

No instances of neurological worsening occurred. Three patients (3.2%) had incidental durotomies that were

Grade	Fusion Criteria
1	Bridging interbody bone through or around the cage and/or bridging posterolateral fusion mass
2	Incomplete bridging of interbody bone and posterolateral fusion mass with presence of radiolucent line(s) but no evidence of screw loosening
3	Resorption of interbody and posterolateral fusion mass and/or radiolucent halo around screws

Figure 2. CT reconstructions demonstrating a Grade 1 fusion. Sagittal reconstructions show bridging bone within (A) and behind (B) the TLIF implant and coronal reconstructions (C) show bridging posterolateral fusion mass surrounding the pedicle screws.



repaired intraoperatively: None had a postoperative cerebrospinal fluid leak. Five patients (5.4%) had wound erythema, which was treated with oral and topical antibiotics. One patient (1.1%) had a deep wound infection, which was successfully treated surgically with debridement and 4 weeks of intravenous antibiotic therapy without removal of the hardware. No patient required a blood transfusion.

Eighty-four (91.3%) of the 92 patients had a follow-up CT at 12 to 15 months after surgery. The reasons for failing to have a follow-up CT consisted of insurance refusal because of lack of justifying symptoms (3 patients), patient refusal caused by absence of symptoms (2 patients), and inability to reach the patient to schedule CT (3 patients). In the 84 patients who had CT, solid fusion (CT grade 1) was achieved in 74 patients (88.1%). Within this group (CT grade 1), all patients had bridging interbody bone, but only 72% had bridging posterolateral bone. An additional 6 patients had acceptable fusion (CT grade 2 with less than 5 degrees of angulation and no translation on dynamic radiographs),

yielding a satisfactory fusion rate of 95.2%. None of these patients developed hardware loosening during the minimum 2-year follow-up period. All of the patients who did not have a CT had satisfactory fusion by dynamic radiographic criteria

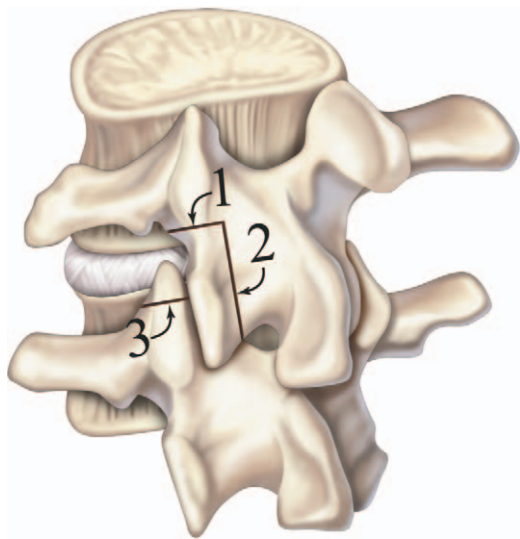


Figure 3. Artist's representation of *en bloc* facetectomy. A transverse cut (1) across the *pars* is joined with a second cut (2) along the lateral margin of the lamina. After removing the inferior articular process, a third cut (3) amputates the superior articular process. ©2010 Anatomical Justice, LLC.

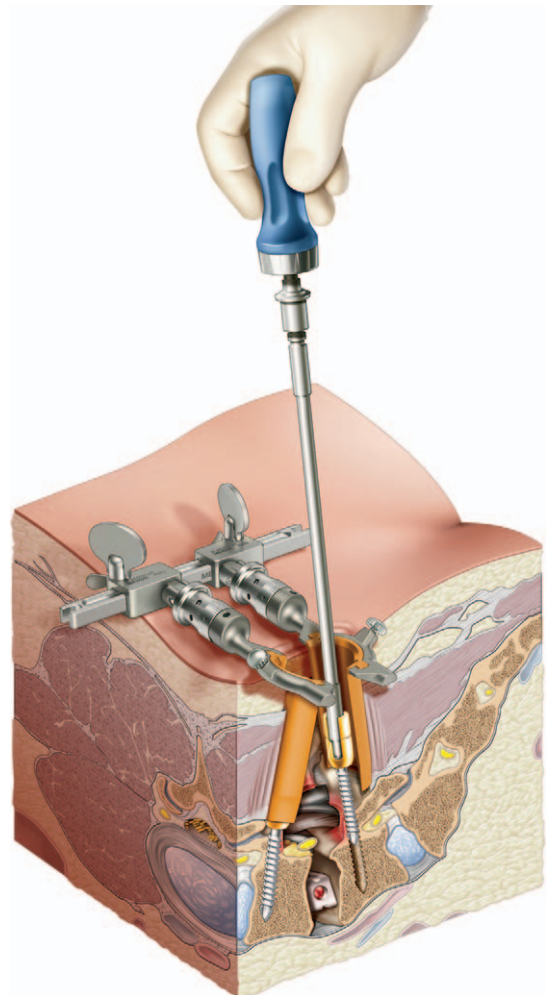


Figure 4. Artist's representation of freehand pedicle screw insertion under direct vision in a MOTLIF procedure. A complete facetectomy has provided exposure of the margins of the pedicles and the adjacent nerve roots, permitting insertion of pedicle screws without the need for K-wires or biplanar fluoroscopy. ©2010 Anatomical Justice, LLC.

TABLE 3. Patient Demographics, Indications, and Clinical Results

Number of patients	92
Mean age (range)	53 yrs (32–75)
Sex	
Male (%)	40 (43.5)
Female (%)	52 (56.5)
Indications for fusion (number, %)	
Spondylolisthesis	65 (70.7)
Degenerative	46 (50.0)
Isthmic	19 (20.7)
Spondylolisthesis grade	
Grade I	51 (55.4)
Grade II	14 (15.2)
Retrolisthesis with foraminal stenosis	22 (23.9)
Multiple recurrent disc herniations	5 (5.4)
MOTLIF level (number, %)	
L5–S1	33 (35.9)
L4–5	45 (48.9)
L3–4	13 (14.1)
L2–3	1 (1.1)
Mean operating time (range)	148 min (111–182)
Mean fluoroscopy time (range)	29.3 s (21.5–40.2)
Mean hospital stay (range)	1.2 d (1–3)
Estimated blood loss (range)	65.2 mL (30–100)
Mean follow-up (range)	35 mo (24–42)
Back pain	
Mean preoperative VAS (range)	51 (20–99)
Mean 6-month postoperative VAS (range)	19 (5–40)
Mean 2-year postoperative VAS (range)	21 (6–43)
Leg pain	
Mean preoperative VAS (range)	58 (25–99)
Mean 6-month postoperative VAS (range)	17 (0–35)
Mean 2-year postoperative VAS (range)	16 (0–36)
Disability	
Mean preoperative ODI (range)	53 (37–83)
Mean 6-month postoperative ODI (range)	16 (5–29)
Mean 2-year postoperative ODI (range)	13 (4–26)
ODI indicates; VAS, Visual Analog Scale	

on last follow-up. Overall, 4 of the 92 patients (4.3%) had fusion failure requiring revision.

Data pertaining to the accuracy of freehand pedicle screw placement is presented in Table 1. Of the 336 pedicle screws that were CT-imaged in this study, 306 (91.1%) were grade 1 insertions and 26 (8.6%) were grade 2. Only one patient had an unacceptable laterally-placed screw (grade 3), which

required revision. No screws were inserted too medially into the spinal canal and no patient had a neurological deficit related to screw placement (grade 4).

DISCUSSION

A successful minimally invasive fusion operation is one in which none of the surgical objectives are compromised because of lack of exposure. These objectives include satisfactory decompression of the spinal canal and neural foramina, thorough evacuation and preparation of disc space for TLIF, insertion of an appropriately-sized TLIF implant, safe and accurate pedicle screw insertion, and anatomical spondylolisthesis reduction. Although good results have been reported with percutaneous TLIF through nonexpandable tubes (p-TLIF, also known as MI-TLIF for minimally invasive TLIF),^{2–9} some of these studies rely on the use of bone morphogenic protein (BMP) to augment fusion rates. Mini-open TLIF (oTLIF and its variations) performed through expandable retractors offers superior exposure compared with p-TLIF.^{1,10,13} Yet in many reported mini-open approaches, surgeons still rely on biplanar fluoroscopy for K-wire and cannulated pedicle screw insertion and use BMP for fusion.

We believe that the modified technique presented here enhances the exposure and eliminates the problems with muscle creep into the field of view that hamper other techniques. The enhanced exposure in MOTLIF facilitates identification of anatomical landmarks for pedicle screw insertion and allows accurate insertion of noncannulated pedicle screws by a freehand technique. The need for biplanar fluoroscopy is eliminated, reducing radiation exposure and making the technique more accessible to surgeons unfamiliar with percutaneous technique. The improved exposure is obtained by modifying the location of the skin incision and the approach corridor and performing a systematic *en bloc* facetectomy.

All previous description of mini-open and percutaneous TLIF have relied on making the skin incisions lateral to the pedicles and following the natural cleavage plane between the multifidus and longissimus muscles.^{1–15,21} There are two problems with this approach. First and most important, the intermuscular Wiltse approach always directs the surgical corridor too far laterally, as dictated by the muscular anatomy,^{22–26} requiring the surgeon to tilt the retractor medially and fight the mass of the multifidus muscle between the retractor and the spinous process. The multifidus muscle fascicles traverse obliquely from each spinous process to the superior articular process of the vertebra two levels below.²³ The longissimus fascicles attach to the medial aspect of the transverse process.²³ As a result of this anatomical arrangement, the intermuscular cleavage plane always leads to the lateral aspect of the facet joint, between the superior articular process and transverse process. When Wiltse first described this approach in 1973, he intended its use for posterolateral not interbody fusion.²⁵ Second, the multifidus muscle is thick near the sacrum and gradually thins as it extends cranially.²⁵ As a result, the location of the intermuscular cleavage plane is variable (more medial in the

more cranial segments), thus making it difficult to find the dissection plane through skin incisions that are made at an arbitrary distance from the midline.

To overcome these difficulties, in MOTLIF the skin incision is made precisely in the parasagittal plane bisecting the pedicles and a transmuscular surgical corridor is developed through the multifidus muscle to center the exposure on the facet joint. We have found that the transmuscular corridor provides superior exposure for facetectomy, lateral recess decompression, and TLIF, whereas still providing good exposure for pedicle screw insertion and intertransverse fusion. Furthermore, the retractor remains stable in the wound in vertical orientation, does not need to be tilted medially, and is not constantly displaced by the medial mass of the multifidus muscle. Because the retractor is not attached to the table at a fixed angle, it readily “floats” over the target whereas maintaining the exposure, thus facilitating the introduction of implant inserters and screwdrivers at optimal trajectories.

Another feature that distinguishes it from oTLIF and pTLIF is that MOTLIF does not rely on tubular dilators. The musculotendinous attachments of the multifidus to the facet joint are too strong to be detached by tubular dilators. In MOTLIF, these attachments are visualized under magnification, bipolar-coagulated, and cut flush with the bone before insertion of the expandable retractor, providing superior exposure and stable retractor placement.

In MOTLIF, the facet joint is resected *en bloc*. This technique yields large pieces of cortico-cancellous bone from the hypertrophic articular processes that can be thoroughly cleared of their soft tissue attachments and used for fusion. By contrast, piecemeal facetectomy with drills and rongeurs wastes bone and yields a low-quality fusion substrate contaminated with soft tissue attachments. In the current study, high fusion rates were achieved with local autograft, comparable with studies that relied on the use of BMP or iliac crest bone graft.^{1–15,21} The cost and potential complications associated with the use of BMP are well-known^{19,20,27–30} and are best avoided, if possible.

The use of stereotactic navigation and intraoperative computed tomography to enhance the accuracy of minimally invasive pedicle screw placement and reduce radiation exposure has been extensively described.^{16–18,31–34} In the current study, we have demonstrated highly accurate pedicle screw placement by freehand technique without image guidance. We relied only on lateral fluoroscopy, which reduces radiation exposure compared to biplanar fluoroscopy. Our mean fluoroscopy time of 29.3 seconds compares favorably with other studies that report means times ranging from 38.7 seconds to 3.7 minutes for one-level operations.^{35–38} Recently, a low-dose radiation protocol has been described that combines direct exposure and visualization of pedicle landmarks and avoidance of biplanar fluoroscopy (as in our technique) with pulsed low-dose fluoroscopy (that produces lower resolution images) to push mean fluoroscopy time to 10.4 seconds.³⁹

In conclusion, MOTLIF differs from oTLIF in that it uses a transmuscular surgical corridor, requires manual detachment of multifidus from the underlying bone, and relies on an *en bloc* facetectomy to achieve decompression and provide high-quality local autograft. High fusion rates were achieved without the use of BMP or iliac crest autograft. The MOTLIF exposure allowed highly accurate pedicle screw placement by a freehand technique. It avoids biplanar fluoroscopy, thereby reducing radiation exposure. MOTLIF is a safe and effective minimally invasive technique, which may appeal to spine surgeons who are proficient in microsurgery but unfamiliar with percutaneous techniques. This represents the largest published report of mini-open TLIF and its variations to date.

➤ Key Points

- ❑ A modified technique for oTLIF is presented in detail.
- ❑ MOTLIF provides good exposure for interbody fusion and freehand pedicle screw insertion.
- ❑ Good clinical results and high fusion rates were achieved with use of local autograft from *en bloc* facetectomy.
- ❑ Highly accurate pedicle screw placement was achieved by a freehand technique. Biplanar fluoroscopy was avoided and low fluoroscopy times were recorded.
- ❑ This minimally invasive technique may appeal to surgeons who are proficient in microsurgery but unfamiliar with percutaneous techniques.

Supplemental digital content is available for this article. Direct URL citations appearing in the printed text are provided in the HTML and PDF version of this article on the journal’s Web site (www.spinejournal.com).

References

1. Mummaneni PV, Rodts GE Jr. The mini-open transforaminal lumbar interbody fusion. *Neurosurgery* 2005;57(4 Suppl):256–61.
2. Khoo LT, Palmer S, Laich DT, et al. Minimally invasive percutaneous posterior lumbar interbody fusion. *Neurosurgery* 2002;51(5 Suppl):S161–6.
3. Schwender JD, Holly LT, Rouben DP, et al. Minimally invasive transforaminal lumbar interbody fusion (TLIF): technical feasibility and initial results. *J Spinal Disord Tech* 2005;18 (suppl): S1–6.
4. Park P, Foley K. Minimally invasive transforaminal lumbar interbody fusion with reduction of spondylolisthesis: technique and outcomes after a minimum of 2 years’ follow-up. *Neurosurg Focus* 2008;25:E16.
5. Holly L, Schwender J, Rouben D, et al. Minimally invasive transforaminal lumbar interbody fusion: indications; technique; and complications. *Neurosurg Focus* 2006;20:E6.
6. Ringel F, Stoffel M, Stuer C, et al. Minimally invasive transmuscular pedicle screw fixation of the thoracic and lumbar spine. *Neurosurgery* 2006;59(4 suppl 2):361–6.
7. Ozgur B, Yoo K, Rodriguez G, et al. Minimally-invasive technique for transforaminal lumbar interbody fusion (TLIF). *Eur Spine J* 2005;14:887–94.

8. Scheufler KM, Dohmen H, Vougioukas VI. Percutaneous transforaminal lumbar interbody fusion for the treatment of degenerative lumbar instability. *Neurosurgery* 2007;60 (4 suppl 2):203–12.
9. Habib A, Smith ZA, Lawton CD, et al. Minimally invasive transforaminal lumbar interbody fusion: a perspective on current evidence and clinical knowledge. *Minim Invasive Surg* 2012; doi:10.1155/2012/657342.
10. Dhall SS, Wang MY, Mummaneni PV. Clinical and radiographic comparison of mini-open transforaminal lumbar interbody fusion with open transforaminal lumbar interbody fusion in 42 patients with long-term follow-up. *J Neurosurg Spine* 2008;9:560–5.
11. Peng CW, Yue WM, Poh SY, et al. Clinical and radiological outcomes of minimally invasive versus open transforaminal lumbar interbody fusion. *Spine (Phila Pa 1976)* 2009;34:1385–9.
12. Wu RH, Fraser JF, Hartl R. Minimal access versus open transforaminal lumbar interbody fusion: meta-analysis of fusion rates. *Spine (Phila Pa 1976)* 2010;35:2273–81.
13. Lee DY, Jung TG, Lee SH. Single-level instrumented mini-open transforaminal lumbar interbody fusion in elderly patients. *J Neurosurg Spine* 2008;9:137–44.
14. Scarone P, Lepeintre JF, Bennis S, et al. Two-levels mini-open transforaminal lumbar interbody fusion: technical note. *Minim Invasive Neurosurg* 2009;52:275–80.
15. Rodriguez-Vela J, Lobo-Escolar A, Joven-Aliaga E, et al. Perioperative and short-term advantages of mini-open approach for lumbar spinal fusion. *Eur Spine J* 2009;18:1194–201.
16. Idler C, Rolfe KW, Gorek JE. Accuracy of percutaneous lumbar pedicle screw placement using the oblique or “owl’s-eye” view and novel guidance technology. *J Neurosurg Spine* 2010;13:509–15.
17. Wood MJ, Mannion RJ. Improving accuracy and reducing radiation exposure in minimally invasive lumbar interbody fusion. *J Neurosurg Spine* 2010;12:533–9.
18. Youkilis AS, Quint DJ, McGillicuddy JE, et al. Stereotactic navigation for placement of pedicle screws in the thoracic spine. *Neurosurgery* 2001;48:771–8.
19. Carter JD, Swearingen AB, Chaput CD, et al. Clinical and radiographic assessment of transforaminal lumbar interbody fusion using HEALOS collagen-hydroxyapatite sponge with autologous bone marrow aspirate. *Spine J* 2009;9:434–8.
20. Glassman S, Carreon L, Djurasovic M, et al. Posterolateral lumbar spine fusion with INFUSE bone graft. *Spine J* 2007;7:44–9.
21. Bagan B, Patel N, Deutsch H, et al. Perioperative complications of minimally invasive surgery (MIS): comparison of MIS and open interbody fusion techniques. *Surg Technol Int* 2008;17:281–6.
22. Fujibayashi S, Neo M, Takemoto M, et al. Paraspinal-approach transforaminal lumbar interbody fusion for the treatment of lumbar foraminal stenosis. *J Neurosurg Spine* 2010;13:500–8.
23. Hoh DJ, Wang MY, Ritland SL. Anatomic features of the paramedian muscle-splitting approaches to the lumbar spine. *Neurosurgery* 2010;66:13–25.
24. Vialle R, Wicart P, Drain O, et al. The Wiltse paraspinal approach to the lumbar spine revisited: an anatomic study. *Clin Orthop Relat Res* 2006;445:175–80.
25. Wiltse L. The paraspinal sacrospinalis-splitting approach to the lumbar spine. *Clin Orthop Relat Res* 1973;91:48–57.
26. Wiltse L, Bateman J, Hutchinson R, et al. The paraspinal sacrospinalis-splitting approach to the lumbar spine. *J Bone Joint Surg Am* 1968;50:919–26.
27. Cahill KS, Chi JH, Day A, et al. Prevalence, complications, and hospital charges associated with use of bone-morphogenetic proteins in spinal fusion procedures. *JAMA* 2009;302:58–66.
28. Chen N-F, Smith ZA, Stiner E, et al. Symptomatic ectopic bone formation after off-label use of recombinant human bone morphogenetic protein-2 in transforaminal lumbar interbody fusion. *J Neurosurg Spine* 2010;12:40–6.
29. Ghogawala Z, Benzel EC, Schlenk RP. BMP: A case for evidence and for common sense. *Congress Quarterly* 2010;11:16–7.
30. Kaiser MG, Groff MW, Watters WC, et al. Guideline update for the performance of fusion procedures for degenerative disease of the lumbar spine. Part 16: bone graft extenders and substitutes as an adjunct for lumbar fusion. *J Neurosurg Spine* 2014;21:106–32.
31. Bydon M, Xu R, Amin AG, et al. Safety and efficacy of pedicle screw placement using intraoperative computed tomography: consecutive series of 1148 pedicle screws. *J Neurosurg Spine* 2014;21:320–8.
32. Kim TT, Drazin D, Shweikeh F, et al. Clinical and radiographic outcomes of minimally invasive percutaneous pedicle screw placement with intraoperative CT (O-arm) image guidance navigation. *Neurosurg Focus* 2014;36:E1.
33. Rivkin MA, Yocom SS. Thoracolumbar instrumentation with CT-guided navigation (O-arm) in 270 consecutive patients: accuracy rates and lessons learned. *Neurosurg Focus* 2014;36:E7.
34. Shin BJ, Njoku IU, Tsiouris AJ, et al. Navigated guide tube for the placement of mini-open pedicle screws using stereotactic 3D navigation without the use of K-wires: technical note. *J Neurosurg Spine* 2013;18:178–83.
35. Fan G, Fu Q, Gu G, et al. Radiation exposure to surgeon in minimally invasive transforaminal lumbar interbody fusion with novel spinal locators. *J Spinal Disord Tech* 2015;28: E173–180.
36. Funao H, Ishii K, Momoshima S, et al. Surgeons’ exposure to radiation in single- and multi-level minimally invasive transforaminal lumbar interbody fusion; a prospective study. *PLoS One* 2014;9:e95233.
37. Grelat M, Zairi F, Quidet M, et al. Assessment of the surgeon radiation exposure during a minimally invasive TLIF: Comparison between fluoroscopy and O-arm system. *Neurochirurgie* 2015; 61:255–9.
38. Kim CW, Lee YP, Taylor W, et al. Use of navigation-assisted fluoroscopy to decrease radiation exposure during minimally invasive spine surgery. *Spine J* 2008;8:584–90.
39. Tumialan LM, Clark JC, Snyder LA, et al. Prospective evaluation of a low-dose radiation fluoroscopy protocol for minimally invasive transforaminal lumbar interbody fusion. *Operative Neurosurg* 2015;11:537–44.