

Application of lateral tarsoconjunctival flap to correct ocular complications of Madelung's disease

A case report and literature review

Lung-Chi Lee, MD^a, Tsu-Heng Weng, MD^a, Ke-Hao Huang, MD^{a,b}, Hsin-Ting Lin, MD^a, Chang-Min Liang, MD, PhD^a, Ming-Cheng Tai, MD^a, Jiann-Torng Chen, MD, PhD^a, Ke-Hung Chien, MD, PhD^{a,*}

Abstract

Rationale: Madelung's disease is a specific type of benign symmetric lipomatosis, which is characterized by overgrowing fat distributed at the neck and shoulder. This excessive fat accumulation may occur in different regions, including vital organs, such as the larynx, trachea, or the orbits. Surgery is usually performed to correct the esthetic or functional concern of the affected area. There are only few case reports mentioned about the orbital involvement of this disease. This study aimed to describe a case of Madelung's disease with ocular complications and the successful treatment using tarsoconjunctival flap.

Patient concerns: A 90-year-old obese male presented with decreased visual acuity accompanied with severe band form punctate epithelial erosions and ciliary injections in both eyes. Exophthalmos and ectropion of the lower eyelids were observed.

Diagnoses: Orbital computed tomography revealed a rare entity of Madelung's disease with significant massive deposits of lipomas located symmetrically around the orbit and neck region.

Interventions: Bilateral lateral tarsoconjunctival flaps with lateral tarsal strip procedures were performed to correct the lower eyelid ectropion-related exposure keratopathy.

Outcomes: The patient obtained improved visual acuity, intact and clear corneal surfaces, and perfect lower eyelid positions over both eyes.

Lessons: Madelung's disease is a rare condition. There are few reports to describe its ocular complications, due to lipoma overgrowing in the orbit. We shared our successful experience to correct ocular complications using tarsoconjunctival flap technique.

Abbreviations: γ -GT = gamma-glutamyl transpeptidase, BSL = benign symmetric lipomatosis, CT = computed tomography, FROD = fat-removal orbital decompression, GO = Grave's ophthalmopathy, MRI = magnetic resonance imaging.

Keywords: benign symmetric lipomatosis, ectropion repair, exophthalmos, Launois-Bensaude syndrome, Madelung's disease, orbital involvement, tarsoconjunctival flap

1. Introduction

Madelung's disease is characterized by multiple benign symmetric, nonencapsulated fat accumulations involving the neck, upper trunk, and various regions. The disease mostly affects men aged between 30 and 60 years, with a prevalence of approximately 1:25,000.^[1] The pathogenesis remains unclear, but it is closely

related to genetic predisposition with triggering factors, such as metabolic diseases and alcohol consumption, and has been reported to be associated with alcoholic liver dysfunction.^[2]

Madelung's disease is usually diagnosed clinically using computed tomography (CT) or magnetic resonance imaging (MRI). Patients with Madelung's disease may be at risk of serious complications caused by compression of the trachea and esophagus. There is no guideline for management; as such, treatment varies from disease presentation including lipectomies and/or liposuction.^[3] Herein, we present a case of Madelung's disease with rare orbital involvement with ocular complications of severe exposure keratopathy and subsequent successful surgical treatment using tarsoconjunctival flaps.

2. Case report

A 90-year-old obese Asian male patient presented with progressive redness of both eyes with tearing and blurry vision for several years. The patient's medical history was otherwise unremarkable, except long-term hypertension control. There was no known alcohol consumption problem.

Upon the first observation, the patient had a "bulldog's cheeks" appearance with deep nasolabial and marionette folds, accompanied by a prominent fat neck and buffalo hump

Editor: N/A.

The authors have no conflicts of interest to disclose.

^a Department of Ophthalmology, Tri-Service General Hospital, ^b Department of Ophthalmology, Songshan Branch of Tri-Service General Hospital, National Defense Medical Center, Taipei, Taiwan.

* Correspondence: Ke-Hung Chien, Department of Ophthalmology, Tri-Service General Hospital and National Defense Medical Center, Taipei 114, Taiwan (e-mail: yred8530@gmail.com).

Copyright © 2018 the Author(s). Published by Wolters Kluwer Health, Inc. This is an open access article distributed under the terms of the Creative Commons Attribution-Non Commercial-No Derivatives License 4.0 (CCBY-NC-ND), where it is permissible to download and share the work provided it is properly cited. The work cannot be changed in any way or used commercially without permission from the journal.

Medicine (2018) 97:42(e12864)

Received: 20 June 2018 / Accepted: 25 September 2018

<http://dx.doi.org/10.1097/MD.00000000000012864>

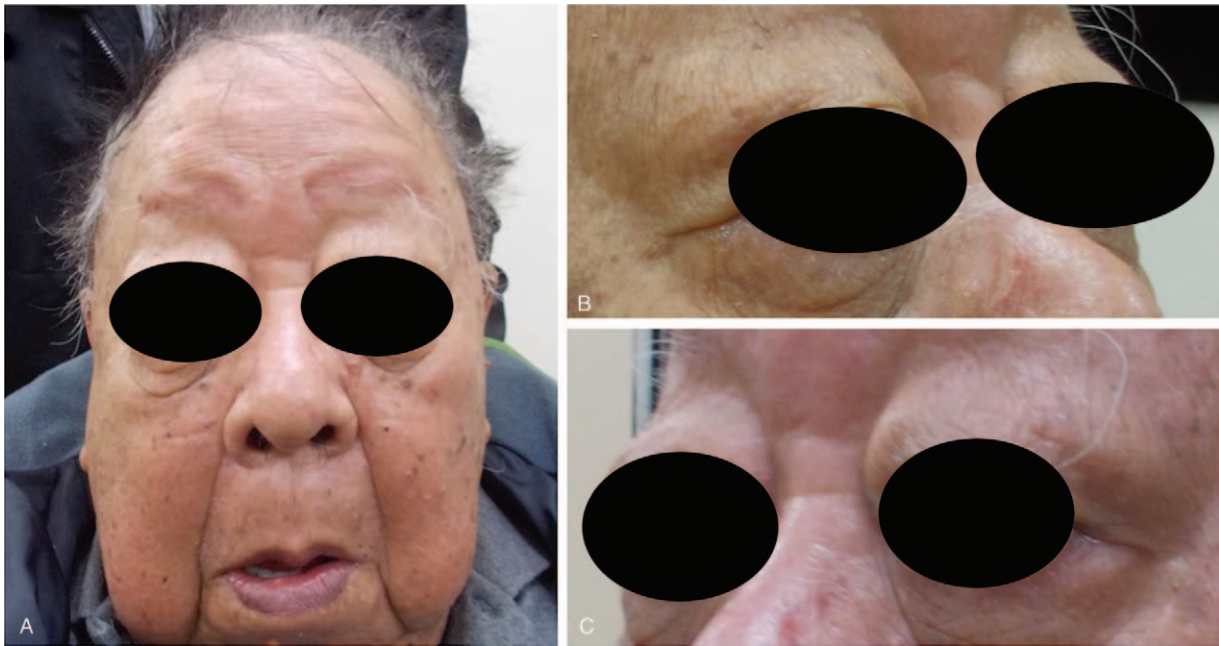


Figure 1. A 90-year-old man presented with progressive redness of both eyes with tearing and blurry vision for several years. Exophthalmos of both eyes with large lid bagging and moderate mid-face drop were eminent upon observation (A). Ectropion throughout the lower lids with inner tarsal conjunctiva show and severe band form punctate epithelial erosions over the lower third of the cornea in both eyes were noted (B and C).

(Fig. 1A), and a body mass index of 31.2 (weight 80 kg; height 160 cm). On ophthalmic examinations, the best corrected visual acuity was 6/60 with moderate cataract in both eyes. Exophthalmos of both eyes was evident on examination (Hertel value: OD: 26 mm, OS: 25 mm). Puffiness of both upper eyelids with ptosis was found (the marginal reflex distance 1 was 0 mm and levator muscle function was 10 mm, OU). Bilateral ectropion throughout the whole lower eyelids with the inner tarsal conjunctiva show accompanied with large lid bagging and moderate mid-face drop were the most significant findings. Severe band form punctate epithelial erosions with ciliary injections were noted over the lower third cornea of both eyes (Fig. 1B and C).

To exclude pathologic causes of proptosis including orbital tumor or thyroid-associated ophthalmopathy, orbital CT scan with contrast was done. Significant massive deposits of lipomas were located symmetrically around the orbit and neck region without abnormal enhancement, which raised the diagnosis of Madelung's disease (Fig. 2A and B). Prominent extraconal fat caused the protrusion of the orbital septum compatible with the large bagging of lower lid fat pad (Fig. 2C). Further, the excessive symmetric intraconal adipose tissue accumulation resulted in a bilateral grade 3 proptosis (the posterior sclera was located 3 mm anterior to the interzygomatic line^[4]) and stretching of the optic nerves and extraocular muscles (Fig. 2D). Additionally, the thyroid function test was obtained and revealed euthyroid status.

Therefore, under the impression of a rare entity of Madelung's disease with orbital involvement and subsequent ocular complications of lower eyelid ectropion-related severe exposure keratopathy, the patient underwent a single-stage operation of both eyes to correct the ectropion. The operation done under local anesthesia was constituted of 2 techniques: a lateral tarsoconjunctival flap procedure and a lateral tarsal strip procedure. First, a lateral tarso-conjunctival flap was created from the posterior lamellar of the upper eyelid; an 8-mm

horizontal incision starting from the lateral canthus was made 4 mm superior to the eyelid margin. The lateral tarsoconjunctival flap was then everted and secured to the epithelial denuded lower eyelid margin. Second, a lateral tarsal strip procedure was conducted for reinforcement of the significant lower eyelid laxity; a lateral canthotomy and inferior cantholysis was done prior to securing the lateral tarsoconjunctival flap to the lower eyelid margin. The excessive part of the lower eyelid was first trimmed and then reattached to the periosteum of the lateral orbital rim to reinforce the inferior orbicularis muscle.

One month after the surgery, the patient's visual acuity improved to 6/10 for both eyes. A clear and intact corneal surface with much less redness of the conjunctiva was observed under the slit-lamp biomicroscope (Fig. 3A and B). Perfect lower lid positions were also noted during opening and closing both of his eyes (Fig. 3C and D). The patient was pleased with the surgical results with great satisfaction.

The patient had signed an inform consent and approved all information and images being published. The institutional review board of Tri-Service General Hospital has waived the requirement for approving this single clinical case report from using all medical records associated, based upon their policy to review case report of more than 3 cases.

3. Discussion

Madelung's disease is named after the German surgeon Madelung,^[5] who described a disease of cervical lipomatosis in 1888. This disease entity was actually first described in 1846 by Brodie in his lecture notes^[6] and is also known as Launois-Bensaude syndrome, multiple symmetric lipomatosis, and more generally, as benign symmetric lipomatosis (BSL) in the literature.^[3] Differential diagnosis of the disease includes morbid obesity, Cushing syndrome, angiolipomatosis, neurofibromatosis, and liposarcoma.^[1]

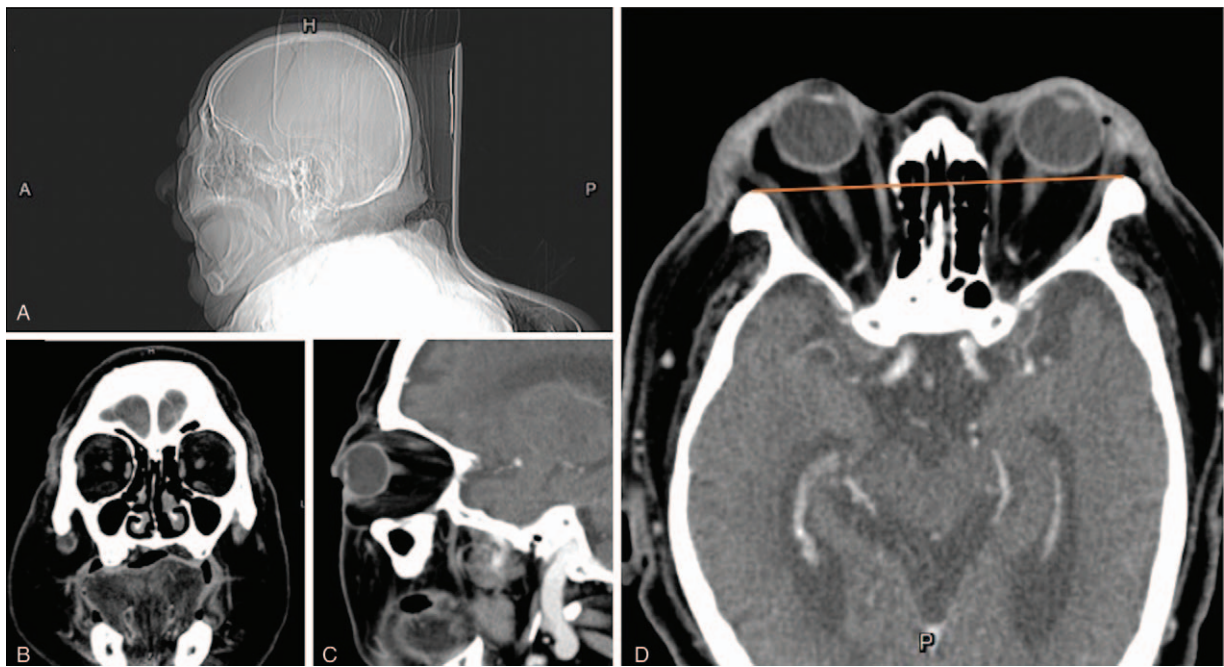

Figure 2. Orbital CT revealed significant massive deposits of lipomas located symmetrically around the orbit and neck region (A–D). The x-ray scan also showed buffy upper trunk figure (A). Coronal view (B) showed obvious subcutaneous fat and macrogloria. Sagittal view (C) showed prominent intra and extra-orbital fat causing the large bagging. Transverse view (D) also revealed significant intraconal fat causing a grade 3 proptosis and stretching of the optic nerve. The orange line is the interzygomatic line.

A classification proposed in 1991 based on the fat distribution pattern separated the diseases into 4 types: type I BSL (Madelung’s “fat neck”) affects the neck and submental region; type II BSL (pseudoathletic type) is localized at the shoulder girdle, upper arms and trunk; type III (gynecoid type) involves the

pelvic girdle; and type IV, was also named abdominal type.^[7] Most patients have combined types of fat accumulation patterns. In a case series of 59 patients with Madelung’s disease reported by Pinto et al,^[8] 50.9% of the patients have more than one subtype of BSL. Despite the disfiguring lipomatosis in different

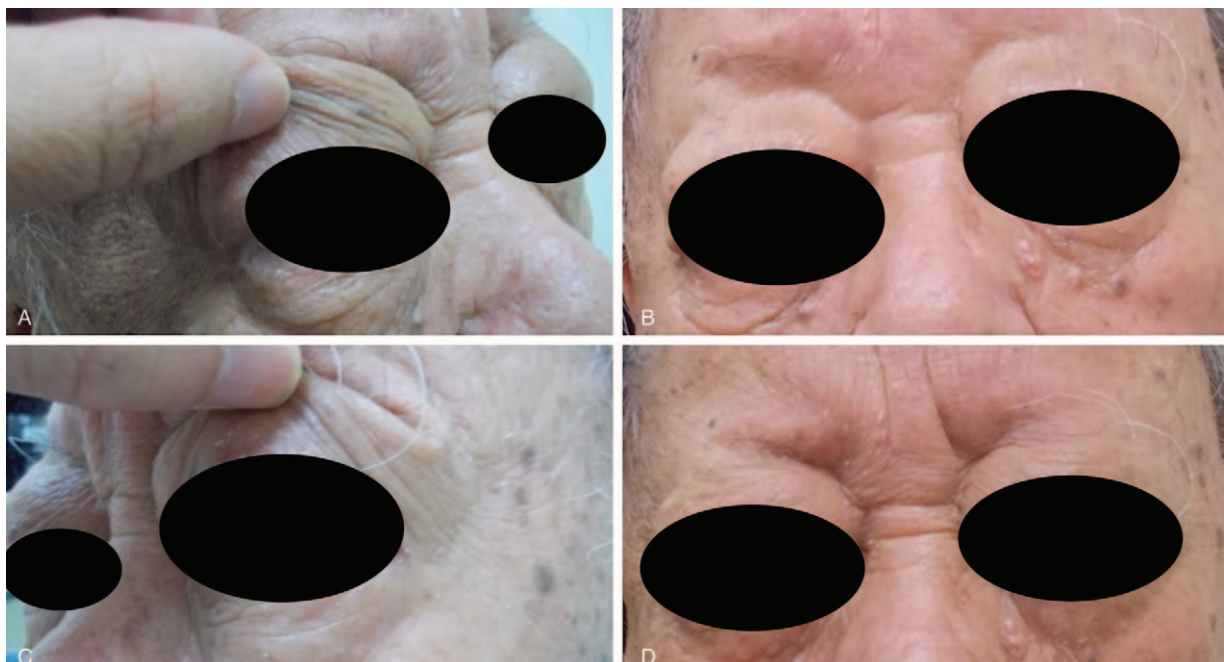


Figure 3. After bilateral lateral tarsal strip procedures, the lower eyelid ectropion-related exposure keratopathy was greatly improved (A and B). The patient was satisfactory with improved vision, intact corneal surface, and perfect lower lid positions (C and D).

Table 1**Cases of benign symmetric lipomatosis with orbital involvement in literature.**

Author (s), year	Age	Sex	BSL type	Alcohol consumption	Symptoms/Signs	Surgical treatment
Laure et al. ^[14] 2011	70	Male	I	Yes, alcohol abuse for 50 years	Bilateral proptosis with recurrent eyeball luxation	Bilateral orbital lipectomy with upper blepharoplasty for lipomatous exophthalmos and subsequent bilateral Kuhnt–Szymanowski procedure for lower lid ectropion
Subash et al. ^[15] 2012	49	Male	I	Denied, but markedly elevated γ -GT	Bilateral proptosis	Bilateral medial orbital wall decompression and fat excision for lipomatous exophthalmos
Lee et al, 2018, current article	90	Male	I	No	Bilateral proptosis with ectropion and severe exposure keratopathy	Bilateral lateral tarso-conjunctival flap with tarsal strip for lower lid ectropion

γ -GT = gamma-glutamyl transpeptidase, BSL = benign symmetric lipomatosis.

types of BSL, which is usually indicated for esthetic surgery, uncommon presentations have been documented in literature and may cause serious complications. Lingual^[9,10] and laryngeal involvements^[11–13] are rare localizations of this disease; affected patients may present with symptoms caused by compression of the trachea and esophagus, such as dysarthria, dysphagia, and obstructive sleep apnea.^[13] Orbital involvement is another rare localization of Madelung's disease that may theoretically cause severe ocular complications such as optic nerve compression and orbital compartment syndrome due to the overgrowing intraorbital fat.

Two prior case reports with orbital involvement were found in the literature (Table 1). The first case was reported in 2011 by Laure et al.^[14] He described a 70-year-old Caucasian male patient with bilateral symmetric proptosis and recurrent episodes of luxation of the eyeball for 2 years. The patient was diagnosed with Launois–Bensaude syndrome and had a 50-year history of alcohol abuse. The Hertel exophthalmometer value was 26 mm for both eyes. The vision of both eyes was not affected, and the remaining ophthalmic exam was insignificant, except for a right conjunctival fat herniation. Bilateral grade III proptosis with elongated optic nerve was seen on the orbital CT scan. After ruling out other etiologies, the proptosis was believed to be caused by lipomatous origin; eventually, the patient received a bilateral intra- and extraconal lipectomy accompanied with bilateral upper blepharoplasty. A subsequent bilateral Kuhnt–Szymanowski procedure was also carried out 12 days after surgery to correct a secondary bilateral lower lid ectropion.^[14]

Subash et al.^[15] described another case with similar presentations in 2012; a 49-year-old Russian man diagnosed with Madelung's disease 3 months prior presented with bilateral proptosis with Hertel value of 23 mm in both eyes. The patient denied excessive alcohol consumption history, but a markedly elevated gamma-glutamyl transpeptidase (γ -GT > 202) was noted. The visual acuity was normal with unremarkable ophthalmic examination. The CT scan of the orbit revealed symmetric orbital fat accumulation and straightening of both optic nerves. Owing to the stretching of the optic nerve, the patient eventually underwent an operation of bilateral medial wall decompression with orbital fat excision.^[15]

In our case, the diagnosis of Madelung's disease with orbital involvement is quite evident under imaging studies, especially after excluding dysthyroid eye disease. The severe exposure keratopathy was assumed to be caused by excessive proptosis

secondary to the overgrowth of the intraorbital fat. Hence, after ensuring that our patient's visual function was not threatened by the excessive intraorbital fat, we successfully performed one easy and efficient operation under local anesthetics to correct his lower eyelid malposition.

In general, management for BSL varies from different clinical concerns and disease presentations. Alcohol abstinence is generally advised under the concern of further disease progression. In contrast to obesity, exercise or diet control does not affect the fatty tissue proliferation in lipomatosis.^[2] Hence, surgical treatment such as lipectomies and/or liposuction is the mainstay therapy for BSL.^[2,8,16] In a large retrospective study published in 2017 involving 59 patients who underwent surgical treatment for Madelung's disease, an average of 4 surgeries were performed for each patient during a 10-year period, in which 39% of these patients still had disease recurrence.^[8] Overall, a total of 230 procedures were performed with 83.5% lipectomies, 13% liposuction alone, and 3.5% lipectomy combined with liposuction. These procedures were considered effective for relieving patient's esthetic concerns and motility issues.^[8]

A similar concept of fat removal surgery was introduced in 1988 by Olivari^[17] to treat orbital fat hypertrophy caused by Grave's ophthalmopathy (GO). Olivari's technique was utilized in Laure's case^[14] to treat the lipomatous exophthalmos. The procedure achieved a successful surgical result, with a total of 7 mm reduction of proptosis of both eyes.^[14] In Subash's case,^[15] orbital fat excision in conjunction with a medial wall decompression was done, which resulted in a 2-mm reduction of proptosis.

This fat-removal orbital decompression (FROD) technique has been reported to provide effective, safe, and promising results with low complication rate.^[18] In a large series published in 2007, Richter et al.^[19] concluded their 20-year experience of performing this technique over 3000 GO eyes. Most patients achieved significant improvements in ocular protrusion, visual acuity, diplopia, strabismus, retrobulbar pressure, and headache.^[19] A mean reduction of 5.9 mm with an average of 6.3 ml fat resection was observed from a 24.3 mm mean value of preoperative proptosis. A 15.6% complication rate (214 patients in 1374 patients) was reported, in which 89 patients with persistent diplopia required additional strabismus surgery and 19 patients had supraorbital nerve paresis that were attributed to intraoperative injuries.^[19] In another recently published large series conducted in Taiwan involving a total of 1604 GO eyes, all

patients received a 4.5 mL orbital fat resection with significantly correlated improvements of proptosis with an average 4.4 mm reduction from baseline (Hertel value: 21.1 mm).^[20] According to by Cheng et al., 85.1% of eyes achieved complete success with improvement and no recurrence, 13.7% had only partial success with new onset or persistent diplopia, and 1.2% failed to achieve surgical outcome. No complication was reported after these fat-removal surgeries. Interestingly, both series reported patients that underwent additional surgeries for eyelid retraction after FROD. In Cheng's series,^[20] 20.9% of patients underwent eyelid retraction surgery within 6 months, while an average of 2.5 lid surgeries were carried out for each patient in Richter's series.^[19]

In the presented case, FROD under general anesthesia was not deemed suitable, considering the added surgical risk due to patient's general condition and advanced age. Besides, unwanted post-FROD complications, such as new-onset strabismus, supraorbital nerve injuries or possible intraoperative uncontrollable hemorrhage, and postoperative intraorbital infection poses great threat to the patient's ocular health. Hence, we focused mainly on dealing with proptosis-related lower eyelid ectropion that causes severe symptomatic ocular surface problem using a simple time-sparing procedure under local anesthesia. The procedure of choice was constructed of a lateral tarsoconjunctival flap technique in conjunction with a lateral tarsal strip. This technique has been previously utilized to effectively treat eyelid malposition by Tao et al.^[21] in a large retrospective case series for a total of 110 patients with facial nerve paresis. All patients reported satisfactory static eyelid position with decreased lagophthalmos and great cosmetic effects. The only complication discussed was the diminished temporal visual field caused by the lateral tarsoconjunctival flap; this minor blemish could be easily reversed or titrated by sharp dissection of the medial portion of the flap under slit lamp biomicroscope. Interestingly, additional upward movement of the lower eyelid during lid closure was observed, related to an upward lift vectors transmitted from the fornix through supraduction caused by Bell's phenomenon. This added dynamic effect during lid closure provides great advantage in correcting eyelid ectropion, retraction, and lagophthalmos. Hence, the authors also advocated this technique with much experience in treating nonparalytic lower eyelid ectropion, caused by mid-face drop, cicatricial lid disorder, or globe protrusion, such as in the presented case.

Our results demonstrated the apparent efficacy of lateral tarsoconjunctival flaps with lateral tarsal strip procedures in this rather rare disease entity. However, given the limitation of our single case report and the rarity of orbital involved Madelung's disease, the medical choice was purely derived from our personal experience and may not be suitable for every patient scenario. A short follow-up period is another limitation in our study. Therefore, further study may need to include more cases and longer follow-up time to evaluate the long-term surgical outcomes of lateral tarsoconjunctival flaps with lateral tarsal strip procedures in these patients.

4. Conclusion

Madelung's disease is a rare but benign entity. Literature review showed different clinicopathologic findings caused by the lipomatosis, usually systemic presentations. However, physicians should note that local fat proliferation might occur and cause severe complication, such as airway compression in lingual or tracheal involvement. Orbital involvement in this disease is even

rarer. To our knowledge, this is the third case report that describes ocular complications due to fat overgrowing in the orbit. Two prior case reports utilized FROD to treat the hypertrophic intraorbital fat. Herein, we shared our experience in correcting ocular complications with one simple and safe procedure using tarsoconjunctival flap, which could be a treatment reference for ophthalmologists in the future.

Author contributions

Conceptualization: Jiann-Torng Chen, Ke-Hung Chien.
Data curation: Lung-Chi Lee, Ke-Hao Huang, Hsin-Ting Lin.
Formal analysis: Lung-Chi Lee, Ke-Hao Huang, Hsin-Ting Lin.
Investigation: Lung-Chi Lee, Ke-Hao Huang, Hsin-Ting Lin.
Methodology: Lung-Chi Lee.
Resources: Tzu-Heng Weng, Chang-Min Liang, Ming-Cheng Tai, Ke-Hung Chien.
Software: Chang-Min Liang.
Supervision: Tzu-Heng Weng, Chang-Min Liang, Ming-Cheng Tai, Jiann-Torng Chen, Ke-Hung Chien.
Validation: Tzu-Heng Weng, Ke-Hung Chien.
Writing – original draft: Lung-Chi Lee.
Writing – review & editing: Jiann-Torng Chen, Ke-Hung Chien.
 Lung-Chi Lee orcid: 0000-0003-4745-4088.

References

- Zeitler H, Ulrich-Merzenich G, Richter DF, et al. Multiple benign symmetric lipomatosis—a differential diagnosis of obesity. Is there a rationale for fibrate treatment? *Obes Surg* 2008;18:1354–6.
- Al Ghazal P, Grönemeyer L-L, Schön MP. Lipomatosen. *J Dtsch Dermatol Ges* 2018;16:313–27.
- Ujpal M, Németh ZS, Reichwein A, et al. Long-term results following surgical treatment of benign symmetric lipomatosis (BSL). *Int J Oral Maxillofac Surg* 2001;30:479–83.
- Fang Z-J, Zhang JY, He W-M. CT features of exophthalmos in Chinese subjects with thyroid-associated ophthalmopathy. *Int J Ophthalmol* 2013;6:146–9.
- Madelung, OW. Über den Fetthals (diffuses Lipom des Halses). *Langenbecks. Arch Klin Chir.* 1888;37:106–130.
- Brodie BC. Clinical lectures on surgery delivered at St George's Hospital. 1846; Lea and Blanchard, Philadelphia:201.
- Donhauser G, Vieluf D, Ruzicka T, et al. Benign symmetric Launois-Bensaude type III lipomatosis and Bureau-Barrière syndrome. *Hautarzt* 1991;42:311–4. Available at: <http://www.ncbi.nlm.nih.gov/pubmed/1874620>.
- Pinto CIC, Carvalho PJMC, Correia MMO. Madelung's disease: revision of 59 surgical cases. *Aesthetic Plast Surg* 2017;41:359–68.
- Ettl T, Gaumann A, Ehrenberg R, et al. Encapsulated lipomas of the tongue in benign symmetric lipomatosis. *J Dtsch Dermatol Ges* 2009;7: 441–4.
- Mayo Yáñez M, González Poggioli N, Álvarez-Buylla Blanco M, et al. Benign symmetric lipomatosis with lingual involvement: case report and literature review. *J Stomatol Oral Maxillofac Surg* 2018;119:148–50.
- Borges A, Torrinha F, Lufkin RB, et al. Laryngeal involvement in multiple symmetric lipomatosis: The role of computed tomography in diagnosis. *Am J Otolaryngol* 1997;18:127–30.
- Ostrowski KR, Rubin AD. Benign symmetric lipomatosis involving the supraglottic larynx: a rare cause of dysphonia. *Otolaryngol Head Neck Surg* 2011;145:360–1.
- Pinto V, Morselli PG, Tassone D, et al. A case of severe obstructive sleep apnoea in Madelung's disease treated by lateral pharyngoplasty. *J Laryngol Otol* 2017;131:834–7.
- Laure B, Sury F, Tayeb T, et al. Launois-Bensaude syndrome involving the orbits. *J Cranio-Maxillofacial Surg* 2011;39:21–3.
- Subash M, Aziz A, O'Doherty M, et al. Lipomatosis of the orbits: possibly a form of Madelung's disease. *Eye* 2012;26:894.
- Herbst KL. Rare adipose disorders (RADs) masquerading as obesity. *Acta Pharmacol Sin* 2012;33:155–72.
- Olivari N. Transpalpebral decompression operation in endocrine orbitopathy (exophthalmos). *Wien Med Wochenschr* 1988;138:452–5.

- [18] Rootman DB. Orbital decompression for thyroid eye disease. *Surv Ophthalmol* 2018;63:86–104.
- [19] Richter DF, Stoff A, Olivari N. Transpalpebral decompression of endocrine ophthalmopathy by intraorbital fat removal (olivari technique): experience and progression after more than 3000 operations over 20 years. *Plast Reconstr Surg* 2007;120:109–23.
- [20] Cheng AM, Wei YH, Tighe S, et al. Long-term outcomes of orbital fat decompression in Graves' orbitopathy. *Br J Ophthalmol* 2018;102:69–73.
- [21] Tao JP, Vemuri S, Patel AD, et al. Lateral tarsoconjunctival onlay flap lower eyelid suspension in facial nerve palsy. *Ophthalm Plast Reconstr Surg* 2014;30:342–5.