

Hip Capsular Reconstruction Made Easy: The Timing and the Technique



J. W. Thomas Byrd, M.D.

Abstract: An iatrogenic capsular defect can be a major contributing factor to macroinstability of the hip. For this circumstance, capsular reconstruction may be appropriately indicated when the capsule cannot be primarily reconstituted. Severe dysfunction may accompany previous failed arthroscopy. This dysfunction should be assessed and addressed with a properly structured rehabilitation program prior to revision surgery. We describe a simplified technique for capsular reconstruction using a dermal allograft.

Historically, simple arthroscopic debridement procedures of the hip did not require a capsulotomy.^{1,2} The emergence of arthroscopic correction of femoroacetabular impingement (FAI) and labral repair included more extensive capsulotomies to effectively perform the procedures.^{3,4} Subsequently, attention has been given to preserving and repairing the capsule.^{5,6} There are now studies reporting that when a capsulotomy is performed, the results of arthroscopy are superior when the capsular incision is closed at the completion of the procedure.⁷⁻⁹ The data are not entirely conclusive, but there are clearly circumstances in which repair is preferable, especially to avoid iatrogenic instability.¹⁰⁻¹³

With the growing number of arthroscopic procedures, there is also an expanding amount of literature on revision hip arthroscopy.¹⁴⁻¹⁶ Capsular deficiency is sometimes implicated in failed hip arthroscopy.^{17,18} Pain and dysfunction around the hip can be multifactorial as reflected by Bryan Kelly's layer concept of the

hip, as reported by Draovitch et al.¹⁹ Lack of capsular integrity may be a contributing factor. Most clearly, this may be implicated when macroinstability or frank dislocation occurs after previous arthroscopy when the capsule was not repaired.

During revision surgery, often the edges of a capsular defect can be freshened, mobilized, and restored with primary suture repair. The spectrum of capsular compromise may parallel concepts of the irreparable labrum and when to consider a labral reconstruction. Most labrums can be repaired, as most capsules can be restored. Steve Burkhart once commented that the

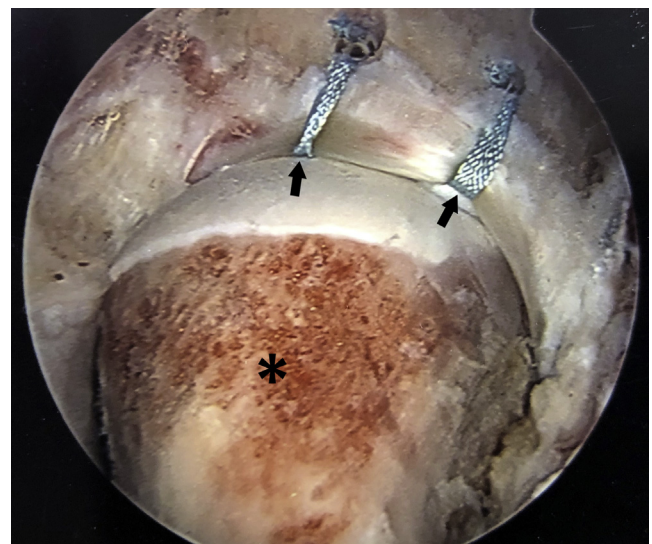


Fig 1. Viewing from the anterolateral portal, an arthroscopic image of the left hip in a 20-year-old woman, having undergone acetabuloplasty and labral refixation with 2 anchors (arrows), as well as femoroplasty (asterisk) via the capsulotomy, which was not closed.

From Nashville Sports Medicine Foundation, Nashville, Tennessee, U.S.A.
The author reports the following potential conflicts of interest or sources of funding: J.W.T.B. is a consultant for Smith & Nephew Endoscopy, receives research support from Smith & Nephew Endoscopy, and receives publishing royalties from Springer, outside the submitted work. Full ICMJE author disclosure forms are available for this article online, as [supplementary material](#).

Received June 18, 2020; accepted September 13, 2020.

Address correspondence to J. W. Thomas Byrd, M.D., Nashville Sports Medicine Foundation, 2004 Hayes St, Ste 700, Nashville, TN 37203, U.S.A.
E-mail: info@nsmoc.com

© 2020 by the Arthroscopy Association of North America. Published by Elsevier. This is an open access article under the CC BY-NC-ND license (<http://creativecommons.org/licenses/by-nc-nd/4.0/>).

2212-6287/201165

<https://doi.org/10.1016/j.eats.2020.09.012>

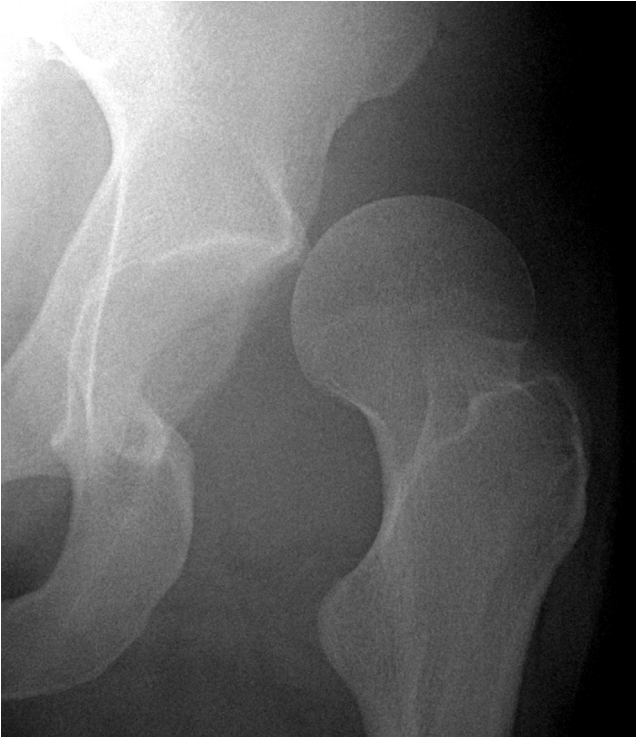

Fig 2. Anteroposterior radiograph showing anterior dislocation of left hip.

irreparable rotator cuff is like the unrunnable marathon: It may not be runnable for one person but could be for another (oral conversation, circa 2008). This may apply to both labral repair in the hip and capsular repair in revision circumstances. Thus, the role of capsular reconstruction in the hip is in flux.

This modest technical article does not attempt to define the indications for capsular reconstruction but

simply describes a manageable method in a case in which capsular reconstruction is clearly appropriate. The importance of making sure the patient is properly prepared for further surgery is also emphasized.

Procedural Technique

Indications

Capsular reconstruction is most clearly indicated in the presence of macroinstability after previous arthroscopic surgery when the capsule has not been restored (Figs 1 and 2). In this scenario, patients may be guarded and deconditioned from favoring their hip. An intra-articular injection and course of supervised physical therapy can be important to better prepare the hip for revision surgery and aid the likelihood of a successful outcome. It is important to precisely assess the architecture of the hip, looking for any bony features that may predispose to instability (Fig 3). Persistent examination findings of apprehension with anterior translation of the femoral head, despite successful rehabilitation, support the role of capsular reconstruction.

Arthroscopic Procedure

Arthroscopy is carried out in a standard supine fashion using 3 previously described portals (anterolateral, anterior, and posterolateral) (Video 1, Fig 4).^{1,20} A survey of the joint is performed, switching among the 3 portals using a combination of 70° and 30° scopes, to assess the status of the previous labral refixation, presence of adhesions, and magnitude of the capsular defect. After other pathology is addressed, attention is turned to the capsule, switching between the anterior and anterolateral portals as viewing and working portals. The edges of the capsular defect are meticulously

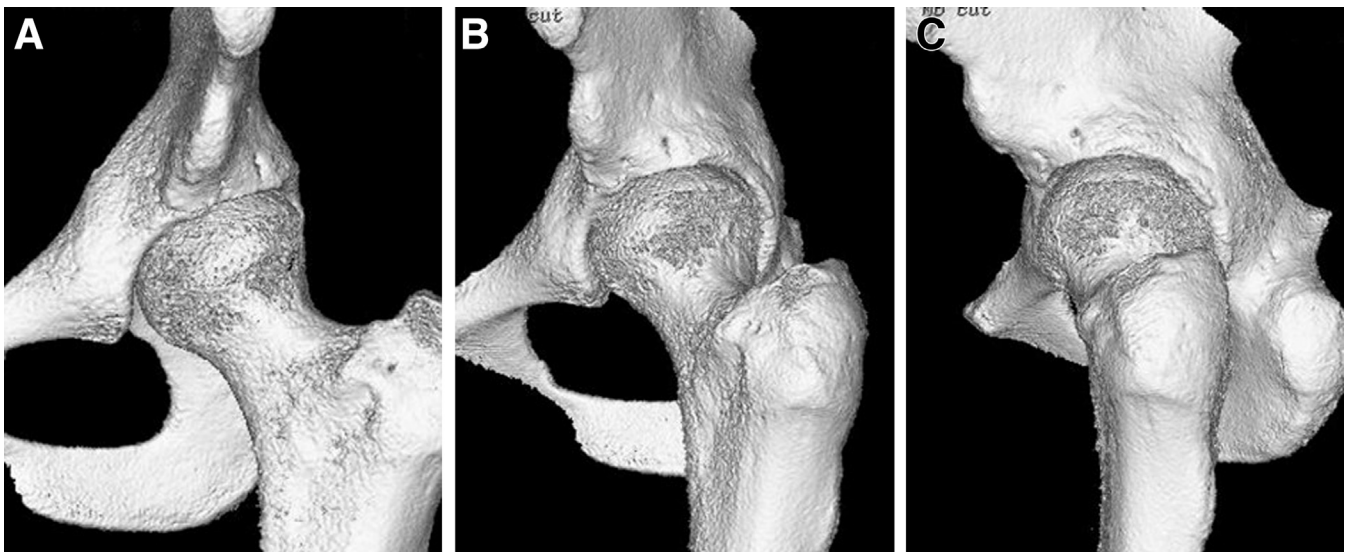


Fig 3. (A-C) Three-dimensional images of the left hip reveal relatively normal bony geometry.

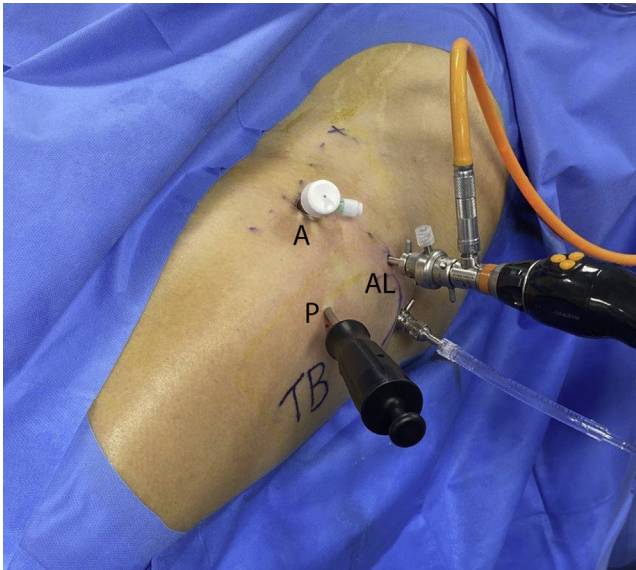


Fig 4. Standard portals for left hip. Viewing is performed from the anterolateral portal (AL) with a 70° scope. The anterior portal (A) is the working portal with an 8.5-mm Clear-Trac cannula. Anchors are placed from a percutaneous distal site (P), ensuring adequate divergence of the anchors at the acetabular rim.

prepared, defining healthy capsular margins medially, laterally, and distally using a 4.5-mm full-radius resector and conservative application of an Eflex ablation tip (Smith & Nephew, Andover, MA) at a low setting. Proximally, the defect is bordered by the rim of the acetabulum, peripheral to the labrum where no capsule was present (Fig 5).

Capsular reconstruction is then performed, viewing from the anterolateral portal and using a Smith & Nephew 8.5-mm Clear-Trac cannula for the working

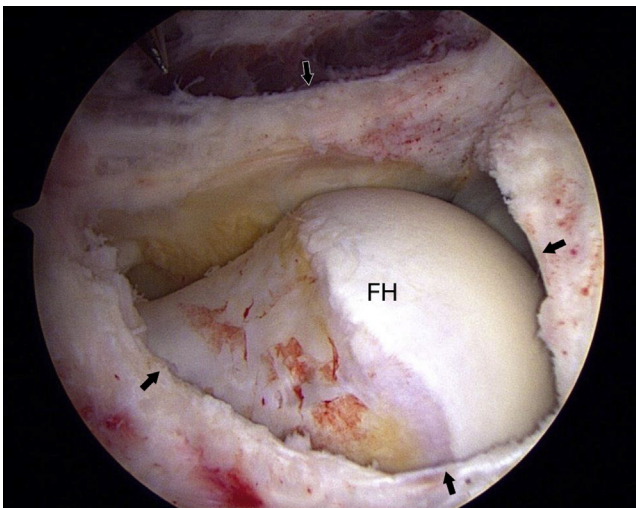


Fig 5. Viewing the left hip from the anterolateral portal, the trapezoidal capsular defect (arrows) is identified with the femoral head (FH) exposed.

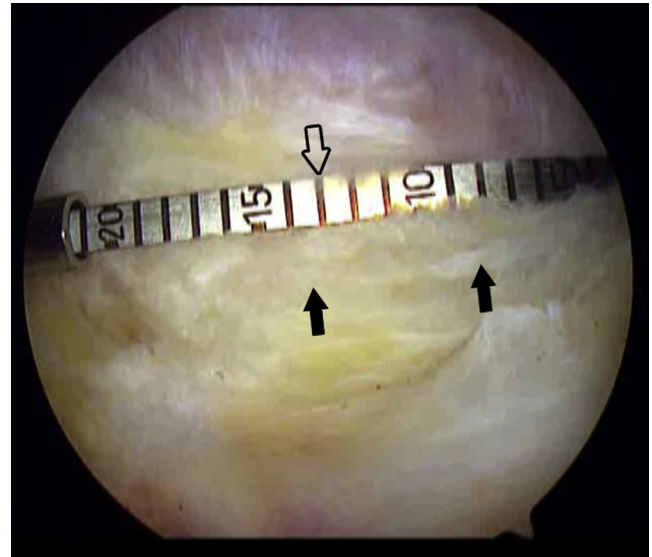


Fig 6. Viewing the left hip from the anterolateral portal, the Arthrex arthroscopic measurement probe (transparent arrow) is used to measure the length of the capsular defect margin (black arrows).

anterior portal. The trapezoidal dimensions of the defect are measured with an Arthrex arthroscopic measurement probe (Naples, FL) (Fig 6). As described by Perets et al. (Ben Domb, senior author),²¹ we use a 1.5-mm ArthroFLEX decellularized dermis patch (Arthrex), cut 1 cm larger than the measured dimensions. These dimensions work well for incorporating the margins of the graft to the acetabular rim and edges of the remaining capsule.

A Smith & Nephew 1.8-mm Q-Fix suture anchor is placed on the acetabular rim at the medial and lateral

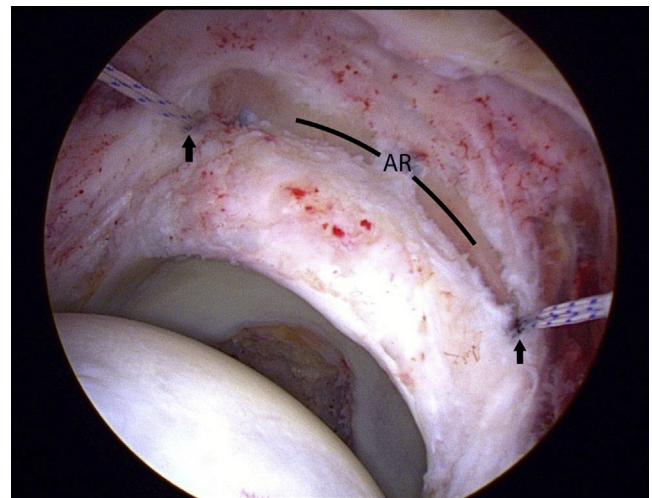


Fig 7. Viewing the left hip from the anterolateral portal, the acetabular rim (AR) has been lightly decorticated and a 1.8-mm Q-Fix suture anchor has been placed at the margins of the capsular defect (arrows).

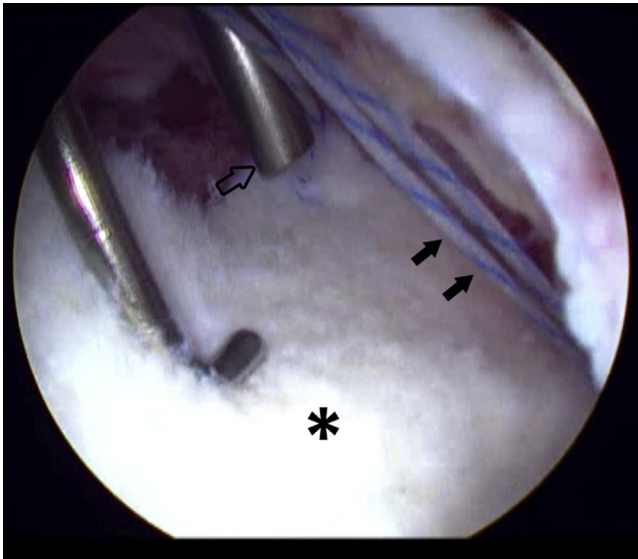


Fig 8. Viewing the left hip from the anterolateral portal, a graft (asterisk) has been delivered into the joint and preliminarily secured with a single half-hitch for the suture in the lateral-most anchor (black arrows), while the medial anchor knot is tied with a knot pusher (transparent arrow).

extent of the capsular deficiency (Fig 7). This anchor is placed from a percutaneous distal site to ensure adequate divergence for safely placing the anchor close to the acetabular rim without perforating its articular surface (Fig 4). The sutures are brought out through the anterior cannula and passed in a mattress fashion through the 2 corners of the graft that align on the acetabular rim. Placing the 2 limbs of each mattress

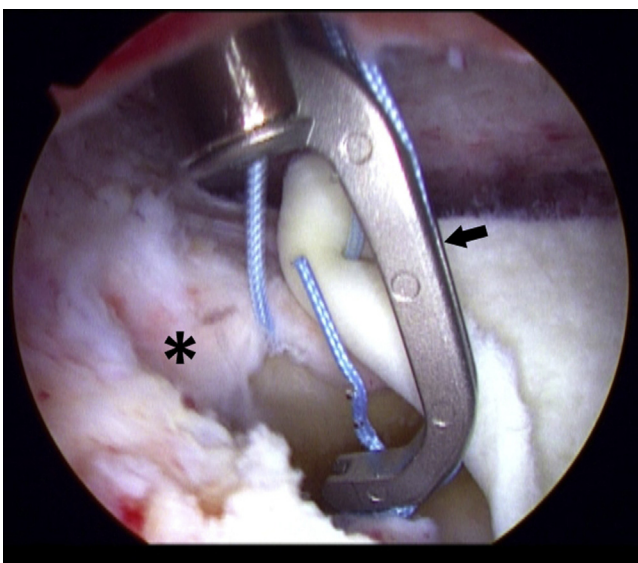


Fig 9. Viewing the left hip from the anterolateral portal, the Speed Stitch device (arrow) is poised to grab the capsule (asterisk) at the margin of the defect.

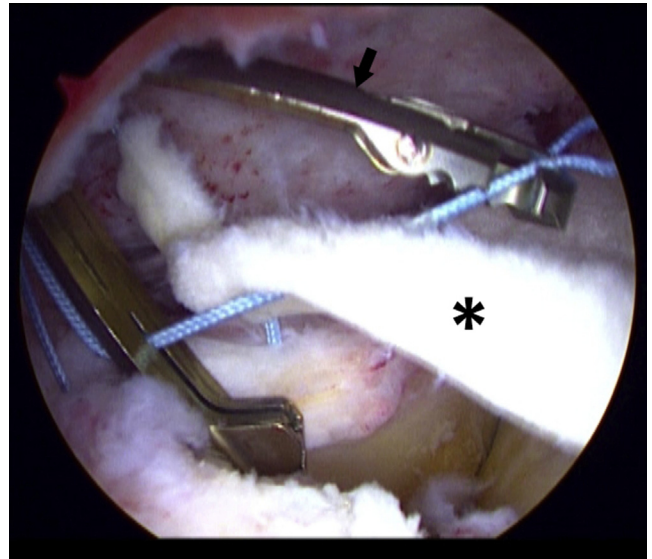


Fig 10. Viewing the left hip from the anterolateral portal, the suture has been passed through the graft (asterisk) with a Truepass device (arrow).

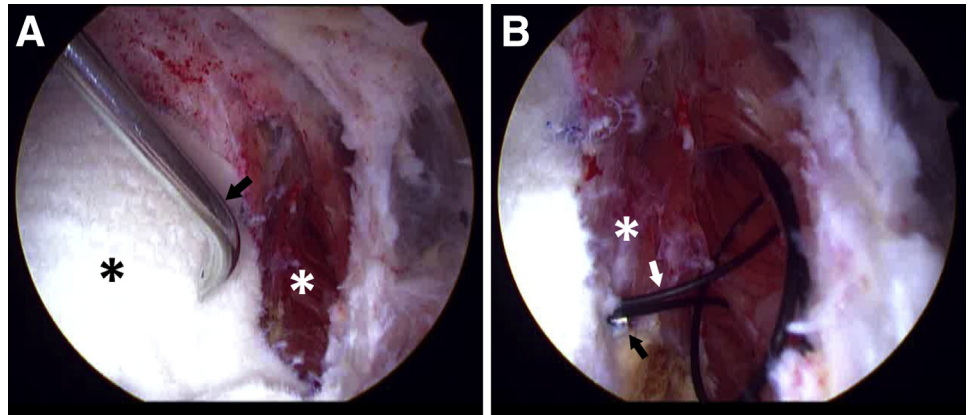
suture 3 to 4 mm apart provides a good soft-tissue bridge so that the suture will not cut out.

By use of the sutures, the graft is then delivered into the joint. Other than properly measuring the defect, this is the only critical part of the procedure. Most important is simply making sure the 2 pairs of sutures are not entangled. We use a half-hitch with the knot pusher on the non-post suture. The graft is delivered into the joint by pulling on the post and pushing with the knot pusher. As an alternative choice, a sliding knot can be used. We use just a single half-hitch because if the sutures become entangled, it is probably easier to resolve than if a complete sliding knot has already been delivered into the joint.

Once the graft is approximated to the acetabular rim, the knots are secured for the 2 suture anchors (Fig 8). With the graft secured at the edges of the acetabular rim, it then lies nicely over the defect. No. 2 Ultrabraid mattress corner sutures (Smith & Nephew) lay the graft nicely over the native capsule. Suture management is facilitated with Speed Stitch, Truepass, and 70° Accu-Pass Direct suture passers (Smith & Nephew) (Figs 9-11). Additional sutures are passed between the corners: medial, lateral, and distal (Fig 12). Although not needed in this case, an additional anchor could be placed in the acetabular rim.

Postoperatively, the patient undergoes a standard rehabilitation protocol, supplemented with a hip spica brace, blocking the final 30° of extension for 8 weeks, followed by gradual restoration of extension to 0°. ²² Precautions against anterior instability are maintained for the first 4 months.

Fig 11. View of the left hip from the anterolateral portal. (A) A 70° Accupass device (arrow) is penetrating the graft (black asterisk) close to the junction with the native capsule (white asterisk). (B) The tip of the Accupass (black arrow) has now been delivered up through the capsule (asterisk), delivering the monofilament suture (white arrow) to be used to shuttle in the No. 2 Ultrabraid suture.



Discussion

Since the implementation of capsulotomies for more extensive arthroscopic hip procedures, the merits of capsular closure have been reported. Still, the exact indications for capsular closure have not been conclusively defined. Similarly, the role of capsular defects in the causation of symptoms after previous arthroscopy is not always clear, and the indications for capsular reconstruction are even less well defined. Nonetheless, it is good to have this option available in the spectrum of techniques that can be used in addressing complex hip problems. Reducing technical barriers simply enhances the option of using this technique when considered appropriate.

The key to this method is how to simplify delivery of the graft and suture management. For surgeons trained in sports medicine and/or arthroscopy, this is less imposing because of their familiarity with restoration and suture management techniques in other joints.

However, surgeons versed in other forms of traditional hip surgery may be very familiar with open methods but find the arthroscopic approach more imposing.

Three established tenets play as a prelude to the technical details of this operation. First, we know that the key to any successful surgical procedure is picking the right patient. Second, we know that many individuals with radiographic features of FAI live long active lives without problems. Thus, when someone encounters trouble with symptomatic FAI, for example, there is likely a perfect storm in which enough factors come together just wrong to become problematic. This is likely true of most revision circumstances for failed previous arthroscopy. Capsular deficiency may play a role but is unlikely to be the sole culprit in the absence of other factors. Third, we know that the success of a procedure is dependent on the postoperative rehabilitation process. So, any rehabilitation deficits that can be addressed prior to surgery put the patient in a better position for a successful outcome. Like most things in life, timing is everything. Often, the toughest decision is not so much what operation to perform as when to perform it. In this case, guidance on behalf of the patient prior to revision surgery, as well as a demonstration on the patient's part to her commitment to the recovery process, set the stage for a technically successful procedure. The role of capsular reconstruction in

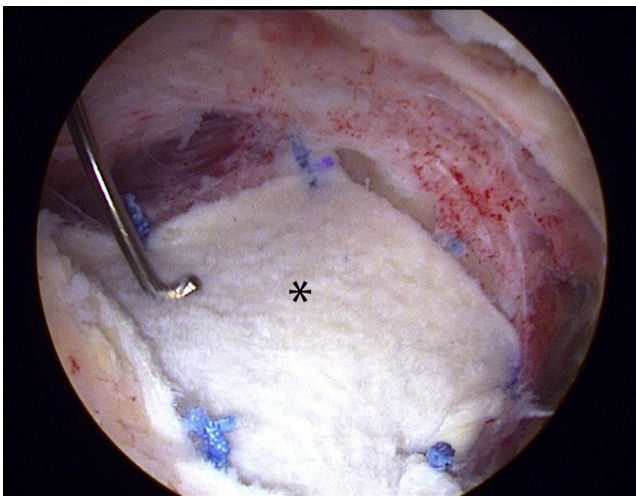


Fig 12. Viewing the left hip from the anterolateral portal, the completed capsular reconstruction with a 1.5-mm Arthro-FLEX decellularized dermis patch (asterisk) is being probed.

Table 1. Advantages and Disadvantages

Advantages

- Provides less invasive arthroscopic approach to capsular reconstruction
- Simplifies technique
- Provides another option for spectrum of failed previous arthroscopy

Disadvantages

- Technique simplified but still requires facile arthroscopic skills
- More imposing for surgeons less familiar with arthroscopic methods
- Long-term capsularization of graft not well defined

Table 2. Pearls and Pitfalls

<p>The surgeon should strive to establish the correct diagnosis. Failed arthroscopy is often multifactorial.</p> <p>The surgeon should make sure that the patient is optimally prepared for the required recovery process.</p> <p>At arthroscopy, the entire hip should be carefully surveyed for other forms of pathology.</p> <p>The technique requires meticulous soft-tissue preparation for visualization and defining the margins of the capsular defect.</p> <p>The surgeon should properly measure the defect and remember to add 1 cm in each dimension.</p> <p>The surgeon should carefully ensure that the 2 suture pairs remain unentangled while delivering the graft into the joint.</p> <p>Once the graft is laid over the defect, basic suture management is applied, using various devices to pass the sutures in the desired fashion.</p> <p>The surgeon should ensure that a postoperative, properly structured rehabilitation program is implemented and conveyed to the patient.</p>	
---	--

the management of hip disorders is evolving and there are limitations (Tables 1 and 2), but the technique is well defined.

References

1. Byrd JWT. Hip arthroscopy utilizing the supine position. *Arthroscopy* 1994;10:275-280.
2. Byrd JWT, Jones KS. Arthroscopic management of femoroacetabular impingement. *Instr Course Lect* 2009;58:231-239.
3. Byrd JWT. Femoroacetabular impingement in athletes, part II: Treatment and outcomes. *Sports Health* 2010;2:403-409.
4. Byrd JWT. My approach to femoroacetabular impingement. In: Byrd JWT, ed. *Operative hip arthroscopy*. Ed 3. New York: Springer, 2013;215-236.
5. Philippon MJ. New frontiers in hip arthroscopy: The role of arthroscopic hip labral repair and capsulorrhaphy in the treatment of hip disorders. *Instr Course Lect* 2006;55:309-316.
6. Domb BG, Philippon MJ, Giordano BD. Arthroscopic capsulotomy, capsular repair, and capsular plication of the hip: Relation to atraumatic instability. *Arthroscopy* 2013;29:162-173.
7. Frank RM, Lee S, Bush-Joseph CA, Kelly BT, Salata MJ, Nho SJ. Improved outcomes after hip arthroscopic surgery in patients undergoing T-capsulotomy with complete repair versus partial repair for femoroacetabular impingement: A comparative matched-pair analysis. *Am J Sports Med* 2014;42:2634-2642.
8. Domb BG, Chaharbakshi EO, Perets I, Walsh JP, Yuen LC, Ashberg LJ. Patient-reported outcomes of capsular repair versus capsulotomy in patients undergoing hip arthroscopy: Minimum 5-year follow-up—a matched comparison study. *Arthroscopy* 2018;34:853-863.e1.
9. Bolia IK, Fagotti L, Briggs KK, Philippon MJ. Midterm outcomes following repair of capsulotomy versus non-repair in patients undergoing hip arthroscopy for femoroacetabular impingement with labral repair. *Arthroscopy* 2019;35:1828-1834.
10. Filan D, Carton P. Routine interportal capsular repair does not lead to superior clinical outcome following arthroscopic femoroacetabular impingement correction with labral repair. *Arthroscopy* 2020;36:1323-1334.
11. Ekhtiari S, De Sa D, Haldane CE, et al. Hip arthroscopic capsulotomy techniques and capsular management strategies: A systematic review. *Knee Surg Sports Traumatol Arthrosc* 2017;25:9-23.
12. Ortiz-Declet V, Mu B, Chen AW, et al. Should the capsule be repaired or plicated after hip arthroscopy for labral tears associated with femoroacetabular impingement or instability? A systematic review. *Arthroscopy* 2018;34:303-318.
13. Acuña AJ, Samuel LT, Roth A, Emara AK, Kamath AF. How capsular management strategies impact outcomes: A systematic review and meta-analysis of comparative studies. *J Orthop* 2020;19:237-243.
14. Shapira J, Kyin C, Go C, et al. Indications and outcomes of secondary hip procedures after failed hip arthroscopy: A systematic review. *Arthroscopy* 2020;36:1992-2007.
15. O'Connor M, Steidl GK, Padaki AS, Duchman KR, Westermann RW, Lynch TS. Outcomes of revision hip arthroscopic surgery: A systematic review and meta-analysis. *Am J Sports Med* 2020;48:1254-1262.
16. Sardana V, Philippon MJ, De Sa D, et al. Revision hip arthroscopy indications and outcomes: A systematic review. *Arthroscopy* 2015;31:2047-2055.
17. Riff AJ, Kunze KN, Movassaghi K, et al. Systematic review of hip arthroscopy for femoroacetabular impingement: The importance of labral repair and capsular closure. *Arthroscopy* 2019;35:646-656.e3.
18. Duplantier NL, McCulloch PC, Nho SJ, Mather RC III, Lewis BD, Harris JD. Hip dislocation or subluxation after hip arthroscopy: A systematic review. *Arthroscopy* 2016;32:1428-1434.
19. Draovitch P, Edelstein J, Kelly BT. The layer concept: Utilization in determining the pain generators, pathology and how structure determines treatment. *Curr Rev Musculoskelet Med* 2012;5:1-8.
20. Byrd JWT. Routine arthroscopy and access: Central and peripheral compartments, iliopsoas bursa, peritrochanteric, and subgluteal space. In: Byrd JWT, ed. *Operative hip arthroscopy*. Ed 3. New York: Springer, 2013;131-160.
21. Perets I, Hartigan DE, Walsh JP, Chaharbakshi E, Close MR, Domb BG. Arthroscopic capsular reconstruction of the hip with acellular dermal extracellular matrix: Surgical technique. *Arthrosc Tech* 2016;5:e1001-e1005.
22. Coplen EM, Voight M. Rehabilitation of the hip. In: Byrd JWT, ed. *Operative hip arthroscopy*. Ed 3. New York: Springer, 2013. 441-440.