

## Testicular myeloid sarcoma: case report

Luzia Beatriz Ribeiro Zago<sup>1</sup>  
 Antônio Alexandre Lisboa Ladeira<sup>2</sup>  
 Renata Margarida Etchebehere<sup>2</sup>  
 Leonardo Rodrigues de Oliveira<sup>2</sup>

<sup>1</sup>Hospital Dr. Amaral Carvalho, Jaú, SP, Brazil

<sup>2</sup>Universidade Federal do Triângulo Mineiro – UFTM, Uberaba, MG, Brazil

*Myeloid sarcomas are extramedullary solid tumors composed of immature granulocytic precursor cells. In association with acute myeloid leukemia and other myeloproliferative disorders, they may arise concurrently with compromised bone marrow related to acute myeloid leukemia, as a relapsed presentation, or occur as the first manifestation. The testicles are considered to be an uncommon site for myeloid sarcomas. No therapeutic strategy has been defined as best but may include chemotherapy, radiotherapy and/or hematopoietic stem cell transplantation. This study reports the evolution of a patient with testicular myeloid sarcoma as the first manifestation of acute myeloid leukemia. The patient initially refused medical treatment and died five months after the clinical condition started.*

**Keywords:** Testicular neoplasms/complications; Sarcoma, myeloid; Leukemia, myeloid, acute; Leukemia infiltration/pathology; Immunohistochemistry; Humans; Male; Adult; Case reports

### Introduction

Myeloid sarcomas are rare extramedullary solid tumors composed of immature cells derived from a myeloid hematopoietic lineage<sup>(1)</sup>.

They are also known as chloromas, myeloblastomas, myelocytomas, chloroleukemia and granulocytic sarcomas and are associated with acute myeloid leukemia (AML) and blastic transformation of chronic myeloproliferative disorders (chronic myeloid leukemia, polycythemia vera and primary myelofibrosis) and myelodysplastic syndromes. They may manifest without any initial compromise of the bone marrow<sup>(2-5)</sup>.

Myeloid sarcomas are associated with AML in 2-8% of the cases, especially in situations of cytogenetic abnormalities such as t(8;22), inv(16) and 11q23<sup>(1,5-7)</sup>. They may be presented simultaneously with AML, as a form of extramedullary disease in recurrence, or may be separate findings that precede an increase in the number of myeloblasts in the bone marrow by some weeks or months. In such situations, blastic infiltration of the bone marrow is not seen<sup>(6)</sup>.

The testicles are considered to be an uncommon site for myeloid sarcomas<sup>(8-10)</sup>. The present study reports a presentation of myeloid sarcoma with testicular involvement as the first manifestation of AML in a case in which the patient initially refused specific treatment. The case presented rapid evolution marked by extensive compromise of abdominal and thoracic soft tissues, the central nervous system, lymph nodes and bone marrow.

### Case report

The present study describes a 38-year-old man with an initial history of an enlarged left testicle that lasted for five months, followed by inguinal adenopathy, weight loss and abdominal distention. The investigation at the clinic where the case was first seen included a biopsy of an inguinal lymph node, which detected infiltration by undifferentiated malignant neoplasia that was compatible with infiltration by myeloblasts, seen through immunohistochemical analysis. The patient initially refused specific treatment for five months, but there was progressive enlargement of the left testicle and inguinal lymph nodes, with progressive clinical deterioration. For this reason, the patient was referred to Hospital de Clínicas, Universidade Federal do Triângulo Mineiro, where he was admitted presenting acute postrenal kidney failure due to extrinsic compression of the urinary tract, which required emergency hemodialysis and percutaneous nephrostomy.

The complete blood count showed leukocytosis ( $14.8 \times 10^9/L$ ), with the presence of blastic cells in peripheral blood, without anemia or thrombocytopenia. A bone marrow aspirate showed that 26% of the nucleated cells were blasts that, from flow cytometry, were defined as presenting an immunophenotype compatible with a myeloid origin (CD45<sup>+</sup>, CD13<sup>+</sup>, CD33<sup>+</sup>, HLADR<sup>+</sup> and CD11c<sup>+</sup>).

An ultrasound scan demonstrated that some abdominal structures were extensively compromised (mesentery, parietal peritoneum, right colon and bilateral obstructive hydronephrosis due to extrinsic compression of the ureters). The left testicle was enlarged

Conflict-of-interest disclosure:  
 The authors declare no competing financial interest

Submitted: 6/24/2012  
 Accepted: 12/11/2012

**Corresponding author:**  
 Leonardo Rodrigues de Oliveira  
 Universidade Federal do Triângulo Mineiro – UFTM  
 Central de Quimioterapia  
 Rua Getúlio Guaritá, snº  
 38080-125 Uberaba, MG, Brazil  
 Phone: +55-34-33185158  
 leonardorodoli@hotmail.com

www.rbhh.org or www.scielo.br/rbhh

DOI: 10.5581/1516-8484.20130018

(volume of 76 mL) due to an infiltrative process, with enlargement of the epididymis and spermatic cord structures and thickening of the skin and subcutaneous tissue. Computed tomography of the abdomen showed that the left diaphragm, ileocecal junction and periaortic-pericaval lymph node cluster were compromised, with severe ascites and moderate bilateral pleural effusion.

Anatomopathological and immunohistochemical analyses of a sample from a left orchietomy (Figures 1 & 2) revealed the presence of diffuse infiltration of the testicle, epididymis and spermatic cord structures by a hematopoietic neoplasia compatible with myeloid sarcoma [CD117<sup>+</sup>, CD34<sup>+</sup>, CD68<sup>+</sup>, myeloperoxidase (MPO)<sup>+</sup>, CD3<sup>-</sup> and CD20<sup>-</sup>]. No cytogenetic analysis was performed.

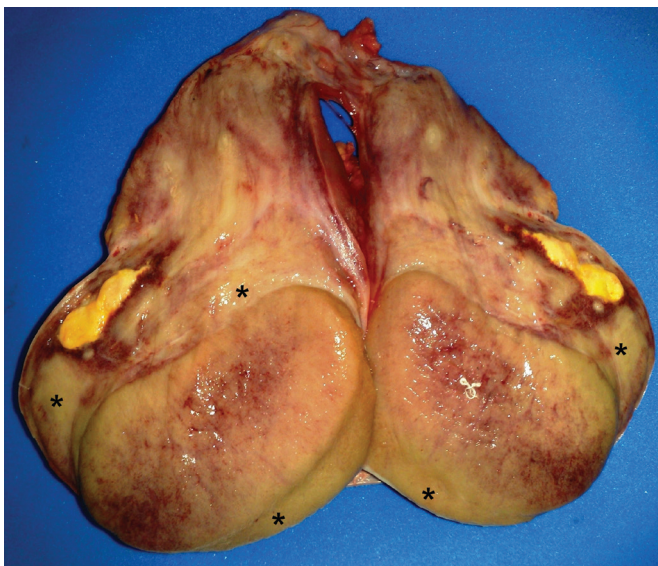

Figure 1 - Testicle without fixation, extensively infiltrated by cream-colored neoplasia (\*) and with areas of necrosis

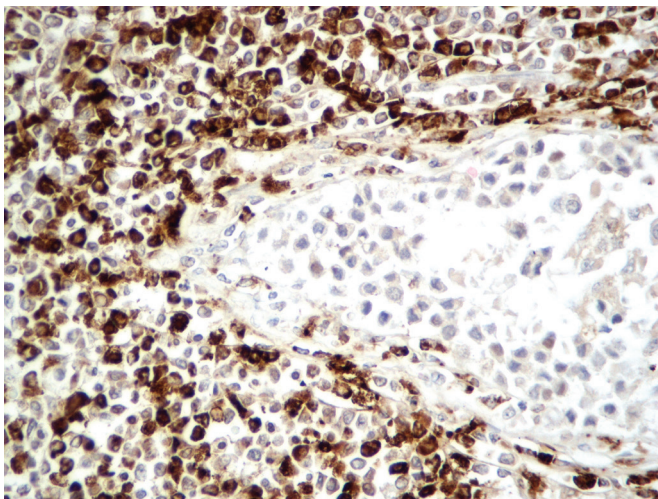


Figure 2 - Immunohistochemical analysis showing a positive reaction for myeloperoxidase, labeling the neoplastic cells (brown) with preservation of the seminiferous duct (negative) on the right side of the image (magnification 400X)

Chemotherapy (cytarabine and hydroxyurea) was started in association with extensive abdominal radiotherapy, but the patient's condition evolved with progressive organ dysfunction that culminated in death seven days later due to disease progression.

## Discussion

Myeloid sarcoma can occur at any age, although it is commonest among young adults<sup>(2,7)</sup>. The sites most affected are bone structures (cranium, paranasal sinuses, sternum, ribs, vertebrae and pelvis), central nervous system, soft tissues of the head and neck (especially the orbit), skin, lymph nodes and breasts<sup>(2,6-8)</sup>. Initial presentation of AML with involvement of the testicles, as described in the present case, is considered to be uncommon, with a poor prognosis<sup>(9,10)</sup>. The correct histological diagnosis is based on identifying the granulocytic characteristics in the neoplastic cells. Because of high morphological variability and possible non-identification of myeloid differentiation (variable), errors may occur especially when the neoplasia presents minimal myeloid differentiation such that it is composed of poorly differentiated cells distinct from the myeloblasts that are found in the bone marrow in cases of concomitant AML<sup>(3,5)</sup>. The differential diagnoses include high-grade non-Hodgkin lymphoma, acute lymphoid leukemia, melanoma, Ewing's sarcoma, blastic plasmacytoid dendritic cell neoplasm and extramedullary hematopoiesis<sup>(5)</sup>. Almost half of such patients are wrongly diagnosed<sup>(6)</sup>.

Immunohistochemistry is of great value in identifying antigens associated with the myeloid lineage (CD13, CD33, CD43, CD117, lysozyme, MPO and CD68). In the present report, the neoplasia was positive for MPO and CD68, which are the most commonly expressed markers of myeloid differentiation<sup>(4,5,7)</sup>. In view of the similarities of findings between myeloid sarcoma and high-grade lymphomas, immunohistochemical analysis of the expression of myeloid antigens (MPO, CD68 and/or lysozyme) of undifferentiated neoplasias and high-grade non-Hodgkin lymphomas is an important tool for ruling out myeloid sarcoma.

There are divergences of views regarding therapeutic management of myeloid sarcoma. The possible options include chemotherapy, hematopoietic stem cell transplantation (HSCT), radiotherapy and surgery. This last option is limited to cases with symptomatic compression due to the tumor<sup>(2,5)</sup>. Radiotherapy can be used in localized forms of the disease, with the aims of consolidating induction chemotherapy, treating lesions that persist after the initial chemotherapy treatment, treating localized recurrences after HSCT, reducing large tumor masses or relieving compression symptoms<sup>(5)</sup>. Systemic chemotherapy similar to what is used to treat AML is considered to be the best strategy for treating myeloid sarcoma. The role of HSCT has not been defined, and this technique should be considered depending on the age, comorbidities, current state of the disease and the cytogenetic and molecular characteristics of the neoplasia<sup>(5,6)</sup>. Nonetheless, defining the best treatment still needs to be characterized through prospective studies<sup>(3,6)</sup>. In the case presented here, the patient was at an advanced stage, with organs extensively compromised by the disease and so chemotherapy and radiotherapy for cytoreduction were chosen.

In conclusion, despite the rarity of myeloid sarcoma, it should be taken into consideration in the differential

diagnoses of undifferentiated neoplasia, with proper use of immunohistochemical techniques in order to make a rapid diagnosis and start treatment, regardless of the unsatisfactory response with frequent relapses and evolution to acute leukemia.

## References

1. Khan MY, Hussein KK, Walter MG, Hasan MK, Kern W, Kharfan-Dabaja MA. Granulocytic sarcoma presenting with malignant anasarca in a patient with secondary acute myeloid leukemia. *Int J Hematol.* 2004;79(3):250-2.
2. Cheah KL, Lim LC, Teong HH, Chua SH. A case of generalized cutaneous granulocytic sarcoma in an elderly patient with myelodysplastic syndrome. *Singapore Med J.* 2002;43(10):527-9.
3. Wong WS, Loong F, Ooi GC, Tse TC, Chim CS. Primary granulocytic sarcoma of the mediastinum. *Leuk Lymphoma.* 2004;45(9):1931-3.
4. Campidelli C, Agostinelli C, Stitson R, Pileri SA. Myeloid sarcoma extramedullary manifestation of myeloid disorders. *Am J Clin Pathol.* 2009;132(3):426-37.
5. Bakst RL, Tallman MS, Douer D, Yahalom J. How I treat extramedullary acute myeloid leukemia. *Blood.* 2011;118(14):3785-93.
6. Yamauchi K, Yasuda M. Comparison in treatments of nonleukemic granulocytic sarcoma: report of two cases and a review of 72 cases in the literature. *Cancer.* 2002;94(6):1739-46.
7. Rocha Filho FD, Ferreira FV, Lima GG, Lima MG, Figueiredo AA. Apresentação incomum de sarcoma granulocítico mamário. *Rev Bras Hematol Hemoter.* 2009;31(4):295-8.
8. Eggener SE, Abrahams A, Keeler TC. Granulocytic sarcoma of the testis. *Urology.* 2004;63(3):584-5.
9. McIlwain L, Sokol L, Moscinski LC, Saba HI. Acute myeloid leukemia mimicking primary testicular neoplasm. Presentation of a case with review of literature. *Eur J Haematol.* 2003;70(4):242-5.
10. Valbuena JR, Admirand JH, Lin P, Medeiros LJ. Myeloid sarcoma involving the testis. *Am J Clin Pathol.* 2005;124(3):445-52.