



OPEN ACCESS

# Status epilepticus from GABA<sub>B</sub>R antibody positive encephalitis due to de novo mixed small cell and adenocarcinoma of the prostate

Christopher Kwan ,<sup>1</sup> Aaron Sia,<sup>2</sup> Cullen O’Gorman<sup>2</sup>

<sup>1</sup>Department of Internal Medicine and Clinical Epidemiology, Princess Alexandra Hospital Health Service District, Brisbane, Queensland, Australia  
<sup>2</sup>Department of Neurology and Stroke, Princess Alexandra Hospital Health Service District, Brisbane, Queensland, Australia

**Correspondence to**  
Dr Christopher Kwan;  
chriskwan88@gmail.com

Accepted 22 October 2020

## SUMMARY

We present a case study of a 67-year-old man who presented with a new onset of recurrent tonic-clonic seizures. He had tested positive to gamma-aminobutyric acid B receptor antibodies in his blood and cerebrospinal fluid, and subsequent CT imaging and transrectal biopsy confirmed the presence of a locally advanced mixed small cell and Gleason 9 adenocarcinoma of the prostate. His seizures remained resistant to treatment with multiple antiepileptic drugs, including sodium valproate, clobazam, topiramate, carbamazepine, phenytoin and lacosamide. He progressed to status epilepticus, which required intravenous immunoglobulin and steroids, followed by plasma exchange 1 week later. The status epilepticus was refractory and required multiple admissions to the intensive care unit.

## BACKGROUND

The management of seizures in the setting of paraneoplastic syndrome remains difficult and is dependent on treatment of the underlying malignancy. This case study outlines the presentation, diagnosis and subsequent management of a patient admitted under the Department of Neurology and Stroke at Princess Alexandra Hospital.

## CASE PRESENTATION

A 67-year-old man presented in December 2019 with a new onset of recurrent tonic-clonic seizures. This was associated with postictal confusion but no baseline changes to cognition. This was not associated with aura. He had no weakness, sensory or visual changes. There was no history of any fevers, rigours, travel or sick contacts. There was no history of weight loss, night sweats. He denied any respiratory symptoms including chronic cough or haemoptysis, and denied any urological symptoms including haematuria or changes in urinary flow.

His medical history was significant for type 2 diabetes mellitus, hypertension and having a 45-pack year smoking history (quit 25 years ago). His medications on admission included lisinopril 20 mg two times per day, metformin extended release 1.5 g at night and gliclazide modified release 30 mg daily. He otherwise was independent with all activities of daily living, lived with his wife and only occasionally consumed alcohol. There was no family or personal history of neurological disorders (including seizure disorders) or developmental issues.

On examination, all his vital observations were normal. He had a Glasgow Coma Score of 15 on arrival and looked well with a normal body habitus. He had a normal neurological examination with a normal cranial nerve, upper and lower limb motor, cerebellar and sensory examinations. His cardiovascular, respiratory and abdominal examinations were all normal.

## INVESTIGATIONS

His full blood count and biochemistry—including serum creatinine and estimated glomerular filtration rate—were normal. His first electroencephalogram (EEG) was normal. MRI scan of his brain was normal. Due to his smoking history, antineuronal antibodies were tested in his blood and cerebrospinal fluid (CSF), which subsequently tested positive to gamma-aminobutyric acid B receptor (GABA<sub>B</sub>R) antibodies without the presence of malignant cells or infection in CSF.

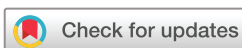Subsequent screening for occult malignancies included CT scans of his chest, abdomen and pelvis, which revealed the presence of a soft tissue density bulkiness of the right seminal vesicle and prostatomegaly of 48×32 mm in size (see figure 1). There was locoregional invasion into the right seminal vesicle and locoregional lymphadenopathy (involving at least five nodes). There were no other lesions of note. Transrectal biopsy was performed, which confirmed the diagnosis of mixed small cell and Gleason 9 adenocarcinoma of the prostate.

Due to ongoing seizures and development of status epilepticus, repeat EEG was requested and found evidence of severe encephalopathy with cortical dysfunction in the left temporal and central regions.

## DIFFERENTIAL DIAGNOSIS

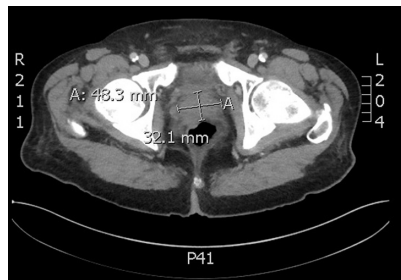
The differential diagnoses for the seizure disorder included new primary epilepsy, or secondary seizure disorder in the setting of infection (including central nervous system (CNS) infections), and malignancy, specifically small cell lung cancer (SCLC).

Five days after initial admission, GABA<sub>B</sub>R antibodies were detected; CT scans were completed on day 6 with subsequent transrectal biopsy completed on day 13 which confirmed the overall diagnosis of GABA<sub>B</sub>R antibody encephalitis secondary to mixed small cell and Gleason 9 adenocarcinoma of the prostate.



© BMJ Publishing Group Limited 2020. Re-use permitted under CC BY-NC. No commercial re-use. See rights and permissions. Published by BMJ.

**To cite:** Kwan C, Sia A, O’Gorman C. *BMJ Case Rep* 2020;**13**:e238172. doi:10.1136/bcr-2020-238172



**Figure 1** CT imaging of prostate lesion.

## TREATMENT

The patient was given 500 mg levetiracetam two times per day but developed status epilepticus on day 7, requiring a dose increase of levetiracetam to 1000 mg two times per day intravenously and 2.5 mg midazolam intravenously. He was subsequently transferred to neurology high dependency unit (HDU) for monitoring due to slow recovery. A drug-related rash was found on day 10, so levetiracetam was changed over to valproate 400 mg two times per day. During the 3 months of hospitalisation, the patient had recurrent seizures despite the addition and titration of multiple antiepileptics, with his most recent antiepileptic regimen now consisting of valproate 500 mg two times per day, clobazam 10 mg at night, topiramate 100 mg daily, carbamazepine 200 mg in the morning and 400 mg at night, phenytoin 300 mg daily and lacosamide 200 mg two times per day. He also had several episodes of status epilepticus, each requiring 2 mg doses of midazolam; he also required two admissions to intensive care unit (ICU) with 800 mg phenobarbitone infusion being required for the first admission.

Due to recurrent seizures in the setting of encephalitis, 5 days of 1 g intravenous methylprednisolone was given, with weaning down to oral 50 mg prednisolone afterwards and initiation of trimethoprim–sulfamethoxazole due to immunosuppression. Due to lack of neurological improvement, 5 days of 30 g intravenous immunoglobulin (IVIG) (with subsequent 30 g monthly IVIG) and then 5 days of 3.5 L plasma exchange were completed once in each of his ICU admissions.

The prostate malignancy was managed by Medical Oncology and cisplatin and etoposide were initiated on day 15. The malignancy was not amenable to surgery as per the urology department. Radiation Oncology was consulted, though radiotherapy could not be performed due to persistent seizures.

## OUTCOME AND FOLLOW-UP

Unfortunately, this patient's neurological function did not recover and he passed away.

## DISCUSSION

GABA<sub>B</sub>R antibody-associated encephalitis is a rare form of autoimmune encephalitis, representing 5% of all cases of autoimmune encephalitis.

GABA<sub>B</sub>R are G-protein-coupled receptors that are composed of two subunits—GABA<sub>B</sub>1 and GABA<sub>B</sub>2.<sup>1</sup> GABA<sub>B</sub>R mediate presynaptic inhibition via the activation of G-protein-coupled inward rectifying potassium channels and inhibition of calcium channels, and attenuate presynaptic firing frequencies.<sup>1</sup> GABA<sub>B</sub>R interacts alongside other ion channels and synaptic receptors (such as excitatory glutamate NMDA and AMPA receptors) to influence synaptic plasticity; this is involved with memory, learning and cognition.<sup>1–3</sup> The highest concentration of GABA<sub>B</sub>R is in the hippocampus, thalamus and cerebellum.<sup>2,4</sup> In animal

models, disruption of GABA<sub>B</sub>R is associated with seizures and cognitive impairment, which is similar to the effects of GABA<sub>B</sub>R antibodies.<sup>2,5</sup>

The first cases of GABA<sub>B</sub>R antibody-related encephalitis were identified by Lancaster *et al* between 2006 and 2009 via a HEK293 cell-based assay performed on patients with suspected paraneoplastic encephalitis.<sup>6</sup> Seizures are the most common presentation of GABA<sub>B</sub>R antibody-associated encephalitis, seen in 80% of cases.<sup>2,7</sup> Other symptoms include cognitive impairment, hallucinations, ataxia and opsoclonus-myoclonus.<sup>8</sup> Fifty per cent are associated with malignancy—usually SCLC or pulmonary neuroendocrine tumour—although our patient was found to have a small cell prostate cancer (SCPC).<sup>2,9–11</sup> EEG abnormalities are evident in approximately 90.9% of cases, typically presenting with generalised or local and low-amplitude slow-wave activity. 18.2% may present with concurrent temporal epileptiform discharges, as was evident with our patient. In 36.4% of cases, MRI brain scans may show increased signals restricted to the medial temporal lobes, hippocampus and parahippocampal gyrus on MRI fluid-attenuated inversion recovery (FLAIR) or T2-weighted imaging with one diffusion restriction, though our patient had a normal MRI brain scan. Nonetheless, autoimmune encephalitis in general are uncommon, and it is suggested by Graus *et al* that patients should be considered for a diagnosis of autoimmune encephalitis if all three of the following criteria are met: (1) subacute onset (rapid progression <3 months) of working memory deficits (short-term memory loss), altered mental status (defined as decreased or altered level of consciousness, lethargy or personality change) or psychiatric symptoms; (2) at least one of the following features: new focal CNS findings, seizures not explained by a previously known seizure disorder, CSF pleocytosis (>5 white cell count per mm<sup>3</sup>), MRI features suggestive of encephalitis (brain MRI hyperintense signal on T2-weighted FLAIR sequences highly restricted to one or both medial temporal lobes (limbic encephalitis), or in multifocal areas involving grey matter, white matter or both, compatible with demyelination or inflammation and (3) reasonable exclusion of alternative causes.<sup>12</sup>

SCPC is rare at initial diagnosis (≤2% of cases). SCPC is more likely to emerge in men with previous androgen deprivation therapy for prostate adenocarcinoma and rarely occurs de novo as in our patient.<sup>13</sup> It has an aggressive tumour biology that is associated with rapid development of visceral metastases and bulky tumour masses.<sup>14,15</sup> SCPC is characterised by small cell neuroendocrine morphology with the secretion of neuroendocrine tumour markers such as neuron-specific enolase and chromogranin A.<sup>14,15</sup> These tumours grow independently from the androgen receptor axis and are thus usually resistant to androgen deprivation therapy.<sup>14</sup> SCPC has a poor prognosis and most patients are deceased within 1 year.<sup>16</sup>

The management of GABA<sub>B</sub>R antibody-associated encephalitis is dependent on the prompt management of seizures and other neurological symptoms, and the treatment of underlying malignancies. There are no specific guidelines that determine the optimal choices of antiepileptics for GABA<sub>B</sub>R antibody-associated encephalitis or other paraneoplastic encephalitis, but antiepileptic management should be aggressive.<sup>17</sup> Depending on clinical outcomes, most patients will not require long-term antiepileptics.<sup>17</sup> Our patient, however, has required multiple antiepileptics and is still having seizures and cognitive impairment. There are no controlled studies relating to optimal use of immunotherapy in patients with GABA<sub>B</sub>R antibody-associated encephalitis though usually the encephalitis responds well to treatment.<sup>7</sup> Overall treatment response is based on clinical

evaluation as antibody titres often do not correlate with disease activity.<sup>18</sup> When treating for SCPC, the National Comprehensive Cancer Network suggests a combination of etoposide with cisplatin or carboplatin in patients with pure small cell carcinoma of the prostate or combination of docetaxel and carboplatin.<sup>19</sup> A single-arm phase II study investigated the use of carboplatin plus docetaxel in combination with prednisone in 113 patients with SCPC. After progression on carboplatin plus docetaxel, patients were treated with cisplatin and etoposide. Median overall survival of the cohort was 16 months (95% CI 13.6 to 19.0), and the proportion of patients who were progression free after four cycles of carboplatin plus docetaxel and subsequent treatment with cisplatin plus etoposide (N=71) was 65.4% and 33.8%, respectively.<sup>19 20</sup> Androgen deprivation is usually ineffective for SCPCs.<sup>19</sup>

This case highlights the difficulties in seizure management in patients who develop GABA<sub>B</sub>R antibody-associated encephalitis. Four different long-term antiepileptics were prescribed, which did not successfully reduce seizure burden. Another source of difficulty was the limited oncological treatment options available for this patient and the patient only received cisplatin and etoposide. Additionally, the patient's cancer was not amenable to surgical management. He also was not neurologically stable enough to undergo radiotherapy. The case was also unusual in that SCPCs usually arise after androgen deprivation therapy for use of primary prostate adenocarcinoma, but this patient had de novo disease that was associated with paraneoplastic syndrome.

### Learning points

- ▶ Seizures secondary to paraneoplastic phenomena are difficult to treat and require a combined approach of antiepileptic therapy, immunosuppression and treatment of underlying malignancy.
- ▶ GABA<sub>B</sub>R antibodies usually occur secondary to small cell lung cancers but can occur secondary to other small cell cancers in other sites.
- ▶ Primary small cell prostate cancers (SCPCs) are rare and usually occur after androgen deprivation therapy for primary prostate adenocarcinoma as opposed to de novo disease.
- ▶ Treatment options for SCPC are limited and prognosis is poor.

**Contributors** Supervised by CoG. Patient under the care of CoG. Report written by CK, AS and CoG.

**Funding** The authors have not declared a specific grant for this research from any funding agency in the public, commercial or not-for-profit sectors.

**Competing interests** None declared.

**Patient consent for publication** Next of kin consent obtained.

**Provenance and peer review** Not commissioned; externally peer reviewed.

**Open access** This is an open access article distributed in accordance with the Creative Commons Attribution Non Commercial (CC BY-NC 4.0) license, which permits others to distribute, remix, adapt, build upon this work non-commercially, and license their derivative works on different terms, provided the original work is properly cited and the use is non-commercial. See: <http://creativecommons.org/licenses/by-nc/4.0/>.

### ORCID iD

Christopher Kwan <http://orcid.org/0000-0002-3775-4370>

### REFERENCES

- 1 Chalifoux JR, Carter AG. GABAB receptor modulation of synaptic function. *Curr Opin Neurobiol* 2011;21:339–44.
- 2 Qiao S, Zhang Y-X, Zhang B-J, et al. Clinical, imaging, and follow-up observations of patients with anti-GABA<sub>B</sub> receptor encephalitis. *Int J Neurosci* 2017;127:379–85.
- 3 Ulrich D, Bettler B. GABA(B) receptors: synaptic functions and mechanisms of diversity. *Curr Opin Neurobiol* 2007;17:298–303.
- 4 Benarroch EE. GABAB receptors: structure, functions, and clinical implications. *Neurology* 2012;78:578–84.
- 5 Cortez MA, McKerlie C, Snead OC. A model of atypical absence seizures: EEG, pharmacology, and developmental characterization. *Neurology* 2001;56:341–9.
- 6 Lancaster E, Lai M, Peng X, et al. Antibodies to the GABA(B) receptor in limbic encephalitis with seizures: case series and characterisation of the antigen. *Lancet Neurol* 2010;9:67–76.
- 7 Ramanathan S, Mohammad SS, Brilot F, et al. Autoimmune encephalitis: recent updates and emerging challenges. *J Clin Neurosci* 2014;21:722–30.
- 8 Krueger MC, Hoeflberger R, Lim KY, et al. Aggressive course in encephalitis with opsoclonus, ataxia, chorea, and seizures: the first pediatric case of  $\gamma$ -aminobutyric acid type B receptor autoimmunity. *JAMA Neurol* 2014;71:620–3.
- 9 Höftberger R, Titulaer MJ, Sabater L, et al. Encephalitis and GABAB receptor antibodies: novel findings in a new case series of 20 patients. *Neurology* 2013;81:1500–6.
- 10 Dalmau J, Rosenfeld MR. Autoimmune encephalitis update. *Neuro Oncol* 2014;16:771–8.
- 11 Leypoldt F, Armangue T, Dalmau J. Autoimmune encephalopathies. *Ann NY Acad Sci* 2015;1338:94–114.
- 12 Graus F, Titulaer MJ, Balu R, et al. A clinical approach to diagnosis of autoimmune encephalitis. *Lancet Neurol* 2016;15:391–404.
- 13 Zekeridou A, Majed M, Heliopoulos I, et al. Paraneoplastic autoimmunity and small-cell lung cancer: neurological and serological accompaniments. *Thorax Cancer* 2019;10:1001–4.
- 14 Beltran H, Tagawa ST, Park K, et al. Challenges in recognizing treatment-related neuroendocrine prostate cancer. *J Clin Oncol* 2012;30:e386–9.
- 15 Suzuki K, Terakawa T, Kimbara S, et al. Amrubicin for patients with platinum-refractory small-cell prostate cancer: two case reports. *Clin Genitourin Cancer* 2020;18:e324–9.
- 16 Palmgren JS, Karavadia SS, Wakefield MR. Unusual and underappreciated: small cell carcinoma of the prostate. *Semin Oncol* 2007;34:22–9.
- 17 de Bruijn MAAM, van Sonderen A, van Coevorden-Hameete MH, et al. Evaluation of seizure treatment in anti-LG11, anti-NMDAR, and anti-GABA<sub>B</sub> receptor encephalitis. *Neurology* 2019;92:e2185–96.
- 18 Dutra LA, Abrantes F, Toso FF, et al. Autoimmune encephalitis: a review of diagnosis and treatment. *Arq Neuropsiquiatr* 2018;76:41–9.
- 19 Aggarwal R, Zhang T, Small EJ, et al. Neuroendocrine prostate cancer: subtypes, biology, and clinical outcomes. *J Natl Compr Canc Netw* 2014;12:719–26.
- 20 Aparicio AM, Harzstark AL, Corn PG, et al. Platinum-based chemotherapy for variant castrate-resistant prostate cancer. *Clin Cancer Res* 2013;19:3621–30.

Copyright 2020 BMJ Publishing Group. All rights reserved. For permission to reuse any of this content visit <https://www.bmj.com/company/products-services/rights-and-licensing/permissions/>  
BMJ Case Report Fellows may re-use this article for personal use and teaching without any further permission.

Become a Fellow of BMJ Case Reports today and you can:

- ▶ Submit as many cases as you like
- ▶ Enjoy fast sympathetic peer review and rapid publication of accepted articles
- ▶ Access all the published articles
- ▶ Re-use any of the published material for personal use and teaching without further permission

### Customer Service

If you have any further queries about your subscription, please contact our customer services team on +44 (0) 207111 1105 or via email at [support@bmj.com](mailto:support@bmj.com).

Visit [casereports.bmj.com](http://casereports.bmj.com) for more articles like this and to become a Fellow