

# Spontaneous Cerebral Spinal Fluid Rhinorrhea with Meningocele Secondary to Congenital Foramen Rotundum Defect: A Case Report and Review of Literature

## Abstract

Spontaneous cerebrospinal fluid (CSF) rhinorrhea is a rare occurrence. We present a case of spontaneous CSF rhinorrhea in a 57-year-old patient secondary to a sphenoid osseous defect involving the foramen rotundum and maxillary nerve with an associated arachnoid cyst and meningocele compressing the maxillary nerve. The location of the defect made correction amenable to an open skull-based approach. To the best of our knowledge, this is the first reported case of a spontaneous meningocele herniating into the sphenoid osseous defect through the medial aspect of the foramen rotundum. Early detection of these defects, open or endoscopic approaches and definitive treatment by closing the defect can result in excellent outcomes.

**Keywords:** *Arachnoid cyst, cerebral spinal fluid leak, meningocele, skull base defect, spontaneous rhinorrhea*

## Introduction

Cerebrospinal fluid (CSF) rhinorrhea is a well-documented phenomenon, with most cases being attributable to causes such as trauma, neoplasms, postsurgical complications, and congenital defects. Spontaneous CSF leaks are uncommon and the least understood of these etiologies.<sup>[1]</sup> Spontaneous CSF rhinorrhea occurs with comorbidities such as obesity, middle- to older-aged individuals, and increased intracranial pressures, and it is found to be more common in females.<sup>[2]</sup> Frequently misdiagnosed by primary care as allergic rhinitis, literature reports failure to treat this rare cause of CSF rhinorrhea, can increase the risk of meningitis from 10% to 32%.<sup>[3]</sup> Present treatment options include transnasal endoscopic approaches but are limited by the location of the defect, accessibility, and experience of the treating surgical team. Open skull-based approaches are reserved for more complex defects and locations.<sup>[4,5]</sup>

## Case Report

A 57-year-old woman presented to her primary care physician with a 2–3-year history of rhinitis, intermittent clear

discharge, a chronic nonproductive cough, and recent pneumonia. In recent few months, her cough had significantly worsened, she could not sleep supine as this aggravated her symptoms, and more recently, while sitting, she could feel clear drops running down her throat and spontaneously emerging from her left nostril. She had a history of worsening headaches in the past 4 weeks and was referred to the otolaryngologist for the evaluation of chronic allergic rhinosinusitis.

The patient underwent a nasal endoscopic evaluation and a left-sided lateral skull base defect appeared to be the location of the CSF leak. Subsequent referral to neurosurgery for evaluation and definitive surgical treatment was done, with meningitis workup being negative. Further imaging included computed tomographic (CT) scan that revealed an osseous defect between the roof of the left sphenoid sinus and the floor of the left middle cranial fossa, immediately adjacent to the foramen rotundum [Figure 1a-c]. Magnetic resonance imaging ((MRI) revealed fluid buildup in the left sphenoid sinus [Figure 2a-c]. The elevated risk of meningitis and worsening symptoms and

**Kyle William Scott, Daryoush Tavanaiepour<sup>1</sup>, Kourosh Tavanaiepour<sup>1</sup>, Akaber Halawi<sup>2</sup>, Dinesh Rao<sup>3</sup>, Gazanfar Rahmathulla<sup>1</sup>**

*Department of Neurosurgery, College of Medicine, University of Florida, Gainesville, Departments of <sup>1</sup>Neurosurgery, <sup>2</sup>Otolaryngology and <sup>3</sup>Radiology, College of Medicine, University of Florida, Jacksonville, Florida, USA*

**Address for correspondence:**  
Dr. Gazanfar Rahmathulla,  
Department of Neurosurgery,  
College of Medicine, University  
of Florida, 580w 8<sup>th</sup> Street,  
8<sup>th</sup> Floor, Clinical Tower 1,  
Jacksonville, Florida 32209,  
USA.

E-mail: [gazanfar.rahmathulla@jax.ufl.edu](mailto:gazanfar.rahmathulla@jax.ufl.edu)

### Access this article online

**Website:** [www.asianjns.org](http://www.asianjns.org)

**DOI:** 10.4103/ajns.AJNS\_228\_19

### Quick Response Code:



**How to cite this article:** Scott KW, Tavanaiepour D, Tavanaiepour K, Halawi A, Rao D, Rahmathulla G. Spontaneous cerebral spinal fluid rhinorrhea with meningocele secondary to congenital foramen rotundum defect: A case report and review of literature. *Asian J Neurosurg* 2020;15:187-9.

**Submission:** 16-07-2019      **Accepted:** 18-09-2019  
**Published:** 25-02-2020

This is an open access journal, and articles are distributed under the terms of the Creative Commons Attribution-NonCommercial-ShareAlike 4.0 License, which allows others to remix, tweak, and build upon the work non-commercially, as long as appropriate credit is given and the new creations are licensed under the identical terms.

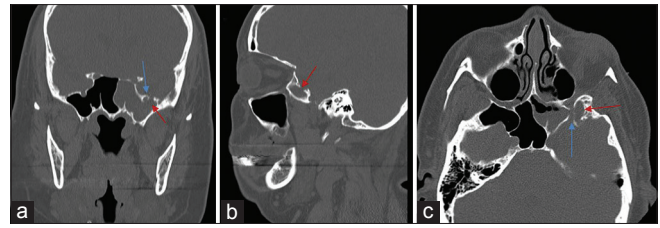
For reprints contact: [reprints@medknow.com](mailto:reprints@medknow.com)

signs required expedient surgical intervention. Given the lateral location of the defect, we favored a left anterior lateral skull base approach with an orbito-zygomatic osteotomy rather than an endoscopic approach.

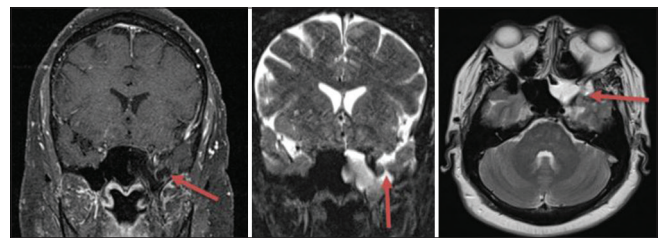
The vascularized pericranium was preserved along with the temporalis, and pericranium used as a pedicle flap to cover the defect.<sup>[6]</sup> The foramen rotundum and the V2 component of the trigeminal nerve were identified, with the defect being contiguous with them. The osseous defect demonstrated infiltration of meningocele into the sphenoid sinus [Figure 3a], which was later confirmed during the surgery. The nerve was visibly stretched out and under tension with and overlying arachnoid cyst that was causing bowing and displacement of the nerve [Figure 3b]. Two additional defects within the dura were visualized and the arachnoid meningocele was observed to be contiguous with the sleeve of the trigeminal nerve. The arachnoid cyst was incised, with CSF drainage followed by nerve decompression [Figure 3c]. The arachnoid cyst was resected under the microscope with a band of dura seen across the foramen rotundum. A 2 cm × 2 cm Duragen with a slit in the center was created and placed with the trigeminal nerve within the slit and then using the Duragen to circumferentially cover the opening of the dura and trigeminal nerve as well as the small punctate openings that were nearby. CSF flow appeared to decrease significantly. Fibrin glue was then used over this to get better hemostasis and a watertight CSF seal. The vascularized pericranial flap was then rotated and used to cover the anterior lateral middle fossa, including the foramen rotundum and defect. The pericranium was held in place with sutures and fibrin glue [Figure 3d]. We inserted a lumbar drain for 48 h allowing CSF diversion and healing of the defect. The patient was mobilized within the first 24 h with complete cessation of the leak.

## Discussion

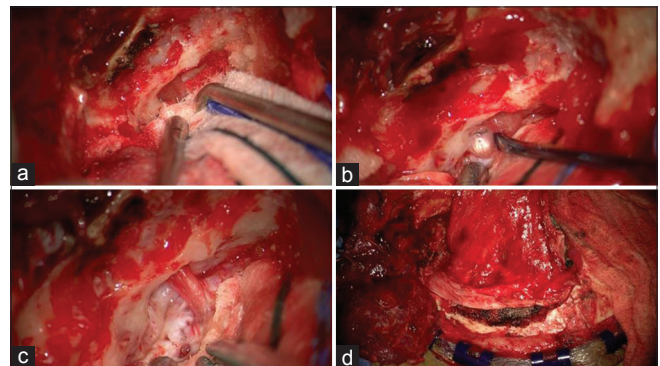
There have been numerous papers demonstrating the common and unique etiologies of CSF rhinorrhea, revealing most of these cases demonstrate brain herniation (82%), arachnoid pits (63%), extensive pneumatization of the sphenoid sinus (91%), and an empty sella (63%).<sup>[7]</sup> The most common anatomical locations for CSF leaks have been those with the thinnest bone segments, namely the cribriform plate, tegmen, the ethmoidalis, and the sphenoid sinus.<sup>[5,7,8]</sup> The most commonly documented osseous defect is through the lateral sphenoid sinus, specifically through the Sternberg canal.<sup>[9]</sup> In fact, this report is the only documented occurrence of a meningocele protrusion involving the foramen rotundum and maxillary nerve. The most common defect in the sphenoid sinus is commonly associated with a compromised lateral pterygoid recess. The diagnosis of spontaneous CSF leaks is clinical, with radiological investigations to confirm the location and plan intervention. Radiological imaging using MRI and CT help identify the anatomical location of the defect.



**Figure 1:** (a) Coronal unenhanced computed tomography image of the face demonstrating an osseous defect within the roof of the left sphenoid sinus (red arrow) lateral to foramen rotundum (blue arrow). Note the dehiscence of the inferior margin of foramen rotundum. (b) Sagittal unenhanced computed tomography image of the face demonstrating an osseous defect within the roof of the left sphenoid sinus (red arrow). (c) Axial unenhanced computed tomography image of the face demonstrating an osseous defect within the floor of the left middle cranial fossa (red arrow) adjacent to foramen rotundum (blue arrow). Note the opacification of the left sphenoid sinus



**Figure 2:** (a) Coronal T1 FS image with gadolinium demonstrating fluid-filled structure (red arrow) extending from the left middle cranial fossa into the left sphenoid sinus. This was confirmed to be a meningocele during surgery. (b) Coronal T2 fat saturated image demonstrating fluid extending from the floor of the left middle cranial fossa into the left sphenoid sinus (red arrow). (c) Axial T2-weighted magnetic resonance imaging at the level of the floor of the middle cranial fossa demonstrating fluid within the left sphenoid sinus. Note the left trigeminal V2 branch within foramen rotundum (red arrow)



**Figure 3:** (a) Left middle fossa zygomatic approach. Extradural dynamic retraction of the anterior middle fossa exposing the V2 nerve under tension extracting through the foramen rotundum. (b) Mobilization of the V2 nerve exposing the meningocele exiting through the foramen rotundum into the sphenoid sinus. (c) Following the resection of the meningocele, the V2 nerve is decompressed, and the enlarged foramen rotundum and dural deficit are visualized. (d) After direct repair of the dura deficit, a vascularized pericranial flap was rotated along the floor of the middle fossa

Various mechanisms leading to CSF leaks have been reported from blunt trauma to congenital defects, and the speculative hypothesis of a ruptured arachnoid diverticulum within the middle cranial fossa.<sup>[10]</sup> Elevated intracranial pressure is thought to lead to impaired CSF reabsorption

at arachnoid granulations, resulting in the development of arachnoid villi in locations with little venous drainage, specifically, in the middle cranial fossa.<sup>[11]</sup> While the exact etiology in the case of our patient may be impossible to determine, the presence of such arachnoid granulations may be the cause, supported by the intraoperative identification of an arachnoid cyst at the site of the defect.

Regardless of the etiology, the surgical approach to repair skull base defects varies by surgeon preferences and the anatomical challenges that are unique in each case. High success rates have been reported utilizing endoscopic approaches (95%) along with bone grafts in osseous defect restoration.<sup>[5,12,13]</sup> Alternatively, success is evident with the use of ventriculoperitoneal shunts to divert CSF flow.<sup>[14]</sup> Transcranial skull-based approaches are advantageous in the ability to directly visualize the intradural and extradural osseous defect, with the increased invasiveness, possibly resulting in greater morbidity and longer hospital stay.<sup>[4]</sup> Given that spontaneous CSF leaks have the highest recurrence rate of any other etiology, the best procedure for any case will likely depend on specific challenges vary on a case-by-case basis.<sup>[15]</sup>

## Conclusion

We report a case of spontaneous CSF rhinorrhea secondary to a congenital sphenoid osseous defect involving the foramen rotundum and maxillary nerve, treated through a direct open skull base approach with complete resolution. To the best of our knowledge, this is the first documented case of this rare osseous defect and its direct treatment.

## Patient consent

The patient/next of kin/guardian has consented to the submission of the case report for submission to the journal.

## Declaration of patient consent

The authors certify that they have obtained all appropriate patient consent forms. In the form, the patient has given her consent for her images and other clinical information to be reported in the journal. The patient understands that name and initials will not be published and due efforts will be made to conceal identity, but anonymity cannot be guaranteed.

## Financial support and sponsorship

Nil.

## Conflicts of interest

There are no conflicts of interest.

## References

1. Har-El G. What is "spontaneous" cerebrospinal fluid rhinorrhea? Classification of cerebrospinal fluid leaks. *Ann Otol Rhinol Laryngol* 1999;108:323-6.
2. Martínez-Capoccioni G, Serramito-García R, Martín-Bailón M, García-Allut A, Martín-Martín C. Spontaneous cerebrospinal fluid leaks in the anterior skull base secondary to idiopathic intracranial hypertension. *Eur Arch Otorhinolaryngol* 2017;274:2175-81.
3. DeConde AS, Suh JD, Ramakrishnan VR. Treatment of cerebrospinal fluid rhinorrhea. *Curr Opin Otolaryngol Head Neck Surg* 2015;23:59-64.
4. Kizmazoglu C, Firat L, Ozyoruk S, Kalemci O, Karabay N, Ozer E. Success rate and complications of cerebrospinal fluid rhinorrhea treated with a transcranial approach. *J Craniofac Surg* 2018;29:e808-12.
5. Woodworth BA, Prince A, Chiu AG, Cohen NA, Schlosser RJ, Bolger WE, *et al.* Spontaneous CSF leaks: A paradigm for definitive repair and management of intracranial hypertension. *Otolaryngol Head Neck Surg* 2008;138:715-20.
6. Al-Mefty O. How to perform cranio-orbital zygomatic approaches. In: Sindou M, editors. *Practical Handbook of Neurosurgery*. Vienna: Springer; 2009. p. 99-113.
7. Shetty PG, Shroff MM, Fatterpekar GM, Sahani DV, Kirtane MV. A retrospective analysis of spontaneous sphenoid sinus fistula: MR and CT findings. *AJNR Am J Neuroradiol* 2000;21:337-42.
8. Tóth M, Selivanova O, Schaefer S, Mann W. Spontaneous cerebrospinal fluid rhinorrhea: A clinical and anatomical study. *Laryngoscope* 2010;120:1724-9.
9. Barañano CF, Curé J, Palmer JN, Woodworth BA. Sternberg's canal: Fact or fiction? *Am J Rhinol Allergy* 2009;23:167-71.
10. Simmonds JC, Scott AR. Spontaneous CSF rhinorrhea from the trigeminal canal in an adolescent. *Int J Pediatr Otorhinolaryngol* 2017;98:162-5.
11. Alonso RC, de la Peña MJ, Caicoya AG, Rodriguez MR, Moreno EA, de Vega Fernandez VM. Spontaneous skull base meningoencephaloceles and cerebrospinal fluid fistulas. *Radiographics* 2013;33:553-70.
12. Asad S, Peters-Willke J, Brennan W, Asad S. Clival defect with primary CSF rhinorrhea: A very rare presentation with challenging management. *World Neurosurg* 2017;106:1052.e1-000.
13. Kljajić V, Vuleković P, Vlaški L, Savović S, Dragičević D, Papić V. Endoscopic repair of cerebrospinal fluid rhinorrhea. *Braz J Otorhinolaryngol* 2017;83:388-93.
14. Darouassi Y, Mliha Touati M, Chihani M, Akhaddar A, Ammar H, Bouaity B. Spontaneous cerebrospinal fluid leak of the sphenoid sinus mimicking allergic rhinitis, and managed successfully by a ventriculoperitoneal shunt: A case report. *J Med Case Rep* 2016;10:308.
15. Chaaban MR, Illing E, Riley KO, Woodworth BA. Spontaneous cerebrospinal fluid leak repair: A five-year prospective evaluation. *Laryngoscope* 2014;124:70-5.