

Solitary neurofibroma of the palate mimicking mucocele: A rare case report

Prasanna Sekhar¹, G Nandhini², K Raj Kumar², A Ramesh Kumar²

¹Department of Oral and Maxillofacial Pathology, Tagore Dental College and Hospital, ²Department of Oral and Maxillofacial Pathology, SRM Dental College and Hospital, Chennai, Tamil Nadu, India

Abstract

Neurofibroma is a benign, slow-growing, peripheral nerve neoplasm. It presents as a solitary tumor or component of neurofibromatosis (NF) and von Recklinghausen's disease. The occurrence of solitary neurofibromas in the oral cavity is less frequent, and those in the palate are reported in less numbers. This report describes an unusual case of solitary neurofibroma in the hard palate which clinically mimicked a mucocele.

Keywords: Hard palate, mucocele, rare neural tumors, solitary neurofibroma

Address for correspondence: Dr. Prasanna Sekhar, Department of Oral and Maxillofacial Pathology, Tagore Dental College and Hospital, Chennai - 600 127, Tamil Nadu, India.

E-mail: dr.prasanna1oralpath@gmail.com

Received: 08.08.2018, **Accepted:** 29.11.2018

INTRODUCTION

Neurofibroma is the most common type of benign, slow-growing, peripheral nerve neoplasm, which arises from a mixture of cell types such as Schwann cells and perineural fibroblasts.^[1] It can arise as a solitary tumor or be a component of NF and von Recklinghausen's disease. Solitary neurofibromas are not frequently seen in the oral cavity, and those in the palate are reported in less numbers.^[2] This report describes an unusual case of solitary neurofibroma in the hard palate which clinically mimicked a mucocele.

CASE REPORT

A 55-year-old female reported with a complaint of swelling in the left upper jaw for the past 1 month. A history revealed that the swelling was initially small in size and gradually increased in size and was associated with pain. A medical history revealed that the patient is a known hypertensive

and diabetic for the past 3 years and is under medication for the same. General examination revealed no lymph node enlargement or any other swellings.

Intraoral examination revealed a single, well-circumscribed, smooth-surfaced swelling in the left side of the anterior part of the hard palate measuring about 0.5 cm × 0.5 cm in size. Palpation revealed that the swelling was soft in consistency, fluctuant and nontender. The mucosa appeared to be normal [Figure 1].

Routine blood investigations were done and were found to be within normal limits. Maxillary intraoral periapical and occlusal radiograph was taken and showed no abnormality. A clinical diagnosis of mucocele was given.

Under local anesthesia, the swelling was completely surgically excised, and the tissue was fixed in 10% formalin and sent for histopathological diagnosis [Figure 2].

This is an open access journal, and articles are distributed under the terms of the Creative Commons Attribution-NonCommercial-ShareAlike 4.0 License, which allows others to remix, tweak, and build upon the work non-commercially, as long as appropriate credit is given and the new creations are licensed under the identical terms.

For reprints contact: reprints@medknow.com

How to cite this article: Sekhar P, Nandhini G, Kumar KR, Kumar AR. Solitary neurofibroma of the palate mimicking mucocele: A rare case report. J Oral Maxillofac Pathol 2019;23:S23-6.

Access this article online

Quick Response Code:



Website:

www.jomfp.in

DOI:

10.4103/jomfp.JOMFP_196_18

Microscopic examination of the excised tissue by routine hematoxylin and eosin staining revealed a cellular mass of tissue composed of interlacing bundles of spindle-shaped cells exhibiting wavy nuclei and associated with delicate collagen fibers and mast cells and separated from the superficial parakeratinized stratified squamous epithelium by the grenz zone [Figure 3].

Toluidine blue staining was also done to demonstrate the mast cells [Figure 4]. Immunohistochemistry showed scattered positivity for S-100 protein [Figure 5].

Based on the histopathological and immunohistochemical findings, the swelling was diagnosed as solitary neurofibroma.

The patient was reviewed after 2 weeks and showed no recurrence.

DISCUSSION

Neurofibroma is a benign peripheral nerve sheath tumor which arises from Schwann cells and peripheral fibroblasts.

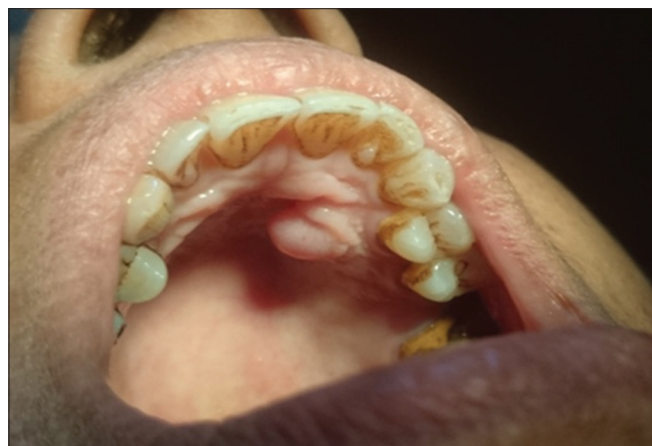

Figure 1: Intraoral view showing smooth localized swelling

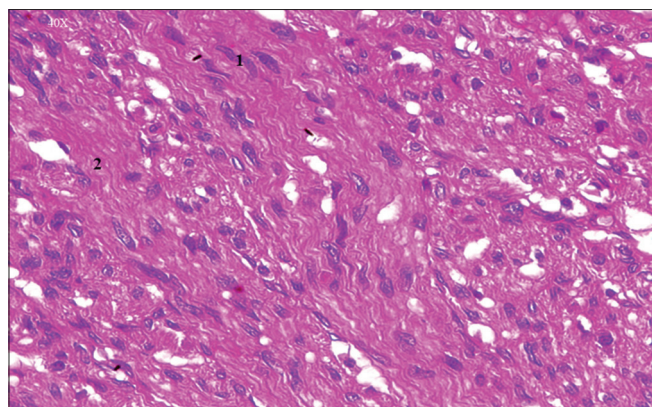


Figure 3: Histopathology showing interlacing bundles of spindle-shaped cells exhibiting wavy nuclei in association with delicate collagen fibers and mast cells (H&E, $\times 20$)

Neurofibroma can either be seen as solitary (sporadic) or as a part of a syndrome-NF. The WHO has classified neurofibromas into circumscribed (solitary) and plexiform type. A single peripheral nerve can give rise to dermal type, and multiple nerve bundles are associated with plexiform type.^[3]

Solitary tumors are most common in young adults and present as slow-growing, soft, painless lesions that vary in size from small nodules to larger masses. The skin is the most frequent location for neurofibromas, but lesions of the oral cavity are not uncommon.^[1] Among 66 neurofibromas in the facial region, the following distribution was found in the literature: tongue and palate – 12, mandibular ridge/vestibule – 15, maxillary ridge/vestibule – 9, buccal mucosa – 10, lip – 4, mandibular intrabony – 2 and gingiva – 1.^[2]

Clinically, the solitary neurofibroma is well circumscribed, especially when the proliferation occurs within the perineurium of the involved nerve. Tumors that proliferate outside the perineurium may not appear well demarcated and tend to blend with the adjacent connective tissues.^[1]

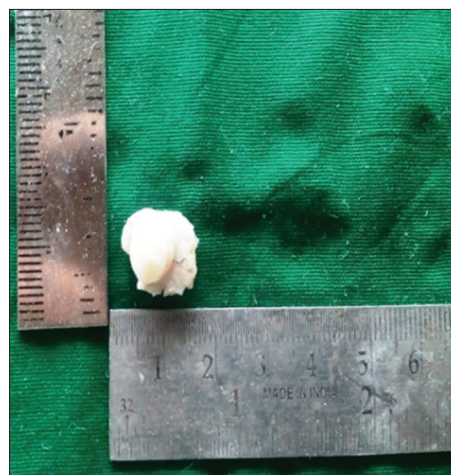


Figure 2: Gross picture

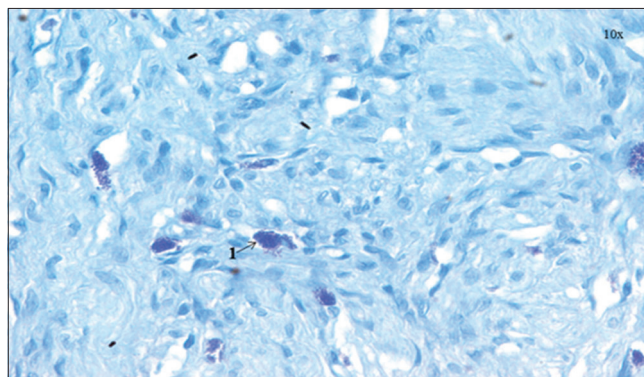


Figure 4: Toluidine blue staining exhibiting mast cells ($\times 20$)

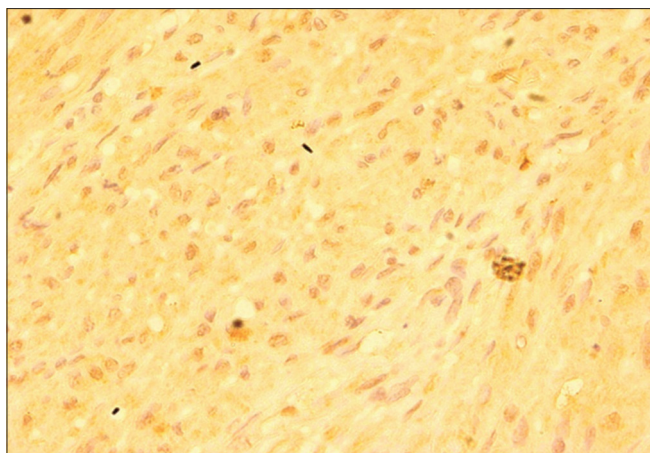


Figure 5: Scattered positivity for S - 100 (IHC, x 20)

In the oral cavity, the neurofibroma appears as discrete, nonulcerated nodule, which is usually the same color as that the adjacent mucosa. It is usually noted in the buccal mucosa, palate, alveolar ridge, vestibule and tongue, and they are composed of the same tissue as that seen in the isolated lesion. Sometimes, neurofibroma may be seen within the jaw, especially the mandible which is associated with mandibular nerve and radiographically appears as a fusiform enlargement of the mandibular canal.^[4]

Distinguishing between isolated neurofibromas and those associated with NF-1 is important because the treatment and prognosis differ greatly. Neurofibroma associated with NF-1 are more likely to recur or undergo malignant transformation.^[2]

Histopathologically, neurofibroma is characterized by the presence of spindle cells with wavy nuclei and is not encapsulated.^[5] These tumors have a bland cytological appearance, with serpiginous nucleocytoplasmic contours and infiltrative poorly delimited boundaries.^[6] Degenerative nuclear pleomorphism may be present (bizarre or atypical neurofibroma). The presence of mitotic activity in neurofibroma is indicative of malignancy.^[7] There is stromal mucin deposition and fibroplasia. Axons course through the tumor, which is difficult to find in routine sections and can be traced using immunohistochemical stains for neurofilament.^[8] Mast cells are seen within the tumor.

Mast cells are formed in the bone marrow and are released into the blood and differentiate when they leave the vasculature and get incorporated into the target tissues. Mature mast cells are normally found in the endoneurial, perineurial and epineurial spaces of peripheral nerves. Accumulation of mast cells intensifies when the nerve is damaged and/or if the nerve is in the process of repair. Mast cells play an important role in neurofibroma development

in NF1 mouse models, but it is not clear whether the mast cell distribution is same in the murine neurofibromas as in the human tumors. Mast cell number and distribution within neurofibromas is done by toluidine blue staining.^[9]

Toluidine blue is one of the most common stains for acid mucopolysaccharides and glycosaminoglycans, which is present in granules of the mast cells.^[10] In the tissue sections stained with 0.1% toluidine blue, mast cell presents with a pale blue -stained nucleus and dark blue/violet grains in the cytoplasm representing the secretory vesicles.

S-100 is a group of low-molecular-weight proteins, which has two calcium-binding sites that have helix–loop–helix conformation. The family comprises around 21 types of S-100 proteins. They are normally seen in cells derived from the neural crest – Schwann cells, melanocytes, chondrocytes, adipocytes, myoepithelial cells, macrophages, Langerhans cells, dendritic cells and keratinocytes. S-100 is involved in numerous intracellular and extracellular functions.^[11-14] They are used as markers in certain tumors and epidermal differentiation. It is found in melanomas, 100% schwannomas, 100% neurofibromas, 50% of malignant peripheral nerve sheath tumour (MPNST), histiocytoma and clear cells sarcomas. They are also used as markers for inflammatory diseases and can mediate inflammation, and it acts as an antimicrobial compound.^[15,16] Neurofibromas are immunopositive for the S-100 protein in 85%–100% of the cases, indicating its neural origin.^[17]

Treatment protocol for solitary neurofibroma is surgical excision of the local tumor, and sometimes, malignant transformation is reported in some cases. In situation where the lesion cannot be separated from the originating nerve, the concerned nerve may be amputated. In multiple neurofibroma, the tumor may be excised due to airway obstruction or esthetic reasons, but it is difficult when they are numerous.^[18] In the present case, the tumor was completely excised and the patient was under regular review for the past 1 year with no signs of recurrence.

CONCLUSION

Solitary neurofibroma can be considered in the differential diagnosis of various intraoral nodules along with mucocele and fibroma. We have reported a case of neurofibroma in palate which is a rare benign tumor, and it was mimicking as mucocele. The diagnosis of neurofibroma was given based on clinical history, radiographic, histopathological, special stains and immunohistochemical studies. The patient was kept under periodic review and no history of recurrence for the past 1 year.

Declaration of patient consent

The authors certify that they have obtained all appropriate patient consent forms. In the form the patient(s) has/have given his/her/their consent for his/her/their images and other clinical information to be reported in the journal. The patients understand that their names and initials will not be published and due efforts will be made to conceal their identity, but anonymity cannot be guaranteed.

Financial support and sponsorship

Nil.

Conflicts of interest

There are no conflicts of interest.

REFERENCES

- Neville BW, Damm DD, Allen CM, Jerry E. Bouquot. Oral and Maxillofacial Pathology. 3rd Edition. Philadelphia; WB Saunders Company 2013. p. 528.
- Maruyama M, Fushiki H & Watanabe, Y. Solitary neurofibroma of the floor of the mouth: a case report. Case reports in otolaryngology 2011;2011:1-3.
- Lin IC, Chin YW. Solitary diffuse neurofibroma of tongue – Case report. Taiwan J Oral Maxillofac Surg 2012;23:187-96.
- Rajendran R, Sivapathasundaram B. Benign and malignant tumours of the oral cavity, Ch. 2.8, Benign tumours of Nerve tissue origin. Shafer's Textbook of Oral Pathology. 6th ed., Ch. 2. Elsevier, India, 2009:198.
- Behbehani EM, Al-Ramzi AH, Mohamed EA. Oral manifestations of neurofibromatosis: Case report. Dent News 1977;4:17-21.
- Narwal A, Saxena S, Rathod V, Bansal P. Intraoral solitary neurofibroma in an infant. J Oral Maxillofac Pathol 2008;12:75-8.
- Available from: <http://www.histopathology-india.net/SoftTissuePath.htm>.
- Available from: <http://www.dermnetnz.org/pathology/neurofibroma-path.html>.
- Tucker T, Riccardi VM, Sutcliffe M, Vielkind J, Wechsler J, Wolkenstein P, *et al.* Different patterns of mast cells distinguish diffuse from encapsulated neurofibromas in patients with neurofibromatosis 1. J Histochem Cytochem 2011;59:584-90.
- Blumenkrantz N, Asboe-Hansen G. A selective stain for mast cells. Histochem J 1975;7:277-82.
- Wilson AJ, Maddox PH, Jenkins D. CD1a and S100 antigen expression in skin Langerhans cells in patients with breast cancer. J Pathol 1991;163:25-30.
- Coppola D, Fu L, Nicosia SV, Kounelis S, Jones M. Prognostic significance of p53, bcl-2, vimentin, and S100 protein-positive Langerhans cells in endometrial carcinoma. Hum Pathol 1998;29:455-62.
- Shinzato M, Shamoto M, Hosokawa S, Kaneko C, Osada A, Shimizu M, *et al.* Differentiation of Langerhans cells from interdigitating cells using CD1a and S-100 protein antibodies. Biotech Histochem 1995;70:114-8.
- Donato R. Intracellular and extracellular roles of S100 proteins. Microsc Res Tech 2003;60:540-51.
- Nonaka D, Chiriboga L, Rubin BP. Differential expression of S100 protein subtypes in malignant melanoma, and benign and malignant peripheral nerve sheath tumors. J Cutan Pathol 2008;35:1014-9.
- Wolf R, Ruzicka T, Yuspa SH. Novel S100A7 (psoriasin)/S100A15 (koebnerisin) subfamily: Highly homologous but distinct in regulation and function. Amino Acids 2011;41:789-96.
- Johann AC, Caldeira PC, Souto GR, de Freitas JB, Mesquita RA. Extra-osseous solitary hard palate neurofibroma. Rev Bras Otorrinolaringol 2008;74:317.
- Rodrigues Johann AC, Caldeira PC, Souto GR, de Freitas JB, Mesquita RA, Kouhsoltani M, *et al.* Solitary neurofibroma of the lip: Report of a rare case. J Res Dent Maxillofac Sci 2015;11:241-4.