



## Case report

# Acute leukemia of ambiguous lineage with trisomy 4 as the sole cytogenetic abnormality: A case report and literature review

S. Moraveji<sup>a</sup>, A. Torabi<sup>b</sup>, Z. Nahleh<sup>a</sup>, S. Farrag<sup>a</sup>, S. Gaur<sup>a,\*</sup>

<sup>a</sup> Department of Internal Medicine, Texas Tech University, Paul L. Foster School of Medicine, 4801 Alberta Avenue, El Paso, TX 79905, USA

<sup>b</sup> Department of Pathology, Texas Tech University, Paul L. Foster School of Medicine, 4801 Alberta Avenue El Paso, TX 79905, USA

## ARTICLE INFO

## Article history:

Received 26 February 2014

Received in revised form

13 April 2014

Accepted 16 April 2014

Available online 2 May 2014

## Keywords:

Trisomy 4

Biphenotypic leukemia

Acute leukemia ambiguous lineage

c-Kit

## ABSTRACT

We describe a patient with acute leukemia of ambiguous lineage who had trisomy 4 as the sole cytogenetic abnormality. Clinical, pathological, immunophenotypic and molecular features are presented and compared with the previous 4 published cases. Over expression of c-kit, which is localized to chromosome 4, was documented on the leukemic blasts. Prognosis seems to be poor. Treatment with acute lymphoblastic leukemia like regimens seems to be superior compared to acute myeloid leukemia like regimens and allogeneic stem cell transplant is recommended after achieving remission.

© 2014 The Authors. Published by Elsevier Ltd. This is an open access article under the CC BY-NC-ND license (<http://creativecommons.org/licenses/by-nc-nd/3.0/>).

## 1. Introduction

The 2008 World health organization (WHO) defines acute leukemias with ambiguous lineage (ALAL) as those leukemias which show no clear differentiation towards either myeloid or lymphoid lineage. It includes acute undifferentiated leukemias which express no specific markers for both lineage and mixed phenotypic acute leukemia (MPAL) which express antigens of both myeloid and lymphoid lineage to such a degree that it is impossible to assign a specific lineage [1].

Cytogenetic abnormalities strongly influence prognosis in cases of acute leukemias. Amongst patients with MPAL, the most commonly reported cytogenetic abnormalities are t(9;22) affecting the Abelson (ABL) oncogene, chromosome 11 abnormalities affecting the mixed leukemia lineage (MLL) gene and a complex karyotype with 3 or more abnormalities [2,3].

Trisomy 4 as the sole cytogenetic abnormality in acute leukemia is quite unusual. It has a reported prevalence of 0.0655% in acute myeloid leukemia (AML) and is even less common in acute lymphoblastic leukemia (ALL) [4,5].

We describe a case of mixed phenotypic acute leukemia with trisomy 4 as the sole cytogenetic abnormality. A literature search describing other 4 published cases is also presented.

## 2. Case report

A 50 year old hispanic female was admitted to our hospital with a 1 week history of headaches, palpitations and fatigue. Her

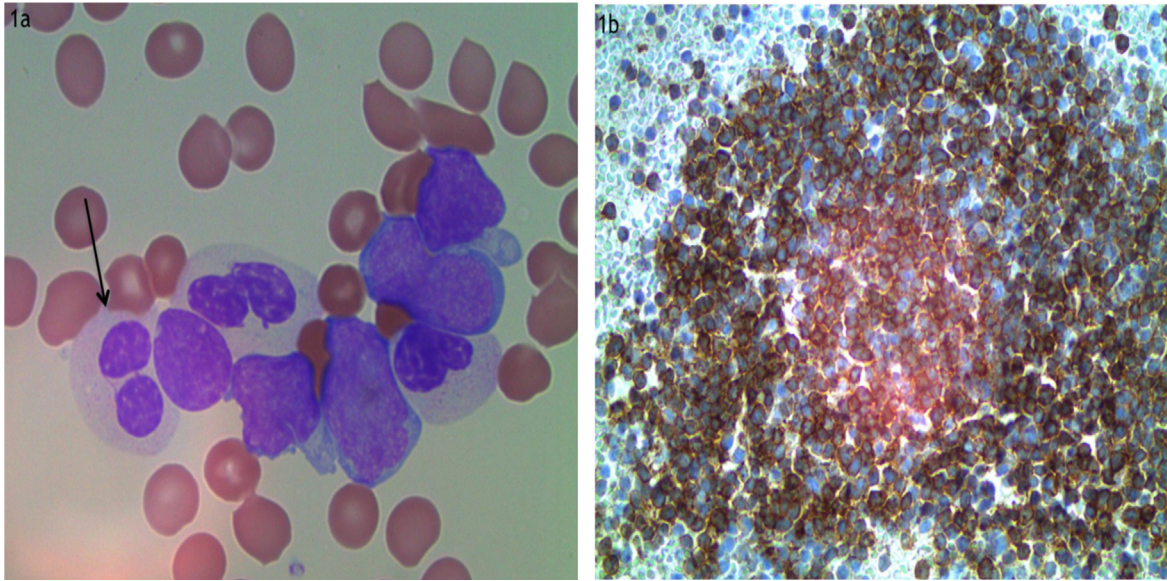
prior medical history was unremarkable. She worked as a waitress and had no known environmental exposure to carcinogenic agents. On the day of admission, she had a brief syncopal episode. On examination she had a temperature of 38.2 °C. Conjunctival and mucosal pallor was noted. Multiple 1–2 cm freely mobile lymph nodes were palpable in the cervical, sub mental and sub occipital regions. Spleen tip was palpable. A petechial rash was noted extending from the feet to the thighs. Complete blood counts revealed a white cell count of 403,000/μl, hemoglobin of 3.2 gm/dl and a platelet count of 6000/μl. Peripheral blood smear showed more than 50% of the nucleated cells to be leukemic blasts with high nuclear/cytoplasmic ratio, and minimally indented nuclei. Majority of circulating neutrophils showed dysplastic features in the form of hypo-lobate nuclei and hypo-granular cytoplasm (Fig. 1a). Platelets were markedly decreased in number. Kidney and liver functions were normal. Cerebrospinal fluid analysis was not consistent with leukemic meningitis.

Bone marrow showed 100% cellularity of which 95% was infiltration by blasts. The blasts had a high nuclear/cytoplasmic ratio and indented nuclei. Auer rods were not present. Strong c-kit expression was noted by immunohistochemistry (1b). Flow cytometry showed the blasts to express CD117, cytoplasmic CD3, CD2, CD7 and myeloperoxidase (MPO) (Fig. 2a–f).

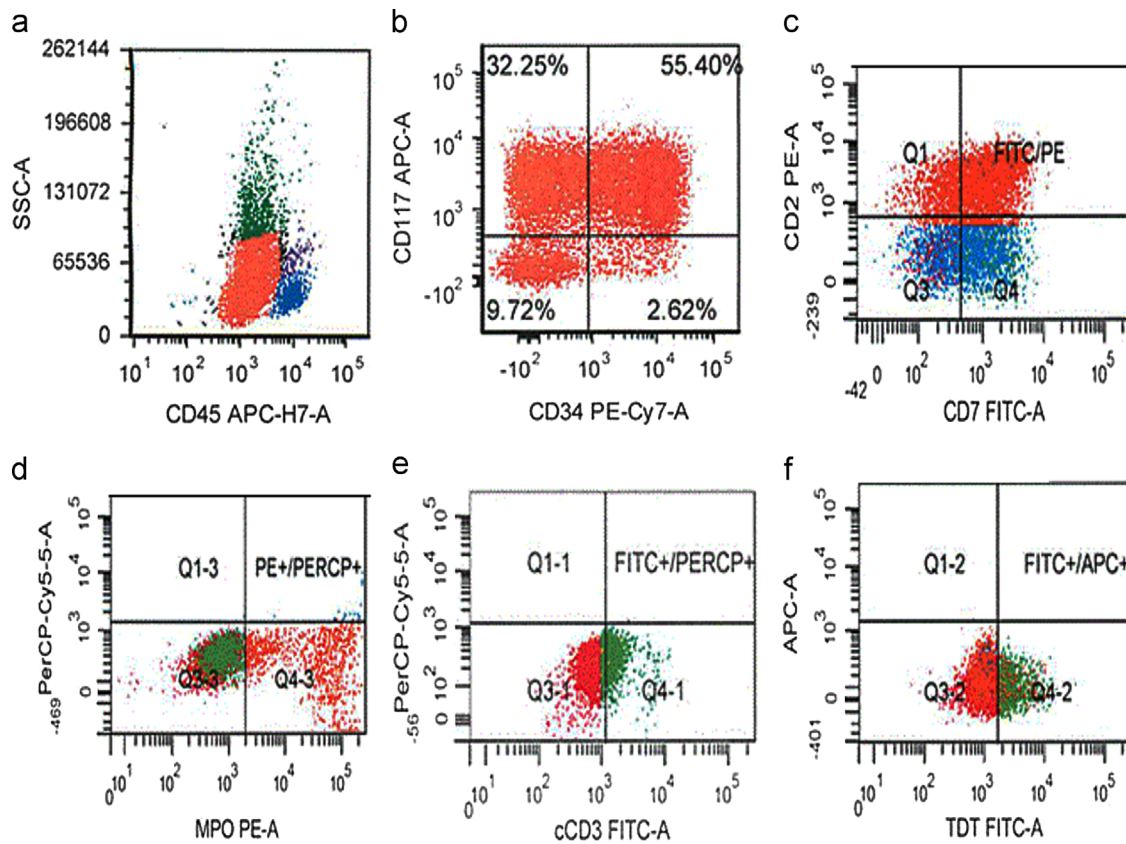
Fluorescent in situ hybridization (FISH) studies did not show bcr/abl (breakpoint cluster region/Abelsen), PML/RARA (promyelocytic leukemia/retinoic acid receptor alpha), CBFβ/MYH11 (core binding factorβ/myosin heavy chain11), AML1/ETO (acute myeloid leukemia 1/eight-twenty one), ETV6/RUNX1 (ETS variant 6/Runt related transcription factor 1) translocation or MLL (mixed lineage leukemia) gene rearrangement.

\* Corresponding author. Tel.: +1 915 449 7779; fax: +1 915 545 6635.

E-mail address: [sumit.gaur@ttuhsc.edu](mailto:sumit.gaur@ttuhsc.edu) (S. Gaur).



**Fig. 1.** Peripheral smear showing hypogranular, hypolobate neutrophils and leukemic blasts (1a) and bone marrow aspirate cell block showing strong expression of c-kit on leukemic blasts (1b).



**Fig. 2.** Flow cytometry plots. Leukemic blasts express CD45 and show low side scatter (a). They express CD34 and CD117 (b). They also express CD7, MPO, cytoplasmic CD3 and TDT (c–f).

Polymerase chain reaction (PCR) studies did not show T cell receptor  $\beta$  gene arrangement, CEBPA (CCAAT enhancer binding protein alpha) mutation or FLT3 (fms like tyrosine kinase 3) internal tandem duplication or tyrosine kinase domain mutation. No activating mutations in the c-kit gene were identified. Cytogenetic studies showed trisomy 4 in all 20 metaphases.

Patient was diagnosed with mixed phenotypic (t/myeloid) acute leukemia. She underwent emergent leukapheresis and was then

started on hyper-fractionated cyclophosphamide, vincristine, doxorubicin and dexamethasone (hyper CVAD) regimen. She also received intrathecal injections of methotrexate and cytarabine for CNS prophylaxis. A repeat bone marrow was obtained on day 27, when she had recovered her peripheral blood counts and was no longer requiring transfusion support. This showed complete morphologic and cytogenetic response which has been maintained after 7 additional cycles of alternating hyper CVAD, methotrexate and high dose

Table 1

Reference	Age (years)	Sex	Race	Country	Immuno-phenotype	CD117	Induction therapy	Complete response (duration)
6	22	Female	NR	Saudi Arabia	t-Myeloid	NR	Cytarabine, idarubicin	–
7	44	Male	NR	Italy	b-Myeloid	NR	Vincristine/daunorubicin/endoxan	+ (50 days)
8	5	Female	NR	Australia	t-Myeloid	NR	Vincristine/daunorubicin/cytarabine	–
9	24	Male	hispanic	US	t-Myeloid	NR	Cytarabine/daunorubicin	+ (10 months)
Present	50	Female	hispanic	US	t-Myeloid	+	Hyper CVAD	+ (6 months)

NR: not reported; –: not achieved; +: achieved, and hyper CVAD: hyper-fractionated cyclophosphamide, vincristine, doxorubicin, dexamethasone.

cytarabine. No matched related stem cell donors were found and she is being evaluated for a matched unrelated donor transplant.

### 3. Discussion

The 2008 WHO criteria for MPAL relies on immunophenotypic demonstration of antigens of more than one lineage (myeloid, b lymphocytic or t lymphocytic), exclusion of AML cases with recurrent cytogenetic abnormalities and exclusion of AML with myelodysplasia (MDS) related changes [1]. The expression of cytoplasmic CD3 and myeloperoxidase on the blasts of our patient support the diagnosis of MPAL. Recurrent cytogenetic abnormalities commonly seen in acute myeloid leukemia were excluded. The presence of significant number of hypo-granular and hypolobate neutrophils in our patients blood smear initially led to a suspicion of myelodysplastic syndrome related acute leukemia. However, we did not identify any significant dysplastic features in her erythroid or megakaryocytic series and there was no history of an antecedent hematological disease. The 2008 WHO criteria for AML with MDS related changes requires the demonstration of dysplastic features in 2 or more cells of myeloid series. This requirement was not met and our patient was diagnosed with MPAL.

Cytogenetic findings are important determinants of prognosis in cases of acute leukemia and in some instances define specific subtypes of acute leukemias with distinct biology and clinical features. We performed a literature search and identified 4 previously published reports of trisomy 4 associated biphenotypic acute leukemia. These are presented in Table 1.

Of note, cases reported by Britton et al. and Keung et al. rely on the demonstration of CD7 and TDT along with myeloid markers to classify the blasts as “biphenotypic” [8,9]. Expression of CD3 is not reported by the authors and these cases would not meet the current 2008 WHO criteria for MPAL.

Age of these patients vary from 5 to 50 years with a median age of 24. There were 2 males and 3 females. Among these 5 reported cases, 2 are of hispanic decent (40%) and this association should be explored further in larger series. Four cases expressed t/myeloid antigens and one expressed b/myeloid markers. Of the three cases with t/myeloid MPAL who underwent molecular studies for t-cell receptor (TCR) gene rearrangement, none showed a clonally rearranged TCR. CBC showed a median white cell count of 40,400/ $\mu$ l (range 5500–403,000/ $\mu$ l), hemoglobin of 8.9 g/dl (range 3.2–9.6 g/dl) and platelet count of 27,000/ $\mu$ l (range 6000–91,000/ $\mu$ l). Median blast count was 80% (range 54–95%). Blast morphology was most commonly reported as resembling FAB L2.

Presence of trisomy raises the possibility of added gene dose contributing to the leukemogenic process. The oncogene, c-kit, is localized to chromosome 4. Leukemic blasts of our patient strongly expressed c-kit. c-Kit expression was not studied in the other 4 reported cases of MPAL. Increased expression of c-kit in patients with acute myeloid leukemia harboring trisomy 4 has been documented in the past [10]. Activating c-kit mutations were not detected in our patient and as c-kit expression is a common finding in acute myeloid leukemia's irrespective of cytogenetic features, the role of c-kit in these leukemias remain speculative [11].

One of the reported cases of trisomy 4 associated MPAL identified prior pesticide exposure of the patient before development of acute leukemia [7]. The presence of pseudo Pelger-Huet cells in our patient also raises the possibility of a prior environmental exposure contributing to the dysplastic changes. Of note, case reports of AML with trisomy 4 have also previously reported environmental exposure as a possible risk factor [12].

Three patients received an AML like induction based on cytarabine and anthracycline. Of these, two failed to achieve a remission and the third relapsed in 10 months. Two patients (including this case) received an ALL like regimen. Both achieved a complete remission. This is consistent with prior reports suggesting superior responses to an ALL like regimen in MPAL [2].

### 4. Conclusions

MPAL with trisomy 4 is a rare malignancy with heterogenous clinical and immunophenotypic features. Further studies need to clarify the potential role of environmental toxin exposures and role of c-kit oncogene in the pathogenesis of this disease. In addition, future case reports need to specify the racial background of the patients to see if there is a hispanic predisposition. Prognosis is poor however outcomes seem better when ALL like treatment protocols are followed.

### References

- [1] Swerdlow SH, Campo E, Harris NL, Jaffe ES, Pileri SA, Stein H. WHO classification of tumours of the haematopoietic and lymphoid tissues. 4th ed. Lyon, France: IARC; 2008.
- [2] Matutes E, Pickl WF, Van't Veer M, Morilla R, Swansbury J, Strobl H, et al. Mixed-phenotype acute leukaemia: clinical and laboratory features and outcome in 100 patients defined according to the WHO 2008 classification. *Blood* 2011;117:3163–71.
- [3] Manola KN. Cytogenetic abnormalities in acute leukaemia of ambiguous lineage: an overview. *Br J Haematol* 2013;163:24–39.
- [4] Bains A, Lu G, Yao H, Luthra R, Medeiros LJ, Sargent RL. Molecular and clinicopathologic characterization of AML with isolated trisomy 4. *Am J Clin Pathol* 2012;137:387–94.
- [5] Mitelman Database of Chromosome Aberrations and Gene Fusions in Cancer. Mitelman F, Johansson B and Mertens F, editors. (<http://cgap.nci.nih.gov/ezproxy.ttuhsu.edu/Chromosomes/Mitelman>).
- [6] Al-Qurashi F, Owaidah T, Iqbal MA, Aljurf M. Trisomy 4 as the sole karyotypic abnormality in a case of acute biphenotypic leukemia with T-lineage markers in minimally differentiated acute myelocytic leukemia. *Cancer Genet Cytogenet* 2004;150:66–9.
- [7] Cox-Froncillo MC, Zollino M, Poeta GD, Bajer J, Stasi R, Venditti A, et al. Trisomy 4 as the sole karyotypic anomaly in acute biphenotypic leukemia with B lineage markers and in acute minimally differentiated myeloid leukemia (MO). *Cancer Genet Cytogenet* 1995;80:66–7.
- [8] Britton V, Kwan YL, White L, Yip MY. Trisomy 4 in a case of acute biphenotypic leukemia. *Cancer Genet Cytogenet* 1990;47:265–9.
- [9] Keung YK, Kaplan B, Douer D. Biphenotypic M0 acute myeloid leukemia with trisomy-4. *Leuk Lymphoma* 1994;14:181–4.
- [10] Ferrari S, Grande A, Zucchini P, Manfredini R, Tagliafico E, Rossi E, et al. Overexpression of c-kit in a leukemic cell population carrying a trisomy 4 and its relationship with the proliferative capacity. *Leuk Lymphoma* 1993;9:495–501.
- [11] Bains A, Lu G, Yao H, Luthra R, Medeiros LJ, Sargent RL. Molecular and clinicopathological characterization of AML with isolated trisomy 4. *Am J Clin Pathol* 2012;137:387–94.
- [12] Sandberg AA, Morgan R, Sait SN, Berger R, Flandrin G, Schrier S, et al. Trisomy 4: an entity within acute nonlymphocytic leukemia. *Cancer Genet Cytogenet* 1987;26:117–25.