



Case report

Jejunal intussusception on jejunostomy tube: A rare cause of occlusion in adults

A. Chirihan^{a,*}, S. Ezzaky^a, I. Eloual^a, A. Madani^b, L. Jroundi^a, F.Z. Laamrani^a^a Radiology Department, Hospital Ibn Sina, Faculty of Medicine and Pharmacy, Mohammed V University, Rabat, Morocco^b Department of General Surgery, CHU Mohamed VI, Oujda, Morocco

ARTICLE INFO

Keywords:

Acute intestinal intussusception

Jejunostomy tube

Occlusion

ABSTRACT

Introduction: Acute intestinal intussusception (AI) in adults secondary to jejunostomy is a rare complication and a surgical emergency requiring early diagnosis and treatment.

Presentation of case: We report the case of a 44-year-old patient, without medical history, who presented dysphagia after caustic ingestion. The patient underwent a Witzel feeding jejunostomy. The evolution was marked by the installation of abdominal distension with vomiting and alteration of the general state, the diagnosis of an intussusception in the jejunostomy tube was made in the abdominal CT scan, which required a surgical intervention, and reduction of intussusception, with simple after effects.

Discussion: Acute intestinal intussusception (IIA) secondary to jejunostomy tube placement is a rare abdominal emergency. It manifests with signs of upper gastrointestinal obstruction. Diagnosis is based on abdominal imaging by ultrasound or CT scan. Treatment is most often surgical (Chavrier et al., 1992) [1].

Conclusion: We present a very rare example of acute intestinal intussusception in adults, complicating jejunostomy, with non-specific clinical signs, which needed an early radiological diagnosis for adequate management.

1. Introduction

Feeding jejunostomy (FJ) is a simple surgical procedure. However, it can result in complications that may be life threatening. The most common complications are mechanical, such as tube migration or dislocation, infection, fluid and electrolyte imbalances, as well as gastrointestinal symptoms. Intestinal intussusception on jejunostomy tube in adults is a very rare complication that is not frequently reported in the literature. It represents a surgical emergency requiring an early diagnosis and management which is often surgical, as we illustrate in this case. This work has been reported in line with the SCARE criteria [2].

2. Observation

A 44-year-old man, without notable personal or family medical history, except for socio-economic problems. Presented with dysphagia after a suicide attempt by caustic ingestion, which progressively turned into a total dysphagia with alteration of the general state, He underwent a gastrojejunostomy according to the Witzel technique, the operative

follow-up was simple with adequate nutritional support from the FJ. However, the seventh day after surgery, the patient developed severe abdominal pain associated with abdominal distension and bilious vomiting, the clinical examination revealed abdominal distension with diffuse pain on palpation; compatible with a digestive obstruction syndrome. An abdominal CT scan with contrast shows a median mass presenting a continuity with the jejunal coves giving a target appearance on axial section and a sausage sign on coronal and sagittal section, with a hypodense center, representing the mesenteric fat, with mesenteric vessels and a distension of the proximal jejunal and oeso-gastro-duodenal loops which is compatible with jejuno-jejunal intussusception. The jejunostomy tube is seen within this structure extending to more than 10 cm (Fig. 1).

The surgery was indicated by the general surgeon who re-operated the patient in the sixth day of the jejunostomy, the intervention was performed by median laparotomy, a proximal small intussusception was found, located at 35 cm from the angle of Treitz, extending over 20 cm with a jejunostomy tube within and a viable digestive tissue (Fig. 2).

Manual reduction and placement of a second jejunostomy was decided, without any postoperative follow-up complications and a

* Corresponding author at: Emergency Radiology Department, Hospital Ibn Sina, Faculty of Medicine and Pharmacy, Mohammed V University, Rabat, Morocco.
E-mail address: chirihane.ayadi@gmail.com (A. Chirihan).

complete resolution of symptoms.

3. Discussion

Jejunostomy is a surgical enteral nutrition procedure that is typically used to improve preoperative nutritional status in patients with upper

gastrointestinal disease or as an additional procedure during major upper gastrointestinal surgery. Feeding jejunostomy can be performed with several techniques, including needle catheter technique, Witzel-Stem open longitudinal incision, percutaneous or laparoscopic endoscopy [3].

The complications of feeding jejunostomy are multiple and variable,

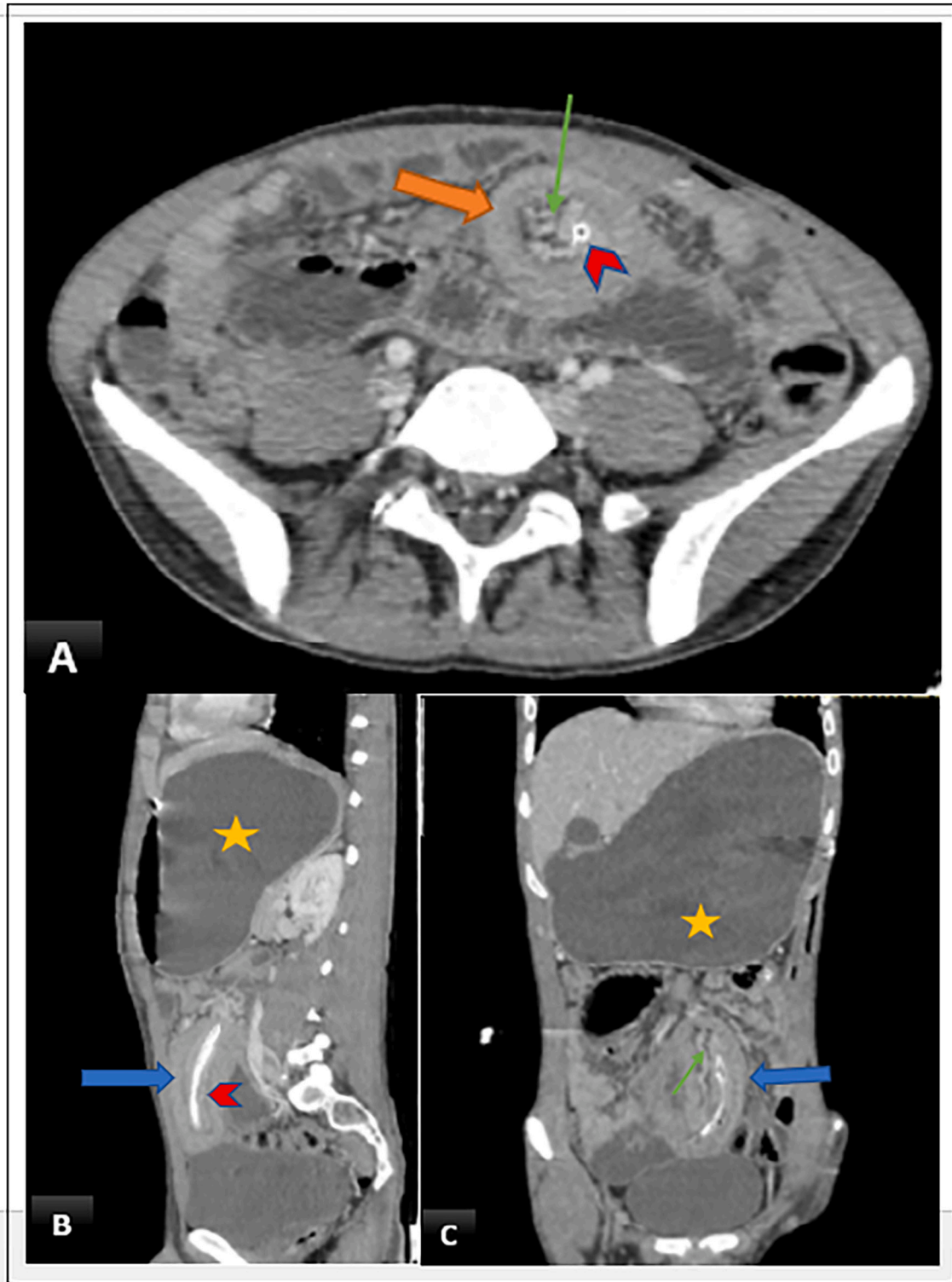


Fig. 1. Abdominal CT scan in enhanced axial section (A); in the reconstruction of the sagittal (B) and coronal (C) section, showing a target sign of jejunojejunal intussusception (orange arrow), containing mesenteric fat and vessels (green arrow), with a jejunostomy tube in the center (head arrow), and a sausage sign in the sagittal and coronal slice (blue arrow), responsible for upstream distension.

ranging from simple gastrointestinal symptoms including nausea, vomiting, diarrhea, constipation, abdominal distention, or mechanical complications such as tube migration, dislocation, skin orifice or intra-abdominal abscesses, and electrolyte imbalances, until an intussusception on the jejunostomy probe, which is the case of our patient [4].

Intussusception of the intestinal tract in adults is rare, accounting for 1 % of all cases of small bowel obstruction and 5 % of all cases of intussusception [5]. The average age of occurrence is 50 years and the sex ratio is 1. They can be anterograde or retrograde [6] risk factors that can be represented by surgical manipulation and postoperative inflammation, spasm and exaggerated peristalsis reaction to the presence of the probe in the digestive lumen, and the formation of postoperative adhesions [7].

Intussusception of the intestinal tract in adults with non-obstructed orifice, is difficult to diagnose as the clinical presentation is nonspecific or has no symptoms in 20 % of cases, and often intussusception in adults is misdiagnosed [8].

However, the presence of bloody stools, abdominal pain, and a palpable abdominal mass is very suggestive. A palpable abdominal mass is very suggestive [9].

In radiology, abdominal CT is the most sensitive and specific exam to confirm the diagnosis of intestinal intussusception. Radiological features suggestive are a target or sausage-shaped mass, referring to a bowel configuration in the other bowel, with a hypodense center, which corresponds to the mesenteric fat containing mesenteric vessels. The presence of a hyperdense bottom material is highly suggestive of a jejunostomy tube. Furthermore, it may provide information on the length and diameter of the intussusception, the point of entry, the type and location of the intussusception, the presence or absence of bowel obstruction, and signs of parietal injury [10]. Ultrasonography can make the diagnosis of intestinal intussusception in adults by showing target or

sandwich appearances, but it may be limited by obesity and severe abdominal distension [11].

The therapeutic attitude to intussusception caused by feeding tubes in adults can be conservative in case clinical and radiological features favor a transient intussusception with the possibility of spontaneous resolution. Changing the tube with a short one without distal pigtail can also be proposed, by injecting air or contrast medium [12]. However, these measures are limited to patients without any signs of severity or who have a high risk of developing a cancer related to short bowel syndrome. The surgical treatment remains, by and large, the first-choice treatment, as Wu et al. recommended surgery for all cases with signs of obstruction [13].

4. Conclusions

Acute intestinal intussusception on jejunostomy tube in adults is a complication not frequently described in the literature, it represents an abdominal emergency requiring a rapid diagnosis and early intervention to avoid intestinal necrosis.

Consent

Written informed consent was obtained from the patient for publication of this case report and accompanying images.

Provenance and peer review

Not commissioned, externally peer-reviewed.

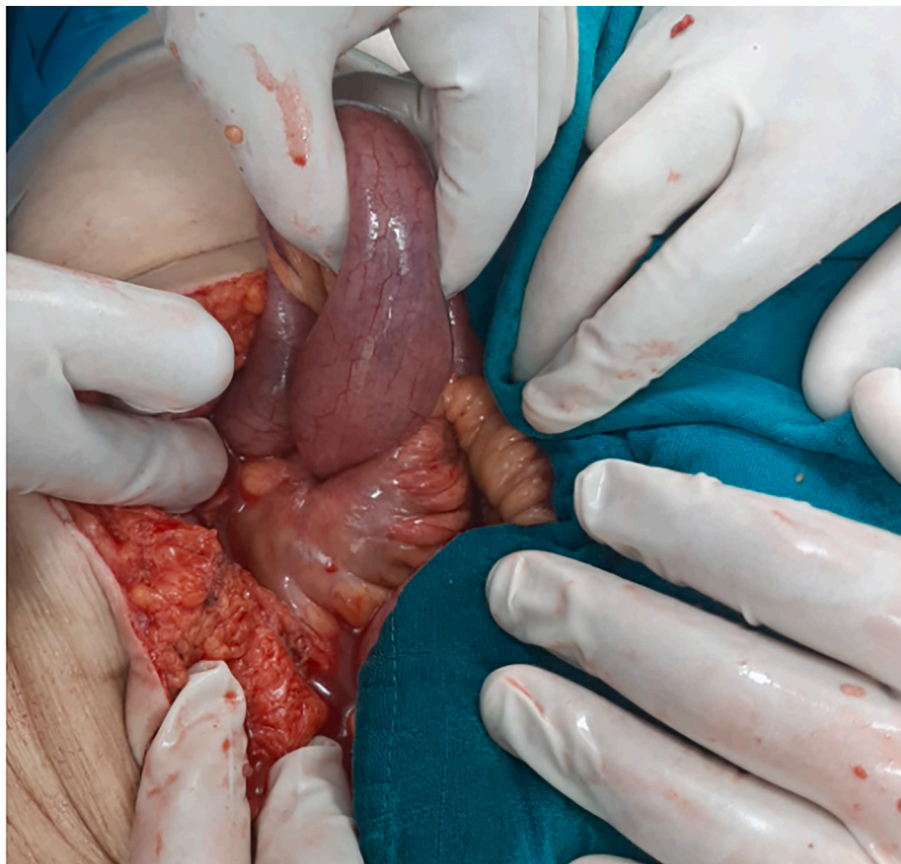

Fig. 2. Operative image showing the jejunojunal intussusception.

Ethical approval

Not required for this case report.

Funding

There is no source of funding for our research.

Guarantor

Ayadi Chirihan.

Research registration number

N/A.

CRedit authorship contribution statement

- **Dr. Ayadi Chirihan, Dr. Ezzaky Sara, Dr. El ouali Ibtissame, Pr. Jroundi Laila, Pr. Laamrani FatimaZahra:** Interpretation of radiological data, data collection, data analysis and interpretation, article writing.
- **Dr. Madani Ayoub:** Have helped in writing article and data collection.

Declaration of competing interest

The authors report no declarations of interest.

References

- [1] Y. Chavrier, D. Tardieu, D. Allard, Evolution of operative and nonoperative treatment of acute intestinal intussusception in children, *Pediatrics* 47 (7-8) (1992) 575–578. PubMed | Google Scholar.
- [2] R.A. Agha, T. Franchi, C. Sohrabi, G. Mathew, for the SCARE Group, The SCARE 2020 guideline: updating consensus Surgical CASE REport (SCARE) guidelines, *Int. J. Surg.* 84 (2020) 226–230.
- [3] J. Tapia, R. Murguia, G. Garcia, P.E. de los Monteros, E. Oñate, Jejunostomy: techniques, indications, and complications, *World J. Surg.* 23 (1999) 596–602, <https://doi.org/10.1007/pl00012353>.
- [4] Souradeep Dutta, Naveen Kumar Gaur, Abhinaya Reddy, Ankit Jain Vishnu Prasad Nelamangala Ramakrishnaiah : Antegrade Jejunojunal Intussusception: An Unusual Complication Following Feeding Jejunostomy. 10.7759/cureus.13264.
- [5] A. Marinis, A. Yiallourou, L. Samanides, N. Dafnios, G. Anastasopoulos, I. Vassiliou, T. Theodosopoulos, Intussusception of the bowel in adults: a review, *World J. Gastroenterol.* 15 (2009) 407–411, <https://doi.org/10.3748/wjg.15.407>.
- [6] U. Pua, Multisegment jejunojejunal intussusception in gastrojejunostomy, *Med. J. Aust.* 1 (Aug 2011) 14. PubMed | Google Scholar.
- [7] L. Pelosof, D.A. Ringold, E. Kuo, Retrograde jejunojejunal intussusception caused by a migrated gastrostomy tube, *Endoscopy* 39 (Suppl 1) (2007 Feb), E262. PubMed | Google Scholar.
- [8] M. Barussaud, N. Regenet, X. Briennon, et al., Clinical spectrum and surgical approach of adult intussusceptions: a multicentric study, *Int. J. Color. Dis.* 21 (834–839) (2006), <https://doi.org/10.1007/s00384-005-0789-3>.
- [9] M. Ishii, M. Yakabe, S. Teramoto, A 94-year-old woman with nontuberculous mycobacterium who developed small intestinal intussusception associated with a percutaneous endoscopic jejunostomy tube, *Nihon Ronen Igakkai Zasshi* 44 (5) (2007) 648–652. PubMed | Google Scholar.
- [10] G. Gayer, R. Zissin, S. Apter, M. Papa, M. Hertz, Pictorial review: adult intussusception—a CT diagnosis, *Br. J. Radiol.* 75 (2002) 185–190, <https://doi.org/10.1259/bjr.75.890.750185>.
- [11] B. Ana, B. Hamilton, P. Carlos, Jejuno-jejunal invagination caused by epithelioid sarcoma: a case report, *J. Med. Case Rep.* 3 (2009) 89. PubMed | Google Scholar.
- [12] B.L. Connolly, P.G. Chait, R. Siva-Nandan, D. Duncan, M. Peer, Recognition of intussusceptions around gastrojejunostomy tubes in children, *AJR Am. J. Roentgenol.* 170 (1998) 467–470 [Abstract] [Google Scholar].
- [13] H. Sakthivel, A.K. Sahoo, A. Amaranathan, N. Raj Kumar, N.K. Maraju, A surgical conundrum in feeding jejunostomy-jejunojejunal intussusception: a case series, *Cureus* 10 (2018), e2233, <https://doi.org/10.7759/cureus.2233>.